



## Pathological and Ultrastructural Study on the Chronic Liver Damage Induced by Thioacetamide in Male Rats



Sohaila Abd El-Hameed<sup>1\*</sup>, Iman Ibrahim<sup>1</sup>, Walaa Awadin<sup>1</sup> and Ahmed El-Shaieb<sup>2</sup>

<sup>1</sup> Department of Pathology, Faculty of Veterinary Medicine, Mansoura University, Mansoura, Egypt.

<sup>2</sup> Department of Pathology, Faculty of Veterinary Medicine, Egyptian Chinese University, Cairo, Egypt.

### Abstract

**T**HIOACETAMIDE (TAA) is an organosulfur compound used as a sulfur donor in many industrial pharmaceuticals. The exposure to TAA could happen through inhalation, ingestion, and injection. It resists biodegradation and causes liver necrosis and fibrosis. In the current study, twenty male Sprague Dawley rats (160-200g) were divided into two groups (control group and TAA group, n=10). In the TAA group, the rats received an intraperitoneal (i.p) dose of TAA at 150 mg/kg/biweekly/nine weeks. The mortality rates were calculated at the end of the experiment. The values of alkaline phosphatase (ALP) and total bilirubin (T.B) were estimated in serum. The livers were examined macroscopically, microscopically, and ultrastructurally to detect any pathological alterations. According to the results, the TAA group recorded a high mortality rate (50%) indicating liver failure. Additionally, the same group showed significant increases in the serum ALP and T.B. TAA induced severe liver cirrhosis represented by irregular nodular liver surfaces, besides, the presence of prominent neoplastic masses in the gross examination. The microscopic examinations revealed diffuse replacement of the hepatic parenchyma by thick fibrous tissue surrounding the regenerative hepatic nodules, dysplastic megahepatocytes with nuclear changes, and development of tubular hepatocellular carcinoma. Moreover, the ultrastructural examination showed nuclear changes, massive mitochondrial damage and fragmentation of the rough endoplasmic reticulum. In conclusion, chronic exposure to TAA induced serious alterations in the livers of rats biochemically, macroscopically, microscopically, and ultrastructurally. Therefore, it is a life-threatening and a public health hazard toxin. High safety precautions should be applied before/during the exposure to TAA.

**Keywords:** TAA, Liver cirrhosis, Rats, Pathological alterations.

### Introduction

The liver is a key organ responsible for metabolism of drugs, and nutrients and waste metabolite excretion. It is also the biggest solid organ and gland in all vertebrates [1]. Its principal role is to regulate the flow and safety of chemicals ingested from the digestive system before they are sent to the circulatory system. Therefore, the complete loss of liver functions can result death, highlighting the liver's crucial role. Death the end result of both acute and chronic liver failure [2]. Liver injury is followed by biochemical and pathological alterations, and consequence by liver fibrosis, cirrhosis and even death [3]. Thioacetamide (TAA) is a water-soluble organosulfur chemical that is commonly used in leather processing and paper industries [4]. It has been recognized to cause hepatotoxicity since 1948

[5]. TAA passes through two steps of bioactivation, first to sulfine and then to sulfene. Sulfine causes nucleoli to grow, increases nuclear volume, alters cell permeability, and inhibits mitochondrial activity [6]. Simultaneously, sulfene triggers the release of nitric oxide synthase and nuclear factor kappa beta, which leads to protein denaturation, lipid peroxidation, and necrosis of the liver cells [7]. TAA is the model hepatotoxin that can cause acute and chronic liver injury [4]. The liver parenchyma of rats exposed to a single dose of TAA (200 mg/kg) showed periportal leukocytic cell infiltration, congested portal blood vessels, arteritis with thrombosis, and multifocal area of necrosis [8]. Additionally, two i.p doses of TAA (300 mg/kg/24-hour intervals) induced severe necrosis and inflammation in the hepatic parenchyma of rats after 24 hours of the second injection [9]. It was reported

\*Corresponding authors: Sohaila Abd El-Hameed, E-mail: drsohailaabelhameed@mans.edu.eg, Tel.: 01006802145 (Received 04/05/2024, accepted 06/07/2024)

DOI: 10.21608/EJVS.2024.286987.2057

©National Information and Documentation Center (NIDOC)

that chronic exposure to TAA is associated with advanced liver damage and cirrhosis with the formation of macroscopic and microscopic nodules [10]. In a rat model, TAA induced centrilobular necrosis and fibrosis in the liver parenchyma after 10 weeks of intraperitoneal (i.p) injection at 200 mg/kg/twice weekly [11]. Moreover, the i.p administration of TAA in rats (three consecutive doses at 400 mg/kg at 24-hour intervals) resulted in liver damage [12]. The current study aimed to investigate the morphological, structural, and ultrastructural pathological alterations associated with chronic exposure to TAA in male rats.

## **Material and Methods**

### *Preparation of thioacetamide (TAA)*

Thioacetamide (TAA) was obtained from Oxford Company, India in the form of whitish crystals and dissolved in sterilized water to form a sterile solution.

### *Experimental design*

Twenty mature male Sprague Dawley rats (160-200g) were purchased from the Animal Experimental Centre, Zagazig University. After one week of adaptation, the rats were randomly divided into two groups (n=10), the control group (received no treatments) and the TAA group (TAA 150 mg/kg/i.p/biweekly) [13]. The rats were kept under hygienic conditions and a 12-hour dark/12-hour light cycle for nine successive weeks (Fig.1).

### *Clinical observations and mortality rates*

The clinical signs and mortalities were checked and registered daily till the end of the experiment. The mortality rates were calculated and represented in percentage (%).

### *Samples collection*

After the end of the ninth week, the rats were anesthetized by thiopental sodium (20 mg/kg/i.p), and blood samples were collected from the retro-orbital veins, centrifuged (4000 rounds per minute for 10 minutes), and stored at -20°C. After that, the rats were humanely euthanized using the cervical dislocation method and the necropsy took place immediately. Livers from the experimental groups were grossly examined for the detection of any macroscopic lesions. Formalin-fixed liver samples (10% neutral buffered formalin) and glutaraldehyde-preserved liver tissues (4% glutaraldehyde) were collected for microscopical, and ultrastructural examinations respectively. All procedures were carried out at the Faculty of Veterinary Medicine, Mansoura University.

### *Estimation of Alkaline phosphatase (ALP) and total bilirubin (T.B) in serum*

#### *Estimation of alkaline phosphatase (ALP) activity*

The kit was derived from Spectrum Diagnostics (Spectrum Diagnostics Egyptian Company for Biotechnology, Cairo, Egypt). The enzyme activity was measured according to the kinetic method of the International Federation of Clinical Chemistry. The activity of ALP was detected by the following equation, p-Nitrophenylphosphate+H<sub>2</sub>O in the presence of ALP-produced p-nitrophenol and phosphate. The enzyme activity was proportional to the increase of absorbance per minute at 405 nm using (Jenway UV/Vis 1506/UK) spectrophotometer. The enzyme activity of ALP in the serum sample U/L was calculated by  $5454 \times \Delta A$  at 405nm/min [14].

#### *Estimation of total bilirubin (T.B) level*

The kit was achieved from Diamond Diagnostics (Diamond Diagnostics Company, Cairo, Egypt). The interaction between Bilirubin and diazotized sulfanilic acid produces colored azobilirubin. The bilirubin concentration in the sample is directly proportional to the intensity of the color formed [15].

### *Pathological examinations*

#### *Macroscopic examination*

Livers were examined by naked eyes for any pathological alterations and photographed by Canon 4000 d digital camera.

#### *Microscopic examination*

The formalin-fixed samples were washed by water, dehydrated by alcohol, cleared by xylene, paraffinized by paraffin wax, sectioned by microtome (5µm thick), deparaffinised by xylene, rehydrated, and finally stained by either hematoxylin and eosin (H&E) or Masson's trichrome (MTC) stain [16]. The microscopic slides were examined by XSZ-107BN biological microscope and photographed by sc30 Olympus camera.

#### *Ultrastructural examination*

This was applied using a transmission electron microscope (TEM). The glutaraldehyde-preserved tissue samples were washed in cacodylate, followed by post-fixation in O<sub>4</sub>S<sub>4</sub> (1 %), rewashed in buffer, dehydrated by alcohol, embedded in aepon and araldite mixture, sectioned by LK ultramicrotome (0.5–1 µ thick), stained by toluidine blue, and resectioned by Leica AG ultra-microtome (500–700 Å thick) [17]. The prepared sections were examined at 80 KV using a JEM 100 CXII electron microscope. The tissue micrographs were taken by a CCD digital camera, Model XR- 41.

#### *Statistical analysis*

This was completed using Graph Pad Software (one way ANOVA and Tukey method) [18]. The results of the serum biochemical analysis were stated as mean ± SD (P<0.0001).

## Results

The clinical signs of rats in the current study were observed and recorded in each group. Rats in the control group showed normal appearance with physical conditions and viability during the whole time of the experiment. In contrast, rats in the TAA group showed weakness, low viability and decrease in the normal physical activities from the 2nd week of TAA treatments and continued to the end of the experiment. The mortality rate in the control group was zero %. The TAA group recorded a high mortality rate (50%) at the 3<sup>rd</sup>, 5<sup>th</sup>, 6<sup>th</sup>, 7<sup>th</sup> and 9<sup>th</sup> weeks of TAA treatments (Fig.2).

The TAA group revealed a significant increase in the serum activity of ALP and the level of T.B compared to the control group (Table 1).

Macroscopically, livers of the control group showed normal hepatic surfaces, size, color, and texture (Fig.3 A). Meanwhile, livers of the TAA group were pale in color, firm consistency, not easy to be cut, irregular nodular dorsal and ventral surfaces with macroscopic neoplastic masses (Fig.3, B&C).

Microscopically, the liver sections of the control group showed normal liver parenchyma with no pathological alterations (Fig.4, A1&A2). In TAA treated group, the liver sections showed severe disruption the liver architecture, diffuse proliferation of fibrous tissues infiltrated with leukocytes, which forming thick fibrous septa surrounding the regenerative nodules, hepatocytes with atypic nuclei, and dysplastic megahepatocytes with abnormal mitotic figures (Fig.4, B1-B4). Furthermore, liver sections from the TAA group exhibited tubular hepatocellular carcinoma with the hepatocytes showing the criteria of malignancy (Fig.5, A-C).

The Masson's trichrome stained liver sections showed normal liver parenchyma in the control group (Fig.6, A1&A2). Meanwhile, diffuse replacement of the liver tissue by thick fibrous tissue and collagen bundles were obvious in the TAA treated group (Fig.6, B1&B2).

Ultrastructurally, the TEM micrographs of the liver sections showed normal ultra-structures of nucleus, nucleolus, mitochondria and rough endoplasmic reticulum in the control group (Fig.7, A). However, the TAA exposed group exhibited extensive nuclear changes as shrunken, bilobed, segmented nucleus, clumped irregular nucleus with increased dark heterochromatin, loss of nucleolus, and fragmented nuclear membrane. The cytoplasm was mostly deteriorated with extensively fragmented rough endoplasmic reticulum, abundant lysosomes, numerous autophagic vacuoles, and large lipid particles. In addition, the mitochondria appeared reduced in number, clumped, and shrunken with a dense matrix (Fig.7, B1&B2).

## Discussion

Liver cirrhosis is a leading disease associated with numerous pathological progressions, counting progressive fibrosis, portal hypertension, and carcinoma. In this study, TAA treatments recorded a high mortality rate, which indicated the collapse of the residual liver function and the replacement of the normal parenchyma by fibrous tissue [19]. TAA is a powerful solvent, which induces hepatic necrosis, fibrosis, cirrhosis and cancer [20]. At that point, the study of the pathological and ultrastructural alterations of the liver after the chronic exposure to TAA is very urgent to be investigated to avoid the toxic hazards of this dangerous compound. In the current study, the TAA group revealed significant increases in the serum ALP and T.B signifying severe liver damage [21].

Macroscopically, the livers from the TAA treated group were pale in color, firm in consistency, and not easy to cut with irregular nodular dorsal and ventral surfaces; the same findings were reported by Su *et al.* (2020) [22]. Also, the liver surfaces exhibited the presence of neoplastic masses. Microscopically, the TAA-treated group showed deposition of thick collagen bundles that divided the parenchyma into separated nodules, which matched with the findings of the previous study of Hori *et al.* (2003) [23]. The macroscopical and microscopical examinations of the livers in the TAA group pointed toward severe liver cirrhosis with prominent cirrhotic nodules. These findings agreed with the findings of Hwang *et al.* (2012) [24]. Additionally, the macroscopic and microscopic examinations exposed tubular hepatocellular carcinoma. As far as we know, this is the first study recorded the development of tubular hepatocellular carcinoma after the exposure to TAA. Ultrastructurally, the hepatocytes in the TAA group showed nuclear changes with absence of the nucleolus, and an increase in the heterochromatin pointing toward dysplasia. The cytoplasm showed mitochondrial damage with depletion in number, and fragmentation of the rough endoplasmic reticulum indicating severe oxidative damage of the liver cells by the action of TAA intermediate metabolites [25, 26]. To the best of our knowledge, the ultrastructural study of chronic liver injury after exposure to TAA has not been discussed before. The biochemical, macroscopical and microscopical findings matched with each other and are in consistent with the ultrastructural findings. We suggested that TAA induced severe oxidative stress, which induced mitochondrial damage. The mitochondrial damage caused necrosis of the hepatocytes, which activated the hepatic stellate cells and, resulted in massive proliferation of the fibrous tissue. The fibrous tissue formed thick septa splitting the liver parenchyma into microscopic nodules. The presence of the regenerating hepatic nodules surrounded by fibrous tissue is a pathognomonic lesion of cirrhosis.

Moreover, we proposed that the persistent oxidative stress and mitochondrial damage with continuous production of the reactive oxygen species induced nuclear changes and initiated the development of the hepatocellular carcinoma.

### Conclusion

In conclusion, the prolonged exposure to TAA caused severe liver damage represented by alteration in the liver serum parameters (ALP&T.B), disruption of the liver architecture (grossly, microscopically, and ultrastructurally). TAA induced severe liver cirrhosis and initiated the development of tubular hepatocellular carcinoma. Therefore, TAA is a life threatening and carcinogenic toxin. Henceforth, high levels of safety precautions should be applied before and during the exposure to this dangerous compound.

### Acknowledgments

Not applicable.

### Funding statement

This study didn't receive any funding support.

### Declaration of Conflict of Interest

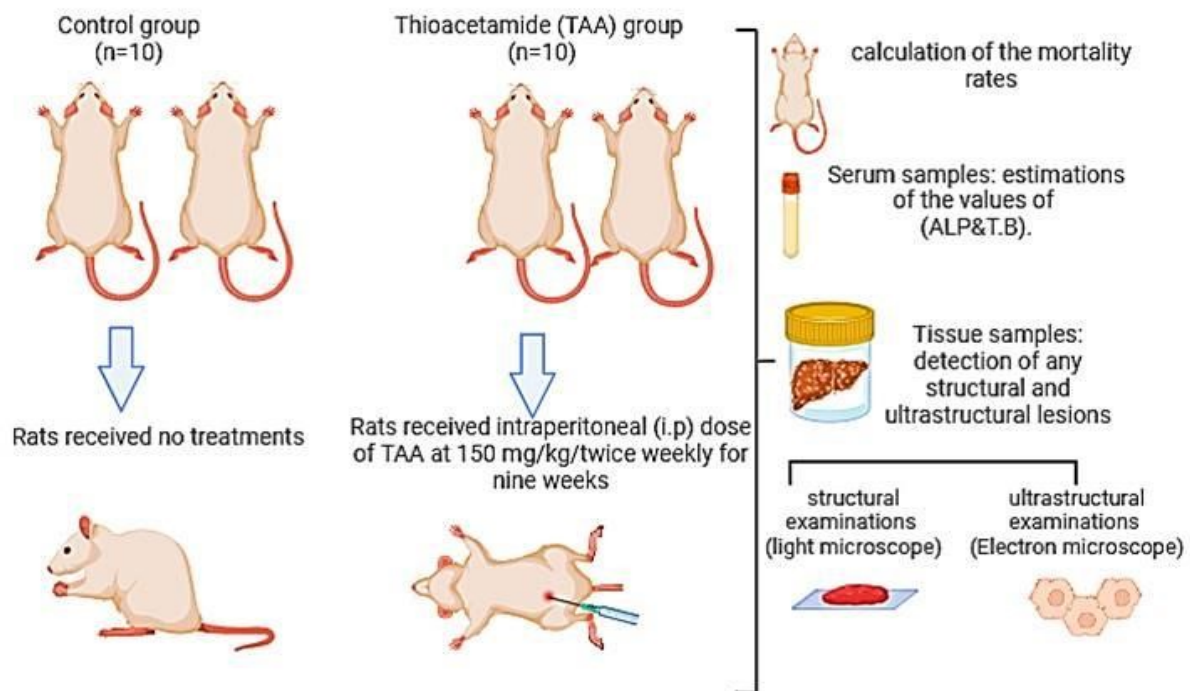
The authors declare that there is no conflict of interest.

### Ethical of approval

This study follows the ethics guidelines of the Faculty of Veterinary Medicine, Mansoura University, Egypt (ethics approval number; PhD, 85).

**TABLE 1.** Statistical analysis of the serum ALP (U/L) and T.B (mg/dl), Mean  $\pm$  SD, (\*\*\*) : significantly different from the control group,  $P < 0.0001$ ,  $n=3$ .

Serum parameter	ALP (U/L)	T.B (mg/dl)
Control group	233 $\pm$ 9.849	0.1633 $\pm$ 0.01528
TAA group	1483 $\pm$ 151.3***	3.613 $\pm$ 0.9989***



**Fig.1.** The *in vivo* experimental design in male rats (created by Biorender.com).

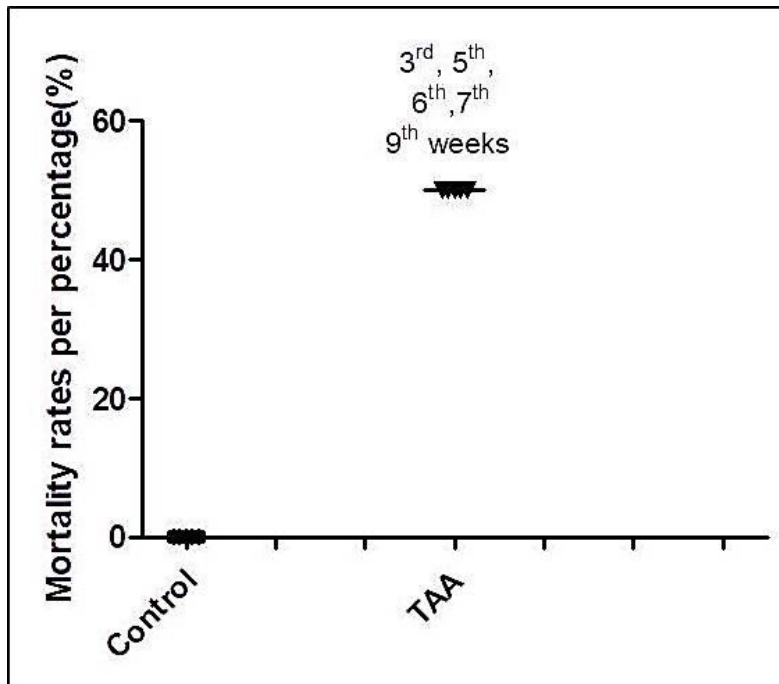


Fig.2 . The mortality rates in the studied groups expressed in percentage (%).

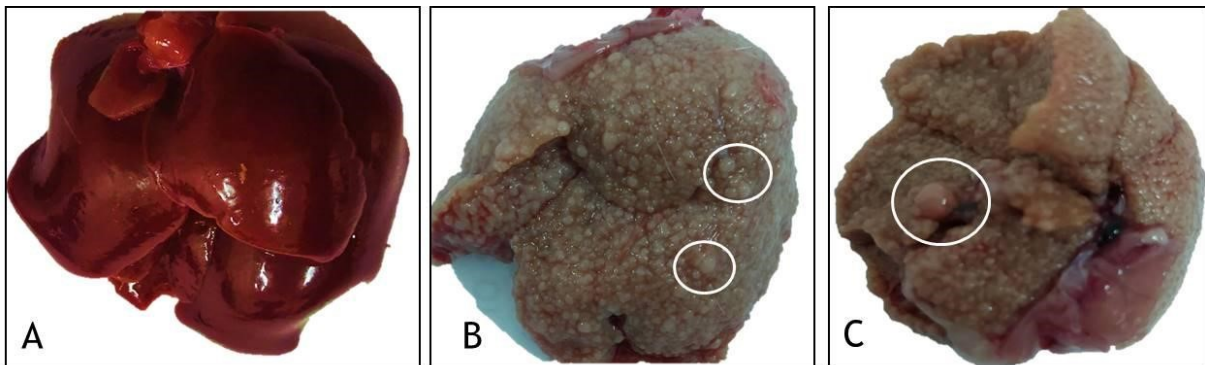


Fig. 3. Macroscopic picture of livers from the control and TAA groups, the control group showing normal liver surface, size, and color (A), The TAA group showing pale livers with nodular and irregular dorsal and ventral surfaces, and prominent neoplastic masses (white circles) (B1&B2).



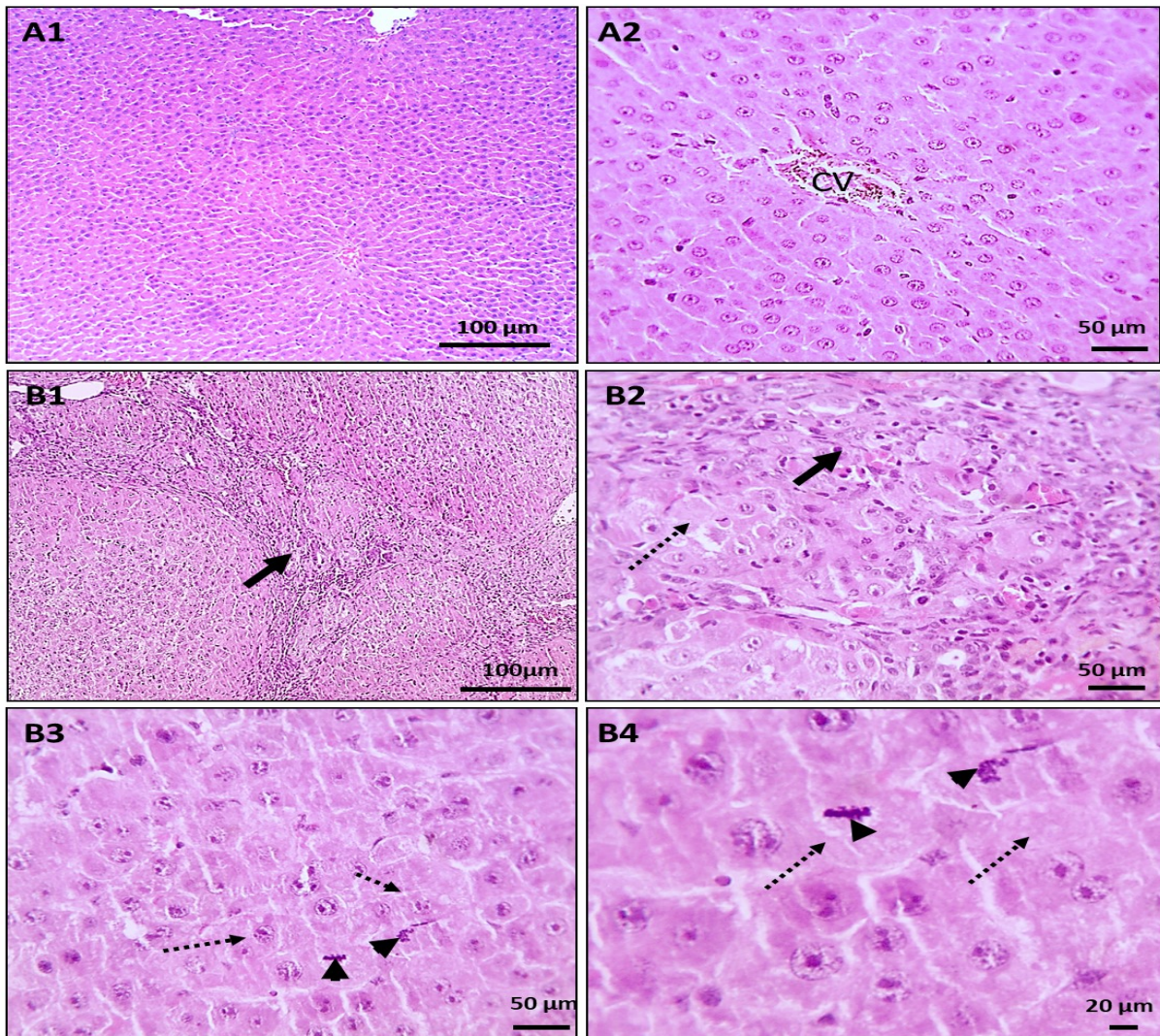


Fig. 4. Microscopic sections of livers from the control and TAA groups, (A): showing liver sections from the control group with normal liver parenchyma, normal central vein (CV), and no histopathological lesions. (B1&B2): liver sections from the TAA group, (B1): showing massive disruption of the liver architecture, diffuse replacement of the hepatic parenchyma by fibrous tissue infiltrated with inflammatory cells (thick arrows) surrounding the regenerative nodules (asterisks), dysplastic megahepatocytes (dashed arrows), and atypic nuclei with abnormal mitotic figures (arrow heads) H&E stain, X:100, Bar: 100 µm (A1&B1), X:400, Bar: 50 µm (A2&B2&B3), X:1000, Bar:20 µm (B4) .

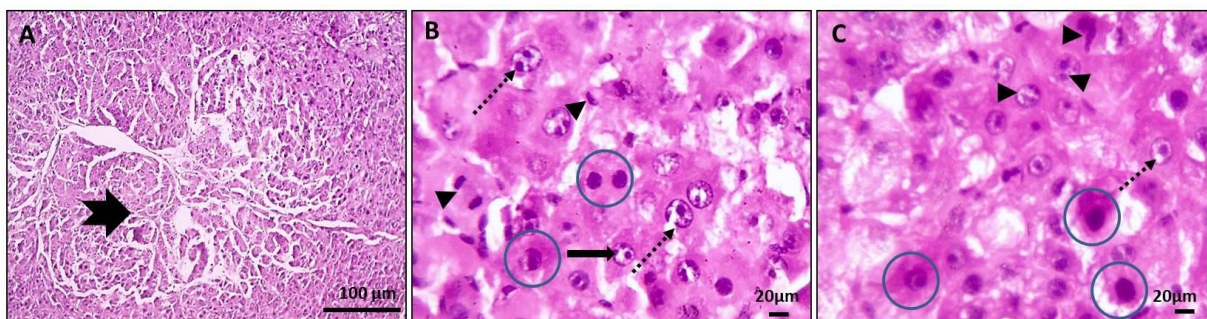


Fig. 5. Microscopic sections of livers from the TAA group showing tubular hepatocellular carcinoma (thick arrow). The cells showing the criteria of malignancy described as hyperchromatia (blue circles), enlarged vesicular nucleus with prominent eccentric nucleolus (dashed arrows), fragmented nucleolus (thin arrows) and numerous forms of mitotic figures are seen (arrowheads) are seen, H&E stain X:100, Bar: 100µm (A), X:1000, Bar:20 µm (B&C).



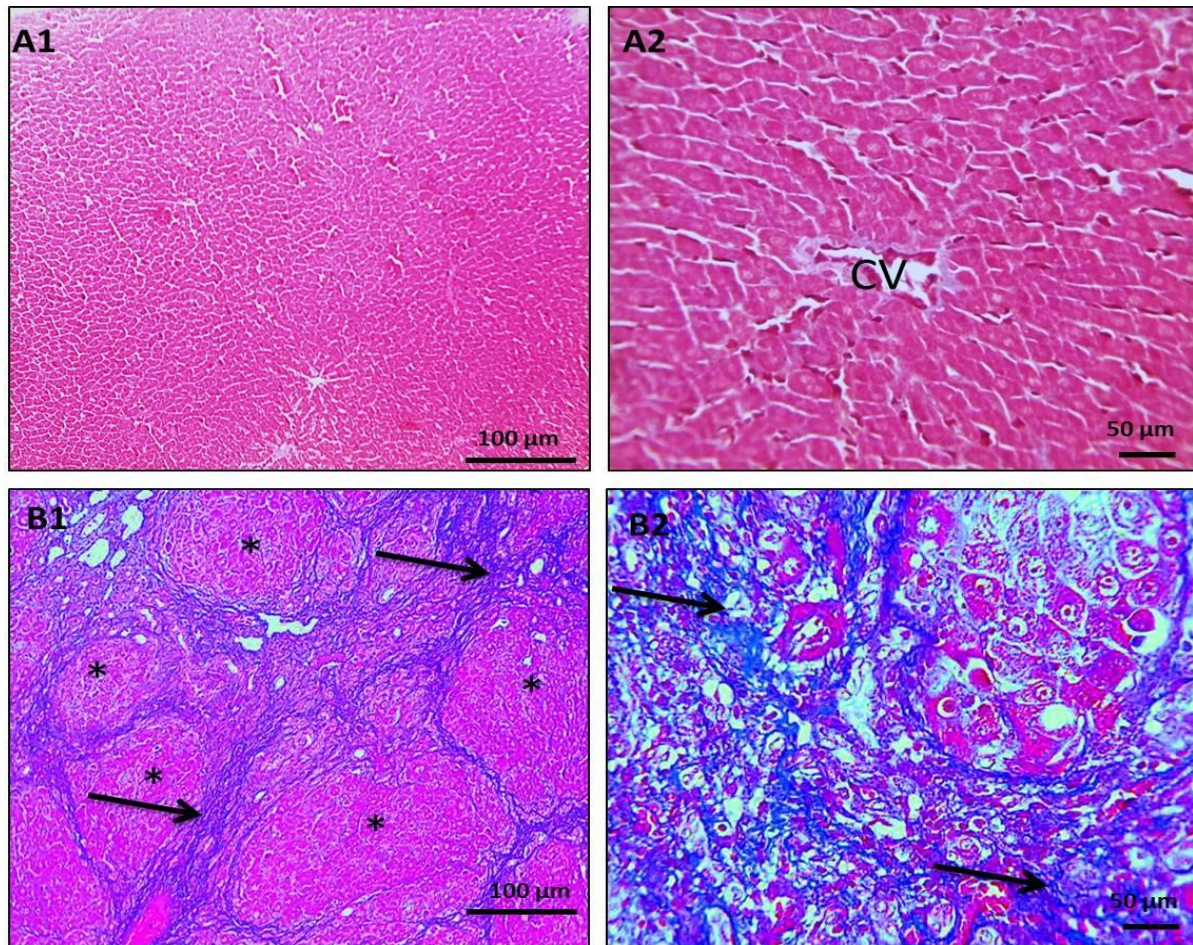


Fig. 6. Microscopic sections of livers from the control and TAA groups, (A1&A2): showing liver sections from the control group with normal liver parenchyma, normal central vein (CV), and no histopathological lesions. (B1&B2): liver sections from the TAA group showing diffuse proliferation of bluish fibrous tissue with deposition of the thick collagen bundles (arrows) surrounding the regenerative nodules (asterisks), MTC stain, X:100, Bar: 100 μm (A1&B1), X:400, Bar:50 μm (A2&B2).

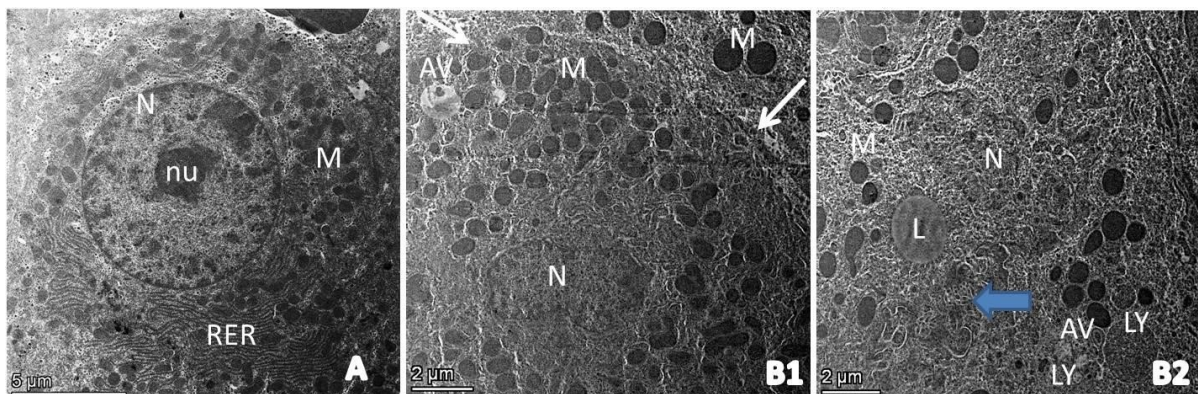


Fig. 7. TEM micrographs of livers from the control and TAA groups, (A): Control group; showing normal ultrastructures of the nucleus (N), nucleolus (nu) with numerous cytoplasmic mitochondria (M), and perinuclear rough endoplasmic reticulum (RER). (B1): TAA group; showing divided, bilobed, (N), minimal mitochondrial damage (M), few autophagic vacuoles (AV), and minimal loss of tight junction (white arrows). (B2): TAA group; showing clumped, irregular nucleus (N) with an increase in the dark heterochromatin, loss of nucleolus, and fragmented nuclear membrane. The cytoplasm showing fragmented RER (blue arrow), few large electron lucent lipid particles (L), abundant small electron dense lysosomes with numerous autophagic vacuoles (AV), and a marked reduction in the mitochondrial number, which mostly appeared clumped, shrunken with dense matrix, Bar: 5μm (A), Bar: 2 μm (B&C).

**References**

- Ozougwa, J. and Eyo, J. Hepatoprotective effects of Allium cepa (onion) extracts against paracetamol-induced liver damage in rats. *African Journal of Biotechnology*, **13** (26), 2680-2688 (2014).
- Alabdulaali, B., Al-Rashed, F., Al-Onaizi, M., Kandari, A., Razafiarison, J., Tonui, D., Williams, M. R., Blériot, C., Ahmad, R. and Alzaid, F. Macrophages and the development and progression of non-alcoholic fatty liver disease. *Frontiers in Immunology*, **14**, 1195699 (2023).
- Friedman, S. L. and Pinzani, M. Hepatic fibrosis 2022: Unmet needs and a blueprint for the future. *Hepatology*, **75** (2), 473-488 (2022).
- Akhtar, T. and Sheikh, N. An overview of thioacetamide-induced hepatotoxicity. *Toxin Reviews*, **32** (3), 43-46 (2013).
- Hajovsky, H., Hu, G., Koen, Y., Sarma, D., Cui, W., Moore, D. S., Staudinger, J. L. and Hanzlik, R. P. Metabolism and toxicity of thioacetamide and thioacetamide S-oxide in rat hepatocytes. *Chemical Research in Toxicology*, **25** (9), 1955-1963 (2012).
- Veerakumar, D. and Muthulingam, M. A REVIEW ON HEPATOTOXICANT OF THIOACETAMIDE (C<sub>2</sub>H<sub>5</sub>NS). *Journal of Experimental Zoology India*, **24** (2), 781 (2021).
- Akhtar, T., Sheikh, N., Abbasi, M. H. and Abbas, A. S. Effects of Nerium oleander leaves extract against thioacetamide induced Liver injury. *Biologia*, **60** (1), 37-41 (2014).
- Mousa, A. A., El-Gansh, H. A. I., Eldaim, M. A. A., Mohamed, M. A. E.-G., Morsi, A. H. and El Sabagh, H. S. Protective effect of Moringa oleifera leaves ethanolic extract against thioacetamide-induced hepatotoxicity in rats via modulation of cellular antioxidant, apoptotic and inflammatory markers. *Environmental Science and Pollution Research*, **26**, 32488-32504 (2019).
- Shapiro, H., Ashkenazi, M., Weizman, N., Shammurov, M., Aeed, H. and Bruck, R. Curcumin ameliorates acute thioacetamide-induced hepatotoxicity. *Journal of Gastroenterology and Hepatology*, **21** (2), 358-366 (2006).
- Moustafa, A. H. A., Ali, E. M. M., Moselhey, S. S., Tousson, E. and El-Said, K. S. Effect of coriander on thioacetamide-induced hepatotoxicity in rats. *Toxicology and Industrial Health*, **30** (7), 621-629 (2014).
- Alshawsh, M. A., Abdulla, M. A., Ismail, S. and Amin, Z. A. Hepatoprotective effects of Orthosiphon stamineus extract on thioacetamide-induced liver cirrhosis in rats. *Evidence-Based Complementary and Alternative Medicine*, **2011**, 1-6 (2011).
- Dorğru-Abbasoğlu, S., Kanbağlı, Ö., Balkan, J., Cevikbaş, U., Aykaç-Tokerl, G. and Uysall, M. The protective effect of taurine against thioacetamide hepatotoxicity of rats. *Human & Experimental Toxicology*, **20** (1), 23-27 (2001).
- Shaker, M. E., Shiha, G. E. and Ibrahim, T. M. Comparison of early treatment with low doses of nilotinib, imatinib and a clinically relevant dose of silymarin in thioacetamide-induced liver fibrosis. *European Journal of Pharmacology*, **670**, (2-3), 593-600 (2011).
- Tietz, N., Rinker, A. and Shaw, L. IFCC methods for the measurement of catalytic concentration of enzymes Part 5. IFCC method for alkaline phosphatase (orthophosphoric-monoester phosphohydrolase, alkaline optimum, EC 3.1. 3.1). *Journal of Clinical Chemistry and Clinical Biochemistry. Zeitschrift für klinische Chemie und klinische Biochemie*, **21** (11), 731-748 (1983).
- Di Giorgio, J. Nonprotein nitrogenous constituents. In *Clinical chemistry: principles and technics*, Harper and Row Hagerstown, Maryland, pp 556-557 (1974).
- Bancroft, J. D. and Gamble, M. *Theory and Practice of Histological Techniques*. Elsevier health sciences: UK, PP 73-138 (2008).
- Bozzola, J. J. and Russell, L. D. *Electron Microscopy: Principles and Techniques for Biologists*. Jones and Bartlett Learning: Boston, P 670 (1999).
- Swift, M. L. GraphPad prism, data analysis, and scientific graphing. *Journal of Chemical Information and Computer Sciences*, **37** (2), 411-412 (1997).
- Friedman, S. L. Liver fibrosis—from bench to bedside. *Journal of Hepatology*, **38**, 38-53 (2003).
- Shojaeifard, M. B., Hojjati, S., Vojdani, S. and Keshavarz, S. Protective Effect of Hydroalcoholic Extract of Clove on Thioacetamide-Induced Hepatotoxicity Animal Model: Effects Hydroalcoholic Extract of Clove Against Hepatotoxicity. *Galen Medical Journal*, **11**, e1603 (2022).
- Rekha, M., Murthy, D. J., Poornima, R. and Dattatreya, K. Evaluation of Deritis Ratio, Alkaline Phosphatase and Bilirubin in Liver Diseases. *Journal of Pharmaceutical Sciences and Research*, **3** (3), 1096 (2011).
- Su, W., Tai, Y., Tang, S.-H., Ye, Y.-T., Zhao, C., Gao, J.-H., Tuo, B.-G. and Tang, C.-W. Celecoxib



- attenuates hepatocyte apoptosis by inhibiting endoplasmic reticulum stress in thioacetamide-induced cirrhotic rats. *World Journal of Gastroenterology*, **26** (28), 4094 (2020).
23. Hori, Y., Sato, S., Yamate, J. and Kurasaki, M. Immunohistochemical study of macrophage migration inhibitory factor in rat liver fibrosis induced by thioacetamide. *European Journal of Histochemistry*, **47** (4), 317-324 (2003).
24. Hwang, S., Hong, H. N., Kim, H. S., Park, S. R., Won, Y. J., Choi, S. T., Choi, D. and Lee, S. G. Hepatogenic differentiation of mesenchymal stem cells in a rat model of thioacetamide-induced liver cirrhosis. *Cell Biology International*, **36** (3), 279-288 (2012).
25. Cardoso, S. M., Pereira, C. and Oliveira, C. R. Mitochondrial function is differentially affected upon oxidative stress. *Free Radical Biology and Medicine*, **26** (1-2), 3-13 (1999).
26. Li, N., Sioutas, C., Cho, A., Schmitz, D., Misra, C., Sempf, J., Wang, M., Oberley, T., Froines, J. and Nel, A. Ultrafine particulate pollutants induce oxidative stress and mitochondrial damage. *Environmental Health Perspectives*, **111** (4), 455-460 (2003).

## دراسة باثولوجية وتركيبية فانقة على تلف الكبد المزمن الناجم عن الثيوسيتاميد في ذكور الفئران

سهيلة عبد الحميد أحمد عبد الحميد<sup>1</sup>، إيمان عبد الوهاب أحمد إبراهيم<sup>1</sup> ولاء فكري عبد الوهاب حسن عوضين<sup>1</sup> و أحمد فوزي محمد الشايب<sup>2</sup>

<sup>1</sup> قسم الباثولوجيا - كلية الطب البيطري - جامعة المنصورة - المنصورة - مصر.

<sup>2</sup> قسم الباثولوجيا - كلية الطب البيطري - الجامعة المصرية الصينية - القاهرة - مصر.

### الملخص

يعتبر مركب الثيوسيتاميد من المركبات التي تدخل في العديد من الصناعات؛ حيث يستخدم كمعطي عام للرابطة الكبريتية في العديد من الصناعات الكيميائية مثل صناعة الجلد والورق؛ كما يعتبر من أخطر المركبات الكيميائية المسببة لتليف الكبد. يعتبر الثيوسيتاميد سم كبد من الدرجة الأولى لأن عملية التمثيل الخاصة به تحدث في الكبد وتتراكم نواتج الأكسدة الخاصة به في أنسجة الكبد مسببة أضرار مدمرة لنسيج الكبد. ولذلك كان من الضروري إجراء تجربة عملية لدراسة التغيرات الباثولوجية الناتجة عن التعرض لمركب الثيوسيتاميد على مستوى الكبد. ولذلك تهدف هذه الدراسة إلى تتبع التغيرات الباثولوجية المختلفة في نسيج الكبد بعد التعرض المزمن لمركب الثيوسيتاميد في ذكور الفئران البالغة. في هذه الدراسة تم استخدام عدد 20 فأر من ذكور الفئران وتم تقسيمها إلى مجموعتين في كل مجموعة 10 فئران. المجموعة الأولى: ضابطة لم يتم فيها التعرض للثيوسيتاميد / المجموعة الثانية: ضابطة تجريبية تم تعريضها لمركب الثيوسيتاميد فقط عن طريق الحقن الوريدي بجرعة 150 ملجم/كجم لمدة 9 أسابيع. ولقد أوضحت النتائج الحالية أن التعرض للثيوسيتاميد أحدث خلل و تغيرات بيوكيميائية وباثولوجية على مستوى عينات الدم وأنسجة الكبد بالإضافة نمو أورام سرطانية في الكبد. كما أثبتت نتائج الدراسة الحالية أن التعرض لمركب الثيوسيتاميد كان مصاحباً بحدوث فشل كبدى وتليف مزمن في نسيج الكبد بالإضافة إلى حدوث سرطان الكبد. كما تم فحص خلايا الكبد باستخدام الميكروسكوب الإلكتروني والتي أظهرت تغيرات واضحة على مستوى النواة مما يوحي بمظاهر خبث الخلايا وتدمير واضح للميتوكوندريا مع انخفاض واضح في عددها داخل الخلايا. نستنتج من هذه الدراسة أن التعرض المزمن لمركب الثيوسيتاميد تسبب في تغييرات بيوكيميائية وباثولوجية خطيرة على رأسها تليف الكبد. ولذلك فإن التعرض لهذا المركب يهدد الحياة. لذلك يجب تطبيق مستوى عالٍ من احتياطات السلامة أثناء التعرض لهذا المركب الخطير.

**الكلمات الدالة:** ثيوسيتاميد، تليف الكبد، تغيرات باثولوجية، فئران.