

## ORIGINAL ARTICLE

# RECONSTRUCTION OF EXTRA-HEPATIC BILIARY TREE IN IATROGENIC INJURY CAUSING BISMUTH I, II, AND III LESIONS

By

Yossry Gaweesh, Mohamed Mazlom, Walid ElShazly

Colorectal unit, Surgical department, Faculty of medicine, University of Alexandria, Egypt

Correspondence to: Walid ElShazly, Email: wshazly@hotmail.com

**Aim:** It has been considered that iatrogenic injuries of the common bile duct can best be repaired with biliary enteric anastomosis between a Roux loop of jejunum and the proximal extra hepatic biliary tree. This study aim to assess the feasibility of Choledochocholedochostomy in biliary reconstruction in iatrogenic biliary injury of Bisthmus I,II and III levels.

**Patients and Methods:** eight patients who had iatrogenic biliary tract injury of Bisthmus II and III levels were prospectively included. The anatomic conditions of the biliary tree were evaluated by endoscopic cholangiography or cholangio resonance. Choledochocholedochostomy was done in all patients with mucosa to mucosa tension free anastomosis, after inserting the T tube (silicone or latex) in the distal segment. Johns Hopkins criteria for evaluation of reconstruction results was used.

**Results:** eight patients were surgically reconstructed. Mean age was 38.12 years (range 23 - 65), Six were female. Treatment success (excellent or good results) was obtained in 7 cases according to Johns Hopkins criteria for evaluation of reconstruction. Mean follow up was 17.5 months (range 12 to 23 months). There was a single case of mortality with pulmonary embolism while morbidity is limited only to mild wound sepsis in 2 cases.

**Conclusion:** Choledochocholedochostomy is always feasible in Bisthmus II and III biliary injury Long term follow up is awaited to assess our promising initial results.

**Keywords:** Biliary fistula, Cholecystectomy, choledochostomy.

## INTRODUCTION

The risk of bile duct injury during open cholecystectomy ranges from 0.1-0.2 % while with laparoscopic cholecystectomy was associated with less than 0.5.<sup>(1,2)</sup> Iatrogenic bile duct lesions are serious complications during cholecystectomy and include biliary leakage and major bile duct injury.<sup>(3)</sup> Magnetic resonance cholangiogram is the most sensitive and accurate test for the diagnosis of complications of cholecystectomy although percutaneous transhepatic cholangiography has been considered preferred investigation.<sup>(4,5)</sup> Other investigations in use are ERCP, ultrasonography, and intra-operative cholangiography (IOC).<sup>(6,7)</sup>

The complex hilar lesions or total transections, are usually not amenable to endoscopic treatment and early referral for surgical intervention is prudent.<sup>(8)</sup> The correct treatment of

these injuries by surgeons experienced with this problem will ensure a successful long-term outcome of this reparative surgery in over 90% of these patients. On the other hand, attempted correction of this very serious problem by the initial operating surgeon who probably has limited or no experience with this situation has been associated with a very high failure rate (over 50% in most series) and repeated hospitalizations, operations, etc. have thus been necessary.<sup>(2,8)</sup>

The principles of surgical management include careful preoperative preparation of the patient, control of sepsis and complete cholangiography. The level of injury to the duct is determined and for this purpose, the Bismuth or Hopital Paul Brousse classification is used.<sup>(9)</sup> Although this classification is intended for established strictures, it is commonly used to describe acute bile duct injuries. After identification of the the injury type perform a

choledochoduodenostomy or jejunostomy as preferred as it is thought that simple peribiliary drainage is not preferred because of the high biliary strictures and mortality rates.<sup>(5,8)</sup>

The knowledge of the blood supply of the normal biliary system and the collateral hilar plate arterial plexus forms the anatomical foundation for successful reconstructive surgery. It was found that the bile ducts possess an arterial plexus on their surface which is supplied from below by ascending marginal vessels derived from the postero-superior pancreaticoduodenal artery. These marginal vessels end above in the right hepatic artery or its branches.<sup>(10)</sup> The right and left hepatic ductal systems are supplied by the right and left hepatic arteries and their sectoral or segmental branches. The right and left hepatic arteries communicate freely via the hilar plate arterial plexus. This collateral system allows the blood supply to the right hepatic duct to be maintained after ligation of the right hepatic artery and interruption of the common hepatic duct or excision of the confluence and also the blood supply of the distal part is maintained which make direct reconstruction is feasible.<sup>(10,11)</sup>

The idea of using the proximal and the distal biliary tree is tempting because of the use of the mechanism of the sphincter located down around the insertion of the CBD to avoid reflux cholangitis and to regulate the entry of bile into the duodenum together with pancreatic secretions to effect the best mix between digestive enzymes and food.

## PATIENTS AND METHODS

Patients who had iatrogenic biliary tract injury prospectively were included in the analysis and patients with injuries that were treated by means of endoscopy and/or radiologic approaches were not included. These patients had either common bile duct or common hepatic duct injuries only complex injuries up to Bismuth type III were included. Bile leaks from the gallbladder bed and cystic ducts were excluded as were other types of strictures not related to a surgical injury.

Patients referred from outside hospitals were fully evaluated with ultrasound and liver function tests. Surgical reconstruction was generally performed as an elective procedure as soon as possible. The anatomic conditions of the biliary tree were evaluated by endoscopic cholangiography or cholangio resonance (Fig. 1).

The proximal hepatic duct was identified and dissected caudocephally, without mobilizing the lateral aspects of the duct in order to preserve its vasculature, dissection was done only in the anterior aspect. The distal part of the CBD is dissected from the pancreas without endangering the blood supply and helping with proper Khorization of the duodenum to compensate for at least 3 cm length reaching

the proximal segment without tension and enabling the surgeon to do a mucosa to mucosa tension free anastomosis (Fig. 2).

The anastomosis is done using only four sutures of four zero vicryl to be tighten after inserting the T tube (silicone or latex ) in the distal part and directing the stent into the right duct in most of the times (Fig. 3). The T tube should be inserted from a separate incision in the distal part of the CBD with only part of the horizontal limb stenting the anastomosis (Fig. 4). A T tube cholangiography should be made to demonstrate the adequacy of the healing before extracting the T tube stenting the anastomosis usually after three months (Figs. 5,6). Low molecular weight heparin prophylaxis is mandatory because of the manipulation of the area of the IVC to avoid massive pulmonary embolism.

The length of follow up was calculated from the date of definitive surgical repair. Johns Hopkins criteria for evaluation of reconstruction (excellent: no symptoms attributable to the biliary tract injury or reconstruction; **good**: mild symptoms not requiring invasive investigation or treatment; **treatment failure**: ongoing symptoms or stricture recurrence that require invasive diagnostic or therapeutic procedures, either radiological or surgical.<sup>(12)</sup>

## RESULTS

A total of 8 patients were surgically reconstructed at our institution after bile duct injury during a 2 year period (2003 - 2005). Mean age was 38.12 years (range 23 - 65), Six were female. Seven patients were referred from other institutions and one patient recognized intra-operative at our institution. In six patients the injury resulted from an open procedure and in 2 from laparoscopic surgery. Five patients presented with external biliary fistula, one of them has associated peritonitis and the other 4 have associated mild sepsis, two patients presented with obstructive jaundice and attacks of ascending cholangitis, and one patient recognized intra-operative. The mean time of presentation is 10.5 days (range immediate - 21 days).

In the preoperative period, 2 patients had serum bilirubin level between 6 and 9 mg/dL and serum alkaline phosphatase between 150 and 300 UI/L, while the other 6 patients have serum bilirubin level below 1.2 mg/dL and serum alkaline phosphatase under 150 UI/L. Four patients had albumin levels above 3 mg/dL, the other four patients had albumin level between 2-2.9 mg/dL. Ultrasonography revealed collection in the peritoneal cavity in 4 patients (50%). Ultrasonography and CT showed biloma in two patients (25%).

Magnetic resonance cholangiopancreatography (MRCP) was done in 6 patients and endoscopic retrograde cholangiopancreatography (ERCP) was done in 2 patients showed the exact site of common bile duct injury.

According to Bismuth staging one of our patient was Stage I, five patients were Stage II, and two patients were stage III.

The mean timing of admission for surgical correction after presentation was 31.5 days (range immediate - 63 days), there was no operative mortality recorded. Mean hospital stay was 18.5 days (range 12 - 25). One patient developed pulmonary embolism with decerebration and died after two months in intensive care unit. Morbidity include only wound sepsis in two patients which were managed conservatively.

One week postoperatively serum bilirubin level return to below 1.2 mg/dL and serum alkaline phosphatase under 150 UI/L in all patients, While serum albumin level require from 2 to 3 months to become above 3 mg/dL in all patients except the single case of mortality. T-Tube cholangiogram was done for 7 patients ten days after surgery and clear out lining of biliary tree was seen. In all these cases, T-tube was removed after 3 months.

Excluding the one death, Excellent outcome which mean that they never experiences jaundice or cholangitis was obtained in 7 patients according to Johns Hopkins criteria for evaluation of reconstruction 9. Mean follow up was 17.5 months (range 12 to 23 months).

## DISCUSSION

The best treatment of common bile duct injuries is the prevention by careful surgical technique. If they occur, the best moment to repair them is during surgery.<sup>(3)</sup> In this series, only one patient (12.5%) were diagnosed immediately and underwent intraoperative repair. This is significantly less than that reported in literature of 29.4%<sup>(8)</sup> and this could be explained by that most of the cases were performed by low experts surgeons.

In our study 25% of common bile duct injuries occurred in patients who had undergone laparoscopic cholecystectomy while rest of injuries were seen in open cholecystectomy cases. The reason for this was that the total number of open cholecystectomy procedures itself was much larger. Nevertheless, iatrogenic injury of bile ducts is still more likely to result from laparoscopic cholecystectomy than open cholecystectomy.<sup>(3)</sup>

It has long been considered that iatrogenic injuries can best be repaired with biliary enteric anastomosis between a Roux loop of jejunum and the proximally dissected segment of the extra hepatic biliary tree.<sup>(5,8)</sup> The traditional teaching includes a mucosa to mucosa tension free anastomosis with or without stenting between the biliary segment and the defunctionalized jejunal loop, to avoid ascending reflux cholangitis.<sup>(8)</sup> Operative repair of

iatrogenic bile duct strictures has a long-term recurrent stricture rate of 10-30% after biliary anastomosis and 50% of these occur within one year.<sup>(13)</sup>

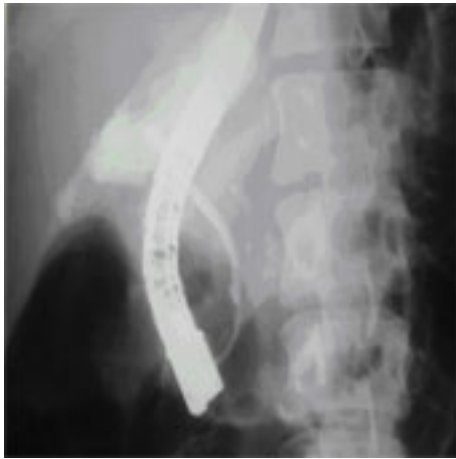It has long been considered that end-to-end anastomosis of the transected bile duct experienced a high chance of failure due to ischemia of the cut ends of the bile duct<sup>(13)</sup> The knowledge of the blood supply of the normal biliary system and the collateral hilar plate arterial plexus make direct reconstruction is feasible.<sup>(10,11)</sup> The high failure rates reported with Choledochocholedochostomy was suggested to be due to technical factors Raute et al.<sup>(14)</sup> reported that in nearly 50% of their patients, the recurrence of the stricture was due to technical faults.

The idea of using the proximal and the distal biliary tree is tempting because of the use of the mechanism of the sphincter located down around the insertion of the CBD to avoid reflux cholangitis and to regulate the entry of bile into the duodenum together with pancreatic secretions to effect the best mix between digestive enzymes and food. It has found that dissection of proximal and distal common bile duct together with proper Khorization of the duodenum can compensate for at least 3 cm length reaching the proximal segment without tension and enabling the surgeon to do a mucosa to mucosa tension free anastomosis usually with a stent inserted in the distal segment and bridging the anastomotic line with part of the horizontal limb of the T tube inserted.<sup>(10,11)</sup>

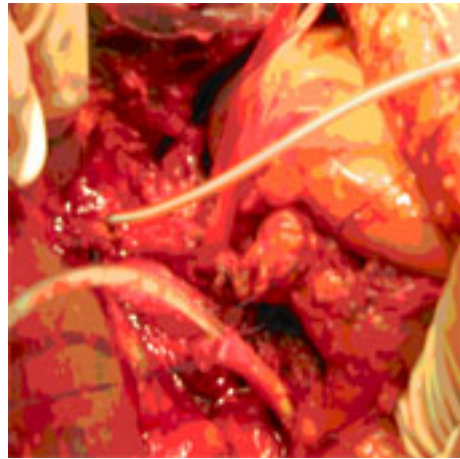
Choledochocholedochostomy is preferred to choledochojejunostomy as construction of the choledochojejunostomy requires longer operating time, removes some length of intestine, and may lead to a longer period of postoperative ileus. In addition, it adds two additional enteric anastomoses and bleeding from the jejunojunction site is frequent.

Mortality depends directly on the delay in the diagnosis and the treatment. Patients with lesions that are promptly discovered and appropriately treated within hours of injury have a mortality rate of less than 10%, while patients with delayed treatment may have a mortality rate nearing 40%.<sup>(8)</sup> This agree with our results as the only case of mortality was that of delayed discovery after 21 day due to delayed referral to our institution this patient suffer pulmonary embolism and died in spite of successful surgical repair.

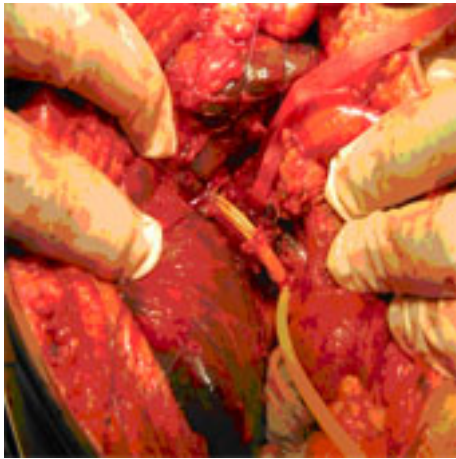It is concluded that Choledochocholedochostomy is almost always feasible in Bismuth I, II, and III with no tension on suture line if adequate mobilization of the proximal and distal segment was done with adequate Khorization of the duodenum. Long-term follow up is awaited to assess our promising initial results in this study.



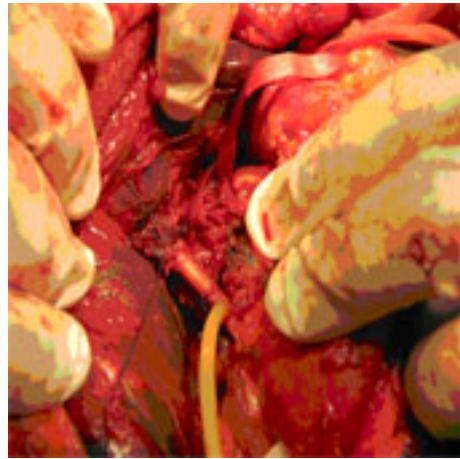
*Fig 1. ERCP of biliary tract with leak of dye proximally without visualization of proximal bile ducts.*



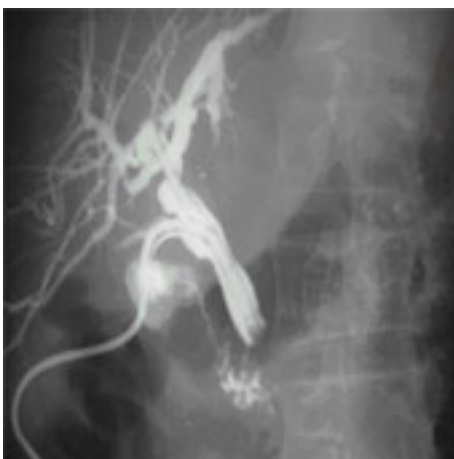*Fig 2. The proximal and distal cut ends of CBD after dissection with a catheter in each side for demonstration.*



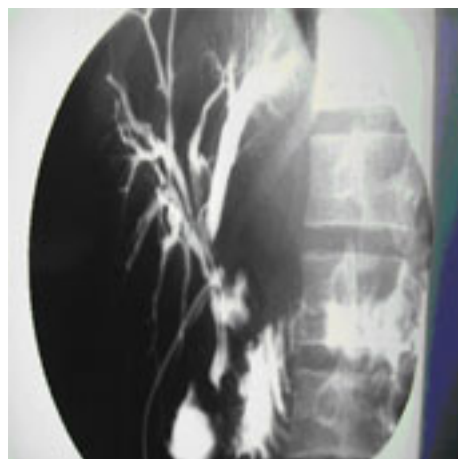
*Fig 3. The anastomosis done using four sutures of four zero vicryl with T tube in the distal part.*



*Fig 4. The T tube is inserted from a separate incision in the distal part of the CBD.*



*Fig 5. T tube cholangiogram after Reconstruction of biliary tree after 3 months.*



*Fig 6. T tube cholangiogram after reconstruction of biliary tree in another patient.*

## REFERENCES

1. Idar S, Sabo E, Nash E, Abrahamson J, Matter I. laparoscopic versus open cholecystectomy in acute cholecystitis. *Surg Laparosc Endosc.* 1997;7:407-14.
2. Pleas HCC, Garden OJ. Bile duct injury: prevention and management. Johnson CD, Taylor I. Ed. *Recent Advances in Surgery.* Churchill Livingstone. 1998;21:1-16.
3. Branum G, Schmitt C, Baillie J, Suhocki P, Baker M, Davidoff A. Management of major biliary complications after laparoscopic cholecystectomy. *Ann of Surg.* 1993;217:532-41.
4. Ahrendt SA, Pitt HA. Biliary tract. In: CM Townsend. *Sabiston Textbook of Surgery.* WB Saunders Company, Philadelphia, Pennsylvania. 2001:1076-111.
5. Ahrendt SA, Pitt Ha. Surgical therapy of iatrogenic lesions of biliary tract. *World J Surg.* 2001;25:1360-5.
6. Chaudhary A, Negi SS, Puri SK, Narang P. Comparison of magnetic resonance cholangiography and percutaneous transhepatic cholangiography in the evaluation of bile duct strictures after cholecystectomy. *Br J Surg.* 2002;89:433-6.
7. Polat F R, Abci I, Coskun I, Uranues S. The importance of intraoperative Cholecystectomy. *JSLS.* 2000;4:103-7.
8. Sawaya DE Jr, Johnson LW, Sittig K, McDonald JC, Zibari GB. Iatrogenic and non iatrogenic extrahepatic biliary tract injuries: a multi-institutional review. *Am Surg.* 2001;67:473-7.
9. Bismuth H, Majno PE. Biliary strictures: classification based on the principles of surgical treatment. *World J Surg.* 2001;25:1241-4.
10. Chen WJ, Ying DJ, Liu ZJ, He ZP. Analysis of the arterial supply of the extrahepatic bile ducts and its clinical significance. *Clin Anat.* 1999;12:245-9.
11. Vellar ID. The blood supply of the biliary ductal system and its relevance to vasculobiliary injuries following cholecystectomy. *Aust N Z J Surg.* 1999;69:816-20.
12. Lillemoe KD, Melton GB, Cameron JL, Pitt HA, Campbell KA, Talamini MA, et al. Postoperative bile duct strictures: management and outcome in the 1990's. *Ann Surg.* 2000;232:430-41.
13. Chaudhary A, Chandra A, Negi SS, Sachdev A. Reoperative Surgery for Postcholecystectomy Bile Duct Injuries. *Dig Surg.* 2002;19:22-7.
14. Raute M, Podlech P, Jaschke W, Manegold BC, Trede M: Management of bile duct injuries and strictures following cholecystectomy. *World J Surg.* 1993;17:553-62.