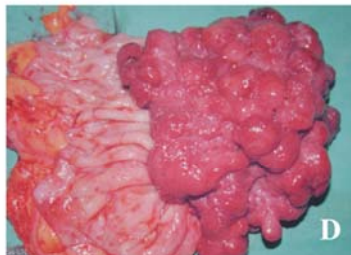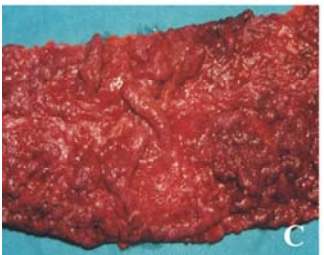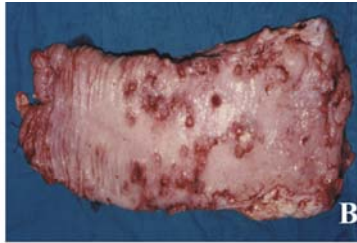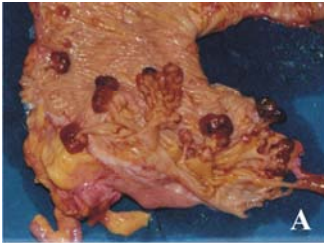


SURGICAL PHOTO QUIZ

By
Presented by the Egyptian Group for Colorectal Surgeons
Ahmed A Abou-Zeid
Professor of Surgery Ain Shams University



Match

- | | |
|------------------------|---|
| 1. Adenomatous polyp | A |
| 2. Villous polyp | B |
| 3. Pseudopolyp | C |
| 4. Hamartomatous polyp | D |

Send your answer to ejs@ess-eg.org

The correct answer and a short comment on the condition will be presented in the next issue of the journal.

The correct answer for previous Photo Quiz (Vol 24, No 3, July, 2005)

The correct answer is hidradenitis suppurativa.

This is a chronic suppurative inflammation of the apocrine sweat glands that are situated in the axilla, groins, suprapubic and perianal regions. Unlike perianal fistula, hidradenitis suppurativa is characterized clinically by the presence of multiple draining sinuses and induration and scarring of the skin and the subcutaneous tissues in between these sinuses. This is very evident in the photograph. Perianal Crohn's is usually less extensive. Condyloma accuminata is a warty lesion that is completely different than the shown photograph and Paget's disease is erythematous lesion that looks like eczema.

