

## ORIGINAL ARTICLE

# ENDOVASCULAR TREATMENT OF CENTRAL VEIN STENOSIS OR OCCLUSION IN HEMODIALYSIS PATIENTS

By

Ahmed Abou-Elnaga, Abdelmonem Mourad,\* Iman Esmat,\*\* Hesham Elsheikh\*\*\*

Department of Surgery, \*\*Department of Cardiology, Ain Shams University, \*Department of Radio diagnosis, Assiut University, \*\*\*Departement of Radiodiagnosis Benha Faculty Of Medicine

**Aim:** A reliable vascular access, preferably an arteriovenous fistula (AVF) is the lifeline of hemodialysis patients. Fistula function may be impaired by subclavian stenosis or occlusion, mainly due to previous subclavian cannulation for temporary vascular access. Currently, there has been a significant improvement in the life span of haemodialysis patients, thus it is very important to maintain vascular access as long as we can.

**Methods:** Between January 2004 to May 2005, 20 balloon angioplasty procedures with or without stent were performed for 13 patients who have chronic renal failure and venous hypertension due to central venous stenosis or occlusion.

**Results:** All procedures were technically successful with no major complications. Seven patients needed reintervention within the 1st year of follow-up. Primary patency rate were 84.6%, 69.2% and 46.2% at 3, 6 and 12 months respectively. All patients with repeated dilatation had no major complications.

**Conclusion:** Endovascular treatment of central vein stenosis or occlusion is an effective alternative to surgery. Regular follow-up and repeated dilatation are indicated to prolong the life of the vascular access.

**Keywords:** Venous, hypertension, angioplasty and renal failure.

## INTRODUCTION

Venous hypertension is a significant problem for patients on regular hemodialysis. This condition can result in impairment of arteriovenous access function, disabling upper extremity, associated with edema and bluish discoloration and pigmentation of the skin, and in advanced cases, ulceration of the finger tips and neurolagias.<sup>(1)</sup> Venous hypertension usually results from central vein stenosis, occlusion, or valvular incompetence in the arteriovenous access outflow vein. High index of suspicious is required to identify patients at risk for venous hypertension. A history of ipsilateral central venous catheter placement and physical signs such as visible distended shoulder venous collaterals, and upper extremity edema were suggestive.<sup>(2)</sup> Diagnosis is confirmed with duplex ultrasound or contrast venography. The primary goal of diagnosis and therapy of venous hypertension is symptomatic relief while maintaining the functionality of

the access.<sup>(3)</sup> Treatment include percutaneous catheter based and open surgical techniques.<sup>(4-5)</sup> The angioplastic management of this problem will be discussed.

## PATIENTS AND METHODS

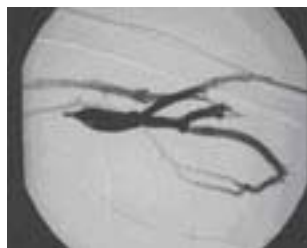This study was performed on chronic renal failure patients during the period form January 2004 to May 2005. They were presented with clinical picture of upper limb venous hypertension in the form of upper limb edema, dilated veins on the shoulder, chest wall and mal-functioning arterio-venous fistula (AVF).

A complete history was taken from all patients, with special emphasis on previous subclavian catheter insertion on the same side. They were also subjected to thorough clinical examination with special attention to signs of venous hypertension.

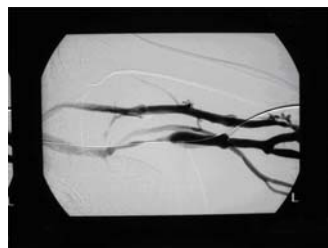
Doppler ultrasound examination was performed using, Elegra Color Doppler Ultrasound Machine (Siemens, Germany) using high frequencies (7.5 Mhz) probe to detect the presence of stenosis or occlusion. All patients who had positive Doppler ultrasound results underwent venography then balloon angioplasty with or without stent according to the situation.

The indications of stent placement were sub-optimal angioplasty results defined as more than 50 % narrowing with persistent filling of the venous collaterals or recurrent stenosis within two months after angioplasty.<sup>(6)</sup>

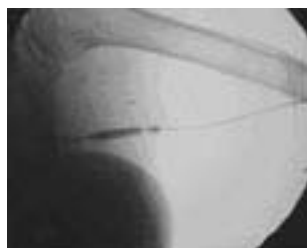**Technique:** In the angiosuit via the affected limb, venography was performed to all patients under local anesthesia (Figs. 1a, 2a), to confirm the diagnosis of venous stenosis or occlusion using angiography machine polystar with digital subtraction facility (Siemens, Germany). After insertion of 7F vascular sheath at the venous access site, a hydrophilic guide wire (Terumo, Japan) was passed through the stenotic or occluded segment of the vein. If the guide wire cannot be passed easily at the site of the occlusion we used a guiding catheter to support the guide wire to pass through the obstructed segment (Fig. 1b).



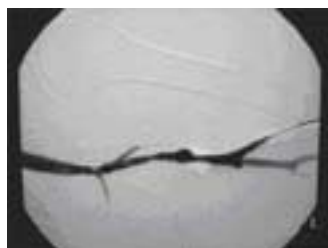
**Fig 1a. Complete occlusion of the vein with multiple collaterals.**



**Fig 1b. Passage of the guide wire with the help of guiding catheter.**



**Fig 1c. Inflation of balloon with appearance of tight waist.**

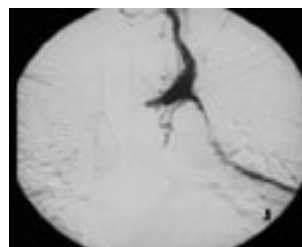


**Fig 1d. Opening of the complete occlusion with disappearance of collateral.**

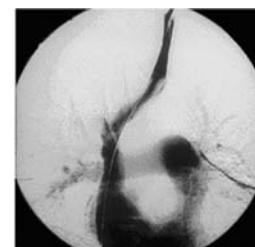
Angioplasty was done using balloon dilatation catheter (Boston scientific, Ireland) (Fig. 1c). The diameter of the balloon was determined according to the diameter of the adjacent normal vein. If a stent was required, its size was

determined during this procedure based on the balloon diameter and the diameter of the adjacent normal vein, which was equal to or 1 mm. larger than the diameter of the balloon and its length determined based on the extent and location of the lesion. The stent used was either balloon expandable stent or self expandable one (Fig. 2b) (Boston Scientific, Ireland). After insertion of some self-expandable stent it had to be redilated by balloon angioplasty in order to achieve full expansion.

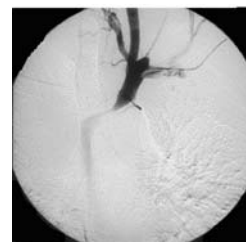
The criterion for technically successful dilatation with or without stent placement was less than 30% residual stenosis with no filling of the venous collaterals<sup>(6)</sup> (Figs. 1d, 2c).



**Fig 2a. Venography show central vein occlusion.**



**Fig 2b. passage of guide wire**



**Fig 2c. Stent placement.**

Follow-up of the patients with dilated segment was done using Doppler ultrasound at 3 months interval up to 12 months. This Doppler ultrasound was also performed when a patient had a problem during hemodialysis or arms swelling. When Doppler ultrasound results were suggestive of restenosis venography were done and redilatation if indicated.

We evaluated both primary patency rate and secondary patency rate. Primary Patency rate defined as the interval between the day of dilatation and the day of 1st redilatation while secondary patency rate defined as the interval between redilatation and permanent vein occlusion or the end of the period of follow-up.<sup>(6)</sup>

## RESULTS

Thirteen patients (8 males 61% and 5 females 39%) were included in this study. Their ages ranged between 38-80 years (mean age was 55 years). There were 5 patients had central vein stenosis (38%) and one patient had central vein occlusion (8%). All these patients had positive history of subclavian vein catheter insertion at the same side. There were 4 patients had brachiocephalic stenosis (30%) and one had brachiocephalic occlusion (8%). Two patients had anastomotic stenosis between the graft and the vein (16%). All the procedures for dilatation or dilatation with stenting were technically successful (Procedural success rate 100%). There were no major complications such as venous rupture or thrombosis.

Follow-up for the patients was performed at 3, 6 and 12 months after the 1<sup>st</sup> intervention, while patients underwent 2<sup>nd</sup> intervention the follow up was performed at 3 and 6 months. Only one patient (8%) underwent reintervention after two weeks. due to improper function of the AV graft so redilatation and stent was applied. The primary patency rate at 3, 6 and 12 months was 84.6%, 69.2%, and 46.2% respectively. During the follow-up period, 7 patients (53.8%) underwent repeated angioplasty, 3 of them (23%) without stent and the remaining 4 patients (30%) with stent, 2 were balloon mounted and the others were self expandable. The secondary patency rate after reintervention was 90% and 75% respectively at 3 and 6 month. All patients who had repeated dilatation passed without complications.

## DISCUSSION

Venous hypertension due to subclavian vein stenosis or occlusion in hemodialysis patients with a history of an ipsilateral subclavian vein cannulation for temporary haemodialysis is a well-known complication. Therefore subclavian temporary vascular access should be abandoned.<sup>(7-9)</sup> Subclavian or brachio-cephalic vein stenosis may cause reduced vascular access flow, increased venous pressure, and subsequent vascular access thrombosis. These patients usually present with ipsilateral arm swelling and insufficient hemodialysis.<sup>(10,11)</sup>

Surgical management of upper extremity central venous obstruction is effective, but it is usually difficult to perform as the approach of the subclavian vein is technically demanding because it lies deep in the thorax, as well as the bad general condition of the patients.<sup>(12,13)</sup>

Percutaneous trans-luminal angioplasty (PTA) with or without stent is used successfully with good short-term results.<sup>(14,15)</sup> Upper extremity central venous stenosis or occlusion can be treated with balloon angioplasty alone. However, because of the high frequency of elastic recoil of

the central veins, the rate of restenosis after PTA is higher than that for peripheral lesions. Thus, it is very difficult to achieve long-term patency after PTA.<sup>(16,17)</sup> Patients with extensive stenosis in which PTA failed and lesions that recur after multiple PTA procedures are usually treated with stent placement. Dilatation of the subclavian and brachio-cephalic veins stenosis or occlusion with or without stenting extended the duration of hemodialysis access. However, after one to two years restenosis was seen frequently.<sup>(18-20)</sup>

In this study thirteen hemodialysis patients who had 20 PTA with or without stent were followed up at 3, 6 and 12 months. Their primary patency rate was 84.6%, 69.2%, and 46.2% respectively. Similar results had been reported by Hagge et al,<sup>(18)</sup> their series of patients showed primary patency rates of 92%, 84%, and 56 % respectively at the same interval of time. However, Vessaly et al,<sup>(19)</sup> reported that the primary patency rate for their patients was 67%, 42%, and 25 % at 3, 6 and 12 months respectively. This difference may be due to they followed up their patients by venography while we followed our patient using Doppler ultrasound (as it is a less invasive technique). In many reports, the one year follow up for primary patency rate following PTA ranged from 33-97%.<sup>(19- 21)</sup>

Restenosis of the vein usually occurs due to intimal hyperplasia at or near the stent site, as well as due to stenosis at a remote location. Restenosis can usually be treated with angioplasty with or without stent placement. In this study, after PTA with or without stent multiple re-interventions were often needed to prolong patency (54%). These results were in consistent with Hagge et al,<sup>(18)</sup> and Vessaly et al.<sup>(19)</sup>

Endovascular treatment of central vein stenosis or occlusion is a simple and safe technique, which can be performed on a day case basis. The procedure effectively improves the symptoms of venous hypertension and preserves the function of AVF. It also reduces morbidity and allows early return to normal activity including dialysis. Follow-up after PTA is essential for possibility of re-dilatation. Doppler ultrasound is a good screening non invasive test for diagnosis of the central vein stenosis and follow-up after dilatation.

## REFERENCES

1. Neville RF, Abullarrage CJ, White PW, Sidawy AN. Venous hypertension associated with arteriovenous hemodialysis access *Semin Vasc Surg.* 2004;17:50-6.
2. Itkin M, Kraus MJ, Trerotola SO. Extrinsic compression of the left innominate vein in hemodialysis patients. *J Vasc Interv Radiol.* 2004;15:51-6.

3. Lumsden AB, MacDonald MJ, Isiklar H, Martin LG, Kikeri D, Narker LA, et al. Central venous stenosis in the hemodialysis patients: Incidence and efficacy of endovascular treatment. *Cardiovascular Surg.* 1997;5:504-9.
4. Duncan JM, Baldwin RT, Caralis JP, Cooley OA. Subclavian vein to right atrial bypass for symptomatic venous hypertension. *Ann Thoracic Surg.* 1991;52:1342-3.
5. Polo JR, Sanabia J, Garcia Sabridol JL, Luno J, Menarguez C, Echenagusia A. Brachial-jugular polytertrafluoroethylene fistulas for hemodialysis. *Am J Kidney Dis.* 1990;16: 465-8.
6. Cuneyt A, Fatih B, Mahmut CY, Gokhan M, Mehmet H. Endovascular stent placement in the treatment of upper extremity central venous obstruction in hemodialysis patients. *European Journal of Radiol.* 2004;49:81-5.
7. Davis D, Petersen J, Feldman R, Cho C, Stevick CA. Subclavian venous stenosis: A complication of subclavian dialysis. *JAMA.* 1984;252:3404-6.
8. Konner K. Subclavian hemodialysis access is it still justified in 1995. *Nephrol Dial Transplant.* 1995;10:1988-90.
9. Schillinger F, Schilliner D, Montagnac R, Milcent T. Postcatheterization vein stenosis in hemodialysis: Comparing angiographic study of 50 subclavian and 50 internal jugular catheters. *Nephrol Dial Transplant.* 1991;6:722-4.
10. Glanz S, Gordon D, Lipkowitz G, Butt K, Hong J, Sclafani S. Axillary and subclavian vein stenosis: Percutaneous angioplasty. *Radiol.* 1988;168:371-3.
11. McNally PG, Brown CB, Moorhead PJ, Raferty AT. Unmasking subclavian vein obstruction following creation of arteriovenous fistulae for hemodialysis: A problem following subclavian line dialysis? *Nephrol Dial Transplant.* 1987;1:258-60.
12. Windus DW. Permanent vascular access, a nephrologist's view. *Am J Kidney Dis.* 1993;21:457-61.
13. Currier CB, Widder S, Ali A, Kuusisto E, Sidawy A. Surgical management of subclavian and axillary vein thrombosis in patients with a functioning arteriovenous fistula. *Surg.* 1986;100:25-28.
14. Bourquelot P, Stolbo J. Surgery of vascular access for hemodialysis and central venous stenosis. *Nephrol.* 2001;22:491-4.
15. Vorwerk D, Gunther RW, Mann H. Venous stenosis or occlusion in hemodialysis shunts: Follow up results of stent placement in 65 patients. *Radiol.* 1995;195:140-3.
16. Beathard G. Percutaneous transvenous angioplasty in the treatment of vascular access stenosis. *Kidney Int.* 1992;42:1390-7.
17. Kovalik EC, Newman GE, Suhocki P, Knelson M, Schwab SJ. Correction of central venous stenosis: Use of angioplasty and vascular Wallstents. *Kidney Int.* 1994;45:1177-81.
18. Haage P, Vorwerk D, Piroth W, Schuermann K, Guenther RW. Treatment of hemodialysis-related central venous stenosis or occlusion: Results of primary Wallstent placement and follow-up in 50 patients. *Radiol.* 1999;212:175-180.
19. Vessely TM, Hovsepian DM, Pilgram TK, Coyne DW, Shenoy S. Upper extremity central venous obstruction in hemodialysis patients: Treatment with Wallstents. *Radiol.* 1997;204:343-8.
20. Kalman PG, Lindsay TF, Clarke K, Sniderman KW, Vanderburgh L. Management of upper extremity central venous obstruction using interventional radiol. *Ann Vasc Surg.* 1998;12:202-6.
21. Gray RJ, Horton KM, Dolmatch BL. Use of Wallstents for hemodialysis access-related venous stenosis and occlusions untreatable with balloon angioplasty. *Radiol.* 1995;195:479-484.