

## SURGICAL TECHNIQUE

### HAEMOSTATIC TECHNIQUE FOR SUPRAPUBIC PROSTATECTOMY

By

Soliman M. Soliman MD. Cairo, FRCS

Nation Prize Holder, Professor of Surgery, Military Medical Academy, Cairo, Egypt

**Aim:** It is a haemostatic technique aiming at insertion of stitches in a special fashion to entangle the prostatic vessels at their anatomical sites before enucleation. The ureters are 100% safeguarded with the aid of Mannitol spirting diuresis test occlusion.

**Materials and Methods:** Eighteen patients with benign prostatic hypertrophy B.P.H. have undergone the haemostatic technique Fig. 1 during the period 1999-2003 with an age range (58 - 81). The stitches are put in two circular insertions at 2 vertical levels 1 cm distal to the ureteric orifices at 5 and 7 O'clock positions; the sites of prostatic vessels (1, 2). The stitches are only tightened when the spirting Mannitol diuresis is maintained. This provides 100% protection against ureteral obstruction.

**Results:** There is a remarkable reduction of intra and post-operative bleeding. This gives a unique chance for dissection under clear vision. The urinary sphincter is preserved and the bladder outlet is better cared of. None of the patients required blood transfusion intra-operatively.

**Conclusions:** The haemostatic technique before enucleation has provided a Suprapubic Prostatectomy without hemorrhage and without entrapment of the ureters.

**Keywords:** Haemostatic stitches, Mannitol spirting diuresis, Prostatectomy.

## INTRODUCTION

There is a pressing need for an effective procedure to avoid haemorrhage during suprapubic prostatectomy without possible ureteric entrapment.

The advent of the haemostatic technique has tided over the common complications of the standard procedure.<sup>(3)</sup>

Special indications for suprapubic prostatectomy include bladder diverticula, tumour, stone and estimated weight of prostatic gland over 70 gms.

The design of the operation relies on the knowledge of the anatomy of the arteries and veins.<sup>(2)</sup> The concept is to occlude the prostatic vessels, safely, at their anatomical sites before enucleation. The prostatovesicular artery, the major arterial supply to the prostate and seminal vesicles is a branch of the inferior vesical artery. It courses medially to the bladder base along the posterolateral aspect of the vesico-prostatic junction at 5 and 7 O'clock positions. The

prostatic veins on the lateral and anterior aspect of the prostatic gland merge with the veins of the vesical plexus and the deep dorsal vein of the penis forming the plexus of Santorini within the pubo-prostatic space.

A simple technique for occluding the prostatic vessels at their anatomical sites before enucleation has been devised.

## PATIENTS AND METHODS

The eighteen patients with B.P.H. have undergone the haemostatic technique during the period 1999-2002 with a mean age of  $69.61 \pm 7.2$  (s.e.m. 1.7) years (range 58-81).

The operation is performed almost exclusively for the treatment of symptomatic bladder outlet obstruction due to BPH.

The primary manifestation is frequency and in advanced cases urinary retention or overflow incontinence. The fundamental diagnostic evaluations are transrectal ultrasonography, urinary flow rate, intravenous urography, repeated P.S.A. (prostatic specific antigen)<sup>(4)</sup> and transrectal ultrasound guided needle-core biopsy in some cases. Operative candidates are routinely referred to a physician for adequate preoperative evaluation and preparation. Every measure is taken to combat bleeding tendency by a haematologist. Prophylactic antibiotics are given till urine culture becomes sterile.

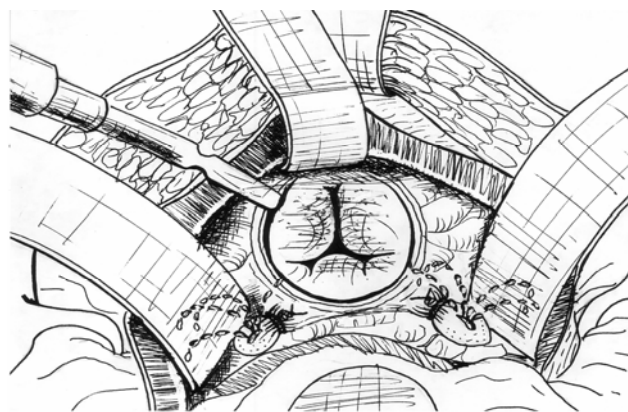
**Operative Technique:** The operation is generally performed with a spinal, epidural or general anaesthesia.<sup>(5)</sup> The patient is placed, in the supine position with a slight Trendelenburg tilt.

A three way 24 F Foley catheter with a 30-ml balloon is introduced and connected to a uribag which is clamped. The bladder is filled with 250 ml of sterile saline from 4 litres washing bag. The lower abdomen, external genitalia and upper thighs are prepped and draped so that the penis is accessible. Suitable illumination with adjustable sterile handle is arranged. Light source with fiberoptic illumination may be of help. Two infusion bottles are set up one with Mannitol 20% and the other with Ringers lactate.

The surgeon stands on the patient's left side. Transverse (Pfannenstiel) incision 4 cm above the symphysis pubis is performed.

Self retaining retractor is inserted (Fig. 1) The anterosuperior aspect of the bladder and the prevesical space are exposed by sweeping the peritoneum by blunt dissection. Stay sutures are applied in the midline 2 and 4 cm above the base of the prostate. Transverse cystostomy is made in between by electrocautery. The fluid within the bladder is aspirated and bladder retractor is inserted. Long thread of silk is attached to the tip of the Foley catheter for its reposition after enucleation. The catheter is then withdrawn by the assistant after deflation of the balloon.

The bladder is carefully examined for associated pathology. The ureteric orifices are clearly scrutinized through the fountain like flow of urine. The haemostatic stitches vicry (2/0 on 31 mm round needle are now inserted at sites of 5 and 7 O'clock positions<sup>(1,2)</sup> one cm distal to the ureteric orifices in a special fashion) (Fig. 1).



**Fig. 1** The haemostatic stitches are put, before enucleation, at 5 and 7 o'clock positions 1 cm distal to the ureteric orifices. The haemostatic stitches are only tightened when the Mannitol spirting diuresis is maintained. This provides haemostasis and 100% protection against ureteric entrapment

The needle is held near its proximal end. It goes in two vertical circles. The first is a pull up bite and the second is the deep bite distal to the ureteric orifice. Test stay tie is made and watch the fountain like flow of urine. If it persists the tie is completed making sure that the ureteric orifice is not entrapped.

In the last 10 cases of the series additional deep haemostatic stitches are inserted through the mucosa for 2 cm near the anterolateral aspect of the prostatic prominence. This is aimed to entangle some of the prostatic veins at their anatomical sites to control venous bleeding after enucleation.

Long cutting diathermy knife is used for circumferential cutting of the prostatic capsule over the most prominent bulge till the whitish prostatic adenoma shows up. The bladder retractors are removed. Enucleation is then commenced by introducing the index finger into the prostatic urethra and thrust anteriorly to crack the anterior commissure (isthmus) between the prostatic lobes. A plane of cleavage between the adenoma and the surgical capsule is developed laterally, posteriorly and inferiorly with blunt dissection. The bladder retractor is now repositioned. The gland is now grasped with Babcock's forceps or stay stitch, and dissection is completed under vision avoiding injury to the external urinary sphincter.<sup>(6)</sup> Urethral mucosa and the fibrous attachment are then divided with a scissors. The prostatic bed is now inspected. Residual bleeding is dealt with cautery and additional stitches.

The bleeding is usually minimal simple ooze. Wedge of the tissue overhanging the prostatic cavity is excised in the middle line posteriorly to reduce the risk of bladder neck contracture.

The urethral catheter is now pulled up and inflated with 30 ml and positioned in the bladder not in the prostatic fossa. The cystostomy is closed in 2 layers with vicryl 3/0 and the bladder is distended with saline. Any leak is reinforced with interrupted stitches. Prevesical corrugated drain is put through a separate stab. Continuous bladder wash with sterile saline is provided by the 3-way catheter. It is kept until the uribag content is grossly clear of blood. The catheter is generally removed on the 6th or 7th day. The prevesical drain is usually removed the following day.

## RESULT

Of the 18 patients operated upon for suprapubic prostatectomy with the haemostatic technique, 12 patients had clear urine from the first postoperative day. The anterolateral haemostatic stitches have remarkably reduced venous bleeding after enucleation in the last 10 cases of the series. Five patients had moderately coloured urine that cleared within 2 days. Dark red urine occurred with one patient. It was proved that the balloon had migrated to the prostatic cavity. New Foley catheter was inserted keeping the balloon in the vesical cavity. One unit of blood was given. Urine cleared within 2 days. Not a single case of ureteral obstruction was reported.

All patients were forewarned of some post-operative voiding urgency that lasted for a few days.

## DISCUSSION

While personal experience plays an important role; the preferred approach for prostatectomy will be the one that gives the easiest exposure and carries the least operative risks. The haemostatic technique before enucleation has provided a prostatectomy without haemorrhage. The complication of ureteric entrapment<sup>(3)</sup> has been completely eliminated through the guidance of the spirting Mannitol diuresis test vascular occlusion. Reduced bleeding during operation gives a unique chance for dissection under clear vision. The urinary sphincter is preserved and the bladder outlet is better cared of. None of the patients required blood transfusion intra-operatively. It is presumed that the migration of the balloon to the prostatic cavity prevented the contraction of the prostatic capsule leading to a venous ooze.<sup>(3)</sup>

The operation of placement of haemostatic plication sutures for uncontrolled bleeding from the depths of the prostatic fossa<sup>(7)</sup> is very difficult to implement and is accompanied meanwhile, with excessive blood loss.

Suprapubic prostatectomy entails special expertise and awareness of its potentially avoidable complications: notably brisk haemorrhage and ureteric entrapment. This has been quite feasible through the haemostatic stitches

before enucleation with the aid of Mannitol spirting diuresis.

The number of cases is small. However, if extensively performed this technique is both simple and practically sound. It is worthy of becoming popular in common surgical practice. There is a high cure rate, lack of complications and overall saving of the hospital time.

*Acknowledgements:* I acknowledge the assistance of professor Fatma Abou-Hashima of Cairo University on the matters relating to patients' statistics.

## REFERENCES

1. Lich R Jr, Howerton I.W, Anatomy and Surgical approach to the urogenital tract in the male. In: Harrison JH, Gittes RF, Perlmutter AD, et al, eds. Campbell's urology, vol 1, ed 4 Philadelphia: Saunders. 1978.
2. Carson CC III, Malek RS. Transurethral prostatic resection: Surgical anatomy of the prostate and prostatic hyperplasia. In: Greene LF, Segura JW eds. Transurethral Surgery. Philadelphia: Saunders. 1979.
3. Jackson E, Fowler, Jr In: Urologic Surgery, Suprapubic prostatectomy. vol 2, 2nd ed. 1992;371:6.
4. Singh R, Cahill D; Popert R and O'Brien O, Repeating the measurement of prostatic - specific antigen in symptomatic men can avoid prostatic biopsy. BJ. Urol. International. 2003; 92:932-5.
5. Nielson K, Anderson K, Asbjorn J, Blood loss in transurethral prostatectomy: epidural versus general anaesthesia. Int. Urol. Nephrol. 1987;19:287.
6. Hutch JA, Rombo ONJR A study of the anatomy of the prostate, prostatic urethra and the urinary sphincter system. J. Urol. 1970;104:443.
7. O'conor VJ Jr, Aid of haemostasis in open prostatectomy; capsular plication J. urol. 1982;127:448.