

Original Article

THE SUB-DELTOID VERSUS INTRA-PERITONEAL IMPLANTATION OF CANINE MACRO-CAPSULE ALLOGENIC AMNIOTIC MEMBRANE; ASSESSMENT OF REJECTION AND NEO-VASCULARIZATION.

By

M M Akl, O A Hammam, A H I HELMY,* M A Mahgoub,** A A A Ammar,*** H A A Ashmawi,***

Departments of Histopathology, *Academic Unit of Surgery & Experimental Surgical Unit, ,*Theodore Bilharz Research Institute, Giza, EGYPT, **Departments of General Medicine and Endocrinology Department, ***Pancreatic Islet Transplantation and diabetic Research Unit (PITRU), **,***Faculty of Medicine, Ain Shams University, Cairo, Egypt.

Aim: Pancreatic islets encapsulation is an alternative for using the immuno-suppression to prevent rejection. We used the amniotic membrane as a macro-capsulation. The main objective was to assess the re-vascularization of the allogenic amniotic membrane macro capsule in different sites to ensure the islet viability when using it for encapsulation.

Methods: 30 amniotic membranes macro capsules were implanted in 15 dogs in two different sites; in the sub-deltoid shoulder region and in a piggy bag pouch in the recipient peritoneal cavity under general anesthesia. The capsules are removed after day 1, 3, 7, 10, 15, 21, 30 and 60 days. All the capsules are subjected to histo-pathological examination and immuno-histochemistry for neo-vascularization using VEGF, Factor VIII and CD4, CD8 for detection of rejection.

Results: All specimens showed inflammation and congested blood vessels with no thrombosis or rejection. VEGF expression and Factor VIII were increased; neo-vascularization associated with vascular invasion but no inflammatory cells of acute rejection. CD4 and CD8 showed mild rejection.

Conclusion: The implantation of the amniotic sac macro capsule was fixed nicely within the omental tissue and the sub-deltoid region with minimal or no sign of rejection. Our results should help the clinical application of using this capsule as an immuno-isolator for pancreatic islets transplantation.

Keywords: pancreatic islets transplantation, macro-capsulation, amniotic membrane, neo-vascularization, rejection.

INTRODUCTION

Islet encapsulation has proved to be a successful method to prevent rejection.⁽¹⁾ Encapsulation of pancreatic islets allows for transplantation in the absence of immuno-suppression.⁽²⁾ The technology is based on the principle that transplanted tissue is protected for the host immune system using either micro-encapsulation techniques or an artificial membrane macro encapsulation. It strongly suggests that this could be achieved and may have important implications as therapy for human insulin-dependent diabetes.^(3,4)

Encapsulation offers a solution to the shortage of donors and the fact that multiple glands may be required to isolate sufficient numbers of islets to treat a single patient, in clinical islet transplantation because it allows xeno-grafting of isolated islets from animal sources or insulin-producing cells engineered from stem cells to be used.⁽⁵⁾

Several different types of systems employing selectively permeable membranes and matrix supports for cells have been successfully tested in animals, including devices anastomosed to the vascular system as arterio-venous (AV) shunts, tubular membrane chambers, and spherical micro- and macro-capsules.^(4,5,6) The use of immuno-isolation

“macro-encapsulation” to help transplanted cells to resist the immune system of the host to destroy them has been applied to the treatment of diabetes. The limitations in cell longevity to function will necessitate periodic replenishment of the cells. The ability to cross species using these technique “macro-encapsulation” has the potential to expand the number of diabetic patients that can be successfully treated.^(7,8,9) The same principle has been used for different diseases and in different sites.⁽¹⁰⁾ Transplanted islets between different animal species have been tried intra-peritoneally and within semi-permeable macro-capsules subcutaneously, they survive and reverse diabetes in diabetic mice. The proof of principle is illustrated for successful xeno-transplantation in humans.⁽¹¹⁾ In our previous studies we’ve proved that intra abdominally implanted macro-capsule formed of the amniotic membrane can be used successfully for islets transplantation because of its immuno-isolation properties and its capability of neo-vascularization when implanted intra abdominally.^(12,13)

Neo-vascularization or angiogenesis is the biological process of forming new blood vessels from existing ones estimated by an abnormal growth of micro-vessels. Angiogenesis is a highly controlled, multi-step process in endothelial cells.⁽¹⁴⁾ Vascular endothelial growth factor (VEGF) is a potent growth factor cytokine mediating angiogenesis. Factor VIII - related antigen is also known as marker of the angiogenic micro-vessel.^(15,16) VEGF also stimulates endothelial cell growth in vitro and in vivo, leading to increased blood vessel permeability and promotes the migration of endothelial cells, forming of tube-like structures.^(17,18)

T-lymphocytes possess the surface antigens CD4 or CD8.⁽¹⁹⁾ Both subtypes of T cells The CD4+ and CD8+ T cells are involved in the cell mediated immunity and they perform a distinct but somewhat overlapping functions.⁽²⁰⁾ They are considered major players in the rejection process.⁽²¹⁾ Major histocompatibility complex (MHC) class II-restricted CD4+T cells are well appreciated for their contribution to peripheral tolerance to tissue allografts,⁽²²⁾ CD4+T cells play a central role both in islet allograft rejection in diabetic mice.⁽²³⁾

In this study we compared the deltoid muscle as a site for implantation versus the intra abdominal site as regards clinical application, assessing revascularization using VEGF, Factor VIII and rejection CD4 + CD8; monoclonal antibodies on tissue sections using indirect immune stain technique.

PATIENTS AND METHODS

Ethical consideration: All experimental protocols & procedures in this study were reviewed and approved by the institutional review board of Ain Shams University and

Theodore Bilharz Research Institute ethical committees.

Donor Procedure: amniotic membrane harvesting: The amniotic membranes obtained by caesarian sections performed on 10 healthy full-term pregnant mongrel female dogs were used to construct the macro-capsules. One of them was taken for histo-pathological and immuno-histochemical studies as a control.

Laboratory preparation of the Amniotic Membrane: capsule preparation: Every amniotic membrane was washed twice with isotonic saline containing antibiotic /antimycotic with gentle milking to evacuate its blood vessels. Then it was preserved at 4°C for 1 hour. After marking the chorionic side, the edges of the membrane were sealed using an adhesive gel (siliastic, medical adhesive silicon type I), giving rise to a small bag-shaped chamber (internal volume 1 mL), which was loaded with an inert marker before being closed to create a lumen that could be easily identified during explantation. The capsule was immersed at room temperature in isotonic saline containing antibiotic/anti mycotic before implantation (2 to 3 hrs).

The recipient procedure: the capsule implantation:

Anesthetic procedures: 15 mongrel dogs (8-14 Kg) were fasted for 12 hours prior to surgery, received IM Ketamine hydrochloride 20 mg/kg & Atropine 0.05 mg/kg., anesthesia was induced using 35 mg/kg of IV Sodium Pentobarbital, and dogs were monitored and maintained on 1.5-2.5% halothane-oxygen mixture with positive pressure ventilation.

The Intra peritoneal (IP) implantation: Dogs were positioned supine, abdomens were shaved & cleaned, swabbed with povidone-iodine surgical scrub and were draped with sterile drapes. Abdomen was opened through a lower midline incision getting the omentum outside on a separate sterile abdominal swab. Implantation of donor capsule was done after refashion the omentum for this purpose in a piggy-bag pouch with the capsule inside (Fig 1,2).

The Deltoid (D) implantation: The dogs were positioned on the left lateral side, the right side deltoid regions were prepared as previously, the skin was opened through a transverse incision over the muscle, formation of a pouch by a muscle splitting technique through the muscle fibre using an artery forceps. The Donor capsule was completely embedded between the deltoid muscle fibres using a special technique to pull it through (cis-trunk manner), closure of the muscle and the skin incision was done (Fig 3,4).

Capsule explantation: All dogs were allowed to live freely and separately in cages after the procedure. They were given 0.5 gm bd IM 3rd generation Cephalosporin. Those animals the survived the procedures were divided into 8 groups i.e. group I (1 day), group II (3 days), group III (7

days), group IV (10 days) group V (15 days) group VI (21 days) group VII (30 days) and group VIII (60 days). Tissue samples (implanted capsule in the omentum and the deltoid sites) were obtained from those animals under general anesthesia. And the animals were sacrificed according to protocol.

Histo-pathological procedures:

Extraction of the implanted amniotic sac capsule was performed from the two sites; they were immediately fixed into 10% buffer formalin & processed into paraffin blocks. 5 μ thick sections were made and stained with Hx & E and M.T. stains to study the histo-pathological changes and fibrosis within the sites of implantation. Control amniotic membrane was included for comparison. All samples were analyzed blindly by the same pathologist after having been randomly assigned code numbers.

Immuno-Histochemical procedures and micro-vessel density analysis:

TESPA impregnated slides were prepared for the immuno-histochemical procedures & studies using the monoclonal antibodies; CD4 / CD8 and VEGF / Factor VIII (Serotec company , United State) for signs of graft rejection and assessment of vascularity respectively. Angiogenesis of the lesions were assessed after highlighting the numbers of micro-vessels using the immuno-histochemical staining technique by Factor VIII and VEGF. The vessel counting was performed in the five microscopic field areas with maximal neo-vascularization, where the greatest number of discrete micro-vessels were stained (Hot spot), these vascular regions were identified by scanning at microscopic magnification (x200). Vessels counted per field were those delineated by brown stained endothelial cells or cell clumps and the mean number of vessels counted/ 5 successive fields were then estimated and the mean number of counted vessel per section were obtained. The scoring system used for both CD 4 & CD 8 is; (0) no cells, (+) mild number of positive cells/5 successive microscopic field = 0-20 % of cells; (++) moderate = 20-40 % of cells. (+++) sever = 40 % of cells.

RESULTS

Of the 15 dogs that were used only one was lost (died on day 58 in group VIII). 40 capsules were prepared from the 10 female donors. Only 30 were implanted and the rest were used as control. The capsules obtained from the implanted sites; 14 from the intra-peritoneal (IP) sites and 14 from the deltoid (d) sites. In all samples obtained from the intra-peritoneal (IP) sites and from the deltoid (d) sites, the capsules could be identified within the implanted tissue through the marker and showed no infection, no apparent necrosis or hemorrhage. The control samples showed a normal amniotic membrane before implantation; loose connective tissue and slight vascularity, a mean of 1-2 blood vessels /HPF.

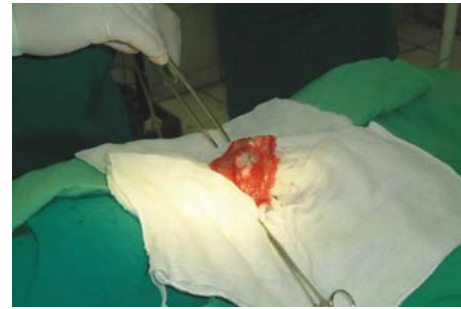

Fig 1. Capsule in the omentum on sterile sheath outside.

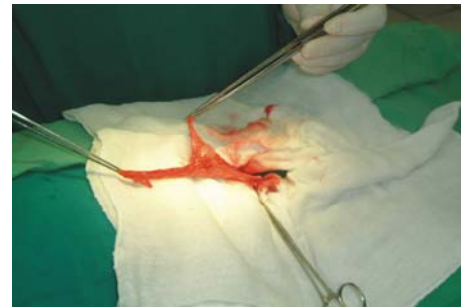

Fig 2. Capsule in the omentum in a piggy bag form prior to closure.

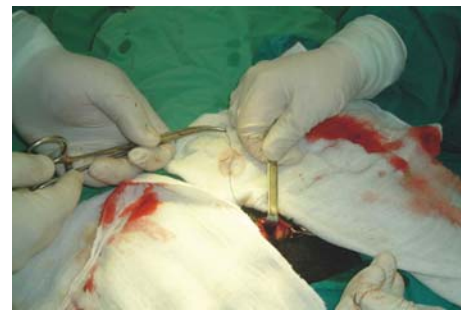

Fig 3. The cis-trunk manner of implanting the macro-capsule in sub-deltoid region.

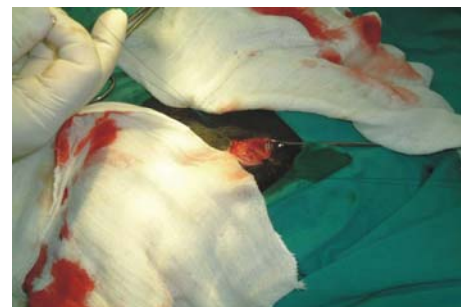


Fig 4. The capsule in the sub-deltoid region prior to closure.

Histo-pathological & Immuno-Histochemical Results Table 1. and (Graph 1-4).

In day 1: Both implanted D and IP capsules showed marked inflammation with CD4, moderate CD8, Moderate to marked angiogenesis with factor VIII and VEGF and no fibrosis.

In day 3-7: Sections showed moderate to marked vascular proliferation (neo-vascularization) in all examined specimens. In addition to signs of localized moderate acute inflammation, edema and congestion with moderate number of (PNL), esinophils & lymphocytes particularly in day 7. There was no necrosis, devitalized tissues nor vascular thrombosis. Both implanted D and IP capsules showed marked angiogenesis proven by VEGF/ VIII, with very mild inflammation but no fibrosis. The CD4 / CD8 showed very mild tendency for rejection.

In day 10 -15: Sections showed continuous moderate vascular proliferation neo-vascularization, angiogenesis and chronic inflammation with mild fibrosis mainly in day 15 in both implanted D and IP capsules, proven by VEGF/ VIII. In the implanted D capsules there was moderate angiogenesis compared to the implanted IP that showed marked angiogenesis. The CD4 / CD8 showed tendency for rejection in day 7, this tendency for rejection decreased proved by mild occasional positive results for CD4/CD8 in day 15. (Fig 5, 6, 7)

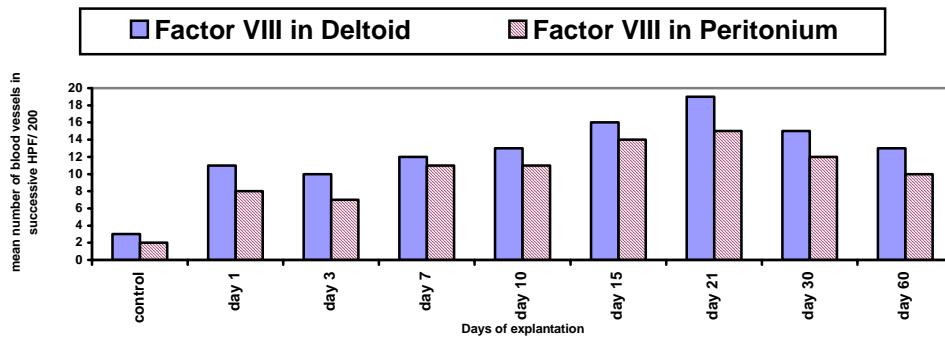
In day 21-30-60: Sections of both implanted D and IP capsules showed continuous increase in vascular proliferation neo-vascularization, angiogenesis noted by the number of vessels up to day 30-60 and inflammation with fibrosis subsided nearly completely 60, proven by VEGF/ VIII. Tendency for rejection was undetected by CD4 and CD8 up to day 60 except very mild positive results for CD8 in day 21. (Fig 8, 9, 10)

Table 1. Immuno-histochemical Results of Tissue Markers.

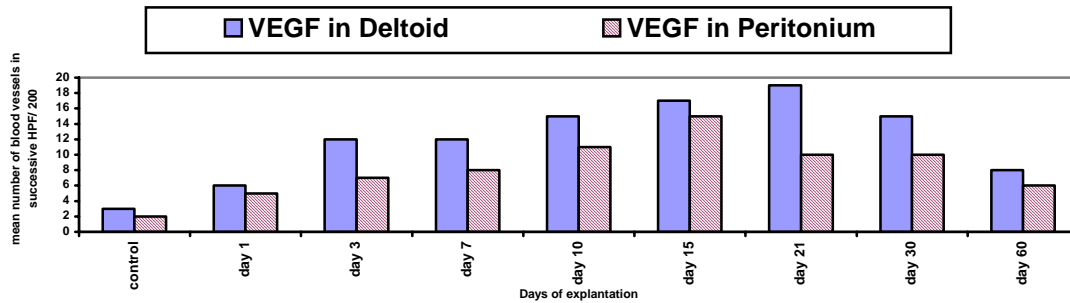
Group	Day	Tendency for rejection				Angiogenesis			
		CD4		CD8		Factor VIII		VEGF	
		D	IP	D	IP	D	IP	D	IP
control		+	+	+	+	3	2	3	2
I	Day 1	+++	++	++	++	11	8	6	5
II	Day 3	++	++	++	++	10	7	12	7
III	Day 7	++	++	++	++	12	11	12	8
IV	Day 10	+	+	++	++	13	11	15	11
V	Day 15	+	+	++	++	16	14	17	15
VI	Day 21	0	0	++	++	19	15	19	10
VII	Day 30	0	0	0	0	15	12	15	10
VIII	Day 60	0	0	0	0	13	10	18	6

D; Deltoid, IP; intra peritoneum,

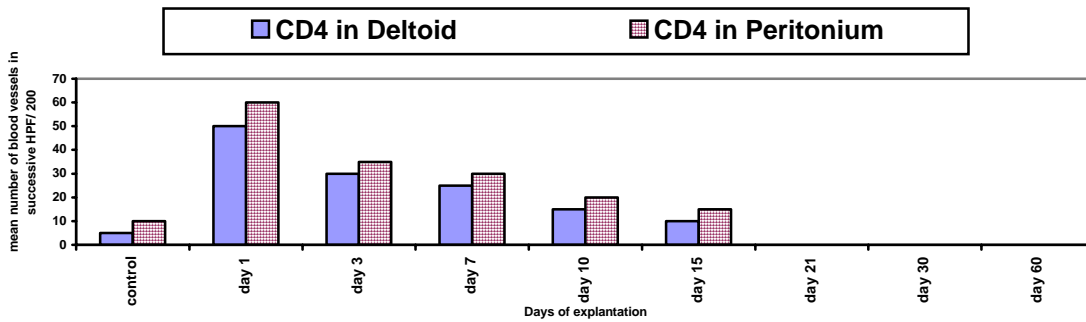
-Vessels counted per field were those delineated by brown stained endothelial cells or cell clumps and the mean number of vessels counted/ 5 successive fields were then estimated and the mean number of counted vessel per section were obtained, scoring system used is: (0) no cells, (+) mild number of positive cells/5 successive microscopic field = 0-5 % of cells; (++) moderate = 5-10 % of cells. (+++) sever > 10 % of cells.



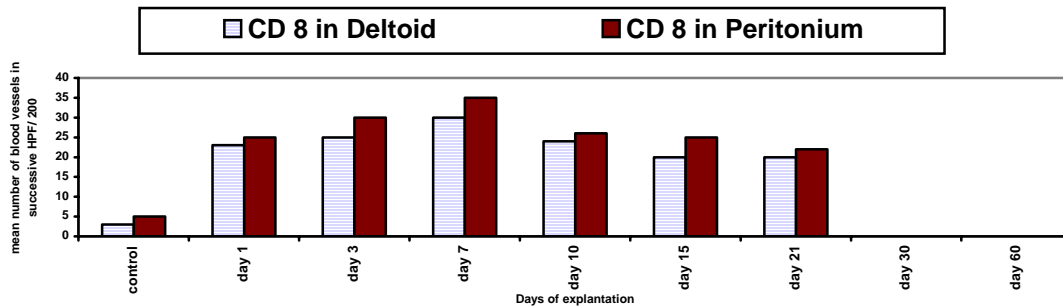
Graph 1 showing the increase number of vessels by factor VIII in D more then IP



Graph 2 showing the increase number of vessels by VEGF in D more then IP



Graph 3 showing No rejection by CD4 of the capsule in D and IP sites day 21,30,60



Graph 4 showing No rejection by CD8 of the capsule in D and IP sites in day 30,60

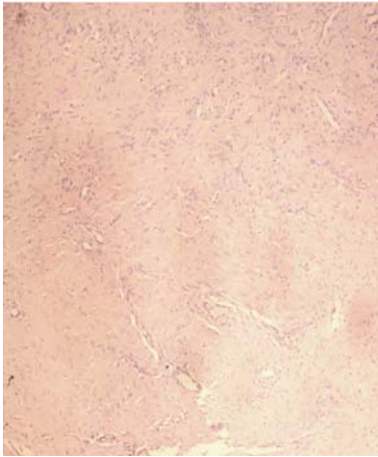


Fig 5. Day 10 CD4 D
Amniotic sac after Deltoid implantation showing mild tendency for rejection (Immunostain DAB,x100).

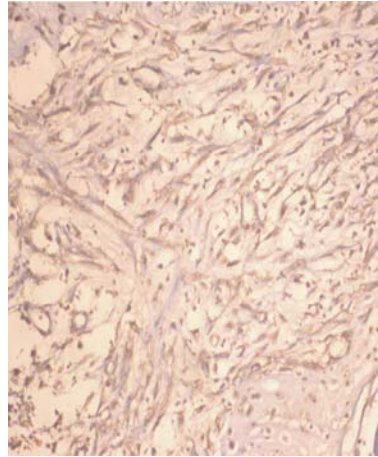


Fig 6. Day 15 Factor VIII D
Amniotic sac after Deltoid implantation showing moderate vascular proliferation and angiogenesis. (Immunostain DAB,x200).

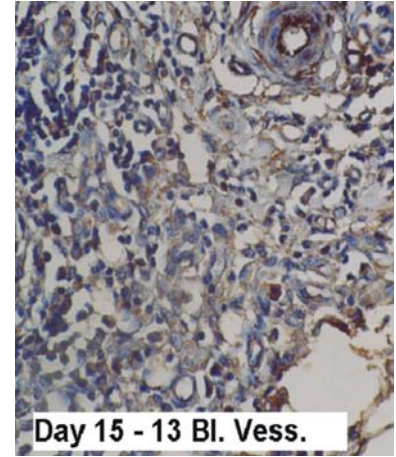


Fig 7. Day 15 VEGF IP
Amniotic sac after intra peritoneum implantation showing moderate vascular proliferation. (Immunostain DAB,x200).

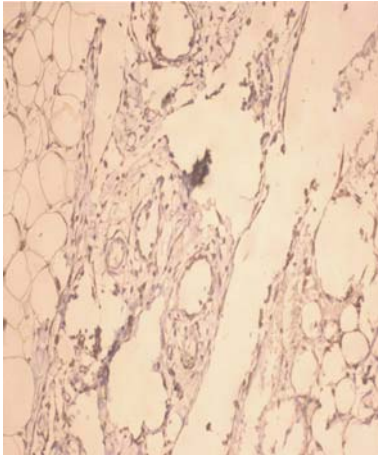


Fig 8. Day 21 Factor VIII D
(Immunostain DAB,x200).

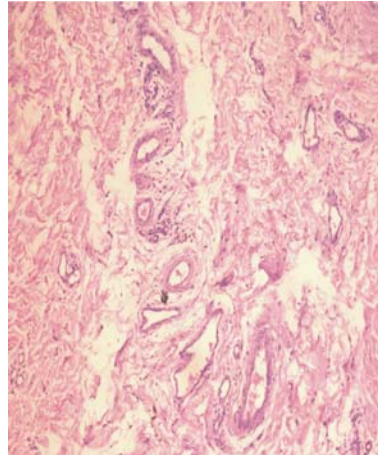


Fig 9. Day 30 Hx & E IP

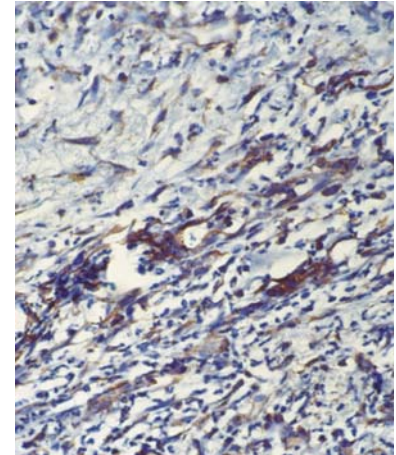


Fig 10. 10 Day 60 VEGF IP
(Immunostain DAB,x200).

Amniotic sac after implantation showing marked increase in vascular proliferation neo-vascularization. Angiogenesis is noted by the number of vessels. No fibrosis D; Deltoid, IP; intra peritoneum

DISCUSSION

Xenogenic pancreatic islets encapsulation could be an alternative to human organ shortage to treat millions of people who suffer from diabetes.⁽²⁴⁾ In our study we were trying to bridge this problem by manufacturing our amniotic sac macro-capsule trying to find out its viability and presence. It is also applicable for any kind of cellular transplantation and Protection from cellular and humoral immunities.

The results of implantation of amniotic sac macro-capsule in both deltoideal and peritoneal sites for up to 60 days was

very good and the same results were obtained from other studies. Getting the capsule in the deltoideal region was very easy technically compared to the intra-peritoneal site.⁽¹¹⁾ There were no loss of any capsules which the same obtained in recent studies. The interval we made for explanation in our study were more than the previous study and other studies.^(12,14)

Histo-pathological examination of all sections from peritoneum and deltoideal sites at all intervals , post implantation, revealed the presence of marked angiogenesis indicated by the presence and detection of micro-vessels in both deltoideal and peritoneal sites at days 3,

7 and 21 while moderate angiogenesis was detected at days 1, 10, 30, 60 days. This is nearly better from other group who studied only the implantation of capsulated islets for less than that.^(15,25)

Inflammation was prominent indicated by the acute inflammatory cells in both deltoid and peritoneal sites in days 1, 3, 7 and declined to mild in days 10, 21, 30, indicated by the chronic inflammatory cells and even disappeared in day 60. Fibrosis was mild to moderate in days 21, 30 and decline to mild in day 60 indicating the viability of the implanted capsule till the end of the experiment. This obtained results where nearly similar or even better than old and recent studies on encapsulated islets.⁽¹⁵⁻¹⁹⁾

Immuno-histochemistry procedures illustrated the angiogenesis well and showed its expression better than the routinely stained sections by Hx & E stains, through the application of VEGF and Factor VIII monoclonal antibodies. VEGF is detected in implanted tissues which prove the formation of new capillaries and revascularization of our amniotic sac macro-capsule.⁽²⁶⁾ We were able to detect VEGF in all intervals of the samples obtained from both sites in our study in early intervals 1, 3, 7, 10, 15 days and was declined like other studies at the late intervals 21, 30 and 60 days.^(15,26) This provide an evidence of the role of the pro-inflammatory function of VEGF in immunity as studied before.⁽²⁷⁾ Previous research studied on islets transplantation Factor VIII monoclonal antibodies were detected in the implanted capsule in all intervals of the whole study which indicate as well the revascularization of our implanted capsule at both sites.⁽²⁸⁾

The role of CD4 and CD8 in diagnosis of antibody mediated rejection in transplantation has been thoroughly studied.^(29,30) The high potential rejection during the stages as from day 3 to 21 days for our implanted capsule, disappeared gradually up to day 60 post implantation. This was proved by the use of the monoclonal antibodies CD4 and CD8. The results obtained by detecting rejection due to the presence of implanted capsule in both sites indicating its survival was the same obtained from recent studies that detected capsulated grafted islets survival by the use of monoclonal antibodies CD4 and CD8.⁽³¹⁾

The new results obtained in our study showing the viability of implanted capsules obtained from both sites until day 60, the deltoid site compared to intra-peritoneal showed less rejection (no expression of both CD4 and CD8) and same inflammatory response by formation of neo vascularization (expression of both VEGF and Factor VIII antibodies) and no fibrosis, which indicate its superiority in applying it clinically.

Implantation of amniotic sac in both deltoid and peritoneal sites particularly in the former site proved to be successful

with minimal inflammation and almost no or minimal fibrosis when followed up to 60 days. Implantation into Deltoid muscle could be better than into abdomen in localizing any inflammation from spreading or flaring up into the peritoneal cavity. The deltoid site is a successful and convenient site for Amniotic sac implantation and could be applied clinically under LA.

Acknowledgement: This work was performed within the frame of project scientific cooperation between "the Pancreatic Islet Transplantation and Diabetes Research Unit , Ain Shams University Hospital and Theodor Bilharz Research Institute, Cairo Egypt. This study was supported by grants from Ain Shams University and Lab. Works, equipments and animal house from Theodor Bilharz Research Institute, we thank *Professor Gehan Al-Fandy* the President of TBRI for her great and continuous support for such work.

REFERENCES

1. Lanza RP, Chick WL. Transplantation of pancreatic islets. *Ann N Y Acad Sci.* 1997;8:323-31.
2. de Vos P, Hamel AF, Tatarkiewicz K. Considerations for successful transplantation of encapsulated pancreatic islets. *Diabetologia.* 2002;45:159-73.
3. Katedra i Zaklad Anatomii Patologicznej AM we Wroclawiu. Gamian E, Kochman A, Rabczynski J, Burczak K. Biocompatibility testing and function of a pancreatic prosthesis consisting of viable pancreatic islets encapsulated in PVA macrocapsules *Polim Med.* 1999;29:3-20.
4. Lanza RP, Ecker DM, Kuhlreiber WM, Marsh JP, Ringeling J, Chick WL. Transplantation of islets using microencapsulation: studies in diabetic rodents and dogs. *J Mol Med.* 1999;77:206-10.
5. Smith C, Kirk R, West T, Bratzel M, Cohen M, Martin F, Boiarski A, Rampersaud AA. Diffusion characteristics of microfabricated silicon nanopore membranes as immunoisolation membranes for use in cellular therapeutics. *Diabetes Technol Ther.* 2005;7:151-62.
6. Desai TA, Chu WH, Tu JK, Beattie GM, Hayek A, Ferrari M. Microfabricated immunoisolating biocapsules. *Biotechnol Bioeng.* 1998;57:118-20.
7. Lanza RP, Jackson R, Sullivan A, Ringeling J, McGrath C, Kuhlreiber W, Chick WL. Xenotransplantation of cells using biodegradable microcapsules. *Transplantation.* 1999;67:1105-11.
8. Risbud MV, Bhargava S, Bhone RR. In vivo biocompatibility evaluation of cellulose macrocapsules for islet immunoisolation: Implications of low molecular weight cut-off. *J Biomed Mater Res A.* 2003;66:86-92.

9. Omer A, Keegan M, Czismadia E, De Vos P, Van Rooijen N, Bonner-Weir S, Weir GC. Macrophage depletion improves survival of porcine neonatal pancreatic cell clusters contained in alginate macrocapsules transplanted into rats. *Xenotransplantation*. 2003;10:240-51.
10. Kim YM, Jeon YH, Jin GC, Lim JO, Baek WY. Immunoisolated chromaffin cells implanted into the subarachnoid space of rats reduce cold allodynia in a model of neuropathic pain: a novel application of microencapsulation technology. *Artif Organs*. 2004;28:1059-66.
11. Elliott RB, Escobar L, Calafiore R, Basta G, Garkavenko O, Vasconcellos A, Bamba C. Transplantation of micro- and macroencapsulated piglet islets into mice and monkeys. *Transplant Proc*. 2005;37:466-9.
12. Mahgoub MA, Ammar A, Fayez M, Edris A, Hazem A, Akl M, Hammam O, Mahgoub M A, Ammar A. Neovascularization of the amniotic membrane as a biological immune barrier. *Transplant Proc*. 2004;36:1194-8.
13. Sippel Kc, Majj, Foster CS. Amniotic membrane surgery. *Curropin Ophthalmol*. 2001;12:269-81.
14. Folkman J Clinical applications of research on angiogenesis. *N Eng J Med*. 1999;333:1757-63.
15. Watanabe H, Sumi S, Urushihata T, Kitamura Y, Iwasaki S, Xu G, Yano S, Nio Y, Tamura K. Immunohistochemical studies on vascular endothelial growth factor and platelet endothelial cell adhesion molecule-1/CD-31 in islet transplantation. *Pancreas*. 2000;21:165-73.
16. Liu Y, CoxSR, Morita, Kourembanas. Hypoxia regulates vascular endothelial growth factorgene expression in endothelial cells. Identification of a 5' enhancer. *Circ Res*. 1995;77:638-43.
17. Quinn T, Peters K, De Vries C, Ferrara N, Williams L. Fetal liver kinase 1 is a receptor for vascular endothelial growth factor and is selectively expressed in vascular endothelium. *Proc Natl Acad Sci USA*. 1993;90:7533-37.
18. Pepper MS, Ferrara N, Orci L, Montesano R. Vascular endothelial growth factor induces plasminogen activators and plasminogen activator inhibitor-1 in microvascular endothelial cells. *Biochem Biophys Res Commun*. 1991;181:902.
19. Roitt ivon; jonathan brostoff & David male(1996).Cells involved in the immune response Lymphocytes *Immunology*. 1996;3:22-29.
20. Romagnani S T-cell subsets (Th1 versus Th2). *Ann Allergy Asthma Immunol*. 2000;85:9-18.
21. Peter M & Carlo E. Cells, tissues and organs of the immune system. In *Immunology*. 6th edition. Roitt I; Brostoff J & Male D (eds). 2001, Mosby. pp15-46.
22. Beilke JN, Kuhl NR, Van Kaer L, Gill RG. NK cells promote islet allograft tolerance via a perforin-dependent mechanism. *Nat Med*. 2005;11:1059-65.
23. Kupfer TM, Crawford ML, Pham K, Gill RG. MHC-mismatched islet allografts are vulnerable to autoimmune recognition in vivo. *J Immunol*. 2005;175:2309-16.
24. Schaffellner S, Stadlbauer V, Stiegler P, Hauser O, Halwachs G, Lackner C, Iberer F, Tscheliessnigg KH Porcine islet cells microencapsulated in sodium cellulose sulfate. *Transplant Proc*. 2005;37:248-52.
25. Stagner J, Mokshagundam S, Wyler K, Samols E, Rilo H, Stagner M, Parthasarathy L, Parthasarathy R Beta-cell sparing in transplanted islets by vascular endothelial growth factor. *Transplant Proc*. 2004;36:1178-80.
26. Mendola JF, Conget I, Manzanares JM, Corominola H, Vinas O, Barcelo J, Gomis R. Follow-up study of the revascularization process of purified rat islet beta-cell grafts. *Cell Transplant*. 1997;6:603-12.
27. Reinders ME, Sho M, Izawa A, Wang P, Mukhopadhyay D, Koss KE, Geehan CS, Luster AD, Sayegh MH, Briscoe DM. Proinflammatory functions of vascular endothelial growth factor in alloimmunity. *J Clin Invest*. 2003;112:1655-65.
28. Linn T, Erb D, Schneider D, Kiszun A, Elcin AE, Bretzel RG, Elcin YM. Polymers for induction of revascularization in the rat fascial flap: application of vascular endothelial growth factor and pancreatic islet cells. *Cell Transplant*. 2003;12:769-78.
29. Nadasdy GM, Bott C, Cowden D, Pelletier R, Ferguson R, Nadasdy T. Comparative study for the detection of peritubular capillary C4d deposition in human renal allografts using different methodologies. *Hum Pathol*. 2005;36:1178-85.
30. Vessie EL, Hirsch GM, Lee TD. Aortic allograft vasculopathy is mediated by CD8(+) T cells in Cyclosporin A immunosuppressed mice. *Transpl Immunol*. 2005;15:35-44.
31. Xu BY, Yang H, Serreze DV, MacIntosh R, Yu W, Wright JR Jr. Rapid destruction of encapsulated islet xenografts by NOD mice is CD4-dependent and facilitated by B-cells: innate immunity and autoimmunity do not play significant roles. *Transplantation*. 2005;80:402-9