

## Original Article

# ONE SURGEON SHOW LAPAROSCOPIC CHOLECYSTECTOMY THROUGH THREE PORTS

By

A I Nafeh MD, M Abbas MD, Y F Youssef MD, A H I Helmy MD, FRCSEd,  
Departments of General Surgery Theodor Bilharz Research Institute, Giza, EGYPT.

**Aim:** The well known advantages of the standard laparoscopic cholecystectomy are attributed to the small four port incisions with less surgical trauma than open surgery. Accordingly, reduction of the number of ports may be proposed to maximize the advantages of laparoscopic cholecystectomy. The aim of this work was to try the feasibility of the three port laparoscopic cholecystectomy and to evaluate if there is a potential advantage over the standard 4 port technique.

**Materials and Methods:** This study included 60 cases divided into 2 equal groups. Patients in the first group (GI) were subjected to standard four port cholecystectomy, while in the second group (GII) the operations were done through three ports. Operations in GII were carried out by one surgeon using 2 handed techniques and a camera man technician.

**Results:** Omitting of the fourth port in GII did not affect the operative field. In GII, only 2 cases needed a fourth port and the conversion rate to open surgery was 3.3% as similar as in GI. The post operative pain was indicated by the number of intramuscular NSAID analgesic injections which was significantly higher in GI ( $1.3 \pm 0.7$ ) than in GII ( $0.9 \pm 0.6$ ) with  $p < 0.05$ . There was no mortality or significant morbidities in both groups.

**Conclusion:** Laparoscopic cholecystectomy through three ports is a feasible and safe technique. It gives more satisfactory results to the patients, particularly those with cosmetic wise concept.

**Keywords:** laparoscopic surgery, cholecystectomy, three port technique.

## INTRODUCTION

Many years ago, the concept of decrease surgical incisions to have less postoperative pain and more cosmetic appearance have been adopted.<sup>(1)</sup> In this concern open mini-cholecystectomy through a small incision gives better results than the conventional open operation.<sup>(2)</sup> Furthermore, micro-cholecystectomy with smaller incision reported to be more superior to the above two approaches. These good results supposed to be due to decrease surgical trauma of the muscle cutting incisions.<sup>(3,4)</sup>

The introduction of laparoscopy has approved this concept. The abdominal incisions have been markedly reduced to four (or more) small stab incisions. This approach magnificently provides less postoperative pain, short hospital stay, good cosmetic appearance and early recovery

and return to normal activities.<sup>(5-7)</sup> It is expected that any decrease in the size or number of stab incisions may provide better results added to the above mentioned advantages of laparoscopic cholecystectomy. However, some surgeons have argued that smaller is not necessarily better,<sup>(8)</sup> while many others proved that reducing the number and size of port incisions have more favourable results.<sup>(9-14)</sup>

The main objective of this work was to try the feasibility of the three port laparoscopic cholecystectomy by one surgeon and an authorized and well trained camera technician. Also, to evaluate if there is potential advantages over the standard four port laparoscopic cholecystectomy.

## PATIENTS AND METHODS

This prospective controlled study was carried out on patients with symptomatic gall bladder stones. The exclusion criteria included acute cases with previous upper abdominal open surgery, severe coagulopathy, associated other abdominal pathology which might need an additional surgery and cases with significant cardiopulmonary diseases. All patients were subjected to history taking, clinical examination and a thorough biochemical, radiological, cardiopulmonary examination and all of them gave an informed consent to enter the study. The patients were divided into two groups. All cases underwent operation under general anaesthesia. Intravenous antibiotic (cefoperqzone, 1000 mg) was injected just before skin incision.

In the first group (GI), standard laparoscopic cholecystectomy was done through four ports; the umbilical port (10mm, for camera), epigastric port (10mm, for working instruments), mid-clavicular port (5mm, for Hartman's pouch retraction) and the anterior axillary port (5 mm, for gall bladder retraction).

Patients in the second group (GII) were subjected to cholecystectomy through three ports, omitting the anterior maxillary port. The three ports included the umbilical (10 mm, for camera), the epigastric (10 mm, for working instruments) and the mid-clavicular one (5 mm, for gall bladder retraction). The last port site was at a lower level than in 4 port technique. A grasper is used through the epigastric port to retract the gall bladder upward and laterally toward the right shoulder, and then another grasper is used through the mid clavicular port to retract the gall bladder Hartman's pouch to expose the Callot's triangle. At that time, the grasper of the epigastric port could be removed without affection of the operative field. In cases of redundant gall bladder that obscure the operative field, it could be retracted to the abdominal wall using a stitch. A prolene stitch size<sup>(1)</sup> with a straight needle passed percutaneously through the gall l bladder fundus or body to get back again and tied on the skin.

Skeletonization and control of the cystic artery and duct could be carried out easily and safely by using 2 handed technique. Dissection of the gall bladder out of its bed is completed and its extraction through the epigastric port was done as in standard laparoscopic cholecystectomy. Sub-hepatic tube drain was used only in selected cases if postoperative bleeding or bile leakage was expected. After full recovery, the patients had narcotic analgesics in the

form of intramuscular pethidine injection at a dose of 1mg./ kg.

The intra-operative findings and the operating time from skin incision to skin closure were reported. Postoperative pain was assessed and calculated as the mean number of intramuscular analgesic injections needed in the form of non steroidal anti inflammatory drugs (Diclofenac sodium 75 mg./amp.) . Hospital stay, postoperative complications, cosmetic results, patient satisfaction and the time needed for return to normal activities were also reviewed in all patients.

## RESULTS

The current prospective controlled study included 60 cases divided into two equal groups. Patients in the first group (GI, n= 30) were subjected to standard laparoscopic cholecystectomy through four ports, while in the second group (GII, n= 30) the laparoscopic surgery was carried out through 3 ports.

Patients' demographic data were almost equally distributed among both groups Table 1. In GII, laparoscopic cholecystectomy could be done through three ports in 27 (90 %) cases. The operative field was quite clear and comparable to that in standard four ports cases (Fig .1). In three cases of GII, the liver and gall bladder hindered the operative field. In one of these 3 cases, laparoscopic cholecystectomy could be completed through 3 ports by retraction of the gall bladder fundus to the anterior abdominal wall using a prolene stitch size1 (Fig .2). In this particular case, the operating time was quite long (122 min). In the other 2 cases we admitted failure of three port technique and the fourth anterior axillary port was inserted for gall bladder fundus and liver retraction as in standard laparoscopic cholecystectomy without significant additional time. The conversion to open surgery in GII occurred in one case (3.3%) due to marked adhesions as similar as in GI Table 2. Sub-hepatic tube drain was used in 2 cases in GII compared to 3 cases in GI but this difference was not significant. The mean operating time was  $65 \pm 22.94$  minutes in GI compared to  $62 \pm 20.24$  minutes in GI, this difference was not significant. No bile duct injury or per-operative mortality was reported in either group Table 2. The postoperative pain was less observed in GII. The mean number of intra -muscular analgesic injections was significantly higher in GI ( $1.3 \pm 0.7$ ) than in GII ( $0.9 \pm 0.6$ ) with  $p < 0.05$ . Patients in GII expressed more satisfaction regarding the post operative skin scars. There was no significant difference in duration of hospital stay or return to normal activities in both groups. There was no significant morbidity reported in this study Table 3.

**Table 1. Pre-operative data.**

	Group I ( GI , n = 30 )	Group II ( GII , n = 30 )
Age ( years)	45 ± 15 .8	47 ± 16.8
Sex ( M:F)	8 : 22	9 : 21
Weight ( Kg)	79 ± 14.2	81 ± 15.9

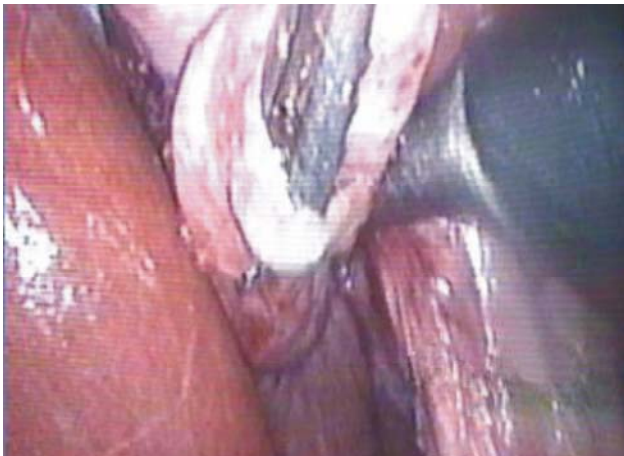
**Table 2. Intra-operative findings.**

	Group I ( GI , n = 30 )	Group II ( GII , n = 30 )
Stitch traction	-	1( 3.33% )
Additional ports	-	2 ( 6.67% )
Conversion	1 ( 3.33% )	1 ( 3.33% )
Drain	3	2
Mean Operating time (min)	62 ± 20.24	65 ± 22.34
Bile duct injury	-	-

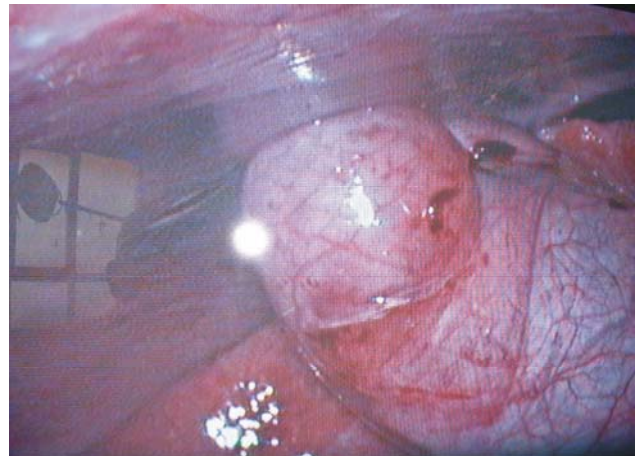
**Table 3. Post operative follow up (failed cases were exuded).**

	Group I (G I , n = 29 )	Group II (GII , n = 27)
Analgesics *	1.3±0.7	0. 9±0.6
Hosp. Stay ( days )	2.2 ± 1.2	2.3 ± 1.4
Return to normal activities ( days )	15.4 ± 5.2	14.6 ± 6.8
Wound infection	1	1
Biliary injuries	-	-
Hernia	-	-

\* The mean number of intramuscular analgesic injections.



**Fig 1. The operative field during 3 port lap. Cholecystectomy**



**Fig 2. Stitch retraction of gall bladder during 3 port lap. Cholecystectomy**

## DISCUSSION

In this work, laparoscopic cholecystectomy has been performed through three stab incisions omitting the most lateral wound for gall bladder fundus retraction with encouraging results. The technique has been done successfully in 27 out of 30 cases (90%). In one of these cases, gall bladder retraction was done using a prolene stitch through the abdominal wall to facilitate completion of the three port technique, but this manoeuvre was found to be time consuming. In this concern, a previous pioneer study described laparoscopic cholecystectomy using three stitches for retraction and manipulation of gall bladder without using instrumental traction. They performed laparoscopic cholecystectomy through only two ports, a supra-umbilical (10 mm/ 5 mm) and an epigastric (10mm) ports. Their operating time ranged from 35 to 139 minutes with an average time of 65 minutes, quite shorter than the single case reported in our study.<sup>(12)</sup>

In the current study, the three port technique failed in 3 (10%) cases. In first two patients, a fourth port was used for gall bladder fundus retraction, and these cases were considered as conversion to conventional four port technique. These results were similar to those reported by other investigators who needed additional ports in 9% of cases.<sup>(15)</sup> Other study reported using of a fourth port in only 5% of cases,<sup>(16)</sup> while other investigators reported three ports technique in 100% without any additional port.<sup>(13)</sup> The third patient was converted to open surgery. The conversion rate to open surgery was 3.33%, exactly the same as in the standard four port technique.

Other studies reported variable rates of conversion ranged from 0%<sup>(17)</sup> to 16%.<sup>(18)</sup> These variations were due to case selection and instrumental facilities. The post-operative pain expressed by the number of intra-muscular analgesic injections was significantly less in GII ( $P < 0.05$ ). Some investigators reported favourable matched results,<sup>(13)</sup> while others demonstrated no reduction in postoperative pain after three ports laparoscopic cholecystectomy.<sup>(19)</sup>

The mean operating time was longer in the three port group, but the difference was not significant and it actually improved progressively with the learning curve. These results were comparable to those noted by other investigators.<sup>(16)</sup>

The economic and cosmetic aspects of the three port operation may be controversial. The omission of one port is not of great financial advantage, but it may have valuable consideration in case of shortage of instruments available in the operating theatre. Regarding the cosmetic impact, abundance of one small scar (5 mm) seemed to be of little consideration, but patients in this group (GII) felt more psychological satisfaction than in the other group (GI).

It was strange enough that patients in group I reported their hope if they were undergone the operation through three ports.

As medical technology has continued to evolve, this type of surgery has been made even less invasive. Smaller instruments as well as better light sources and optics make it possible to perform micro-laparoscopic needle-scopic surgery with more favourable results.<sup>(13,15)</sup> Furthermore, it has been reported that the laparoscopic field of view can be controlled more precisely and effectively by robotic arm than by human.<sup>(20,21)</sup> A relatively recent study described a visual field tracking camera for laparoscopic surgery that allows the visual field to be changed without moving the laparoscope. This system allows the surgeon to control the robotic arm and the camera with manual switches, pedals, or verbal commands.<sup>(22-24)</sup>

So, the laparoscopic cholecystectomy could be performed by a single surgeon without any need to touch the laparoscope.<sup>(25)</sup> However the above mentioned technology requires more financial support, advanced technical skills and experienced surgeons.<sup>(15,25)</sup>

To conclude; laparoscopic cholecystectomy through 3 ports is a feasible and safe technique. It does not add a significant objective advantage over the standard 4 port technique but it provides more challenge for the surgeon particularly in case of instrumental shortage or failure. It also offers a significant less postoperative pain and more subjective satisfaction to the cosmetic wise patient although; these might be on mere psychological base.

## REFERENCES

1. Baxter JN, O'Dwyer PJ. laparoscopic or minilaparotomy cholecystectomy; *BMJ*. 1992;304:559-60.
2. Barkun JS, Barkun AN, Sampalis JS. Randomised controlled trial of laparoscopic versus minicholecystectomy. The McGill Gallstone Treatment Group. *Lancet*. 1992;340:1116-9.
3. Rozsos I, Jooko G. Microlaparotomy cholecystectomy. *Ann Surg*. 1995;222:762-3 (Letter).
4. Helmy AHI , Abbas M , EL - Sebai S , Mohey - EL- Dien A , AL - Kholy B . Is modified open microcholecystectomy still valid in the era of laparoscopic surgery? *Egyptian Journal of Surgery*. 2003;22:37-44.
5. Williams LF, Champan WC, Bonau RA, McGee EC .Comparison of laparoscopic cholecystectomy with open cholecystectomy in a single center. *Am J Surg*. 1993;165:459-465.
6. Kane RL , Lurie N , Borbas C , Morris N , Flood S , McLaughlin B ,et al. The outcomes of elective laparoscopic and open cholecystectomies *J Am Coll Surg*. 1995;180:136-45.

7. Soper NJ, Barteau JA, Clayman RV, Ashley SW, Dunnegan DL. Comparison of early postoperative results for laparoscopic versus standard open cholecystectomy. *Gynecol. Obstet.* 1992;174:114-8.
8. Berci G. Laparoscopic cholecystectomy using fine - caliber instruments: smaller is not necessarily better. *Surg Endosc.* 1998;12:197 (abstract).
9. Cala Z .Laparoscopic cholecystectomy using three trocars. *Surg. Endosc.* 1994; 8 476 (Abstract).
10. Sarli L , Iusco D , Gobbi S , Porrini C, Ferro M , Roncoroni L . Randomized clinical trial of laparoscopic cholecystectomy performed with mini -instruments. *Br J Surg.* 2003;90:1345-8.
11. Trichak S. Three port versus standard four port laparoscopic cholecystectomy. *Surg Endosc.* 2003;17:1434-6.
12. Ramachandran CS and Arora V. Two - port laparoscopic cholecystectomy: an innovative new method for gallbladders removed. *J Laparoendosc. Adv. Surg. Tech A.* 1998;8:303-8.
13. Leggett PL, Churchman - Winn R, Miller G. Minimizing ports to improve laparoscopic cholecystectomy. *Surg. Endosc.* 2000;14:32-6.
14. Yu SC, Yuan RF, Chen SC, Lee WJ. Combined use of mini - laparoscope and conventional laparoscope in laparoscopic cholecystectomy: Preservation of minimal invasiveness. *J Laparoendosc Adv. Surg Tech A.* 1999;(1):57-62.
15. Unger SW, Paramo JC, Perez M. Microlaparoscopic cholecystectomy. Less invasive gallbladder surgery . *Surg. Endosc.* 2000;14:336-9.
16. Tagaya N, Kita J, Takagi K, Imada T, Ishikawa K, Kogure H ,el al. Experience with three-port laparoscopic cholecystectomy. *J Hepatobiliary pancreatic. Surg.* 1998;5:309-11 (abstract).
17. Sarli L, Costi R, Sansebastiano G. Mini - Laparoscopic cholecystectomy versus laparoscopic cholecystectomy. *Surg. Endosc.* 2001;15:614-8.
18. Look M, Chew SP, Tan YC, Liew SE, Cheong DM, Tan JC, el al.CH, Low CH.Post - operative pain in needlescopic versus conventional laparoscopic cholecystectomy: a prospective randomized trial. *J .R Coll. Surg Edinb.* 2001;76:138-42 (Abstract).
19. Leggett PL, Bissell CD, Churchman -Winn R, Ahn C. Three - port microlaparoscopic cholecystectomy in 159 patients. *Surg. Endosc.* 2001;15:293-6.
20. Jacobs LK, Shayani V, Sackier JM. Determination of the learning curve of the AESOP robot. *Surg Endosc.* 1997;11:54-5.
21. Kavoussi LR, Moore RG, Adams JB, Partin AW. Comparison of robotic versus human laparoscopic camera control. *J Urol.* 1995;154:2134-6.
22. Allaf ME , Jackman SV , Schulam PG , Gadeddn JA , Lee BR , Moore RG ,el al. Laparoscopic visual field , voice versus foot pedal interface for control of the AESOP robot . *Surg Endosc.* 1998;12:1415-8.
23. Begin E, Gagner M, Hurteas R, santis S Pomp A. A robotic camera for laparoscopic surgery: conception and experimental results. *Surg. Laparoscopic Endosc.* 1995;5:6-11.
24. Unger SW , Unger HM , Bass RT .AESOP robotic arm. *Surg Endosc .*1994;8:1131.
25. Kimura T, Umehara Y, Matsumot S. Laparoscopic cholecystectomy performed by a single surgeon using a visual field tracking camera. *Surg. Endosc.* 2000;14:825-9.