



## Nephroprotective Impact of Fermented Kefir Laban in Type I Diabetic Rats: Antioxidant and Anti-inflammatory Pathways

Fatimah M. A. Yousef

Department of Food and Nutrition, Faculty of Human Sciences and Design, King Abdulaziz University, Jeddah, Saudi Arabia.

### Abstract

**W**ITH DIABETES cases soaring worldwide, including in Saudi Arabia, researchers are focusing on probiotic-rich foods like fermented kefir laban (FKL) as a potential way to prevent its complications. FKL's unique mix of antioxidants, anti-inflammatory properties, and immune-boosting abilities make it a promising option for preventative healthcare. This investigation aimed to elucidate the influence of FKL administration on markers of oxidative stress and inflammation in diabetic rats, with the primary objective of assessing its potential renoprotective effects. Diabetes was induced by Streptozotocin (STZ) (65 mg/kg) intraperitoneal (i.p.) injection. Forty rats were assigned to four groups: (1) control, (2) diabetic, (3 and 4) diabetic + 2 and 4 ml FKL /200 g body weight daily, respectively by oral administration for 35 days. Serum glucose, insulin, renal function, antioxidants, and pro-inflammatory cytokine markers were assessed. Besides, the renal histopathological changes were examined. FKL administration exhibited potent hypoglycemic and renoprotective effects, evidenced by significant reductions in serum glucose, urea, uric acid, and creatinine levels. FKL also demonstrated a statistically significant increase in serum insulin. Furthermore, FKL suppressed the diabetes-induced inflammation, as indicated by decreased serum tumor necrosis factor-alpha (TNF- $\alpha$ ) and interleukin-6 (IL-6) concentrations. Interestingly, FKL significantly reduced serum malondialdehyde (MDA) while concomitantly increasing superoxide dismutase (SOD) activity. Additionally, FKL mitigated diabetic-induced histopathological alterations in the renal, with the most pronounced effects observed in the group receiving the highest FKL dose. These findings suggest a potential role of FKL in modulating multiple pathways involved in preventing diabetic nephropathy.

**Keywords:** Fermented kefir milk; Diabetic nephropathy; Antioxidants; Anti-inflammatory; Histopathological.

### Introduction

Diabetes is considered a leading public health problem. Globally, it affects millions of populations. The WHO predicts 439 million persons will have diabetes in 2030 [1]. Diabetic nephropathy, cardiovascular disorders, neuropathy, and retinopathy are considered the most common pathological complications of diabetes [2]. Diabetic renal disease remains the unresolved major problems of diabetes that resulted in end-stage renal disease (ESRD) in all diabetic type I and II. Approximately 47 % of ESRD cases are due to diabetic nephropathy [3]. Clinical studies have provided clear evidence that angiotensin-converting enzyme (ACE) inhibitors, and probably also AT1 receptor

antagonists, at least in patients suffering from diabetes, slow disease progression to end-stage renal failure [4]. However, it has numerous side effects. Therefore, there is an urgent need for natural interventions to protect the renal in diabetic cases [5].

The human microbiota is an extremely complex system; it has an important impact on the health status. Numerous studies elucidated the direct and indirect influences of microbiota in health and disease *via* secreted functional molecules [6]. Several studies established the relationship between gut dysbiosis and the development of human diseases. In addition, it is associated with specific metabolic states such as obesity, metabolic syndrome, and diabetes [7,8].

\*Corresponding authors: Fatimah Mohammed Ali Yousef, E-mail: Fyousef@kau.edu.sa Tel.: +00966126400000, Extinction: 26128, Fax: 00966126952437. P.O. Box: 80200, Zip Code: 21589  
ORCID IDs 0000-0002-8636-2285

(Received 10 June 2024, accepted 30 July 2024)

DOI: 10.21608/EJVS.2024.296665.2168

©National Information and Documentation Center (NIDOC)

Food induced a marked impact on the diversity of gut microbiome. Administration of prebiotics, probiotics, and symbiotic dietary supplements positively affected microbiota, resulting in beneficial therapeutic action. Kefir grains are a unique symbiotic consisting of polysaccharides, and a protein matrix composed of a complex microbial association, mainly yeasts and bacteria. Fermented kefir laban is a fermented milk using kefir grains and is considered an excellent source of probiotics with antioxidant phenolic compounds and bioactive peptides [9, 10]. Numerous studies have proven the preventive and therapeutic benefits of FKL. It has cardioprotective and antioxidant effects against isoproterenol-induced myocardial infarction [11]. In addition, FKL has antioxidants [12], antitumoral, immunomodulatory [13], triglycerides and cholesterol-lowering [14], anti-inflammatory, and antifungal activities [15]. In addition, FKL has hypoglycemic effects *via* enhancing pancreatic  $\beta$ -cells [16].

This study aims to assess the nephroprotective effects of FKL in type 1 diabetic rats, focusing on its influence on oxidative stress and inflammation.

## **Material and Methods**

### *Kefir laban and chemicals*

Organic fermented kefir laban (HONEST Com, Saudi Arabian) was purchased from the local market, Jeddah, SA. Streptozotocin (STZ) was obtained from Sigma-Aldrich (St. Louis, MO, USA).

### *Animals*

Male Albino Wistar rats (n= 40, weight 200-240 g) were obtained from the King Fahad Medical Research Center (KFMRS), KAU, Jeddah, SA. The experiment done in KFMRS, and all aspects of the experiment were conducted according to the Canadian guidelines provided by the ethical committee of the experimental animal care. This protocol was certified by the Ethical Committee Unit, Faculty of Medicine, KAU, Jeddah, SA. The approval number PH-1444-9.

### *Induction of diabetes*

The STZ was freshly prepared immediately before injection in 0.01 M citrate buffer (pH=4.5). STZ was injected i.p. in fasted rats (fasting overnight) (65 mg/kg) single dose level. Then all injected STZ rats were allowed to drink sucrose solution (10 %) to avoid hypoglycemia shock and mortality. Diabetes induction was checked after 72 hours of i.p. STZ injection. Blood samples were withdrawn from the tail vein, then fasting blood glucose (FBG) level was measured by a glucometer Accu-Chek® Active (Roche Diagnostics GmbH, Mannheim, Germany). The animals with FBG levels  $\geq$  250 mg/dl were considered diabetic [17]. On the

other hand, control rats were injected with citrate buffer only.

### *Experimental groups*

Rats were allocated to two main experimental groups first group control rats (n=10) and second group diabetic rats (n=30). Diabetic rats were further distributed into three groups: diabetic untreated, diabetic received FKL 2 ml/200 g b.wt/d; and diabetic rats received FKL 4 ml/ 200 g b.wt/d orally. All groups were fed a standard diet during the experiment period (35 days). The dose 2ml/200 g b.wt/d for 35 days was chosen as described by Nurliyani et al. [16]. In control and diabetic untreated groups, the rats received 2 ml PBS/d orally.

Blood samples were taken from the animals after overnight fasting and then centrifuged for 10 minutes at 400 rpm (Hettich Universil 320 R. Switzerland) for serum separation, which was stored at -80 °C for measurement of the biochemical parameters. Renal tissues were fixed in formalin (10%) for histopathological examination.

### *Estimation of serum glucose and insulin concentration*

Glucose was assessed using the procedure of colorimetric kit (BioMerieux, France). Insulin was measured using an ELISA kit (Abcam, UK) following the procedure described in the kit.

### *Estimation of serum renal function indices*

Creatinine, uric acid, and blood urea nitrogen were assessed using the procedure of colorimetric standard kits (Roche Cobas Diagnostic, USA).

### *Estimation of serum oxidative stress indices*

Malondialdehyde (MDA) and superoxide dismutase (SOD) were assessed using ELISA LSBio kits (LifeSpan Biosciences, USA) as described in the kits' procedure.

### *Estimation of serum pro-inflammatory cytokines*

Tumor necrosis factor- $\alpha$  (TNF- $\alpha$ ) and interleukin-6 (IL-6) were assessed by ELISA kits (LifeSpan Biosciences, USA) as described in the kits' procedure.

### *Histological examination*

The formalin-fixed renal tissues were dehydrated with different concentrations of ethanol. Renal tissues were then embedded in paraffin and cut into 5- $\mu$ m sections. Subsequently, the renal tissues were stained with hematoxylin and eosin (H&E), and the slides were used for the histopathological microscopic examination.

### *Data analysis and statistics*

The data analysis was carried out using SPSS (Version 27). Results were presented as mean and SD (standard deviations). Comparison between

groups was assessed by one-way ANOVA test and the Tukey-Kramer post hoc test to compare the results between the study groups LSD post-hoc test. Results with p-values  $\leq 0.05$  were judged significant.

## Results

### *Fermented Kefir Laban (FKL) lowers glucose and elevates insulin levels in diabetic rats*

Serum glucose concentration was significantly elevated in diabetic rats relative to the control rats ( $p \leq 0.05$ ). Ingestion of FKM 2 ml or 4 ml /200 g to diabetic rats resulted in a significantly declined in glucose levels relative to the diabetic rats. The hypoglycemic influence of FKM was markable and significant in diabetic rats that received FKM 4 ml/200 g relative to diabetic rats that received FKM 2 ml/200 g ( $p \leq 0.05$ ). On the other hand, diabetic rats revealed a significant decrease in serum insulin level relative to control rats ( $p \leq 0.05$ ). Administrated FKM at 2 ml or 4 ml/200 g significantly elevated insulin levels relative to the diabetic rats. The high dose was efficient in improving the insulin secretion compared with the low dose. There was a significant difference between diabetic rats received 4 ml FKM relative to diabetic rats that received 2 ml FKM ( $p \leq 0.05$ ) (Fig. 1).

### *Fermented Kefir Laban (FKL) improves renal functions in diabetic rats*

Diabetic nephropathy was found in rats, as evidenced by significantly elevated renal biomarker levels in diabetic rats relative to the control rats ( $p \leq 0.05$ ). On the other hand, renal function biomarkers were significantly and progressively reduced in diabetic rats ingested FKM 2 ml or 4 ml /200g relative to the diabetic rats ( $p \leq 0.05$ ). The high dose was more effective in preventing renal functions; there was a significant difference between diabetic rats that received FKM (4 ml/200 g) relative to diabetic rats that received FKM (2 ml/200 g) (Table 1).

### *Fermented Kefir Laban (FKL) attenuates oxidative stress in diabetic rats*

Diabetics resulted in oxidative stress as evidenced via a significant elevated serum MDA concurrent with a significant reduced in serum SOD activity in diabetic rats relative to the control rats. On the other hand, FKL showed antioxidant activities as evidenced via significantly and progressively reduced MDA concurrent with significantly elevated SOD in groups that ingested FKM 2 ml or 4 ml /200g relative to the diabetic rats ( $p \leq 0.05$ ). The high dose showed a potent antioxidant effect relative to low doses. There was a significant difference between diabetic rats that received FKM 4 ml/200 g relative to diabetic rats that received FKM 2 ml/200 g in serum contents of MDA and SOD ( $p \leq 0.05$ ) (Fig. 2).

### *Fermented Kefir Laban (FKL) attenuates inflammation in diabetic rats*

Inflammation markers (IL-6 and TNF- $\alpha$ ) levels in the serum were significantly increased in diabetic rats relative to the control rats ( $p \leq 0.05$ ). The ingestion of FKM at 2 ml or 4 ml/200 g significantly diminished the serum inflammation markers (IL-6 and TNF- $\alpha$ ) relative to the diabetic rats. However, the influence was more significantly profound in diabetic rats that received the highest dose 4 ml/200 g relative to the low dose 2 ml/200 g (Fig. 3).

### *Fermented Kefir laban (FKL) prevents renal histopathological changes in diabetic rats*

The renal sections in control rats showed normal structure (Fig. 4A). Diabetes induced numerous histopathological alterations in renal tissues as evidenced by decrease in renal glomerular size and corpuscle, marked disorganization of renal parenchyma, dilation of tubular lumina, and atrophy of renal corpuscle (Fig. 4B & C). Diabetic rats received FKM (2 ml/ 200g) showing mild decline in renal glomerular size and corpuscle, mild disorganization of renal parenchyma, dilation of tubular lumina, and atrophy of renal corpuscle (Fig. 4D). Diabetic rats received FKM (4 ml/ 200 g) showing marked preservation of renal parenchyma structure, renal tubules showed healthy lining epithelium similar to that of control (black arrows) (Fig. 4E).

## Discussion

The obtained findings demonstrate that FKL administration to diabetic rats leads to a reduction in serum glucose concentration, an increase in serum insulin concentration, and a significant reduction in serum creatinine, blood urea, and uric acid levels. Additionally, FKL significantly decreases serum MDA, IL-6, and TNF- $\alpha$  levels while concurrently increasing serum SOD activity. The potential blood sugar-lowering effects and delaying the onset of hyperglycemia and insulin resistance of kefir and similar fermented products containing probiotics, including yogurt, kefir beverage, and dahi, have been investigated in earlier research [18-22]. Similar to previous findings, a further study reported that kefir consumption led to reductions in both fasting blood sugar and hemoglobin A1c levels [23].

The precise mechanism by which kefir beverage modulates blood glucose levels is not fully understood. Although the exact pathways remain unclear, researchers have proposed promising hypotheses. A predominant theory suggests that kefir exerts its effects through modulation of the gut microbiome [24,25]. Gut microbiota composition significantly impacts diabetes-associated inflammation. Disruptions in gut bacteria have been linked to raised production and circulation of pro-

inflammatory molecules, subsequently triggering the release of pro-inflammatory cytokines and contributing to insulin resistance [26]. Lipopolysaccharides, potent pro-inflammatory molecules derived from gut microbiota imbalances, exacerbate diabetes progression through multiple mechanisms, including decreased insulin secretion, enhanced beta-pancreatic cell apoptosis, and modulation of various other disease pathways [27,28]. One study proposes that kefir beverage may stimulate skeletal muscle glucose uptake through antioxidant-mediated mechanisms, thereby contributing to glycemic control [29]. Probiotic administration may exert its antihyperglycemic effects by prompting the production of gut-derived insulinotropic polypeptides and glucagon-like peptide-1, induced enhanced glucose uptake [23].

The observed association between kefir-induced reductions in blood glucose and decreased levels of urea, uric acid, and creatinine, indicators of renal function, suggests that kefir's benefits in diabetic rats extend beyond glycemic control to protecting renal health. Notably, these uremic substances accumulate as a consequence of diabetic renal complications [30]. The obtained findings indicated that FKM ingestion significantly reduced serum inflammation markers, specifically IL-6 and TNF- $\alpha$ . Both goat and soymilk kefir reduced inflammation in diabetic rats, as shown by lower levels of the marker IL-6. However, goat milk kefir was more effective, also lowering markers of chronic inflammation (C-reactive protein, CRP) and blood sugar levels [31]. Dextran sodium sulfate-induced colitis models have provided further evidence for kefir's anti-inflammatory properties. Dietary kefir administration in rats demonstrably reduced histological scores of colitis and prevented elevated colonic tissue TNF- $\alpha$  concentrations [32]. Kefir consumption demonstrated a potential anti-inflammatory effect in patients with metabolic syndrome, as evidenced by diminished serum levels of pro-inflammatory cytokines IL-6 and TNF- $\alpha$  [33].

Analysis of oxidative stress markers revealed a significant rise in these markers within the diabetic experiencing complications compared to those without. This observation suggests a potential association between elevated oxidative damage and the development of diabetic complications [34]. Oxidative stress conditions may contribute to the development of oxidative protein modifications, potentially impacting protein function

and cellular integrity [35]. Kefir administration appears to exert a synergistic effect on glycemia and oxidative stress management, potentially contributing to the amelioration of renal function in diabetic rats. This observation supports the potential use of kefir as a non-pharmacological adjuvant to delay the progression of diabetic complications [36].

Kefir consumption may exert protective effects on renal function in diabetics through mechanisms involving the reduction of intraglomerular hypertension and the alleviation of oxidative stress [30]. Biochemical analysis demonstrated a statistically significant increase in serum SOD activity in the diabetic + FKL group relative to the diabetic group. These findings are consistent with the observations reported by Yadav et al. in their study on the effects of kefir on SOD levels in hepatic and pancreatic tissues of diabetic rats [37]. Kefir administration exhibited a potential effect of augmenting renal tissue antioxidant capacity in diabetic rats, as indicated by statistically significant increases in the activity levels of SOD, catalase, and glutathione [30]. Kefir peptides treatment induced a statistically significant reduction in oxidative stress markers and a concomitant increase in SOD activity within the renal of salt-induced spontaneously hypertensive stroke-prone rats [38].

### **Conclusion**

Administration of FKL may potentially improve renal dysfunction, glycemic status, oxidative stress, and inflammation associated with type 1 diabetes. These findings indicate the promising potential of FKL as a supplementary intervention to slow the progression of diabetes-induced nephropathy.

### *Acknowledgments*

The author gratefully acknowledges the KFMRC, Jeddah, SA for technical support.

### *Funding statement*

This study didn't receive any funding support.

### *Declaration of Conflict of Interest*

There is no conflict of interest.

### *Ethical of approval*

This study follows the ethics guidelines for the handling and use of experimental animals established by the experimental animal care ethical committee at KAU. The ethics approval number is PH-1444-9.

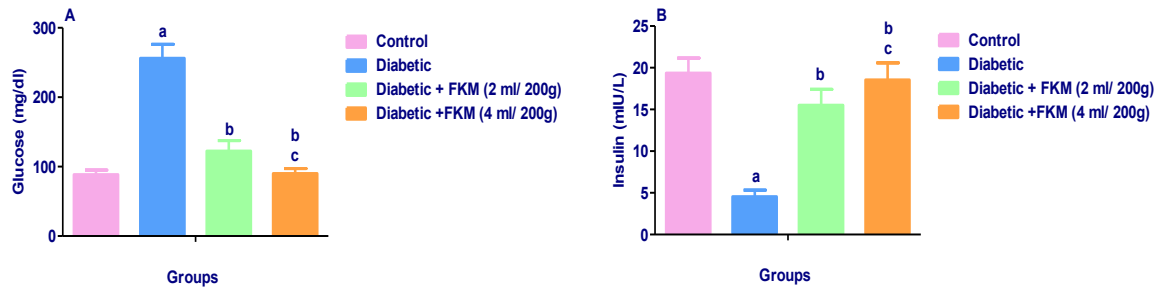


Fig. 1. Influence of FKM on A: serum glucose level and B: serum insulin level measured in diabetic rats. Results illustrated as mean  $\pm$  SD (n = 10). <sup>a</sup>Significant versus control. <sup>b</sup>Significant versus diabetic group. <sup>c</sup>Significant diabetic + FKM (2 ml/200 g) group versus diabetic + FKM (4 ml/200 g) group. ( $p \leq 0.05$ ).

TABLE 1. Influence of FKM on serum renal functions levels in diabetic rats

Experimental groups	Urea (mg/dl)	Uric acid (mg/dl)	Creatinine (mg/dl)
Control	16.67 $\pm$ 2.06	5.73 $\pm$ 0.79	0.69 $\pm$ 0.13
Diabetic	65.30 $\pm$ 6.77 <sup>a</sup>	10.41 $\pm$ 1.01 <sup>a</sup>	1.81 $\pm$ 0.17 <sup>a</sup>
Diabetic + FKM (2 ml/ 200g)	21.22 $\pm$ 2.61 <sup>b</sup>	6.58 $\pm$ 0.88 <sup>b</sup>	0.81 $\pm$ 0.13 <sup>b</sup>
Diabetic +FKM (4 ml/ 200g)	17.24 $\pm$ 1.74 <sup>b,c</sup>	5.60 $\pm$ 0.88 <sup>b,c</sup>	0.66 $\pm$ 0.12 <sup>b,c</sup>

Results illustrated as mean  $\pm$  SD (n = 10). <sup>a</sup>Significant versus control. <sup>b</sup>Significant versus diabetic group. <sup>c</sup>Significant diabetic + FKM (2 ml/200 g) group versus diabetic + FKM (4 ml/200 g) group. ( $p \leq 0.05$ )

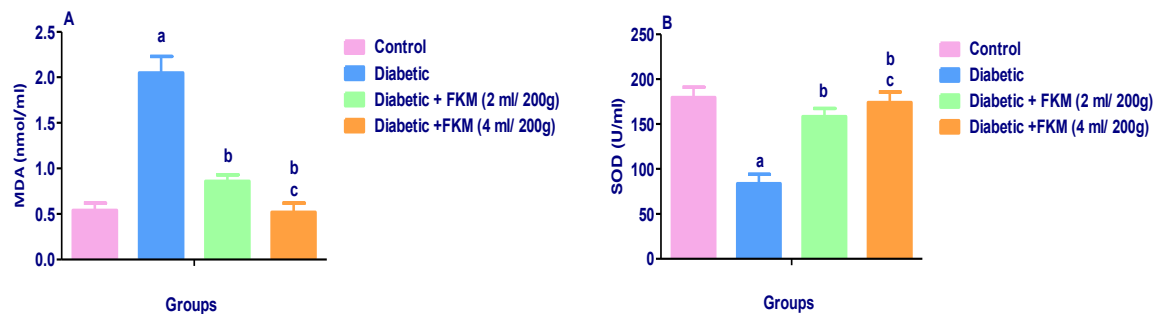


Fig. 2. Influence of FKM on serum oxidative stress indices contents in diabetic rats. Results illustrated as mean  $\pm$  SD (n = 10). A: MDA; B: SOD. <sup>a</sup>Significant versus control. <sup>b</sup>Significant versus diabetic group. <sup>c</sup>Significant diabetic + FKM (2 ml/200 g) group versus diabetic + FKM (4 ml/200 g) group. ( $p \leq 0.05$ )

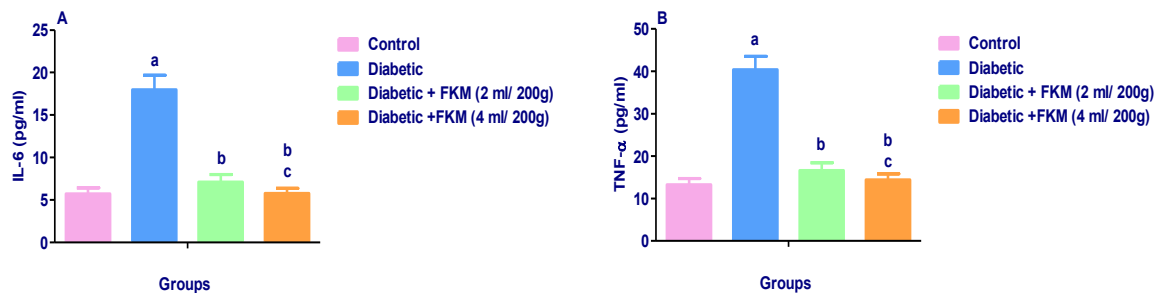
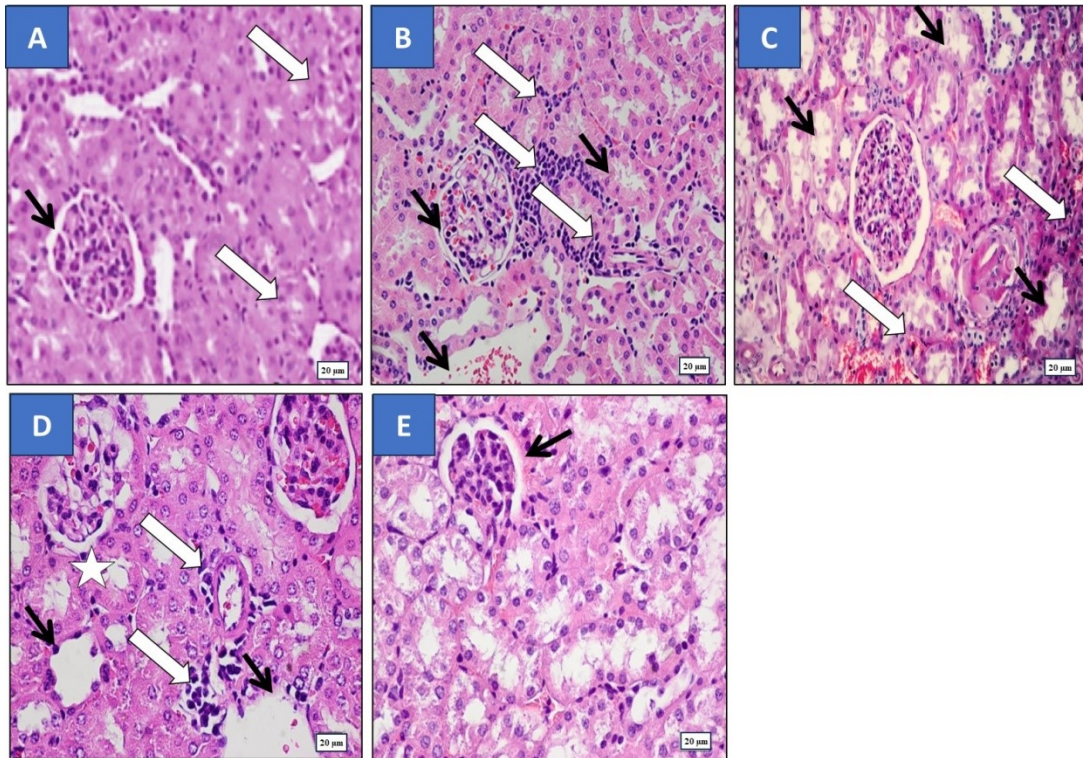


Fig. 3. Influence of FKM on serum anti-inflammatory cytokines indices levels in diabetic rats. Results illustrated as mean  $\pm$  SD (n = 10). A: IL-6; B: TNF- $\alpha$ . <sup>a</sup>Significant versus control. <sup>b</sup>Significant versus diabetic group. <sup>c</sup>Significant diabetic + FKM (2 ml/200 g) group versus diabetic + FKM (4 ml/200 g) group ( $p \leq 0.05$ ).



**Fig. 4.** Influence of FKM on renal histopathological changes (bar =20 µm, H&E staining). Control rats showed normal glomerular capillaries and renal corpuscle (white arrows). Renal medullary tubules and cortical showed normal lining epithelium and narrow lumina (black arrow) (Fig. A). In diabetic rats' renal sections showing marked decline in glomerular size and renal corpuscle (white arrows), marked disorganization of renal parenchyma with deformity and atrophy of renal corpuscle, and dilation of tubular lumina (black arrows) (Figs. B & C). Diabetic rats received FKM (2 ml/ 200g) showing mild decline in glomerular size and renal corpuscle (white arrows) and dilation of tubular lumina (black arrows), mild disorganization of renal parenchyma with deformity and atrophy of renal corpuscle (Fig. D). Diabetic rats received FKM (4 ml/ 200 g) showing observed protection of renal parenchyma structure, slight distortion of some renal corpuscles, renal tubules showed healthy lining epithelium comparable to that of control (black arrow) (Fig. E).

## References

- Shaw, J.E., Sicree, R.A. and Zimmet, P.Z. Global estimates of the prevalence of diabetes for 2010 and 2030. *Diabetes Res. Clin. Pract.*, **87**(1),4–14 (2010).
- Nasiry, D., Khalatbary, A.R., Ahmadvand, H., Amiri, F.T. and Akbari, E. Protective effects of methanolic extract of *Juglans regia* L. leaf on streptozotocin-induced diabetic peripheral neuropathy in rats. *BMC Complement Altern. Med.*, **17** (1), 476 (2017), doi: 10.1186/s12906-017-1983-x
- Saran, R., Robinson, B., Abbott, K.C, Bragg-Gresham, J., Chen, X., Gipson, D., Gu, H., Hirth, R.A., Hutton, D., Jin, Y., Kapke, A., Kurtz, V., Li, Y., McCullough, K., Modi, Z., Morgenstern, H., Mukhopadhyay, P., Pearson, J., Pisoni, R., Repeck, K., Schaubel, D.E., Shamraj, R., Steffick, D., Turf, M., Woodside, K.J., Xiang, J., Yin, M., Zhang, X. and Shahinian, V. US renal data system 2019 annual data report: epidemiology of kidney disease in the United States. *Am. J. Kidney Dis.*, **75**, A6–A7 (2020), doi: 10.1053/j.ajkd.2019.09.003
- El-Kady, M.M., Naggar, R.A., Guimei, M., Talaat, I.M., Shaker, O.G. and Saber-Ayad, M. Early renoprotective effect of ruxolitinib in a rat model of diabetic nephropathy. *Pharmaceuticals*, **14** (7), 608 (2021), doi: 10.3390/ph14070608
- Osadebe, P.O., Odoh, E.U. and Uzor, P.F. Natural products as potential sources of antidiabetic drugs. *British J. Pharmaceutical*, **4**(17), 2075–95, (2014). doi: 10.9734/BJPR/2014/8382
- Belizário, J.E. and Faintuch, J. Microbiome and gut dysbiosis. *Exp. Suppl.*, **109**,459–476 (2018), doi: 10.1007/978-3-319-74932-7\_13
- Baothman, O.A., Zamzami, M.A., Taher, I., Abubaker, J. and Abu-Farha, M. The role of gut microbiota in the development of obesity and diabetes. *Lipids Health Dis.*, **15**(1),108(2016), doi: 10.1186/s12944-016-0278-4
- Federico, A., Dallio, M., DI Sarno, R., Giorgio, V. and Miele, L. Gut microbiota, obesity, and metabolic disorders. *Minerva Gastroenterol Dietol.*, **63**(4), 337–344 (2017).
- Satir, G. and Guzel-seydim Z.B. Influence of kefir fermentation on the bioactive substances of different

- breed goat milks. *LWT-Food Sci. Technol*, **63** (2),852–8 (2015), doi: 10.1016/j.lwt.2015.04.057
10. Fiorda, F. A., Pereira, G. V. Thomaz-Soccol, V., Rakshit, S. K., Pagnoncelli, M. G., Vandenberghe, L. P. and de S Soccol, C.R. Microbiological, biochemical, and functional aspects of sugary kefir fermentation - A review. *Food Microbiol*, **66**, 86–95 (2017), doi: 10.1016/j.fm.2017.04.004
  11. Mert, H., Yılmaz, H., Irak K., Yıldırım, S. and Mert, N. Investigation of the protective effect of kefir against isoproterenol induced myocardial infarction in rats. *Korean J. Food Sci. Anim. Resour.*, **38**(2), 259–72(2018). doi: 10.5851/kosfa.2018.38.2.259
  12. Uchida, M., Ishii, I., Inoue, C., Akisato, Y., Watanabe, K., Hosoyama, S., Toida, T., Ariyoshi, N. and Kitada, M. Kefiran reduces atherosclerosis in rabbits fed a high cholesterol diet. *J. Atheroscler Thromb.*, **17**(9), 980–8(2010), doi: 10.5551/jat.4812
  13. Prado, M.R., Blandón, L.M., Vandenberghe, L.P., Rodrigues, C., Castro, G.R., Thomaz-Soccol, V. and Soccol, C.R. Milk kefir: Composition, microbial cultures, biological activities, and related products. *Front. Microbiol.*, **6**, 1177(2015), doi: 10.3389/fmicb.2015.01177
  14. Jасcolka, T.L., Aguilar, E.C., Teixeira, L.G., Lages, P.C, Raimundo, I.C., Beltráo, N.R.M., Matoso, R.O., Carneiro, R.P., Nicoli, J.R. and AlvarezLeite, J.I. Kefir supplementation improves lipid profile and oxidative stress but does not reduce atherosclerotic lesion in apoE deficient mice. *J. Food Nutr. Disor.*, **2**(3), 1000113 (2013), doi:10.4172/2324-9323.1000113
  15. Nalbantoglu, U., Cakar, A., Dogan, H., Abaci, N., Ustek, D., Sayood, K. and Can, H. Metagenomic analysis of the microbial community in kefir grains. *Food Microbiol.*, **41**,42–51(2014), doi: 10.1016/j.fm.2014.01.014
  16. Nurliyani, Eni, H. and Sunarti. Antidiabetic potential of kefir combination from goat milk and soy milk in rats induced with streptozotocin-nicotinamide. *Korean J. Food Sci. Anim. Resour.*, **35** (6), 847–858(2015), doi: 10.5851/kosfa.2015.35.6.847
  17. Furman, B.L. Streptozotocin-induced diabetic models in mice and rats. *Curr. Protoc. Pharmacol.*, **70**, (5),47–47 (2015). doi: 10.1002/0471141755.ph0547s70
  18. Ostadrahimi, A., Taghizadeh, A., Mobasseri, M., Farrin, N., Payahoo, L., Beyramalipoor Gheshlaghi, Z. and Vahedjabbari, M. Effect of probiotic fermented milk (kefir) on glycemic control and lipid profile in type 2 diabetic patients: a randomized double-blind placebo-controlled clinical trial. *Iran. J. Public Health*, **44**(2), 228–237(2015).
  19. Rosa, D.D., Grześkowiak, L.M., Ferreira, C.L.L.F, Fonseca, A.M., Reis, S.A., Dias, M.M., Siqueira, N.P., Silva, L.L., Neves, C.A., Oliveira, L.L., MacHado, A.B.F. and Peluzio, M.G. Kefir reduces insulin resistance and inflammatory cytokine expression in an animal model of metabolic syndrome. *Food Function*, **7** (8), 3390–3401(2016), doi: 10.1039/c6fo00339g
  20. Cabello-Olmo, M., Oneca, M., Torre, P., Sainz, N., Moreno-Aliaga, M.J., Guruceaga, E., Díaz, J., Encio, I., Barajas, M. and Araña, M. A fermented food product containing lactic acid bacteria protects ZDF rats from the development of type 2 diabetes. *Nutrients*, **11**(10), 2530(2019). doi: 10.3390/nu11102530
  21. Tiss, M., Souiy, Z., Abdeljelil, N., Njima, M., Achour, L. and Hamden, K. Fermented soy milk prepared using kefir grains prevents and ameliorates obesity, type 2 diabetes, hyperlipidemia and liver-kidney toxicities in HFFD-rats. *J. Functional Foods*, **67**, 103869 (2020), doi: 10.1016/j.jff.2020.103869
  22. Salari, A., Ghodrat, S., Gheflati, A., Jarahi, L., Hashemi, M. and Afshari, A. Effect of kefir beverage consumption on glycemic control: A systematic review and meta-analysis of randomized controlled clinical trials. *Compl Therapies in Clin. Pract.*, **44**, 101443(2021), doi: 10.1016/j.ctcp.2021.101443
  23. Hadisaputro, S., Djokomoeljanto, R.R. and Soesatyo, M.H.N.E. The effects of oral plain kefir supplementation on proinflammatory cytokine properties of the hyperglycemia Wistar rats induced by streptozotocin. *Acta Medica Indonesiana*, **44**(2), 100–104(2012).
  24. Carasi, P., Racedo, S.M., Jacquot, C., Romanin, D.E., Serradell, M.A. and Urdacim, M.C. Impact of kefir derived lactobacillus kefiri on the mucosal immune response and gut microbiota. *J. Immunol. Res.*, **2015**, 361604(2015), doi: 10.1155/2015/361604
  25. Bellikci-Koyu, E., Sarer-Yurekli, B., Akyon, Y., Aydin-Kose, F., Karagozlu, C., Ozgen, A., Brinkmann, A., Nitsche, A., Ergunay, K., Yilmaz, E. and Buyuktuncer, Z. Effects of regular kefir consumption on gut microbiota in patients with metabolic syndrome: a parallel-group, randomized, controlled study. *Nutrients*, **11**(9), 2089(2019), doi: 10.3390/nu11092089
  26. Tsalamandris, S., Antonopoulos, A.S., Oikonomou, E., Papamikroulis, G.A., Vogiatzi, G., Papaioannou, S., Deftereos, S. and Tousoulis, D. The role of inflammation in diabetes: Current concepts and future perspectives. *Euro. Cardiol. Rev.*, **14**(1), 50–9(2019). doi: 10.15420/ecr.2018.33.1
  27. Strowski, M.Z. and Wiedenmann, B. Probiotic carbohydrates reduce intestinal permeability and inflammation in metabolic diseases. *Gut*, **58**(8), 1044–1049(2009). DOI: 10.1136/gut.2009.179325
  28. Bourrie, B.C.T., Willing, B.P. and Cotter, P.D. The microbiota and health promoting characteristics of the fermented beverage kefir. *Front. Microbiol.*, **7**, 647 (2016). doi: 10.3389/fmicb.2016.00647
  29. Teruya, K., Yamashita, M., Tominaga, R., Nagira, T., Shim, S., Katakura, Y., Tokumaru, S., Tokumaru, K., Barnes, D. and Shirahata, S. Fermented milk, Kefram-Kefir enhances glucose uptake into insulin-responsive muscle cells. *Cytotechnol.*, **40**, 107–116(2002).
  30. Kahraman, M., Ertekin, Y. and Satman, I. The effects of kefir on kidney tissues and functions in diabetic rats. *Probiotics Antimicrob Prot.*, **13**(2), 375–382(2021). doi: 10.1007/s12602-020-09698-9
  31. Sunarti, S., Nurliyani, N., Tyas, A. and Kristian, S. The influence of goat milk and soybean milk kefir on IL-6 and CRP levels in diabetic rats. *Romanian J. Diabetes Nutri. Metabol. Dis.*, **22**(3), 261–267(2015).

32. Senol, A., Isler, M., Sutcu, R., Akin, M., Cakir, E., Ceyhan, B.M. and Kockar, M.C. Kefir treatment ameliorates dextran sulfate sodium-induced colitis in rats. *World J. Gastroenterol.*, **21**(46), 13020–13029(2015). doi: 10.3748/wjg.v21.i46.13020
33. Bellikci-Koyu, E., Sarer-Yurekli, B., Karagozlu, C., Aydin-Kose, F., Ozgen, A. and Buyuktuncer, Z. Probiotic kefir consumption improves serum apolipoprotein A1 levels in metabolic syndrome patients: a randomized controlled clinical trial. *Nutri. Res.*, **102**, 59–70(2022). doi: 10.1016/j.nutres.2022.02.006
34. Cakatay, U., Telci, A., Salman, S., Satman L. and Sivas, A. Oxidative protein damage in type I diabetic patients with and without complications. *Endocr. Res.*, **26**(3), 365–79(2000). doi: 10.3109/07435800009066174
35. Kayali, R., Telci, A., Cakatay, U., Karaca, C., Akcay, T., Sivas, A. and Altug, T. Oxidative protein damage parameters in plasma in chronic experimental diabetes in rats. *Eur. J. Med Res.*, **8**(7), 307–312(2003).
36. Punaro, G.R., Maciel, F.R., Rodrigues, A.M., Rogero, M.M., Bogsan, C.S.B., Oliveira, M.N., Ihara, S.S.M., Araujo, S.R.R., Sanches, T.R.C., Andrade, L.C. and Higa, E.M.S. Kefir administration reduced progression of renal injury in STZ-diabetic rats by lowering oxidative stress. *Nitric Oxide*, **37**, 53–60(2014), doi: 10.1016/j.niox.2013.12.012
37. Yadav, H., Jain, S. and Sinha, P.R. Oral administration of dahi containing probiotic *Lactobacillus acidophilus* and *Lactobacillus casei* delayed the progression of streptozotocin-induced diabetes in rats. *J. Dairy Res.*, **75**(2), 189–195 (2008). doi: 10.1017/S0022029908003129
38. Chen, Y., Chen, H., Fan, H., Tung, Y., Kuo, C., Tu, M. and Chen, C. Anti-inflammatory, antioxidant, and antifibrotic effects of kefir peptides on salt-induced renal vascular damage and dysfunction in aged stroke-prone spontaneously hypertensive rats. *Antioxidants*, **9**(9), 790(2020).doi: 10.3390/antiox9090790

## التأثير الوقائي للكلبي للبن الكفير المُخمر في الجرذان المصابة بداء السكري من النوع الأول: المسار المضاد للأكسدة والمضاد للالتهابات

فاطمة محمد علي يوسف

قسم الغذاء والتغذية - كلية العلوم الإنسانية والتصاميم - جامعة الملك عبد العزيز - جدة - المملكة العربية السعودية.

### الملخص

مع تزايد انتشار مرض السكري على مستوى العالم، بما في ذلك في المملكة العربية السعودية، يركز الباحثون على الأطعمة الغنية بالبروبيوتيك مثل لبن الكفير المخمر كوسيلة لمنع المضاعفات المرتبطة بالمرض. يتمتع لبن الكفير بخصائص متعددة مثل تأثيره المضاد للأكسدة والالتهابات وقدرته على تعزيز المناعة، مما يجعله مفيداً للرعاية الصحية الوقائية. يهدف هذا البحث إلى دراسة تأثير لبن الكفير على مؤشرات الإجهاد التأكسدي والالتهابات في الجرذان المصابة بالسكري، مع تقييم تأثيره الوقائي المُحتمل على الكلبي. تم تقسيم أربعين جرّداً ذكراً إلى أربع مجموعات: (1) مجموعة ضابطة، (2) مجموعة مصابة بالسكري، و(3 و4) مجموعات مصابة بالسكري ومعالجة بجرعة 2 مل أو 4 مل من لبن الكفير لكل 200 جم من وزن الجسم يومياً لمدة 35 يوماً. أظهرت النتائج أن تناول لبن الكفير أسفر عن تأثيرات فعالة في خفض مستويات السكر في الدم وحماية الكلبي، حيث لوحظ انخفاض كبير في مستويات الجلوكوز، اليوريا، حمض البوليك، والكرياتينين في مصل الدم. كما زاد مستوى الأنسولين في الدم بشكل ملحوظ، مما يشير إلى تحسن في التحكم في سكر الدم. بالإضافة إلى ذلك، لوحظ تثبيط في الاستجابة الالتهابية من خلال انخفاض تركيزات عامل نخر الورم ألفا والإنترلوكين-6. وأظهر لبن الكفير انخفاضاً ملحوظاً في الدهون المؤكسدة، وهي مؤشر على الإجهاد التأكسدي، وزيادة في نشاط إنزيم السوبر أوكسيد ديسموتيز المضاد للأكسدة. كذلك، أظهر لبن الكفير وقاية من التغيرات النسيجية المرضية التي يسببها السكري في الكلبي، وكانت التأثيرات الأكثر وضوحاً في المجموعة التي تلقت الجرعة الأكبر من لبن الكفير. خلصت الدراسة إلى أن لبن الكفير يلعب دوراً محتملاً في تعديل مسارات متعددة مرتبطة باعتلال الكلبي السكري.

**الكلمات المفتاحية:** لبن الكفير المتخمّر، اعتلال الكلبي السكري، مضادات الأكسدة، مضادات الالتهابات، الهستوباثولوجي.