

# Diagnostic analysis of pulmonary nodules using Multi-Slice Computed Tomography (MSCT) chest in breast cancer patients

<sup>1</sup>Mona A. F. Hafez\*, <sup>2</sup>Ahmed Mahmoud, <sup>3</sup>Ekram Mahmoud, <sup>4</sup>Ola M. M. Shetat

<sup>1</sup>Cairo University, Faculty of medicine; Associate Professor at Diagnostic Radiology and Intervention Department, and Consultant Radiologist at Baheya Centre for the Early Detection and Treatment of Women's Cancer, Egypt

<sup>2</sup>Baheya Centre for the Early Detection and Treatment of Women's Cancer; Specialist at Radiology Department, Giza, Egypt

<sup>3</sup>National Cancer Institute; Professor at Radiology Department, Cairo University

<sup>4</sup>National Cancer Institute; Lecturer at Radiology Department, Cairo University

## ABSTRACT

Correspondence to  
**Mona Ahmed Fouad Hafez**  
 Cairo University, Faculty of  
 medicine; Associate professor at  
 Diagnostic Radiology and  
 intervention Department, and  
 consultant Radiologist at Baheya  
 Centre for the Early Detection and  
 Treatment of Women's Cancer;  
 address: El Saray Street, Manial,  
 Cairo, Egypt;  
 Tel.: +201006856286;  
 e-mail address:  
[mona.fouad@kasralainy.edu.eg](mailto:mona.fouad@kasralainy.edu.eg)

**Kasr Al Ainy Medical Journal**  
 2023, 29:5–14

**Background:** The aim of the study is the evaluation of pulmonary nodules seen at multi-slice CT (MSCT) chest in known patients with breast cancer and follow-ups aiming to provide basic features for indeterminate and suspicious pulmonary nodules, evaluating pulmonary nodules assist in assessing the probability that these nodules are indicative of metastasis. **Methods:** Prospective analysis of 107 female patients, who were known with breast cancer. MSCT chest was done for all cases. Pulmonary nodules were assessed in date and categorized as indeterminate and suspicious nodules, and then after 2 years of follow-up according to nodule behavior and/ or positron emission tomography (PET) CT, they are categorized as benign and malignant nodules. **Results:** Nodule size, multiplicity, density, shape, and behavior, there was a strong association with the type of nodule, as indicated by a P-value of less than 0.001. The cut-off size and density of pulmonary nodules were 6.5 mm and -99.5 HU respectively with high specificity in differentiating malignant from benign nodules. **Conclusions:** A multi-slice CT chest is imperative in the diagnosis of pulmonary nodules in cases of breast cancer. Nodule characteristics and behavior are important parameters for the provisional diagnosis, whether benign or malignant.

**Keywords:** Breast cancer, Multi-slice computed tomography (MSCT), Pulmonary nodules, Nodule multiplicity, Nodule density

## INTRODUCTION

The lung is the second common site for breast cancer metastases. Pulmonary metastasis are often detected as incidental findings in radiographic studies. Early detection of lung metastases is crucial for establishing an effective treatment plan [1].

Pulmonary metastases are mostly displayed in variable sizes and shapes, solitary or multiple nodules, lymphangitic, intrabronchial, or air space metastasis [2]. Single or multiple pulmonary nodules are detected on many CT scans; yet, most of these nodules are benign. Indeterminate pulmonary nodules were observed in CT scans with no evidence of other metastasis. However, there is no agreement on whether these patients should be treated as if they have early-stage breast cancer, with curative treatments, or as if they have metastatic cancer, which does not use curative treatments [3, 4]. So the likelihood of these nodules being of a metastatic origin is uncertain in individual cases [5].

Benign causes of nodules as infective causes such as atypical pneumonia, tuberculosis, atypical mycobacterial infection, and chicken-pox old scarring; non-infective causes may include rheumatoid nodules,

granulomata, and broncho-alveolar atypical hyperplasia [6], and also post-radiation pneumonitis could produce anterior reticulonodular lesions at radiation port [7].

MSCT is the diagnostic technique of choice and a very helpful imaging tool to reach the diagnosis and exclude any associated findings [8].

Management guidelines for lung nodules identified through routine CT scans in clinical practice have been proposed, but these guidelines do not apply to patients with pre-existing cancers, such as breast cancer [9]. No other guidelines developed for metastatic breast cancer nodules, and almost need to progress in it.

Our objective was to assess the efficacy of analyzing pulmonary nodules observed on multislice computed tomography (MSCT) of the chest in patients with a known diagnosis of breast cancer. This involved evaluating the fundamental characteristics of these nodules on chest CT scans and follow-ups, with the aim of providing essential features for indeterminate and suspicious pulmonary nodules in breast cancer patients. This analysis is intended to aid in determining the likelihood that these nodules represent metastatic disease.

## METHODS

This prospective study involved female cases over the period of two years from April 2018 to March 2020 with known breast cancer referred for cancer staging or coming complaining of chest symptoms.

They were referred from the outpatient clinic of Baheya Center for the Early Detection and Treatment of Women's Cancer, to perform CT of the chest.

The patients included in the study had been diagnosed with breast cancer, underwent MSCT chest scans that revealed pulmonary nodules, and then underwent multiple CT chest scans over a period of two years.

This study excluded patients with primary malignancies other than breast cancer or those who had lost follow-up.

This study was carried out with approval from the institutional review board, adhering to our ethical committee's guidelines. All participants provided informed written consent.

### All patients underwent:

- Medical history assessment and physical examination.
- After sono-mammographic breast evaluation and staging with CT chest, abdomen, and pelvis as well as a bone scan, advanced cancer stages were identified, such as large tumours (T4), pathological lymph nodes (N2), and/or distant metastases.
- MSCT chest was done to all patients in the radiology department at Baheya Center for the Early Detection and Treatment of Women's Cancer, using Siemens Scope, Germany (CTAWP92544) MSCT 16 Channels.
- No preparation required. Helical-volumetric axial cuts without contrast performed in full inspiration in supine position with 1.5 mm slice thickness, 1.5 mm pitch, 0 gantry tilt, FOV around 320 mm from the neck root to renal arteries, KV 120, mAs 25, Rotation time 0.5 s, total exposure time 8–10 s.
- All volumetric CT chest assessed at lung window WW 1500 WL -500, and mediastinal window WW 300, WL 30 (WW refers to window width, while WL refers to window level).
- Reconstructed two-dimensional axial, coronal and sagittal images, and three-dimensional MIP (maximum intensity projection) images were assessed.
- We evaluated the largest pulmonary nodule using GE Healthcare's lung analysis software (Lung VCAR; Advantage Workstation). The lung nodules were selected and segmented manually. Semiautomatic region of interest (ROI) selection was performed to cover the largest possible area of each nodule and exclude large vessels and pulmonary arteries. Every contiguous transverse level was covered in this manner. Based on the lesion segmentation, voxel-based CT numbers were generated.

### Data Analysis:

- Two radiologists; of 16 and 9 years of experience in chest imaging; reviewed the CT chest images along with the clinical data, the previous radiology reports (including the mammography, breast ultrasound, CT abdomen and pelvis, bone scan), and histopathological reports. Results confirmed by the two radiologists in consensus with each other.
- The following parameters of the dominant nodule were assessed:
  - Nodule **location**: central versus peripheral versus sub-pleural, and sub-fissural.
  - The **size** of the dominant nodule was measured manually as the average of the short-axis and the long-axis diameters in one CT section.
  - Nodule **number** (solitary, few less than 5 nodules and multiple).
  - Nodule **shape** (regular “rounded, or oval” versus irregular “speculated, or stellate, or angulated” versus lobulated”).
  - Nodule **margin** (well-defined versus ill-defined)
  - Mean, minimum, and maximum **density**, and **histogram** of the dominant nodule was measured: based on the mean attenuation of the total voxels and volume, the computer computed the density by multiplying each voxel's unit volume by the number of voxels. Attenuation measurements were performed in the lung window by placing a region of interest (ROI) over a nodule, which included the central and most solid portion of the nodule after excluding cystic areas, blood vessels, calcium and fat detected in the mediastinal window.
  - The **nature** of the nodule was determined (solid, part-solid, ground glass).
  - The presence of **extrapulmonary metastasis** was determined.
  - The site and nature of **breast cancer** were assessed.
- Suspicious versus indeterminate nodules suggested according to the Fleischner Society pulmonary nodule guidelines [10], nodule parameters and morphological features. Small size nodule < 8 mm, single or few, with smooth margin, regular shape, and with no associated extra-pulmonary metastasis suggested to be indeterminate. Other than these features suggested to be suspicious.
- The final diagnosis as metastatic versus benign nodules concluded mainly according to the behavior of the pulmonary nodules assessed in all cases after follow-up for 2 years either stationary, progressive and regressive, and PET CT was done to the cases with pulmonary nodules more than 1 cm in diameter. As most of the nodules are small to be biopsied and the biopsy of the pulmonary nodule is not in the management protocol of the hospital. Based on nodule behavior, benign nodules are concluded in cases with stationary course, or short-

term regression in inflammation, and metastatic nodules are concluded in cases with progression or regression after chemotherapy.

- Statistical analysis: Data were coded and entered using Statistical Package for the Social Sciences version 28 (IBM Corp., Armonk, NY, USA). Data were summarized using mean, standard deviation, median, minimum, and maximum in quantitative data and using frequency (count) and relative frequency (percentage) for categorical data. We used the 95% CI (confidence interval) area under the ROC curve (receiver operating characteristic) to evaluate the AUC (area under the curve) of the dominant pulmonary nodule, and then standard diagnostic indices, including sensitivity and specificity were calculated. The Chi-square ( $\chi^2$ ) test was performed to compare categorical data. The exact test was used when the expected frequency was  $<5$ . P-values of  $<0.05$  was considered statistically significant and  $<0.001$  was considered highly significant.

## RESULTS

This study involved 107 patients, all of whom were females, with breast cancer and pulmonary nodules.

Demographic features: the age of patients, under the study, ranged from 27 up to 80 years old; with mean age of 56.15 (S.D.  $\pm 11.99$ ). No significant difference in mean age between patients included with the final diagnosis of malignant or benign nodules with p-value of 0.448. The mean age for benign nodules was 55.35 (S.D.  $\pm 11$ ) and the mean age for malignant nodules was 56.96 (S.D.  $\pm 12$ ).

According mainly to pulmonary nodules behaviour after two years, the final diagnosis of benign nodules was in 49.5% of cases and neoplastic nodules was in 50.5% of cases. The final diagnosis to the pulmonary nodules primary diagnosis, and primary breast cancer characters was displayed in **Table 1**. There was a highly statistically significant relation (p-value  $<0.001$ ) between the primary diagnosis of lung nodules either (suspicious or indeterminate) and the final diagnosis either malignant or benign. Also, cases with extrapulmonary metastasis (e.g., bone, liver) had a significant correlation with malignant pulmonary nodules (p-Value = 0.041).

**Table 1:** The final diagnosis of lung nodules in relation to their primary diagnosis, number, and primary breast cancer characters

		Final Diagnosis				P-value
		Malignant		Benign		
		Count	%	Count	%	
Primary Diagnosis	Suspicious	49	90.7%	10	18.9%	<b>&lt; 0.001**</b>
	Indeterminate	5	9.3%	43	81.1%	
Cancer staging	Early	16	29.6%	20	37.7%	0.375
	Advanced	38	70.4%	33	62.3%	
Site of Cancer	Right	22	40.7%	25	47.2%	0.248
	Left	32	59.3%	26	49.1%	
	Bilateral	0	0.0%	2	3.8%	
Extrapulmonary metastasis	Yes	37	68.5%	26	49.1%	<b>0.041*</b>
	No	17	31.5%	27	50.9%	

p-value  $>0.05$  NS; \*p-value  $<0.05$  S; \*\*p-value  $<0.001$  HS

### Nodule multiplicity and its relation to nodule size:

According to this study, there was a significant positive relationship between the number of nodules in the CT chest and increasing their susceptibility to be malignant.

25 patients had solitary nodules (23.4 %) and 82 patients who had few or multiple nodules (76.6 %) in

the CT scan. A smaller number of nodules was associated with a reduced likelihood of malignancy. Multiple nodules have a significant (p-value  $< 0.001$ ) higher probability of being malignant nodules.

Size was calculated and tabulated in association with multiplicity (**Table 2**). Size ranged from 2 mm up to 40 mm with a mean size of 8.56 mm (SD  $\pm 7.18$ ).

**Table 2:** Multiplicity of pulmonary nodules associated with the size of the largest nodule in breast cancer patients to the final diagnosis:

	Size	Total	Malignant	Benign	%of malignant
Single	2-4 mm	12	2	10	16.7%
	5-9 mm	10	2	8	20.0%
	10-49 mm	3	1	2	33.3%
	Total	25	5	20	20%
Few	2-4 mm	10	2	8	20.0%
	5-9 mm	35	15	20	42.9%
	10-49 mm	11	10	1	90.9%
	Total	56	27	29	48.2%
Multiple	2-4 mm	2	1	1	50.0%
	5-9 mm	13	10	3	76.9%
	10-49 mm	11	11	0	100.0%
	Total	26	22	4	84.6%
<b>Total single</b>		25	5	20	20.0%
<b>Total multiple</b>		82	49	33	59.8%
<b>Total</b>		107	54	53	50.5%

**Nodule size and density and their relation to the final diagnosis:**

There was a statistically significant relation between nodule size and the final diagnosis. The mean size in cases of malignant nodules was 11.44 mm, but the mean size of benign nodules was 5.63 mm (P-value < 0.001).

Regarding the density, the mean density of the nodules was measured as well as the maximum and

minimum densities (Histogram). The mean density of malignant lung nodules was (-91.52 HU) but in cases of benign nodules, it was (-247.13 HU). There was a significant relation between mean density and the type of nodule. In contrast to that, minimum density had no significant relation (**Table 3**).

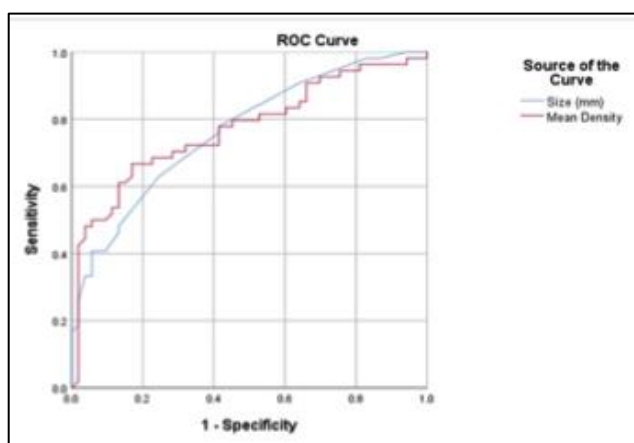
**Table 3:** Relation of nodules size and radiological density with the final diagnosis

	Final Diagnosis										P-value
	Malignant					Benign					
	Mean	SD	Median	Mini.	Maxi.	Mean	SD	Median	Mini.	Maxi.	
Size (mm)	11.44	8.86	7.00	3.00	40.00	5.63	2.78	5.00	2.00	18.00	<0.001**
Mean Density (HU)	-91.52	171.51	-41.00	-682.00	98.00	-247.13	166.39	-220.00	-628.00	98.00	<0.001**
Min (HU)	-476.20	269.11	-515.50	-904.00	25.00	-557.83	198.00	-606.00	-918.00	65.00	0.235
Max (HU)	-16.06	179.24	59.50	-739.00	160.00	-147.58	201.01	-96.00	-620.00	113.00	<0.001**

p-value >0.05 NS; \*p-value <0.05 S; \*\*p-value <0.001 HS

The cut-off levels regarding size and mean density of nodule were calculated to detect its type (CI =95 %) using the ROC Curve (**Figure 1**). The nodule size cut-off was 6.5 mm with sensitivity and specificity of 63%

and 75% respectively. The mean density cut-off level was (-99.5 HU) with sensitivity and specificity of 67% and 83 % respectively in differentiating malignant from benign (**Table 4**).



**Figure 1:** ROC curve for detection of malignancy using the size and mean density

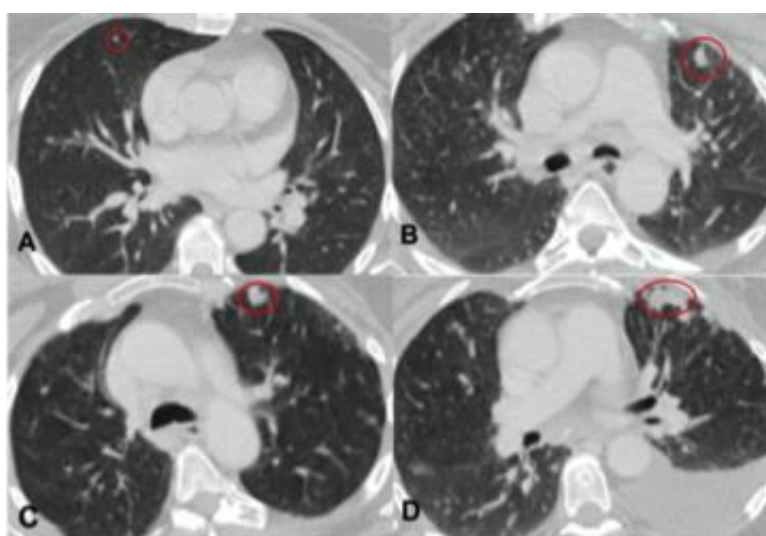
**Table (4):** Cut off levels of size and mean density with their sensitivity and specificity.

	Area Under the Curve	P-value	95% Confidence Interval		Cut off	Sensitivity %	Specificity %
			Lower Bound	Upper Bound			
Size (mm)	0.765	< 0.001	0.677	0.854	6.5	63	75.5
Mean Density (HU)	0.772	< 0.001	0.681	0.862	-99.5	66.7	83

**Relation of nodule location, shape, and margin to the final diagnosis:**

The shape of lung nodules is highly significantly related to the final diagnosis (p-value <0.001). Also,

nodules with ill-defined margins had a higher probability to be malignant (p-value <0.05), (Figure 2). However, nodule locations had no significance to the final diagnosis (Table 5).



**Figure 2:** A 50-year-old woman with a history of left breast cancer treated with modified radical mastectomy (MRM) and radiotherapy. A) Based CT scan (lung window) was done for metastatic work-up of the patient, showing few peripheral pulmonary nodules, the illustrated the dominant one is seen right sided based on the transverse fissure, showing partially solid nature. B & C) follow-up CT scans (lung window) were done after 6 and 12 months respectively showing the progressive course with the newly developed dominant nodule is seen at left sided anterior segment UL. D) The final 2 years follow-up CT scan (lung window) for the same patient, showed progressive course as regards the number, size and density of the previously noted pulmonary nodules, the illustrated dominant one was seen at the anterior segment of the left upper lobe, showing solid nature. Diagnosed as metastatic nodules.

**Table (5):** Relation between nodule characters in CT scan regarding (location, shape, and margin) with the final diagnosis

		Final Diagnosis				P-value
		Malignant		Benign		
		Count	%	Count	%	
Location	Central	2	3.7%	4	7.5%	0.335
	Peripheral	24	44.4%	29	54.7%	
	Subpleural, Subfissural	28	51.9%	20	37.7%	
Shape	Regular	23	42.6%	43	81.1%	< 0.001**
	Lobulated	12	22.2%	5	9.4%	
	Irregular	19	35.2%	5	9.4%	
Margins	Well-defined	26	48.1%	41	77.4%	0.002*
	Ill-defined	28	51.9%	12	22.6%	
Nature	Solid	14	25.9%	5	9.4%	0.007*
	Part-solid	36	66.7%	34	64.2%	
	GG	4	7.4%	14	26.4%	

p-value >0.05 NS; \*p-value <0.05 S; \*\*p-value <0.001 HS

Regarding radiological nature, ground glass (GG) appearance was more related to benign nodules but solid ones are more to be malignant ( $p$ -value < 0.007), (Figure 3).

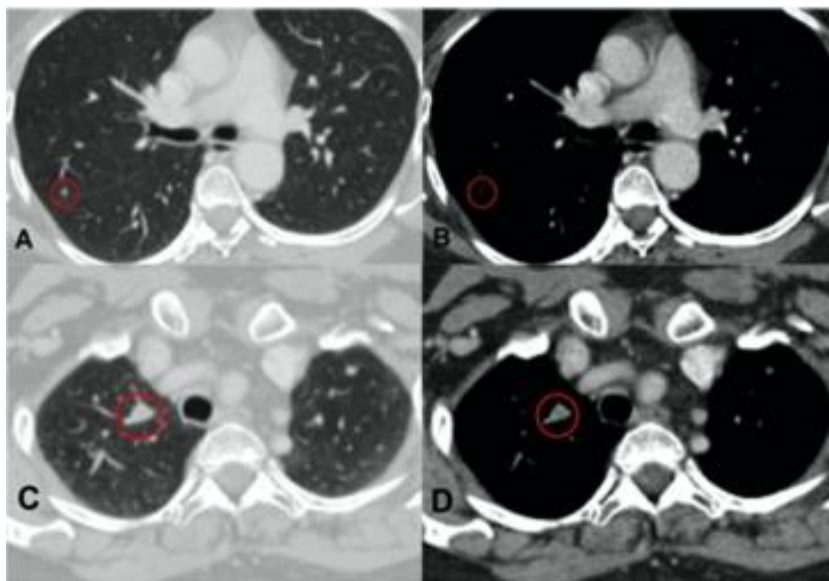
**Behavior and nature of the nodules and their relation to the final diagnosis:**

The behaviour of the nodules was traced for two years. The progressive behaviour was significantly associated with malignant nodules ( $p$ -value < 0.001) (Figure 4, 5). There was intermediate sensitivity, high

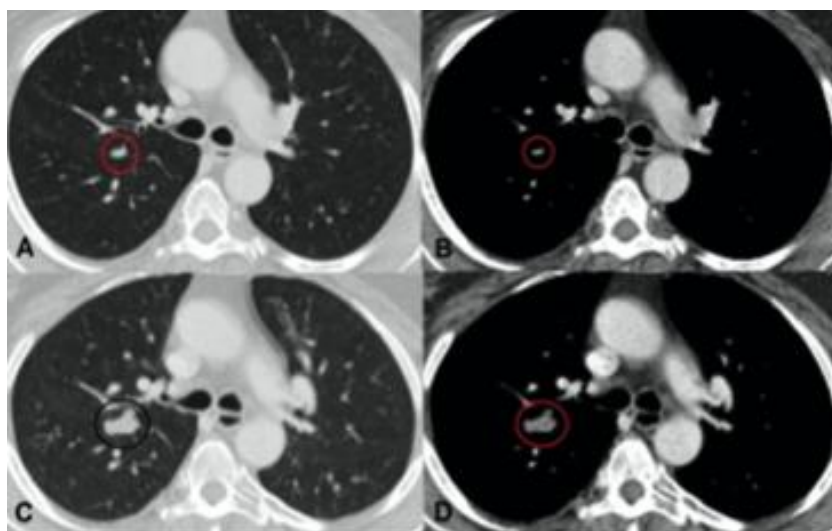
specificity, and accuracy of nodule behaviour (66.7 %, 100%, and 83.2% respectively) to the final nodule diagnosis either malignant or benign.

**Accuracy of MSCT in primary diagnosis of the nature of pulmonary nodules:**

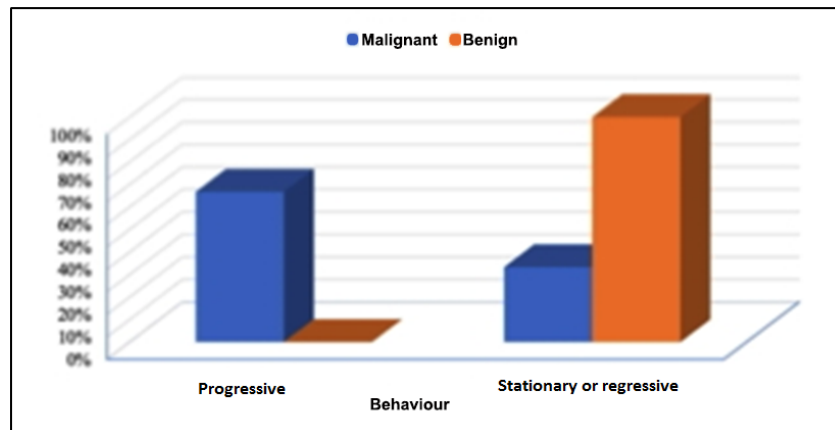
Sensitivity, specificity, and accuracy for the initial MSCT diagnosis of the nodule were calculated in comparison to the final diagnosis; they were (90.74%, 81.13%, and 85.98%) respectively.



**Figure 3:** A 66-year-old woman with a history of right breast cancer. A&B) CT scan (lung and mediastinal windows) for metastatic work-up of the patient, showed few pulmonary nodules, the illustrated dominant one was seen based on the right oblique fissure, showing partially solid nature. C&D) 2 years follow-up CT scan (lung and mediastinal windows) for the same patient, showed progressive course as regards the number of the nodules, the illustrated dominant one showed solid nature. Diagnosed as metastatic nodules.



**Figure 4:** A 69-year-old woman with a history of right breast cancer. A&B) CT scan (lung and mediastinal windows) for metastatic work-up of the patient, showing few peripheral pulmonary nodules, the illustrated dominant one was seen based on the right oblique fissure, showing partially solid nature. C&D) 2 years follow-up CT scan (lung and mediastinal windows) for the same patient, showed progressive course as regards the size and density of the dominant nodule which was illustrated showing solid nature. Diagnosed as metastatic nodules.



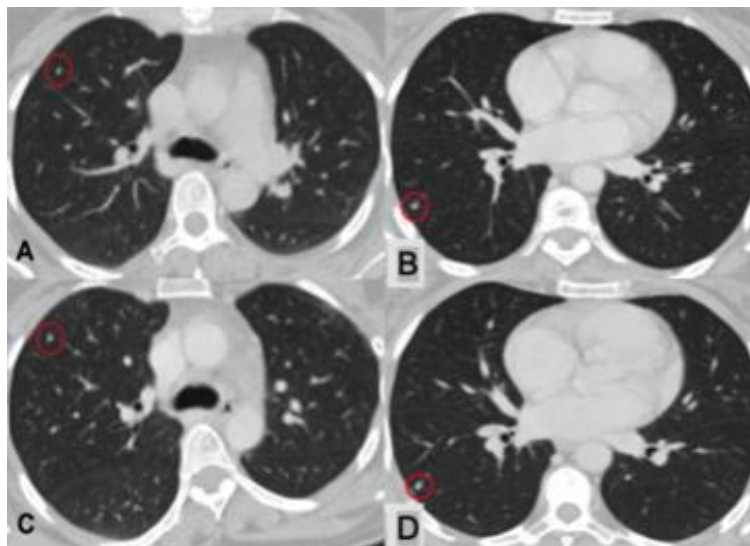
**Figure 5:** Bar chart of nodule behaviour in relation to its type

## DISCUSSION

As thin-section MSCT technology has advanced, we have noticed an increasing trend of patients presenting to the clinic following routine staging CT scans, showing indeterminate pulmonary nodules but no signs of metastatic disease. It remains uncertain whether these patients should be managed as having early breast cancer or as metastatic cases [3]. As the biopsy of these nodules is a challenge, in this study we intended to put the basic features of MSCT that we can use in everyday

practice with our basic CT machine to distinguish between benign and malignant pulmonary nodules.

For lung nodules, as in this study, it was agreed that stability of nodule size over 2 years, is a reliable determinant of benignity and excludes malignant origin [11] (**Figure 6**). In another study; the indeterminate pulmonary nodule was found to have a lower likelihood of metastatic disease than a suspicious one even in patients with primary breast cancer of a more histologically aggressive nature [3]. Standard adjuvant therapy is advised for managing indeterminate nodules to optimize treatment outcomes, with subsequent follow-up CT scans recommended [9].



**Figure 6:** A 43-year-old woman with a history of left breast cancer. A) CT scan (lung and mediastinal windows) for metastatic work-up of the patient, showed few peripheral pulmonary nodules, the illustrated dominant one was seen at the anterior segment of the right upper lobe, showing partially solid nature. C) 2 years follow-up CT scan (lung and mediastinal windows) for the same patient, showed stationary course of the nodule. Diagnosed as granulomatous nodule owing to the associated apical reticulations and calcified mediastinal lymph nodes not shown in images. Another 42-year-old woman with a history of right breast cancer. B) CT scan (lung window) for metastatic work-up of the patient, showing few peripheral pulmonary nodules, the illustrated dominant one is seen at the lateral segment of the right lower lobe, showing partially solid nature. D) 2 years follow-up CT scan (lung and mediastinal windows) for the same patient, showing stationary course of the nodules. Diagnosed as non-specific nodule.

Results are more or less the same as Caprica et al 2016 study on 228 cases with pulmonary nodules in cases with non-pulmonary cancer, there were 64% of metastatic nodules and they concluded that a high rate of inaccurate diagnosis and inappropriate treatment can result from assuming all patients with pulmonary nodules have metastatic disease. [12].

Currently, international guidelines suggest that the size and growth rate are the key factors in evaluating the characteristics of a pulmonary nodule. Nevertheless, size remains the primary radiological marker for identifying potential malignancy [13].

According to nodule size, in accordance with our results, Truong et al [11] stated that the diameter of nodules is positively correlated with the likelihood of malignancy. As a nodule's diameter increases, the likelihood of malignancy increases; yet small nodules are not excluded from malignancy. For nodules less than 4 mm, the risk of malignancy is less than 1%, whereas for nodules 8 mm or larger, the risk increases to 10%–20%. Also, these results come in agreement with Li et al [5], who found a statistically significant relation between lung nodule diameter and the final diagnosis in terms of malignancy. On the other hand; Kim et al [4] classified lung nodules identified via chest CT based on their size. Among 163 nodules, 11.7% of those smaller than 1 cm in diameter were found to be malignant, while 17.6% of larger nodules (greater than 1 cm) were malignant. However, no significant correlation was observed between nodule size and the presence of true metastasis.

The cut-off levels have been calculated in this study regarding the nodule size was 6.5 mm. This cut-off level provides great value to our practice regarding the need for follow-up or intervention in the pulmonary nodule. Similarly, the guidelines have determined the minimum threshold size of lung nodules for follow-up as 6 mm and malignancy prevalence among patients with 4–6 mm nodules was very low in multiple follow-up sets [9]. Yankelevitz et al [14] analyzed multiple studies comparing the size of nodules and the frequency of malignancy. The study revealed that a single pulmonary nodule with a diameter of less than < 6 mm, had malignancy rates of less than 1%.

Furthermore, the density of nodules affected the malignancy probability, which reflected the histological differences between lesions [13]. Regarding breast cancer metastatic lung nodules; these density numbers have not been reported in previous literature. In this study of non-calcified pulmonary nodules, the mean density of malignant lung nodules was -91.52 HU with cut off level of - 99.5 HU, but it was -247.13 HU (P-Value <0.001) for benign pulmonary nodule. This finding aligns with the results of other studies conducted on the density of lung nodules; they also found that the presence of solid components developing with time increased the risk for malignancy [15]. Zhan et al [16] concluded that CT attenuation value greater than -449.52 HU were more likely to be invasive

adenocarcinoma (IAC), however, Zhang et al [17] measured the solid components of pulmonary nodules and stated that the attenuation value higher than -192 HU had 77% sensitivity, and 62% specificity to differentiate IAC. Despite these findings, existing literature does not advocate for the use of nodule density in the routine differentiation between malignant and benign nodules. This is due to significant overlap and the wide range of densities observed among malignant nodules, as well as the variability in measurement methods, which may be subjective in various situations. Additionally, there is considerable variability in nodule density, especially within the malignant group, with substantial overlap. Size, shape, and margin also demonstrate limited efficacy in distinguishing malignant nodules from benign ones [18].

In terms of nodule multiplicity, in correlation to the final CT diagnosis, a reduced number of nodules was linked to a lower probability of malignancy and there is a significant (p-value < 0.001) higher probability to be malignant nodules in multiple nodule cases. This agreed with results from a study conducted at the University of Chicago Medical Center, multiplicity of nodules correlates significantly with increased likelihood of cancer [5]. But MacMahon et al [10] who recommended that multiple nodules located in a single area of the lung are generally indicative of an infectious process rather than malignant nodules.

There was a strong relationship between the morphological characteristics of lung nodules and the likelihood of malignancy [19]. There are multiple classification systems for nodules based on their external and internal characteristics, such as being ragged, densely speculated, somewhat irregular with slight speculation, or irregular with speculation. However, a standardized classification system for nodule morphology is not currently in use. Some of these existing classifications are overly complex and subjective, making them less suitable for research purposes. Most of the literature suggested the use of morphology with density and size in categorization [20]. Current study results were in agreement with another study by Xu et al [21], malignant nodules were more often non-spherical, irregular, lobulated, or speculated at baseline compared to smooth, rounded, or polygonal in benign nodules. Larici et al [13] agreed with this study, that benign nodules are typically distinguished by well-defined margins and a smooth contour, while malignant nodules often present with spiculated margins and an irregular or lobular contour.

Specifically, a spiculated irregular margin, often described as a corona radiata or sunburst sign, is highly indicative of malignancy, with a positive predictive value of 90% [11]. However, benign conditions such as lipoid pneumonia, tuberculoma, progressive massive fibrosis (PMF), and focal atelectasis can also present with spiculated margins due to infections or inflammation. Moreover, smooth margins do not



necessarily exclude malignancy as 20% of primary lung cancers have a smooth margin [11]. Likewise, it was also reported by Chun et al [22] that the edges of both benign and malignant nodules were smooth.

Regarding the nature of pulmonary nodules; in agreement with the current study the early lung screening studies concluded that the malignancy prevalence was higher among solid lung nodules, particularly when considering semi-solid than among solid nodules [12]. The literature showed variability in this category regarding nature. According to the review of Truong et al [11], follow-up was more conclusive in diagnosing persistent partial nodules as malignant, but the literature showed variability in this category regarding its nature. In cases of organizing pneumonia and focal interstitial fibrosis, persisting partial nodules have a higher likelihood of being malignant. As previously mentioned, in a study by Kim et al [4], Seventy-five percent of the persistent ground-glass appearances were of malignant origin. This significant variation was explained by detailing the histopathological types of the original malignancy.

The limitations of this study included the absence of histopathological confirmation of lung lesions, which would have yielded more definitive results compared to relying solely on CT observations. Also, within our follow-up, patients received chemotherapy, which could stabilize the tumor and change in their behaviour.

**Conclusions:** In breast cancer cases with pulmonary nodules, multi-slice CT (MSCT) of the chest is essential in establishing the final diagnosis. MSCT characteristics, including baseline nodule size, mean and maximum density, and morphological features, can effectively differentiate between benign and malignant nodules, which has a substantial impact on management and prognosis.

A multi-center study is necessary to measure the advanced radiomic features to develop final guidelines in cases of pulmonary nodules in breast cancer patients.

#### List of abbreviations

Multi-Slice Computed Tomography (MSCT)

Computed Tomography (CT)

Ground glass (GG)

Invasive adenocarcinoma (IAC)

Positron emission tomography (PET)

Progressive massive fibrosis (PMF)

#### Declarations

##### Ethics approval and consent to participate

The study was approved by the ethical committee of Baheya centre for early detection and treatment of breast cancer and national research centre. An informed written consent was taken from all subjects. IRB number **201912090028**.

**Consent for publication:-** All patients included in this research gave written informed consent to publish the data contained within this study.

**Availability of data and material:** - The datasets used and analyzed during the current study are available from the corresponding author on reasonable request.

**Competing Interests:** No financial or non-financial competing interests

**Funding:** No funding sources.

#### Authors' contributions:

MH wrote the manuscript. OM shared in writing and revision of the manuscript. OM and MH collected patient data, image processing and collection of patient's images. EH participated in the design of the study and performed the statistical analysis. EH and OM conceived of the study, and participated in its design and coordination and helped to draft the manuscript.

All authors have read and approved the manuscript.

**Acknowledgements:** This research was carried out at Baheya centre for early detection and treatment of breast cancer, which is fully equipped with modern machines for breast cancer diagnosis.

## REFERENCES

1. Connolly JE, Erasmus JJ, Patz EF. Thoracic manifestations of breast carcinoma: Metastatic disease and complications of treatment. *Clin Radiol* 1999;54(8):487–494.
2. Jung JI, Kim HH, Park SH, Song SW, Chung MH, Kim HS, Kim KJ, Ahn MI, Seo SB, Hahn ST. Thoracic manifestations of breast cancer and its therapy. *Radiographics* 2004;24(5):1269–1285.
3. Lee B, Lim A, Lalvani A, Descamps MJL, Leonard R, Nallamala S, Lewis JS, Coombes RC, Stebbing J. The clinical significance of radiologically detected silent pulmonary nodules in early breast cancer. *Ann Oncol* 2008;19(12):2001–2006.
4. Kim H, Han W, Moon H, Min J, Ahn S, Kim T, Im S, Oh D, Han S, Chie EK, Ha SW, Noh D. The value of preoperative staging chest computed tomography to detect asymptomatic lung and liver metastasis in patients with primary breast carcinoma. *Breast Cancer Res Treat* 2011;126(3):637–641.
5. Li F, Armato SG, Giger ML, MacMahon H. Clinical significance of noncalcified lung nodules in patients with breast cancer. *Breast Cancer Res Treat* 2016; 159(2):265–271.
6. Zander DS, Farver CF. *Pulmonary Pathology: A Volume in the Series: Foundations in Diagnostic Pathology*. Cincinnati, Ohio: Elsevier, 2017.
7. Mesurole B, Qanadli SD, Merad M, Mignon F, Baldeyrou P, Tardivon A, Lacombe P, Vanel D. Unusual radiologic findings in the thorax after radiation therapy. *Radiographics* 2000;20(1):67–81.
8. Seo JB, Im JG, Goo JM, Chung MJ, Kim MY. Atypical pulmonary metastases: spectrum of radiologic findings. *Radiographics* 2001;21(2):403–417.
9. Bankier AA, MacMahon H, Goo JM, Rubin GD, Schaefer-Prokop CM, Naidich DP. Recommendations for measuring pulmonary nodules at CT: A statement from the Fleischner society. *Radiology* 2017;285(2):584–600.
10. MacMahon H, Naidich DP, Goo JM, Lee KS, Leung ANC, Mayo JR, Mehta AC, Ohno Y, Powell

- CA, Prokop M, Rubin GD, Schaefer-Prokop CM, Travis WD, Van Schil PE, Bankier AA. Guidelines for management of incidental pulmonary nodules detected on CT images: From the Fleischner Society 2017. *Radiology* 2017;284(1): 228-243.
11. Truong MT, Ko JP, Rossi SE, Rossi I, Viswanathan C, Bruzzi JF, Marom EM, Erasmus JJ. Update in the evaluation of the solitary pulmonary nodule. *Radiographics* 2014;34(6):1658-1679.
  12. Caparica R, Mak MP, Rocha CH, Velho PHI, Viana P, Moura MRL, Menezes MR, Amato MBP, Feher O. Pulmonary Nodules in Patients With Nonpulmonary Cancer: Not Always Metastases. *Journal of Global Oncology* 2016;2(3),138-144.
  13. Larici AR, Farchione A, Franchi P, Ciliberto M, Cicchetti G, Calandriello L, Del Ciello A, Bonomo L. Lung nodules: Size still matters. *Eur. Respir Rev* 2017;26(146):170025.
  14. Yankelevitz DF, Yip R, Smith JP, Liang M, Liu Y, Xu DM, Salvatore MM, Wolf AS, Flores RM, Henschke CI, International Early Lung Cancer Action Program Investigators Group. CT screening for lung cancer: Nonsolid nodules in baseline and annual repeat rounds. *Radiology* 2015;277(2):555-64.
  15. Lee JH, Hong JI, Kim HK. Guidelines for the Investigation and Management of Ground Glass Nodules. *J Chest Surg* 2021;54:333-337.
  16. Zhan Y, Peng X, Shan F, Feng M, Shi Y, Liu L, and Zhang Z. Attenuation and Morphologic Characteristics Distinguishing a Ground-Glass Nodule Measuring 5–10 mm in Diameter as Invasive Lung Adenocarcinoma on Thin-Slice CT. *American Journal of Roentgenology* 2019 213:4, W162-W170.
  17. Zhang Y, Shen Y, Qiang JW, Ye JD, Zhang J, Zhao RY. HRCT features distinguishing pre-invasive from invasive pulmonary adenocarcinomas appearing as ground-glass nodules. *Eur Radiol* 2016; 26:2921–2928.
  18. Khan AN, Al-Jahdali HH, Irlion KL, Arabi M, SS. Solitary pulmonary nodule: A diagnostic algorithm in the light of current imaging technique. *Avicenna J Med.* 2011;1(2):39–51.
  19. Wang YX, Gong JS, Suzuki K, Morcos SK. Evidence based imaging strategies for solitary pulmonary nodule. *J Thorac Dis.* 2014 Jul;6(7):872-87.
  20. Hu B, Ren W, Feng Z, Li M, Li X, Han R, Peng Z. Correlation between CT imaging characteristics and pathological diagnosis for subcentimeter pulmonary nodules. *Thorac Cancer.* 2022 Apr;13(7):1067-1075. doi: 10.1111/1759-7714.14363. Epub 2022 Feb 24. PMID: 35212152; PMCID: PMC8977167.
  21. Xu DM, van Klaveren RJ, de Bock GH, Leusveld ALM, Dorrius MD, Zhao Y, Wang Y, de Koning HJ, Scholten ET, Verschakelen J, Prokop M, Oudkerk M. Role of baseline nodule density and changes in density and nodule features in the discrimination between benign and malignant solid indeterminate pulmonary nodules. *Eur. J. Radiol* 2009;70(3):492-8..
  22. Chun EJ, Lee HJ, Kang WJ, Kim KG, Goo JM, Park CM, Lee CH. Differentiation between malignancy and inflammation in pulmonary ground-glass nodules: The feasibility of integrated 18F-FDG PET/CT. *Lung Cancer* 2009;65(2):180-6.