

## APOPTOSIS AND DNA CHANGES IN HEPATOCYTES AFTER SELECTIVE PORTAL VEIN EMBOLIZATION; CONTROLLED EXPERIMENTAL STUDY.

By

A. H. I. Helmy, O. M. Hammam,\* T. Abou Shousha, \* S. A. Keshta

Departments of General Surgery & Experimental Unit, \* Pathology, Theodore Bilharz Research Institute.

**Introduction:** Extensive hepatic resection could be done by performing pre-operative portal vein embolization (PVE), to induce compensatory hypertrophy in the predicted remnant liver. The aim of this study is to evaluate the effect of selective (PVE) on hepatocytes

**Methods:** The study was done on 23 adult Shin Sheila rabbits, embolization of the lateral right branch of the portal vein using Histoacryl was done. The animals were divided into 2 groups: (group-A) ; 12 animals sacrificed in < 30 days and (group-B); 11 animals sacrificed between 30 to 60 days. Biopsies were taken from embolized (E) and non embolized (NE) lobes and examined.

**Results:** Degeneration was remarkable in (E) lobe in (group-A), while it was not noticeable in (group-B). Regeneration was evident in (E) lobe in (group-B). Proliferation occurred in (NE) lobes in (group-A) in the (NE) lobes. Regeneration was marked in (group-B) in the (E) lobe. Morphometric DNA study showed apoptosis in the (E) lobe of (group-A) were more than in the (NE) lobes while in (group-B) they were nearly the same in both lobes.

**Conclusion:** PVE induce apoptotic changes in (E) lobe in the early stage this was re-compensated by increased cellular proliferation in late stage evident by increased in S phase fraction of DNA by image analysis study.

**Keywords:** hepatic resection, portal vein embolization, hepatocyte degeneration hepatocyte regeneration

### INTRODUCTION

Hepatocellular carcinoma (HCC) mainly affects patients with cirrhosis or with various degrees of fibrosis.<sup>(1)</sup> The management of hepatic malignancy is one of the most controversial areas in medicine. It is a continuously evolving field which requires a multimodal approach. In addition the recent development of novel approaches such as cryosurgery, thermal ablative techniques as well as biological and immunological manipulation of malignant cells has added to the complexity of this Field.<sup>(2)</sup>

Recent improvements in the therapeutic management of (HCC) have led to further evaluation of the role of surgery for this disease.<sup>(3)</sup> Considering that liver transplantation for malignancy had disappointing long term results due to tumour recurrence. Advance in liver surgery has made extensive liver resection safer but cases of unresectable tumours due to site and size are still present.<sup>(2)</sup> However, major hepatic resections have been associated with significant morbidity and mortality<sup>(4)</sup> as liver failure

develops after extensive liver resection.<sup>(5)</sup> Segmental resection, when appropriate, is a safe technique that allows complete resection of the liver tumour with maximum preservation of liver parenchyma and it is particularly useful for patients with HCC.<sup>(6)</sup> There is no agreement regarding the preoperative measurement of liver volumes and the minimal safe size of the liver remnant after extended hepatectomy.<sup>(7)</sup> Preoperative portal vein embolization (PVE), to induce compensatory hypertrophy in the predicted remnant liver, decreases the clinical complications after hepatectomy.<sup>(5)</sup> However, criteria for selection of patients for portal vein embolization before major hepatectomy for advanced stage (HCC) have not been clarified in detail.<sup>(8)</sup> The aim of the study is to evaluate the effect of selective portal vein embolization on regeneration and degeneration of hepatocytes both on selective portal vein embolized (E) and non embolized (NE) part of the liver.

## PATIENTS AND METHODS

**Ethical considerations:** All experimental protocols in this study were reviewed and approved by the institutional review board of Theodore Bilharz Research Institute "Animal Research Ethical Committee". All Procedures were performed at the Theodore Bilharz Research Institute, Experimental Surgical Unit. All animals used for this study were obtained from the Biological Resources Production Unit at Theodor Bilharz Research Institute (TBRI).

**The Experimental design:** The present study was done on 23 adult male and female shin Sheila rabbits weighing an average of 2.5 kg and with an average age of 6 months. The rabbits were kept in separate cages, fasting overnight but water was given freely.

**Anaesthetic procedure:** The animal was anesthetized by intramuscular diluted ketamine hydrochloride (PoM Ketalar® (P-D) 10mg/mL 20-mL vial Astra Zeneca); the dose used was 4mg/kg prepared as mixture formed of 1 mL + 9 mL of normal saline; starting with an initial dose 8 mL of the prepared mixture then followed by 1 mL, then another 1 mL and so on until the animal is completely relaxed and asleep.

All animals had a single intramuscular injection of prophylactic antibiotic Oxytetracycline HCl (PAN-Terramycin\*/LA 200 mg oxytetracycline/mL 30ml. / bottle pfizer-Egypt under license pfizer Inc.USA) after induction of anesthesia by a recommended dose of 2.5 mL/10kg.body wt. for Rabbit. Infiltration anesthesia by subcutaneously injection of anhydrous lignocaine hydrochloride 0.5% (PoM Xylocaine® Astra Zeneca 0.5%, 5mg/mL 20-mL vial) was done at the line of incision as well, the maximum volume used was 4 mL / animal.

**Operative Procedure:** The abdominal wall is cleaned and moistened with sterile water after the hair is shaved. The animal was placed in supine position. A midline incision from xiphoid process to pubic area was done under complete aseptic condition. Exploration and identification of the portal vein and hepatic artery were identified and dissected. The portal vein was controlled with the right portal branch using either Debakey vascular forceps or the snigger technique (using vicryl ligature to pass around the vessel lumen then the two threads of the ligature passed through the lumen of a small piece of nelton catheter tube, pulled and clamped with an artery forceps to control the flow).

The embolization was performed by injecting 0.5 - 1 mL of n. Byteryl-2 cyanoacryle, ( 1 x 0.5 mL Histoacryl®-B | BRAUN Surgical GMBH D-34209 Melsungen Germany) in the distal part of the clamped right portal vein using a

black needle attached to the nozzle tube of the glue to control amount used. At the end the embolized lobe distinguished by the gross appearance was marked (by vicryl 5/0 ligature) to facilitate its identification during the second operative procedure. After closure of the abdominal wall, all animals are then housed under identically controlled environmental conditions. Free diet and water was permitted immediately post operatively. Post operative intramuscular injection of antibiotic Oxytetracycline HCl by a recommended dose of 2.5 mL/10kg.body wt. for Rabbit was given daily for five days.

The second laparotomy was done 14 - 54 days after the first procedure through the previous incision. The animal was anesthetized by the same method described before. Total hepatectomy was performed. The marked embolized (E) right lateral lobe was separated from other non embolized (NE) lobes of the liver and both were sent for histopathological examination.

**Histopathological Procedures:** Specimens of the embolized (E) lobe and non embolized (NE) lobes of liver from sacrificed rabbits were fixed in 10% buffered formalin, processed into paraffin blocks through ascending grades of ethyl alcohol, xylene and embedded in paraffin wax. Five microns-thick tissue sections were cut serially at different planes. The following stains were used for histopathological study: Haematoxylin and Eosin (H&E) for routine evaluation of liver pathology and counting of apoptotic figures. We used the Masson trichrome for evaluation of fibrous tissue content of liver section and its distribution. The Feulgen stain was used for DNA cytometry by automated image analysis in hepatocytes in the regenerative phase. The liver sections were examined, paying attention to the following points: Disturbance in hepatic lobular architecture, Hepatocytic degeneration; in the form of cloudy swelling, hydropic and ballooning degeneration, Hepatocytic regeneration; in the form of double nuclei and thickened liver cell plates, Hepatocytic necrosis (cytoplasmic changes in the form of acidophilic changes councilman changes and nuclear changes in the form of piknosis, karryorrhesis and karryolysis, Portal angiogenesis was noticed by the new vascular formation in the portal tracts in the form of small vascular buds and collapsed vascular spaces, Portal inflammation; in the form of mononuclear cellular infiltration by plasma cells and lymphocytes, Portal fibrosis in the form of expansion of the portal tract by fibrous tissue. Apoptosis was defined as a form of cell death distinct from necrosis (programmed cell death). Apoptosis, in contrast to necrosis affects scattered single cell in the midst of living tissues. The light microscopic manifestations of apoptosis are better appreciated with knowledge of the diagnostic ultrastructural appearances.

Evaluation of DNA content by Image Analysis of Nuclear

DNA: Automated image analysis assessment of nuclear DNA content of the Hepatocytes stained by Feulgen stain was performed using the computer controlled analysis system (Kontron Image Analysis System). This essentially consists of a computer controlled microscope (Zeiss axioskop microscope), video camera, two monitors, video printer, computer unit PC-IBM compatible, 486D×100), desk jet colored printer 560c. Image analysis technique was performed using the soft urea program CIRES, which allowed the colored compound that develops in the stained nuclei to be directly proportional to DNA content within the nucleus and can be measured as quantifiable integrated optical density (IOD). A number of nuclei ranging from 150-200 cells were submitted for DNA analysis in each case at 400x lens magnification. Only single monolayered nuclei without overlapping were analyzed.

The elaborated DNA histograms were classified as either diploid or non diploid based on DNA index (DI) of the main peak. The diploid histograms were further sub classified into 3 grades according to the degree of increase in S phase, mild (10-20% increase), moderate (over 20-30% increase) and marked (above 30 to 40% increase). The proliferating index and 5C exceeding rate %. Terms used in DNA analysis:

- 2C = DNA content of normal cell or diploid cell that contains 2 complement / each chromosome.
- 4C = DNA content of normal cell which is tetraploid containing 4 complements / each chromosome.
- Euploid = DNA content of the normal cell.
- Diploid = DNA content of the normal cell at 2C.
- Tetraploid = DNA content of the normal cell at 4C.
- Aneuploid = Abnormal DNA content.
- Proliferation index (PI) = is the measure of the cell division rate, estimated by the percentage of the cells in S phase in a certain population sample.

## RESULTS

The study was done on 23 Shin Sheila rabbits; these animals were divided into two main groups; First group A-(early) includes animals that survived the first operative procedure (embolization of right portal vein branch) and sacrificed at < 30 days from the first operative procedure

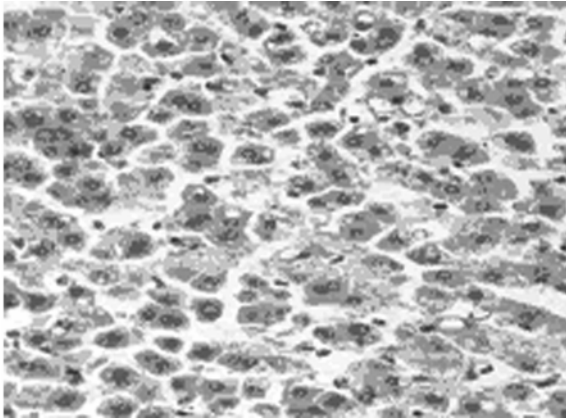
(12 animals). Second group B-(late) includes animals sacrificed between 30 to 60 days after the first post operative procedure (11 animals). All animals had the second operative procedure (total hepatectomy) and both embolized (E) lobe and non embolized (NE) lobes were examined pathologically.

Hepatocytic degeneration in the form of cloudy swelling, hydropic and ballooning degeneration was remarkable in (E) lobes due to decrease in its portal blood supply as a result of PVE. This was more apparent in group A, while it was not noticeable in group B due to occurrence of revascularization and consequently improvement of its blood supply. (Histopathology results (Fig. 1) plates 1-3).

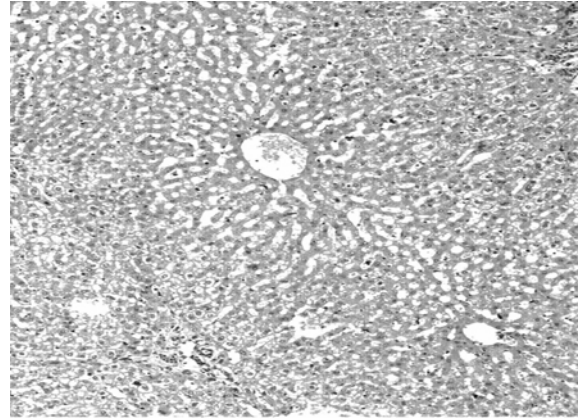
Hepatocytic regeneration in the form of double nuclei and thickened liver cell plates was evident in both (E) & (NE) lobes. It was more evident in group A in the (NE) lobes. This is explained by the redistribution of portal flow after embolization. This was marked in group B in the (E) lobe due to occurrence of recanalization of embolized portal branch and the development of capsular collateral circulation (Histopathology results (Fig. 1) plates 4-6).

Morphometric DNA study; by automated image analysis for DNA cytometry were obtained and the results were shown as histograms plotted (DNA Histograms results (Fig. 2) I-IV) which showed increased cellular proliferation pool (S phase i.e. indicating increased regenerative activity) in group A in the (NE) lobes than the (E) lobe; histogram I showing marked increased 30-40 % of proliferating cell-pool (NE) lobes, histogram II showing moderate increased 20-30 % of proliferating cell-pool (E) lobes The increase was more in the (E) lobe than the (NE) lobes in the group B histogram III showing moderate increase 20-30 % of proliferating cell-pool (NE) lobes and histogram IV showing moderate increased % of proliferating cell-pool (E) lobes.

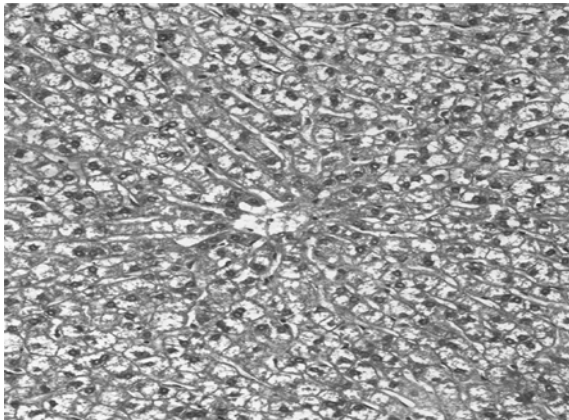
The number of cells in apoptosis with its manifestations shown by the light microscope was more in the (E) lobe of group A than in the (NE) lobes. While in group B the number of apoptotic cells was nearly the same in both (E) & (NE) lobes.



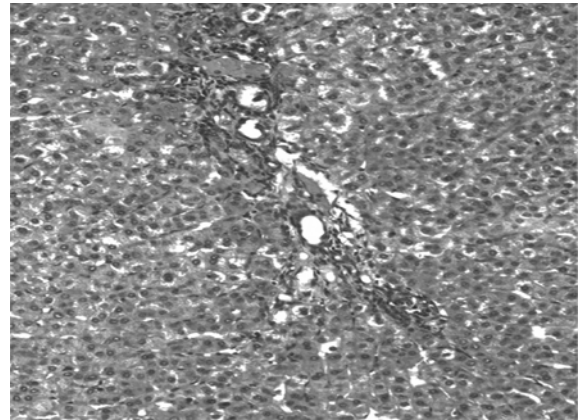
1. Hepatocytic degeneration showed ballooning early(A)  
(E) lobe Masson Trichome x200



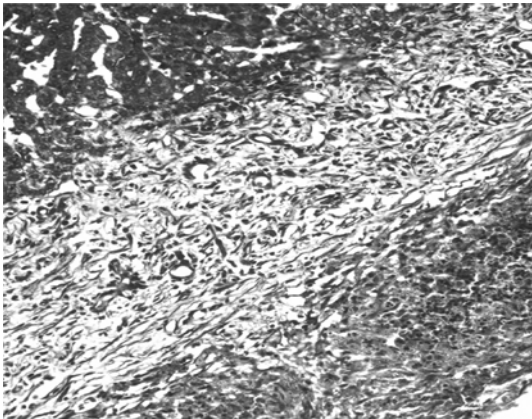
2. Hyperplastic proliferating hepatocytes; double nuclei, thickened liver cell plates and compressed sinusoids early (A)  
(NE) lobe H&E stain x400



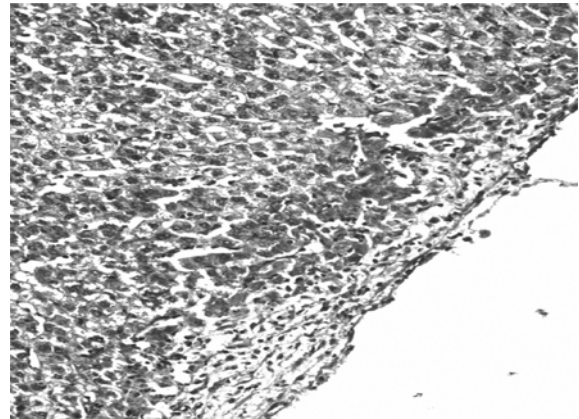
3. Hepatocytic degeneration showed cloudy swelling early(A)  
(E) lobe H&E stain x200



4. Newly formed vessels in the portal tract late (B)  
(E) lobe H&E stain x200

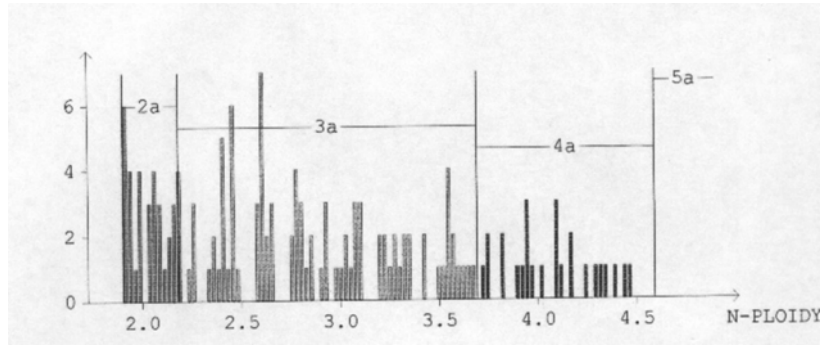


5. Thickened liver capsule marked neo-vascularization late (B)  
(E) lobe Masson Trichome x100

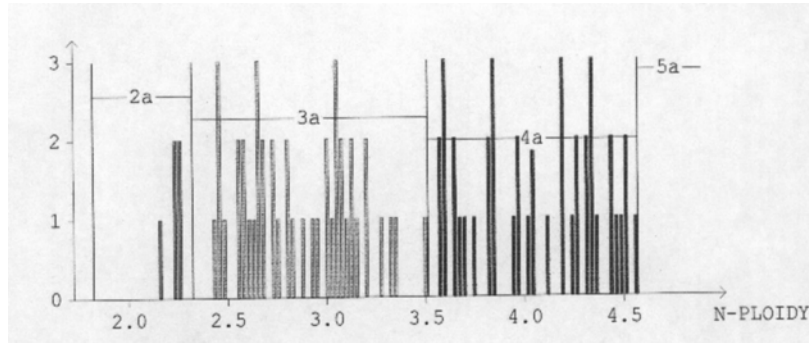


6. Absence of neo-vascularization Liver Capsule late (B)  
(NE) lobe Masson Trichome x100

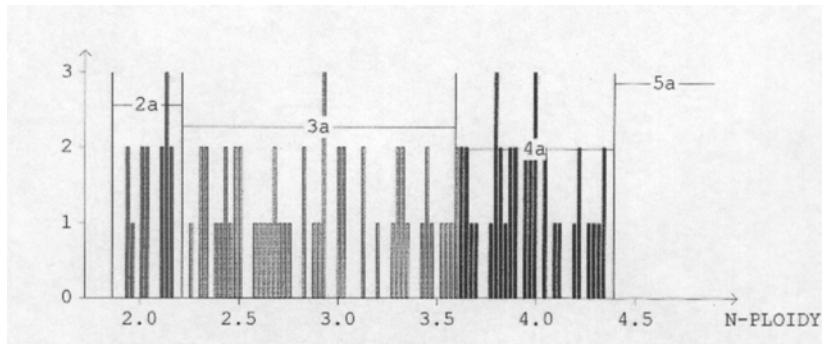
**Fig 1: Histopathology results plates (1-6)**



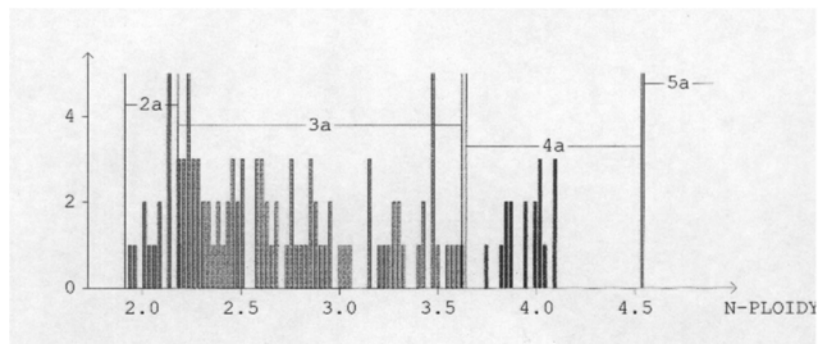
*I-DNA histogram in early (A) non-embolized (NE) liver showing marked increased % of proliferating cell-pool*



*II-DNA histogram in early (A) embolized (E) liver, showing moderate increased % of proliferating cell-pool*



*III-DNA histogram in late (B) non-embolized (NE) liver showing moderate increase % of proliferating cell-pool*



*IV-DNA histogram in late (B) embolized (E) liver, showing moderate increased % of proliferating cell-pool*

**Fig 2: DNA Histograms in early and late phases both in E and NE lobes (I-IV)**

## DISCUSSION

Liver regeneration is a process in which quiescent cells begin to proliferate in order to restore an equivalent tissue deficit. It is an extraordinary example of how cellular proliferation is regulated in intact animals.<sup>(12)</sup> Residual hepatocytes up regulate both proliferative and liver specific genes in order to preserve tissue specific function. In addition hepatocyte proliferation is tightly co-ordinate to complement regenerative responses in hepatic non parenchymal cells e.g. endothelial biliary epithelium, stellate and kupffer cells so that the entire organ can be reconstituted within days.<sup>(11)</sup>

The liver has a tremendous regenerative capacity. This distinguishes it from other vital organs that cannot replace functional tissue once it has been destroyed. Although hepatocytes rarely proliferate in the healthy adult liver, virtually all surviving hepatocytes replicate at least once after 70% partial hepatectomy.<sup>(11)</sup> The most applicable method for PVE is the percutaneous transhepatic catheter directly to portal vein<sup>(9)</sup> which was difficult in our study due to non feasibility so the open (trans abdominal) method was done. Embolization of the right lateral branch of portal vein in the rabbits allowed embolization of about 25% of total liver tissue and hence redistribution of portal blood flow. Using different embolizing material (cyanoacrylate, thrombin, coils or absolute alcohol) for PVE did not show any specific difference,<sup>(10)</sup> in our study we used cyanoacrylate for PVE as it was available in TBRI and it allowed immediate embolization of the portal vein branch and immediate identification of the embolized lobe. Preoperative interruption of the portal flow in the liver territories planned to be removed, induces their atrophy and the compensatory hypertrophy of the segments spared by the resection. This compensatory hypertrophy of the non embolized segments is maximal during the first two weeks and persists, although to a lesser extent during approximately six weeks considering that the magnitude of hypertrophy is correlated with the volume of parenchyma embolized.<sup>(13)</sup>

In our study hepatocytic regeneration was evident in non embolized lobes (NE) which is explained by the redistribution of portal blood flow after embolization. This was marked in the (A) early phase (animals sacrificed in less than 30 days) more than the (B) late phase (animals sacrificed between 30 to 60 days), may be due to occurrence of recanalization of the embolized portal branch with consequent decrease in the stimulus for regeneration or to the development of capsular collateral circulation in the embolized lobe.

In our study hepatocytic degeneration was remarkable in the embolised lobes (E) most probably due to the decrease in its portal blood supply as a result of embolization of portal

vein branch. This was more apparent in the (A) early phase post embolization while it was not that noticeable in the (B) late phase. This may be explained due to the occurrence of revascularization and consequently improvement of its blood supply as time goes (Histopathology plates 1-6). Various factors including species, age, magnitude of resection, environment and diet modify the regenerative response however none of them appear to be the controlling factor.<sup>(14)</sup>

The Morphometric DNA study results were the same as previous authors with a better outcome in our study.<sup>(15)</sup> The cellular proliferation pool (S phase) was found to be more in the early group A in the (NE) lobes than the (E) lobe. This is due to the hepatic portal flow was directed mainly to the (NE) lobe i.e. the hepatocytic degenerative effect of PVE on the (E) lobe which initiated liver regeneration in the NE lobe. This also was accompanied with increase the number of apoptotic cells in the E lobe. This cellular proliferation pool (S phase) was reversed due to the surface neo-vascularization of the E lobe in the late group B i.e. the late hepatocytic regenerative effect of the (E) lobe. This was indicated by the amount of apoptotic cells which was nearly equal in both E and NE lobes (Histrograms I-IV).

This study has shown PVE in Shen Shiela rabbits with acceptable results in hepatocytic regeneration in the non embolized lobes which is maximum in less than 30 days post embolization then it declines. Capsular revascularization occurred between 30 to 60 days after PVE in the embolized lobes decreasing the process of regeneration in the non embolized lobes. Morphometric study for cellular proliferation and apoptosis has confirmed the early and late effect of PVE in stimulating liver regeneration. PVE is causing hepatocyte degeneration in the embolized lobes and regeneration in the non embolized lobes however this was partially reversible at late stage.

## REFERENCES

1. Fakete F; Belghiti J; Flejau TF; Panis Y; Molas G Hepatocellular carcinoma in undamaged liver. *Ann Ital Chir.* 1991;62:545-49.
2. Millar AJ; Hartley P; Khan D; Spearman W, Andronikou S, Rode H: Extended hepatic resection with transplantation back up for an "unresectable" tumour. *Pediat. Surg. Int.* 2001;17:378 - 81.
3. Mazziotti A; Grazi GL; Covallari A: Surgical treatment of hepatocellular carcinoma on cirrhosis: a Western experience. *Hepatogastro enterology*, 1998;45 Suppl 3:1281-87.
4. Greif F; Rubin M; Mor E; Nudelman I; Sihon A; Figer A; Belinki A; Lelcuk S: 129 liver surgeries , five years of experience in a surgery department. *Harefuah.* 1999;136:421-25,514.

5. Nishi-Shinbashi; Minato-Ku:Hyperbaric oxygenation after portal vein embolization for regeneration of the predicted remnant liver.J. Surg. Res. 2001;100:63-8.
6. Billingsley KG; Jarnagin WR and Fong Y; Blumgart LH: Segment-oriented hepatic resection in the management of malignant neoplasms of the liver.J. Am. Coll. Surg. 1998;187:471-81.
7. Vauthey JN; Chaoui A; Do KA; Bilimoria MM; Fenstermacher MJ; Charnsangavej C; Hicks M; Alsfasser G; Lauwers G; Hawkins IF; Caridi J : Standardized measurement of the future liver remnant prior to extended liver resection: methodology and clinical associations. Surgery. 2000;127:512-9
8. Wakabayashi H; Yachida S; Maeba T; Maeta H: Indications for portal vein embolization combined with major hepatic resection for advanced-stage hepatocellular carcinomas. A preliminary clinical study.Dig. Surg. 2000;17:587-94.
9. Ishikawa M; Yogita S; Iuchi M; Yagi K; Chikaishi H; Fukuda Y; Miyake H; Harada M; Tashiro S: Experimental and clinical studies on liver regeneration following transcatheter portal embolization. Hepatogastroenterology. 2000;47:226-33
10. Abdalla EK; Hicks ME; Vauthey JN: Portal vein embolization: rationale, technique and future prospects. Br J Surg. 2001;88:165-75
11. Diehl AM, Rai R: Regulation of Liver Regeneration by Pro-Inflammatory Cytokines. J Gastroenterol Hepatol. 1996;11:466-70.
12. Leffert HL, Koch K and Lad PJ : Hepatocyte regeneration, replication and differentiation. In: Arias, I.M., Jakoby, W.B., Popper, The liver, Biology and Pathology. Raven Press, New York. 1994;833-850.
13. Farges O,Denys A:Portal vein embolization prior to hepatectomy. Techniques , indications and results.Ann Chir 2001;126:836-44
14. LaBrecque DR : The Role of Hepatotrophic Factors in Liver Regeneration--a Brief Review Including a Preliminary Report of the in Vitro Effects of Hepatic Regenerative Stimulator Substance, J Biol Med. 1979;52:49-60.
15. Harada H, Imamura H, Miyagawa S, Kawasaki S.Fate of the human liver after hemihepatic portal vein embolization: cell kinetic and morphometric study.Hepatology. 1997;26:1162-70.