

LAPAROSCOPIC NISSEN FUNDOPLICATION: TECHNIQUE AND PRELIMINARY RESULTS

By

Ayman M. Hassanién, MD; Sarwat M. Ali, MD; Ali Magdi, MD.

Department of General Surgery, El-Minia University

Laparoscopic Nissen fundoplication is positioned to become the standard of surgical treatment for patients with gastroesophageal reflux disease (GERD). The present study aimed to evaluate in a prospective manner the technique and the clinical results of laparoscopic Nissen fundoplications. Between January 1998 and January 2001, 28 patients (17 male and 11 female with a mean age 42 ± 6.7 years) who had undergone a laparoscopic approach for a Nissen fundoplication in El-Minia University Hospital were studied. All patients had undergone medical treatment for at least 3 months and then were referred to surgery due to unsatisfactory symptom control in 19 patients (67.8%) or to avoid life long medications in 9 patients (32.2%). Laparoscopic Nissen fundoplication was done with or without division of short gastric vessels. It was successful in 24 of 28 patients (85.7%). The mean operative time was 126 ± 12.4 minutes. The mean post operative hospital stay was 3.1 ± 0.2 days. Conversion from laparoscopic to open fundoplication was needed in 4 cases (14.3%). There was no operative mortality with low serious morbidity. The mean heartburn score was 2.68 ± 1.26 before operation versus 0.35 ± 0.79 after operation by one year, with significant improvement ($P < 0.01$). The mean preoperative dysphagia score was 1.1 ± 0.9 versus 0.32 ± 0.21 by one year postoperatively ($P < 0.01$). Troublesome dysphagia was reported in 10 patients (35.7%), one was reoperated upon and 9 cases responded to dilatation or diet management.

Conclusion: *Laparoscopic Nissen fundoplication is a promising technique because it is safe with low morbidity rate and short hospital stay. The short term functional results shows the effectiveness of the technique in controlling the gastroesophageal reflux disease. Long term results should be studied.*

Key words: Laparoscopy. Nissen fundoplication. Reflux esophagitis

INTRODUCTION

Although most people experience transient reflux of gastric contents into the esophagus, some suffer from frequent heartburn due to repetitive, pronounced esophageal acid exposure and are diagnosed as gastroesophageal reflux disease (GERD)^(1,2). The initial management of GERD involves lifestyle changes and elimination of foods and medications that affect lower esophageal sphincter (LES) pressure. If these initial steps fail, patients are given a maintenance regimen of acid suppression therapy. Although medical management simply attempts to minimize the injury by reducing the caustic nature of the refluxed contents, the goals of surgical therapy focus on improvement of LES function. The most common antireflux procedure, Nissen fundoplication, has

proven a safe and durable mode of therapy, with reported success rates greater than 90%^(3,4).

The difficult part of the operation lies in achieving access to the esophageal hiatus. Laparotomy leads to parietal injury disproportionate with the simplicity of the actual procedure. Moreover, sustained traction on the costal margin is necessary for good visualization throughout the operation. Recovery time is conditioned by the extent of the trauma inflicted to achieve good exposure. Access by a laparoscopic approach limits trauma to the abdominal wall and could therefore diminish the postoperative morbidity rate and hospitalization time⁽⁵⁾. The use of laparoscopy and the recognition that surgical management is effective have increased the numbers of patients being referred for surgical therapy^(6,7,8,9,10,11,12,13).

Early clinical studies of laparoscopic Nissen fundoplication documented successful relief of reflux symptoms in 90% of patients (7). As a result, laparoscopic Nissen fundoplication is positioned to become the standard of surgical treatment for patients with GERD(14).

The present study aimed to evaluate in a prospective manner the technique and the preliminary results of laparoscopic Nissen fundoplications

PATIENTS AND METHODS

Between January 1998 and January 2001, 28 patients with GERD (17 male and 11 female, age ranged from 21 to 64, mean \pm SD 36 ± 9.3 years) were treated a laparoscopic Nissen fundoplication, in El-Minia University Hospital. The exclusion criteria were previous gastric or esophageal surgery or big sized hiatus hernia more than 5 cm with short esophagus. Three patients were excluded and the three had prior gastroesophageal procedures (one myotomy, one prior antireflux procedure, and the third had a laparoscopic vagotomy) A detailed written consent was taken from all patients.

Clinical evaluation

Each patient completed a symptom questionnaire before surgery. Symptoms of GERD (heartburn, dysphagia, regurgitation) were rated on a scale from 0 to 4, giving a maximum severity score of 12 (0, no symptoms; 1 infrequent symptoms; 3 frequent symptoms; 4 incapacitating symptoms). All patients had undergone barium studies and endoscopy. Endoscopic esophagitis was graded as: 0, normal; 1, erythema only (fig. 1); 11, non confluent erosions (fig.2), III, confluent erosions and/or circumferential shallow ulcerations; and IV, deep ulcer, stricture or Barrett's mucosa (15). Of the 28 patients, 12 underwent manometry and 14 patients underwent 24-h esophageal pH studies. The diagnosis of GERD was based on the presence of at least two of the following criteria: spontaneous reflux of barium, esophagitis at endoscopy, inflammatory changes in biopsy specimens, or an abnormal 24-h pH recording. All patients had undergone treatment with H2 receptor antagonists or omeprazole for at least 3 months and were referred for surgery, either because of unsatisfactory symptom control in 19 patients (67.8%) or because of an expressed wish to avoid life-long oral medication in 9 patients (32.2%).

Operative technique

The procedure was done under general anesthesia and the patient was in the lithotomy position with the table tilted 30°, head up, and the surgeon stood between the patients legs. After placing a nasogastric tube to deflate the stomach, a Verres needle was inserted in the midclavicular line just below the left costal margin, and the abdomen was

insufflated with CO₂ gas to a maximum pressure of 10 mmHg. Five ports were placed.

A 10 mm port was introduced just to the left of the midline, midway from the xiphisternum to the umbilicus; this was used initially for the 30° laparoscope (Carl Storz, Japan) . Additional ports were placed undervision. Five millimeter ports were placed in the midclavicular line just below the right costal margin for insertion of a grasping forceps for dissection or liver retraction, and in the epigastrium just below the xiphisternum, also for a grasping forceps or liver retractor. A 10 mm port is placed in the left anterior axillary line just below the costal margin for passage of an endo-Babcock. The fifth port is a 10mm port placed in the left midclavicular line a variable distance below the costal margin. This distance was determined by the width of the patient's costal angle and the need to avoid instruments clashing with other ports. This was the principal operating port for dissecting and suturing.

The first step of the procedure was to divide the gastrohepatic omentum along the upper lesser curve of the stomach. This was done over a short distance to avoid damage to the hepatic branches of the vagus nerve. Then, the stomach was retracted to the left to expose the right crus of diaphragm. The anterior edge of the right crus was identified by incising the overlying peritoneum and was peeled gently off the esophagus, allowing access to the mediastinum around the esophagus. The stomach was retracted to the right hand side, and the left crus was identified similarly and dissected and removed from the esophagus.

The esophagus was elevated, and the posterior vagus nerve was identified behind the esophagus. This is dissected gently and window was created. The window posterior to the esophagus was widened. The left and right crura were closed behind the esophagus by one to three 2-0 Prolene sutures passed through the muscle bundles of the crura. The upper 10cm of the greater curvature of the stomach was mobilized by clipping and dividing short gastric vessels and peritoneal attachments to the spleen and diaphragm. A Babcock grasper was passed from the right subcostal port behind the esophagus to grasp the mobilized fundus which was then pulled through the window behind the esophagus. The wrap was fixed around the esophagus. The contiguous part of the fundus of the stomach was used for the fundoplication to avoid an excessively loose wrap (Fig. 3). Two simple 2-0 interrupted Prolene sutures were placed biting through the anterior wall of the esophagus and the gastric wrap (Fig.4). The pneumoperitoneum was released, and the ports were removed and tubal drain was applied.. The operative time was recorded.

Postoperative management

Nasogastric tube was removed on the second postoperative day, and fluid intake commenced on the second day. Semisolids are commenced on the third day. The patient usually leaves the hospital on the fourth postoperative day.

Follow up

Follow up was carried out 1 week, 1 month, 3 months and 1 year after operation. A standard questionnaire was completed at each examination. Objective evaluation with barium meal, upper endoscopy, 24 h pH recording and manometry was performed after 3 months. Endoscopy and barium meal were repeated after 1 year.

Statistical analysis

Descriptive data were expressed as mean \pm standard deviation or medians and ranges for continuous variables and as number and percent for categorical variables. Preoperative versus postoperative data were analysed using the Wilcoxon signed rank test (for categorical data) and paired t-test (for continuous data).

RESULTS

Symptoms of patient population

Twenty patients (71.4%) presented by typical reflux symptoms (heart burn, regurgitation, dysphagia), 6 patients (21.4%) had typical and one or more atypical symptoms (cough, chest pain, hoarseness, asthma) and 2 patients (7.2%) had atypical symptoms without significant heart burn (Fig. 5). Nine patients (32.1%) had a complete response to medical therapy of GERD (score, 0-1) and were seeking surgery to avoid life-long oral medication and its high costs while, 19 patients (67.8%) had frequent or incapacitating symptoms (score, 3-4).

Investigations:

Preoperative endoscopic grading was done for all patients. Grade 0-1 was present in 13 patients (46.4%), grade II was present in 8 patients (28.6%), grade III was present in 6 patients (21.4%), grade IV was present in 1 patient (3.6%).

Barium studies were done for all patients to exclude stricture or paraesophageal hernia. Ambulatory 24-hour pH testing was performed in 14 patients (50%) and the results were abnormal in all patients. The mean percent time with a distal esophageal pH less than 4 was $18.9 \pm 22\%$ of a 24^o period in the study population. Manometry study was done in 18 patients (64.3%) and the resting lower esophageal sphincter pressure was less than 10 mmHg.

Operative results

Of 28 laparoscopic Nissen funduplications attempted, 24 were successfully completed laparoscopically (85.7%).

The mean operating time was 120.6 ± 11.4 ranged from 90 to 200 minutes. The time taken to complete the procedure decreased significantly as experience improved. The mean operating time for the last 5 cases was 95 ± 6.6 minutes. Intracorporeal knot tying was used in the first 10 cases (35.7%), whereas extracorporeal knot tying was used in 14 cases (50%), leading to reduction in operating time.

The mean postoperative hospital stay was 3.1 ± 0.2 days ranged from 3 to 7 days for completed laparoscopic funduplications. There were no perioperative deaths. All patients were able to return to normal activity within 3 weeks of laparoscopic surgery.

The effectiveness of surgery was evaluated by patient responses to the preoperative symptom scoring and to additional questions addressing the patients overall satisfaction with the surgical result.

The mean heartburn score of patients undergoing surgery was 2.68 ± 1.26 before operation, 0.24 ± 0.63 after the operation by one month and 0.35 ± 0.79 after the operation by one year ($P < 0.01$). One year after operation, 15 patients were available for follow up, only one patient (6.66%) had frequent heartburn and had abnormal results of 24-hour pH studies (Fig. 6).

Regurgitation was scored as 2 or greater in 14 patients (50%) before operation. One year after operation only one patient (6.66%) reported regurgitation (score, >2) ($P < 0.001$).

The mean preoperative dysphagia score was 1.1 ± 0.9 . Postoperatively, the mean dysphagia score was 0.55 ± 0.8 at 4 weeks and 0.32 ± 0.21 at one year ($P < 0.01$). Although dysphagia was decreased, on the overage, 10 patients (35.7%) reported new onset dysphagia with a score of 2 or more. Endoscopic dilatation was performed in 4 patients (14.3%) and dietary counseling was sufficient in 5 patients (17.8%). Only one patient reported severe dysphagia (score 3) 1 year after operation and reoperation was done.

Frequent atypical symptoms present in 8 patients (28.6%) with heartburn before operation were improved by operation in 6 of 8 patients (75%) ($P < 0.05$).

Causes of conversion to open funduplication were listed in (Table 1).

Table (1): Causes of conversion to open funduplication

<i>Cause</i>	<i>No</i>	<i>(%)</i>
1- Esophageal perforation	1	(3.5)
2- Gastric perforation	1	(3.5)

3- Bleeding from short gastric vessels	1	(3.5)
4- Inadequate dissection of the posterior window	1	(3.5)

The four cases of conversion were early in the series (case 1,3,4 and 8).

The operative complications were listed in (Table 2). In the early experience, a small gastric perforation in one case (3.57%) and an esophageal perforation in another case (3.57%) were repaired immediately after conversion to open procedures with uneventful recoveries. Pneumothorax occurred in two cases (7.15%) and did not interfere with the laparoscopic procedures. No chest drains were required. Bleeding from a short gastric vessel required conversion to the open procedure in one patient. The need for conversion to open procedure occurred in 4 cases (14.3%).

Postoperatively, two patients developed deep venous thrombosis (7.1%) and treated by heparin and oral anticoagulation for 3 months. One patient (3.6%) required nasogastric suction for 6 days for a prolonged ileus, and another had a pneumonia, which resolved with antibiotic therapy (Table 3).

Table (2): Operative complications

Complication	NO	%
Gastric and esophageal perforation	2	7
Pneumothorax	2	7
Bleeding from short gastric vessels	1	3.5

Table (3): Post operative complications

	NO	%
Deep venous thrombosis	2	7.1
Paralytic ileus	1	3.6
Pneumonia	1	3.6
Gas bloating	2	7.1

Two patients underwent open surgery within one year as a result of poor outcomes from the laparoscopic procedure. One was for recurrent reflux, and the second for severe dysphagia. Early troublesome dysphagia for solids lasting more than 3 months, was experienced by 9 patients (32.2%), excluding 1 patient (3.5%) who reoperated on for this problem. The dysphagia had resolved in 5 patients (17.8%) by dietary counseling. Endoscopic balloon dilatation was required in 4 patients (14%).

Gas bloat was reported in 2 patients (7%), but no patient had sufficient bloating to warrant take down of the fundoplication

The outcome of our initial experience with patients at greater than 3 months follow up is evaluated . Twenty seven of 28 patients are free of reflux symptoms; 22 patients have undergone laparoscopic surgery alone. Four patients who have undergone conversion to open surgery also are free of reflux symptoms. One patient continues to have symptoms of gastroesophageal reflux disease, and another continues to have dysphagia for solids. Clinical follow up has ranged from 3 to 12 months (mean 12 + 2.3 months).

Follow-up esophageal manometry and 24-hour pH studies. Eighteen patients volunteered to have repeat esophageal manometry and eleven patients agreed to 24-hour esophageal pH studies, 3 to 12 months after surgery. The results of these studies were shown in figures 7 and 8. There was a significant increase in resting pressure of the lower esophageal sphincter, with a significant decrease in its intrathoracic length and increase in its intra-abdominal length (P<0.0001). The postoperative lower esophageal sphincter pressure was in the normal range. The mean total time with pH < 4 fell from 18.9 ± 22 % preoperatively to 3.7 + 7% postoperatively) (P<0.01). There was evidence of abnormal acid exposure in the esophagus in one of 11 patients after surgery. The only one who tested positive was operated upon again for recurrent reflux disease.

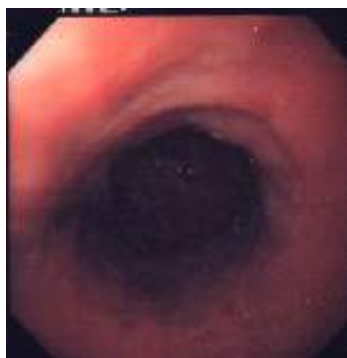


Fig. (1): Endoscopic view of hiatus hernia with incompetent cardia and linear erosions.

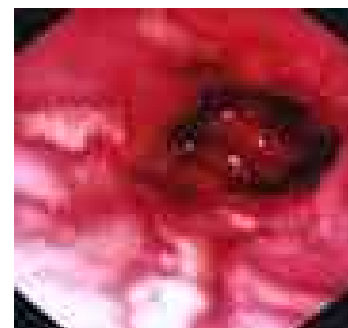


Fig. (2): Endoscopic view showing longitudinal ulcerations with reflux esophagitis

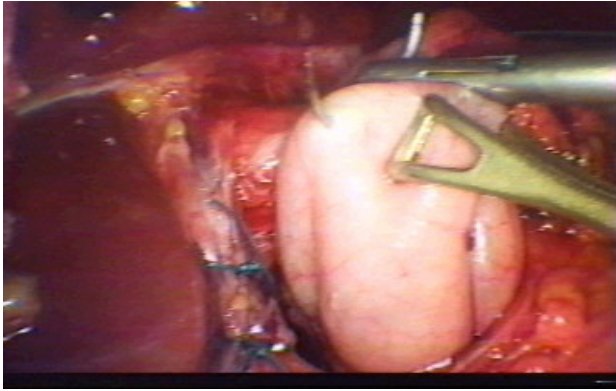


Fig. (3): The contiguous part of the fundus was used for fundoplication



Fig. (4): Interrupted prolene sutures to secure the fundoplication.

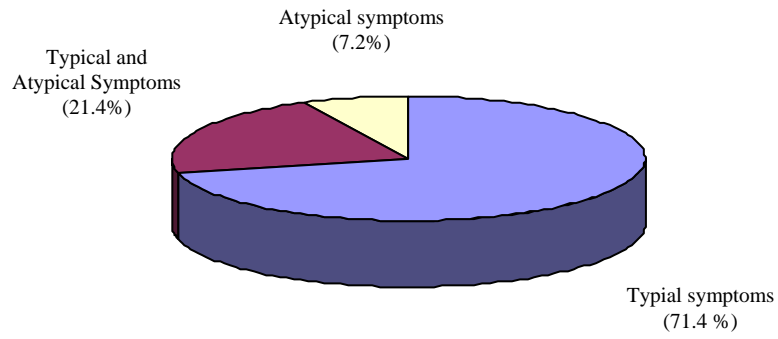


Fig. (5): Symptoms of patient population

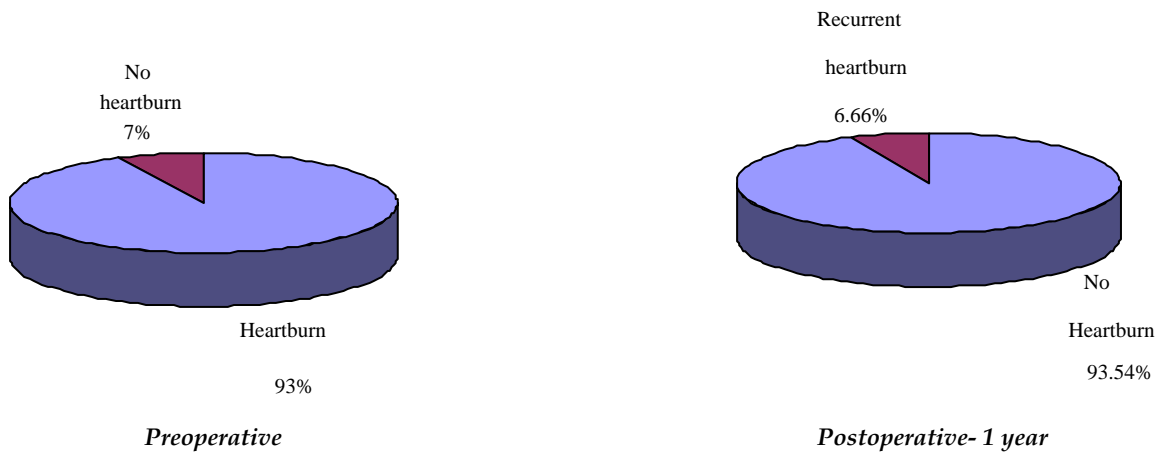


Fig (6): Heartburn response to laparoscopic Nissen fundoplication

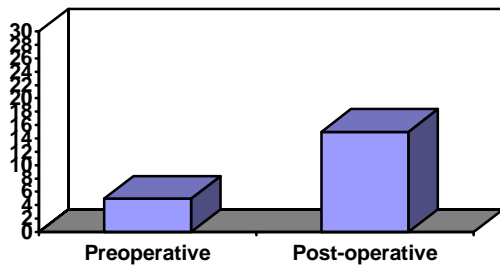


Fig. (7): Lower esophageal sphincter manometry (mmHg + SD) before and after laparoscopic Nissen fundoplication, showing a significant increase in resting sphincter pressure after the procedure. The 2.5th - 97.5th percentile for normals lies between 6-28 mmHg. * $P < 0.0001$ versus pre-op.

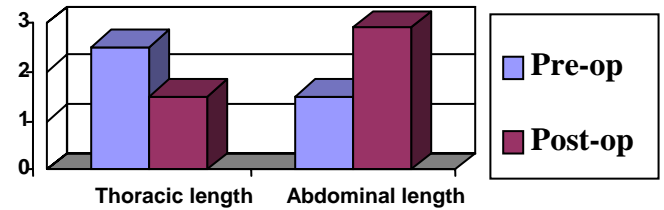


Fig.(8): Length of the lower esophageal sphincter before and after laparoscopic Nissen fundoplication, showing a significant decrease in the intrathoracic length, with a significant increase in the intra-abdominal length after surgery. * $P < 0.0001$ versus pre-op

DISCUSSION

The medical management of gastroesophageal reflux disease often is ineffective, most patients who respond to initial medical therapy relapse after one year⁽¹⁵⁾, because it does not address the major underlying problem, which is a mechanically ineffective antireflux barrier at the lower esophagus^(15,16).

The comparison of medical and surgical therapy indicated the superiority of surgical therapy in controlling this disease⁽¹⁷⁾.

Visualization of the oesophageal hiatus and of the posterior wall of the oesophagus is poor with laparotomy, irrespective of the incision used. The obesity of most patients suffering from GERD only accentuates the problems of adequate exposure. At laparoscopy, however, dissection of the oesophageal hiatus is facilitated by the magnified image, which can demonstrate the entire dissection including that of the back wall of the oesophagus⁽⁵⁾. Other advantages were the lower results of wound sepsis, pulmonary complications, deep venous thrombosis, incisional hernias and rapid return to normal activities with shorter hospitalization and less pain^(5,16).

This study has shown the ability to perform a conventional Nissen fundoplication using the laparoscopic approach in 24 of 28 patients (85.7%). The early results after this procedure were good as those reported for the open procedure, because exactly the same procedure was carried out in both. The operative mortality of 0% is similar to many studies of the Nissen fundoplication in which

mortality rates range from 0 to 2%.

There are always arguments as to whether short gastric vessels should be divided routinely^(7,9) or only when necessary to achieve a loose wrap⁽¹⁸⁾. Dallemagne⁽¹⁹⁾ describes division of these vessels, although we have not found this necessary except in 3 of our patients (10.7%). Likewise, Geagea⁽²⁰⁾ found it unnecessary to divide short gastric vessels when constructing a loose Nissen fundoplication laparoscopically. Watson⁽²¹⁾ found that the division of short gastric vessels did not improve any clinical or objective postoperative outcome. In our study, the division of SGVs was done if a loose wrap of the fundus can not be constructed.

The current study demonstrates the feasibility of performing a Nissen fundoplication laparoscopically. The technique has undergone some minor modifications for enabling considerable improvements in operating time. The most significance factor reducing the time taken for fundoplication was a change from intracorporeal to extracorporeal knot tying. This is similar to results of Jamieson⁽¹⁸⁾ who believe that with experience and the use of extracorporeal knot tying, it is feasible to perform a laparoscopic Nissen fundoplication in the great majority of cases in 60 to 120 minutes.

Also, the use of a tape placed around the esophagus at an early stage has facilitated dissection of the posterior esophagus because it enables the esophagus to be lifted forward for direct vision of the retroesophageal space. This enables the creation of a large window behind the esophagus and visualization of the pillars of the hiatus from

the right side of the esophagus to facilitate posterior hiatal repair, if required.

Furthermore, it is clear that certain features are not easy to judge laparoscopically. For instance, we have not yet learned to judge the width of the hiatus; thus, we are not certain which patients require hiatal closure remains an open question for laparoscopic fundoplication, as it does for open fundoplication..

The success rate of laparoscopic Nissen fundoplication is high exceeding 90% in many series^(8,15,22,23,24). The success rate of the current study was (85.7%). The failed cases were the early cases during the start of the learning curve.

Anvari⁽²²⁾ reported a mean + SD length of operating time 69.9 +2.4 minutes and mean + SD hospital stay 2.7 + 0.1 days.

In the present study the mean + SD operating time was 120.6 +2.4 minutes and mean + SD hospital stay was 3.1 + 0.2 days. The main reasons of prolonged operating time in the present study were: the time consuming intracorporeal knot tying used in the first 10 cases and the technique was challenging at the start of this study due to early experience.

Postoperative pain was minimal because surgical trauma on the abdominal wall and retraction of costal margin are greatly reduced compared with the open procedure. On the first day postoperatively all patients were out of bed and walking, complaining only of the discomfort caused by the nasogastric tube. This early ambulation probably improves the pulmonary function⁽⁵⁾. In the present study, the incidence of major complications was low and no deaths were reported. This was similar to other studies^(9,18).

Although follow up has not exceeded 12 months, the clinical results are promising. In the present study, one patient developed recurrent reflux symptoms. The size of the hiatal hernia at the time of the initial surgical procedure was large (4cm). Funduplications performed in the presence of large hiatal hernias were three time, more likely to fail than those with negligible or no hiatal hernias. This difference may be related to anatomic shortening of the esophageus, inadequate mobilization of the esophageus, or a combination of these two factors leading to axial tension on the gastroesophageal junction^(25,26,27).

Dysphagia that fails to resolve is troublesome⁽²⁸⁾. Postoperative dysphagia was a problem early in the present study. Our response was to start performing full fundus mobilization on all patients with this technical adaptation and dietary counseling before hospital discharge, troublesome dysphagia has been reduced. Endoscopic balloon dilatation has been used in a subgroup of patients with no identified cause of dysphagia^(29,30). This was done in

our study and some patients required multiple sessions of endoscopic dilatation. The dilatation was successful in those with normal peristalsis and an intact fundoplication. Troublesome dysphagia due to anatomical problems are best to be corrected surgically^(31,32).

In the present study, one patient required reoperation for severe dysphagia. Hiatal stenosis was the cause and the last stitch was removed and the dysphagia improved postoperatively. The fundoplication was left intact and this was consistent with the results of Watson⁽³²⁾, who reported that in case of hiatal stenosis, the fundoplication could be left intact.

CONCLUSION

Laparoscopic Nissen fundoplication is a promising technique because it is safe with low perioperative morbidity rate and short hospital stay. The short term functional results shows the effectiveness of the technique in controlling the gastroesophageal reflux disease. Long term results should be studied.

REFERENCES

1. Patrick G., Jackson, Michael A., Gleiber, Reza Askari, Stephen Evans. Predictors of outcome in 100 consecutive laparoscopic antireflux procedures. *Am J Surg* 2001; 181: 231-235.
2. Revicki DA., Wood M., Maton PN. Sorensen S.; The impact of gastroesophageal reflux disease on health -related quality of life. *Am J Med* 1998; 104: 252-8.
3. Grande L., Toledo V., Manterola C.; Value of Nissen fundoplication in patients with gastroesophageal reflux judged by long term symptom control. *Br J Surg* 1994; 81: 548-50.
4. DeMeester TR., Bondvina L., Albertucci M.; Nissen fundoplication for gastroesophageal reflux disease: evolution of primary repair in 100 consecutive patients. *Ann Surg* 1986; 204: 9-20.
5. Cadere GB, Houben JJ, Bruyns J, Himpens J, Panzer JM and Glin M: Laparoscopic Nissen fundoplication: technique and preliminary results. *Br. J Surg* 1994; 81: 400-403.
6. Campos GM., Peters JF., DeMeester TR.; Multivariate analysis of factor predicting outcome after laparoscopic Nissen fundoplication. *J Gastrointest Surg* 1999; 3: 292-300.
7. Hunter JG., Smith CD., Branum GD., Waring JP., Trus TL., Cornwell M.; Laparoscopic fundoplication failures: patterns of failure and response to fundoplication revision. *Ann Surg* 1999; 230: 595-606
8. Kahrilas PJ.; Laparoscopic antireflux surgery: silver bullet or the emperor's new clothes? *Am J Gastroenterol* 1999; 94: 1721-2.

9. Watson DL, Devitt PG, Jamieson GG; The changing face of treatment for hiatus hernia and gastro-esophageal reflux. *Gut* 1999; 45: 791-2.
10. Hunter JG., Trus TL., Branum GD., Waring JP., Wood WC.; A physiologic approach to laparoscopic fundoplication for gastroesophageal reflux disease. *Ann Surg* 1996; 223: 673-687.
11. Rattner DW., Brooks DC.; Patient satisfaction following laparoscopic and open antireflux surgery. *Arch Surg* 1995; 130: 289-94.
12. Hinder RA., Filipi GJ., Wetscher G., Neary P., DeMeester TR., Perdakis G.; Laparoscopic Nissen fundoplication is an effective treatment for gastroesophageal reflux disease. *Ann Surg* 1994; 220: 472-383.
13. Weerts JM., Dallemagne B., Hamoir E.; Laparoscopic Nissen fundoplication; detailed analysis of 132 patients. *Surg laparosc. endosc* 1993; 3: 359-364.
14. El-Serag HB., Sonneberg A.; Outcome of erosive reflux esophagitis after Nissen fundoplication. *Am J Gastroenterol* 1999; 94: 17771-6.
15. Tytgat GNJ; Non-radiological investigation of the esophagus. In: Watson A, Celestin LR (eds). *Disorders of the esophagus*. London: Pitman 1993, 24-36.
16. Hinder RA., Charles JF., DeMeester TR. and Galen Perdakis; Laparoscopic Nissen fundoplication is an effective treatment for gastroesophageal reflux disease. *Ann Surg* , 1994;220, 472-83.
17. Spechler SJ; Comparison of medical and surgical therapy for complicated gastroesophageal reflux disease in veterans. *N Engl J Med*; 326: 786-792; 1992.
18. Jamieson GG., Watson DL., Jones RB., Mitchell PC. and Anvari M.; Laparoscopic Nissen fundoplication. *Ann Surg*, 1994; 220: 137- 145.
19. Dallemagne B, Weerts JM, Jehacs C, et al.; Laparoscopic Nissen fundoplication: preliminary report. *Surg Laparosc Endosc* 1991; 1:138-143.
20. Geagea L; Laparoscopic Nissen's fundoplication: preliminary report on ten cases. *Surg Endosc* 1991; 5:170-173.
21. Watson DI, Pike GK, Baigrie RJ, et al.: Prospective double-blind randomized trial of laparoscopic Nissen fundoplication with division and without division of short gastric vessels. *Ann Surg*, 1997; 226: 642-652.
22. Anvari M, Allen c and Borm A: Laparoscopic Nissen fundoplication is a satisfactory alternative to long-term omeprazole therapy. *Br. J Surg* 1995; 82; 938-942.
23. O'Hanrahan T, Marples M, Bancewi J, : Recurrent reflux and wrap disruption after Nissen fundoplication: detection, incidence and timing. *Br. J. Surg* 1990; 77, 545-547.
24. Watson DI, Baigrier RJ, Jamieson GG: A learning curve for laparoscopic fundoplication. Definable, avoidable, or a waste of time? *Ann Surg* 1990 , 224, 198-203.
25. Soper NJ, Dunnegan D: Anatomic fundoplication failure after laparoscopic antireflux surgery. *Ann surg* 1999; 229: 669-677.
26. Johnson AB, Oddsdottir M, Hunter JG: Laparoscopic collis gastroplasty and Nissen fundoplication. *Surg Endosc* 1998; 12: 1055-1060.
27. Jobe BA, Horvath KD, Swanstrom LL: Postoperative function following laparoscopic collis gastroplasty for short esophagus. *Arch Surg* 1998; 133: 867-874.
28. Wills VL, and Hunt DR: Dysphagia after antireflux surgery. *Br. J. Surg* 2001; 88: 486-499.
29. Gaudric M, Sabate JM, Artru B, Chaussade S: Results of pneumatic dilatation in patients with dysphagia after antireflux surgery. *Br J Surg* 1999; 86: 1088-91
30. Wo JM, Trus TL, Rischardson WS, Hunter JG, Barnum GD, Mauren SJ: Evaluation and management of post fundoplication dysphagia. *Am J Gastroenterol* 1996; 91: 2318-22.
31. Horgan S, Pohl D, Bogetti D, Eubanks T, Pelligrini C: Failed antireflux surgery: what have we learned from reoperations? *Arch Surg* 1999; 134: 809-17.
32. Watson DI, Jamieson GG, Mitchell PC, Devitt PG, Britten-Jones R: Stenosis of esophageal hiatus following laparoscopic fundoplication. *Arch Surg* 1995; 130: 1014-16.