

MATHIUE & SNODGRASS; COULD BOTH BE COMBINED?

By

El-Desouki M. and Khairi A.

Pediatric Surgery Department, Alexandria Faculty of Medicine, Alexandria, Egypt.

Objective: *To review a new technique for correcting distal-to-mid penile hypospadias where we combined both Mathiue' & Snodgrass techniques.*

Material & Methods: *From May 2000 to May 2001, 10 boys (mean age= 6years) were treated for mid-to-distal penile hypospadias at the pediatric surgery unit, Alexandria faculty of medicine using a new technique where we combined both Mathieu and Snodgrass techniques.*

After the two parallel incisions on both sides of the urethral plate were made, they were carried out proximally for an equal distance to that one from the urethral meatus to the glans tip. The urethral plate was incised as usual in Snodgrass and the proximal flip flap raised and sutured to the edges of the urethral plate as usual in Mathiue. The width of the proximal flap was as little as 5 mm. A second layer from the prepuce subcutaneous tissue or from local tissue were laid over the tube which was stented with an 8 or 10 Fr soft tube for 5-7 days. The mean follow up was 6 months.

Results: *The 10 boys were stented; 2 for 5 days and 8 for 7 days. 3 cases (30%) developed a urethro-cutaneous fistula. 4 cases (40%) were already circumcised and 6 (60%) were circumcised during the same procedure. 2 cases (20%) developed meatal stenosis and one case (10%) had partial repair disruption.*

Conclusion: *Combined Mathiue and Snodgrass repair for correction of Mid-to-distal penile hypospadias is a reliable method. It suits cases where the urethral plate is narrow and at the same time allows the use of a smaller flip flap when the proximal skin condition does not allow for the usual flap size.*

Keywords: hypospadias, Mathieu, Snodgrass, Tubularized incised plate, TIP.

INTRODUCTION

Hypospadias is a congenital defect thought to be caused by incomplete fusion of the urethral folds, resulting in a proximally located urethral meatus anywhere from the glans to the perineum.⁽¹⁾ The prevalence of hypospadias has been reported to range from 4.7 to 8 per 1000 male births.^(2,3) This dictates that every pediatric surgeon frequently confronting hypospadias and its different types. The hypospadias correction remains one of the most challenging problems in pediatric surgery. In all commonly used classification systems, glanular, coronal and subcoronal (anterior) and distal penile and midshaft, and proximal penile (middle) defects constitute the great majority of all hypospadias.⁽⁴⁾ These rates are approximately 50%, 30%, and 20% for anterior, middle and posterior (penoscrotal, scrotal and perineal) hypospadias, respectively. The modern-day objectives of hypospadias

surgery are; complete straightening of the penis, positioning of the meatus on the penile tip, normalization of voiding and erection, creation of a urethra of uniform caliber and symmetrical appearance of the glans and shaft.⁽⁵⁾

Multiple operations have been described for repairing distal hypospadias. All methods offer a good cosmetic result and low complication rate. Recent methods have attempted to improve further the cosmetic appearance, particularly as it relates to meatal conformation. Snodgrass described a form of urethral tubularization with longitudinal incision of the urethral plate to create an elliptical meatus.⁽⁶⁾ This is a modification of the Thiersch-Duplay urethroplasty, in which the urethral plate is circumscribed and tabularized.

Snodgrass modification was to incise the urethral

plate prior to tubularization in order to allow a larger caliber urethra. To prevent fistulae, a transverse island of dorsal subcutaneous tissue is mobilized to cover the repair. Deepithelialized local skin flap to cover a tabularized incised plate, has been described and claimed to give an excellent cosmetic and functional result.⁽⁷⁾ meatal-based vascularized flap (Mathieu) repair is a suitable option for subcoronal or distal penile hypospadias without chordee.^(8,9)

Urethral fistulae are probably the most common complication of hypospadias repairs. Tissue ischemia is the most important factor to be blamed. Complications could be minimized with proper selection of an operation properly tailored to the individual's anatomy.⁽¹⁰⁾ Regardless of the type of surgery used, meticulous surgical technique and proper handling of delicate tissues are necessary for desired results. We present a technique, where a combination of both Mathieu and Snodgrass was used

PATIENTS AND METHODS

From May 2000 to May 2001, 10 boys (mean age=6years) were treated for mid-to distal penile hypospadias at the pediatric surgery unit, Alexandria faculty of medicine using a new technique where we combined both Mathieu and Snodgrass techniques.

Following anaesthetic induction, a traction suture of 5-0 prolene is placed in the glans penis. An equal distance from the urethral meatus to the glans tip is measured on the proximal penile shaft skin.

Typically, a width of 8 mm is measured for the proximal flap. However, in this technique, and as urethral

plate will be incised, the flap could be decreased to as small as 5 mm. A line marked beginning at either lateral margin of the previously marked urethral plate and carried around the dorsal aspect of the penis as a circumcising incision. Skin and glanular incisions are made. Glans wings are incised deeply, the penile shaft skin is developed proximal to the transverse lines of incision. The penile skin proximal to the meatus is mobilized off the urethra in a proximal to distal direction. Every attempt is made to preserve the subcutaneous tissues just lateral to the urethra, which provide much of the blood supply to the meatal-based-flap.⁽⁶⁾ The urethral plate is then incised from the dorsal aspect of the urethral meatus to the glans tip. The perimeatal-based flap is folded over the meatus and bilateral running subcuticular sutures are placed to approximate this flap to the lateral aspects of the urethral plate, thereby, tabularizing the tissues; over 8 Fr silastic catheter; using 6-0 poly lactin suture; thus creating the neourethra. A second layer coverage is performed with dorsal subcutaneous tissue. Urethral maturation, glans approximation, and skin closure are performed.(Figure1)

RESULTS

The 10 boys were stented; 2 for 5 days and 8 for 7 days.3 cases (30%) developed a urethrocutaneous fistula. 4 cases (40%) were already circumcised, where only local ventral tissue could be used for a second layer over the tube, and 6 (60%) were not, in which cases prepuce subcutaneous tissue could be used as a second layer cover.

2 cases (20%) developed meatal stenosis and one case (10%) had partial repair disruption.

Table (1): Complications encountered with the technique

<i>Complication</i>	<i>Number</i>
Stenosis	2*
Fistula	3
Disruption (partial)	1

* Improved with dilatation

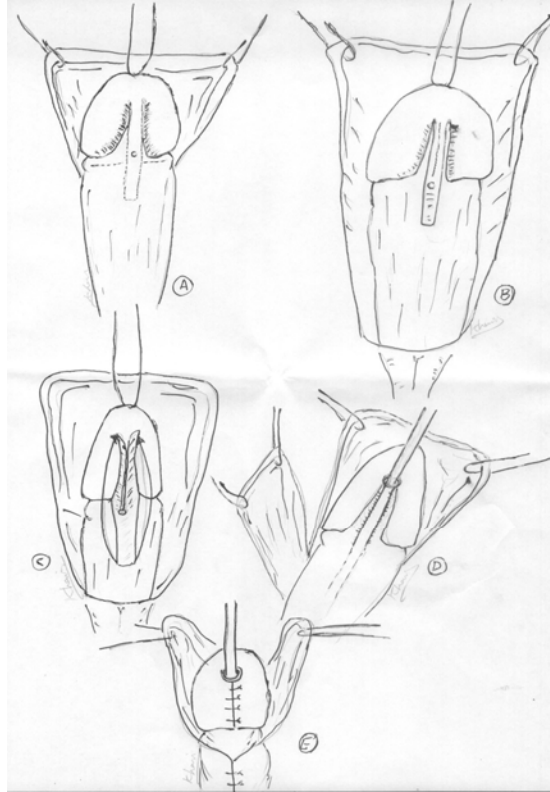


Fig.(1): (A) Vertical parallel lines separate the urethral plate from the glans and carried out proximally for the same length. The horizontal line indicates circumcising incision to deglove the penis. The middle dotted line indicates the incision of the urethral plate from meatus to glans tip. (B) Urethral plate after being dissected from the glans and the shaft.(C) The urethral plate after incision. The bilateral incisions carried proximally to separate the flip-flap from the shaft. (D) The proximal flip-flap is separated and rolled over the urethral meatus and sutured to the lateral edges of the separated urethral plate. Dorsal subcutaneous vascular flap is ready to cover the new tube. (E) Glanuloplasty and skin cover ventrally made easy by dorsal skin slit.

DISCUSSION

A variety of repairs are available for correcting distal hypospadias. The meatal-based flap (Mathieu) repair is a reliable method for correcting distal hypospadias with a low fistula rate. However, it can not be used for boys with distal hypospadias and inadequate ventral skin. Snodgrass described a form of urethral tubularization with longitudinal incision of the urethral plate, aiming at getting a larger caliber urethra.

We present a new technique, where the principles of both techniques are combined, aiming at getting the best out of the two. A deficient ventral skin is the main indication, where a formal Mathieu is not feasible. As the blood supply for the meatal-based flap is from the bilateral subcutaneous tissues on both sides of the urethral plate, as well as the flap pedicle, incising the plate does not interfere with either sources. Forming the tube from three longitudinal parts; namely the two halves of the incised plate and the flip-flap

allows using this technique in cases where the urethral plate is small and the ventral skin is deficient.

Meticulous technique and gentle tissue handling is still a crucial prerequisite as is the case in all types of hypospadias repair. The technique is still for proper evaluation in a large number of cases.

REFERENCES

1. Winslow BH, Devine CJ Jr: Principles in repair of hypospadias. *Semin Pediatr Surg* 1996; 5:41.
2. Khuri FJ, Hardy BE, Churchill BM: Urologic anomalies associated with hypospadias. *Urol Clin North Am.* 1981; 8:565.
3. Sheldon CA, Duckett JW: hypospadias: management principles in *Pediatr urology.* *Pediatr Clin North Am.* 1987; 34:1259

4. Duckett JW: Hypospadias. In Walsh PC, Retik AB, Vaughan ED Jr, Wein AJ (eds): *Campbell's Urology*, ed 7, vol Philadelphia, WB Saunders, 1998, p2093.
5. Keating MA, Duckett JW: failed hypospadias repair. In Cohen MS, Resnick MI(ed): *Re-operative Urology*. Philadelphia, WS Saunders, 1995, p187.
6. Snodgrass W: Tubularized incised urethroplasty for distal hypospadias. *J Urol*. 1994; 151:464- 465.
7. Jonathan H. Ross, Robert Kay: *J urol* 50 (1), 1997.
8. Mathieu P: Traitement en un temps de l'hypospadias balanique an juxta-balanique. *Chir (Paris)*. 1932; 39:481.
9. Retik AB, Mandell J, Bauer SB and Atala A Meatal based hypospadias repair with the use of a dorsal subcutaneous flap to prevent urethrocutaneous fistula. *J Urol* . 1994; 152:1229-1231.
10. Alan B. Retik, Michael Keating, James Mandell: Complications of hypospadias repair. *Urol Clin North Am*. 1988; 15:223.