

Evaluation of Conservative Management of Traumatic Extradural Hemorrhage and Role of Surgery during Follow-up

Mahmoud Mohamed Metwally, Tarek Hassan Abdel-Bary,
Mohamed Reda Abd El Aziz, Hassan Ahmed Abaza

Neurosurgery Department, Faculty of Medicine, Zagazig University, Egypt

*Corresponding author: Mahmoud M. Metwally, Mobile: (+20) 01279520640, Email: magicyya74@gmail.com

ABSTRACT

Background: The most significant accidental head injury complication is extradural hematoma (EDH), requiring to be diagnosed immediately and treated either conservative or surgically.

Objective: The current study intended to assess the effectiveness, prognosis, and results of conservative EDH management.

Patients and methods: This prospective study included 30 patients with EDH who were admitted to Zagazig University Hospitals. The conservative management was performed, only four of the 26 cases that underwent conservative care of EDH during follow-up required surgical intervention.

Results: Patients with Glasgow coma scale score (GCS) 13/15 were 2 cases (6.7%), both cases went for delayed surgical intervention due to increase size of hematoma to surgical volume and deterioration of conscious level. Patients with GCS 14/15 were 7 cases (23.3%); 2 cases went for delayed surgical intervention due to deterioration and the other 5 cases completed their conservative management. Patients with GCS 15/15 were 21 cases (70%). All cases who went for surgical intervention at time when they deteriorate, had improvement for their GCS to be 15/15 with in the first 6 hours postoperatively.

Conclusion: Patients who meet the criteria (volume < 30 mm, thickness 9) may benefit from conservative surgical therapy of their EDH. Successful outcomes are produced by the conservative management, and the advantages of the conservative management of EDH have increased.

Keywords: Traumatic Extradural Hemorrhage; Conservative Management; Follow-up.

INTRODUCTION

Neurosurgical emergencies include EDH. In order to prevent permanent brain damage and death due to hematoma expansion and herniation, it is necessary to perform a prompt surgical evacuation⁽¹⁾. Even with conservative treatment and attentive monitoring, a patient with modest EDH may experience abrupt neurological decline. Even though surgery is the only way to address this problem, many individuals can avoid a craniotomy by carefully monitoring their neurological conditions repeatedly⁽²⁾. Children aged 0 to 3 who have head trauma differ from adults in this regard. Only 1-3% of children who arrive with head trauma get an EDH diagnosis, making it an uncommon finding. Both unintentional falls and blunt head trauma are the most common causes of head trauma in children. The middle meningeal artery accounts for 73% of the EDH bleeding, which is typically related to temporal bone fractures. Venous bleeding can also occur from ripping venous dural sinuses, emissary veins, or venous lakes inside the dura mater⁽³⁾.

The majority of traumatic venous EDHs happen in youngsters, and most don't have a connection to a broken skull. Because the dura can separate from the bone structure so easily, EDHs are frequently found in the temporal-parietal region; regions of dural detachment⁽²⁾.

The treatment of epidural hematomas is based on clinical and brain imaging criteria, such as GCS score, pupillary size, volume, thickness, and mass effect detected on CT scan, as well as the neurosurgeon's personal experience. The specific management of these

lesions was not fully established and proposed in class I or II evidence-based guidelines⁽⁴⁾.

Therefore, this study aimed to evaluate the efficacy, prognosis, and outcome of conservative management of EDH and also, to define the requirement and criteria of delayed surgical intervention.

PATIENTS AND METHODS

This prospective cohort study was carried out at Zagazig University Hospitals' Department of Neurosurgery, Faculty of Medicine, and included patients with EDH. Presuming that every case that satisfies the inclusion and exclusion criteria was included over the six-month study period (five instances per month). Consequently, 30 cases made up the complete sample. The 95% confidence interval and 80% research power were used to determine sample size.

Inclusion criteria:

Patients had a CT scan diagnosis of EDH. The hematoma's diameters were less than 30 cc, its thickness was less than 15 mm, and its midline shift was less than 5 mm. GCS lied in the (13-15/15) range.

Exclusion criteria:

Individuals having a GCS below 13. Related brain injuries like ASDH, ICH, or brain contusions. Initial surgical EDH (< 30 cc, midline shift less than 5 mm, thickness < 15 mm). Other criteria that affect conscious level, follow-up interruption, or prognostic affection, such as a major lung contusion requiring sedation and intubation. Patients suffering from

conditions like liver illness that cause blood coagulopathy.

Operational design:

A full history taking, a full general examination, a careful assessment for signs of traumatic sequelae, skull fractures, hematomas, lacerations, CSF otorrhea or rhinorrhea, hemotympanum, and raccoon eyes were performed for each patient. Comprehensive neurological assessment, including a general look at the patient's memory and cognitive abilities, level of consciousness, speech, evaluation of the pupils, motor power, assessment of the cranial nerves, visual field abnormalities, numbness, ataxia, and other cerebellar symptoms and signs of elevated intracranial pressure were all scored on the GCS. Standard laboratory tests were carried out.

CT serial imaging was used to monitor the extent of the hematoma and to assess other neurological impairments, pupillary changes, vital signs, conscious level, and improvement of weakness, if any. The Espersen equation = $a \times b \times c \times 0.5$ was used for determining the volume of the EDH (EDHV), where a, b, and c stood for the hematoma's diameters in the coronal axial, and sagittal planes⁽⁵⁾.

CT brain was the principal investigation for all the patients. When a patient was first admitted, a first CT scan was carried out to look for any signs of a skull fracture, including size, location, midline shift, brain edema, and small hypodense convex inward suspicious lesions. If a patient had their first CT scan performed within six hours of the trauma, a follow-up scan was scheduled within twelve hours, and if the patient had their first CT scan performed after twenty-four hours, it was scheduled within twenty-four hours.

Second follow-up CT scan of the patient's brain was arranged 48 to 72 hours before the patient was discharged to ensure that their status was stable. A second CT scan was performed one week and one month later to monitor the progression and regression of the hematoma in terms of size and density.

Once the diagnosis of expanding extradural hematoma was settled by performing the second CT, conservative treatment was terminated when increased volume and the decision of surgery was taken. The target of surgery was decompression.

At the time of admission and hospital stay, all patients were categorised based on several clinical indicators, treatment modalities, and neuro-radiological findings. In group A: the hematoma needs to be surgically removed right away. The study did not include this group. Patients in Group B were split up as follows: (B-1) patients received conservative care.; and (B-2) Patients, who show signs of EDH on their initial CT scan but who may need surgery as part of conservative management, receive initial conservative treatment.

The (B) group was the primary objective of the study. After admission and a neurological assessment, conservative care got underway. Every patient had a CT scan of their head in addition to having their level of consciousness and pupil size monitored. The patient received supportive and symptomatic care, including IV fluids, PPI, analgesics, and prophylactic antibiotics. If there was a progressive hematoma enlargement, a neurological deficiency manifests, or there is a decline in aware level, surgery would be necessary.

Along with the process of collecting information and documentation, a close observation and monitoring of the cases was carried out. Every patient received normal neurological care in all circumstances, along with either conservative or surgical management. Every patient had routine CT scans performed. After completing follow-up CT brain scans and neurologically stable examinations, patients were released from the outpatient clinic one week and one month later.

The Jannett and Bonds criteria, which include death, vegetative state, severe disability, moderate disability, and satisfactory recovery, were used to calculate the result score based on the Glasgow outcome score. Patients who were severely disabled, vegetative, moribund, or who passed away were grouped together in the poor result group, whereas those with a moderate disability who regained independence (GOS-3, 2 and 1) were deemed to have had a positive outcome.

Ethical approval:

The Ethics Committee of Zagazig University's Faculty of Medicine gave its approval to the project. Prior to filling out an informed consent form, every participant or his caregiver in the study received a thorough explanation of the study's goals. Every phase of the study was conducted in accordance with the Helsinki Declaration.

Statistical analysis:

Data were analyzed using Microsoft Excel software. Data were then imported into Statistical Package for the Social Sciences (SPSS version 20.0) software for analysis. Qualitative data were represented as number and percentage and were compared by Chi-square test. Quantitative continuous group were represented by mean \pm standard deviation (SD), range, median, and interquartile range (IQR). P value was set at <0.05 for significant results and <0.001 for high significant result.

RESULTS

The present study showed that there were 21 (70%) males, 9 (30%) females, the mean age was 19.2 (± 9.7 SD). The most frequent mode of trauma was motor car accident (66.7%). The common age group was between 10-30 years old (**Table 1**).

Table (1): Demographic data and mode of trauma in studied cases.

Demographic data	No.	%
Gender		
Male	21	70
Female	9	30
Mode of Trauma		
Motor car accident	20	66.7
Fall from height	6	20
Isolated head trauma	4	13.3
Age group		
Less than 10 years	10 – 30 years	More than 30 years
5 (16.7%)	21 (70 %)	4 (13.3%)
Age (years)		
Min. – Max.		3 – 43
Mean ± SD.		19.2 ± 9.7
Median (IQR)		17.5

In group B-1, there was 21 (80.8%) had associated skull fracture, while in group B-2, all the 4 patients had associated skull fracture (**Figure 1**).

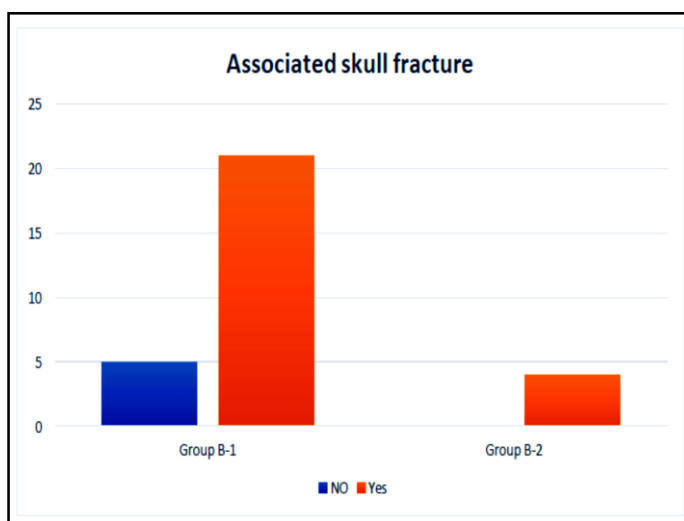


Fig. (1): Associated skull fracture in studied cases.

According to location of hematoma, in group B-1 the most common site was parietal. In group B-2, the most common site was temporal (**Table 2**).

Table (2): Comparison between the two studied groups according to location of hematoma.

Location	Group B-1 (n = 26)		Group B-2 (n = 4)	
	No.	%	No.	%
Frontal	6	23.1	1	25.0
Parietal	13	50	1	25.0
Temporal	3	11.5	2	50.0
Occipital	1	3.8	0	0.0
Temporoparietal	2	7.7	0	0.0
Posterior Fossa	1	3.8	0	0.0

Time from injury to management in group B-1 was 48 hours (± 32.6 SD), while in group B-2 was 18 hours (± 39 SD), in which there was insignificant difference between both studied groups as regards time from injury to management (**Figure 2**).

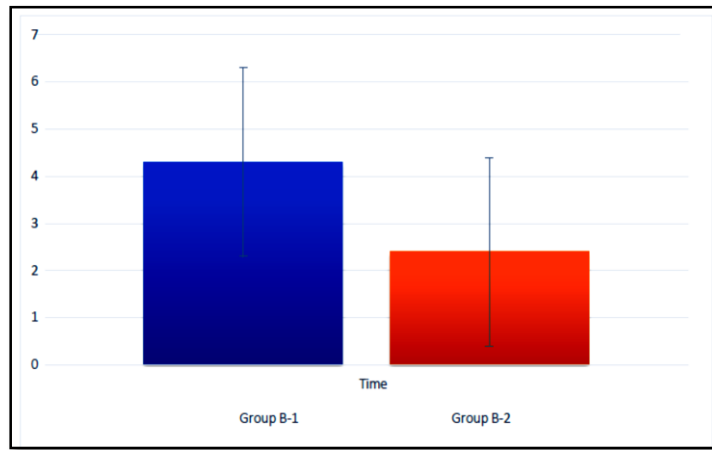


Fig. (2): Comparison between the two studied groups according to time from injury to management

As regards to GCS, in group B-1, there was highly significant difference between both studied groups, as GCS was higher in group B-1 (Table 3).

Table (3): Comparison between the two studied groups according to GCS on admission

GCS	Group B-1 (n = 26)		Group B-2 (n = 4)		Test of Significance	p
	No.	%	No.	%		
13	0	0.0	2	50.0	$\chi^2 = 17.637$	0.001*
14	5	19.2	2	50.0		
15	21	80.8	0	0.0		

χ^2 : Chi square test, *: Statistically significant

There was significant difference between both studied groups as regards thickness of EDH, associated with skull fracture, size of hematoma and midline shift (Table 4).

Table (4): Comparison between the two studied groups according to characteristic of hematoma

Characteristic of Hematoma	Group B-1 (n = 26)		Group B-2 (n = 4)		Test of Significance	p
Thickness of EDH, mm					U= 4.500	0.04*
Min. – Max.	3 – 11		8 – 13			
Mean ± SD.	7 ± 1		9 ± 1.5			
Median (IQR)	6 (4 – 9)		9 (8.5–12.5)			
Associated skull fracture	No.	%	No.	%	$\chi^2 = 0.923$	MC _p = 0.01*
No	5	19.2	0	0.0		
Yes	21	80.8	4	100.0		
Midline shift					$\chi^2 = 15.188$	<0.001*
No	25	96.1	1	25.0		
Yes	1	3.7	3	75.0		
Size of hematoma (initial size)					U= 8.478	<0.001*
Min. – Max.	5 – 15		10 – 22			
Mean ± SD.	7 ± 3.5		18 ± 5			
Median (IQR)	6 (5.5 – 8.9)		15 (14.7–19.5)			

χ^2 : Chi square test MC: Monte Carlo, U: Mann Whitney test; *: Statistically significant, IQR: Interquartile range

All cases were with good prognosis in which Glasgow Outcome Scale was 5, in group B-1 and group B-2 (Table 5).

Table (5): Prognosis of studied cases.

Prognosis	Studied cases	
	No.	%
Good	30	100.0
Bad	0	0.0

DISCUSSION

The most common cause of extradural hemorrhage is a broken temporal or parietal bone that damages the middle meningeal artery or vein, causing blood to pool between the dura and the skull. It usually results from damage to the area of the temple immediately next to the eye, though it can also happen after a dural venous sinus tear ⁽⁶⁾.

This study was conducted on thirty individuals who presented to the emergency department with EDH; 26 of these cases were treated conservatively.

Men represented 21 patients in our study, compared to 9 females out of 30 patients, meaning that men outweigh women by a ratio of 7:3 (70% to 30%). **Duthie et al.** ⁽⁷⁾ stated that 30% of their patients were women and 70% of their patients were men. These outcomes agree with those of our investigation.

Malik et al. ⁽⁶⁾ showed that the ratio of male to female is 4:1. Furthermore, according to **Dubey et al.** ⁽⁵⁾, there are more young male patients than female patients; the male to female ratio for the bulk of patients was 3.5:1.

Five patients (16%) were younger than ten years old, 21 patients (70%) were between the ages of ten and thirty, and four patients (13%) were older than thirty. 19.2 years was the average age. This suggested that those between the ages of 10 and 30 were more vulnerable to trauma, which is consistent with findings from another study by **Bricolo and Pasut** ⁽⁸⁾ that revealed extradural hematoma cases ranged in age from 1 to 75 years, with the age group with the highest frequency being 11 to 20 years.

In this study, there were 20 (66.7%) patients who had motor vehicle accidents, 6 (20%) patients who had falls from a height, and 13.3% of patients who had heavy object injuries. This indicates that MCA is the mechanism of trauma that occurs most frequently, which is consistent with previous authors' findings that road accidents are the main source of injuries, with motorcycle and bus injuries occurring most frequently ⁽⁵⁾.

There were 25 patients (83.3%) who had fissure fracture of their skulls, and 5 patients (16.7%) had no fracture of their skulls. This was not reported in other studies, e.g., **Dubey et al.** ⁽⁵⁾, **Malik et al.** ⁽⁶⁾, and **Duthie et al.** ⁽⁷⁾. We believe that the majority of patients (83.3%) having fissure fractures has a significant impact on EDH. Numerous patients may experience EDH due to fissure fractures, which result in blood accumulating in the extradural space, or from injuries to the vein or MMA.

The hematoma's location in our investigation was as follows: In fourteen patients (46.6%) were found to be in opposition to the parietal area, seven patients (23.3%) to the frontal area (In table 2 there are only 6 cases, 23.1%), two patients (6.7%) to the temporoparietal area, five patients (16.7%) to the temporal area, and one patient (3.3%) to the occipital region. One patient (3.3%) had the post-fossa region on

the other side. Out of the thirty patients who underwent delayed surgical intervention, two (50%) had temporal hematomas, one (25%) had frontal hematomas, and one (25%) had parietal hematomas.

Miller et al. ⁽⁹⁾, stated that the temporoparietal region accounts for 70% of extradural hematomas, with the frontal and occipital regions accounting for 10% and 10%, respectively. This contradicts our findings, as the site in Miller and Satham was primarily in the temporoparietal area due to the presence of a fissure fracture; trauma to the parietal region may cause injury to the MMA or vein, causing EDH opposite the parietal region, or the fissure itself may be the source of the EDH.

Also, **Bricolo and Pasut** ⁽⁸⁾ reported that 49% of cases were temporal in position, 23% were parietal, and 21% were frontal, 4% were in the posterior fossa and 3% were located in the occipital region.

In contrast to frontal or parietal EDH, temporal EDH is less likely to be treated conservatively because it compresses the brain's temporal lobe, which in turn compresses the brain stem ⁽⁸⁾. These findings are consistent with the observation that the majority of our conservative patients were frontal or parietal. Furthermore, three patients in our study who had a temporal hematoma and were receiving conservative care chose to forego immediate surgical operation. This indicates that temporal hematomas are serious conditions that require close observation and radiological follow-up since there is a significant risk of deterioration.

There have been reports of a 4% to 7% incidence of posterior fossa epidural hematomas among intracranial epidural hematomas. Following this, patients having a hematoma larger than 10 millilitres in volume or posterior fossa EDH with low GCS were evacuated. According to **Wong** ⁽¹⁰⁾ conservative management of posterior-fossa EDH may be applied if the EDH volume was only less than 10 ml, the thickness was less than 15 mm, and the midline shift was less than 5 mm. Due to the posterior fossa's low volume, patients deteriorate quickly and develop obstructive hydrocephalus, which is only detectable in thirty percent of cases on CT scans ⁽¹¹⁾.

Two cases (6.7%) of the patients in the current study who had GCS 13/15 underwent delayed surgical intervention because the hematoma's size had increased to the surgical volume and the patient's state of consciousness had declined.

Seven patients (23.3%) had GCS 14/15; two of these instances underwent delayed surgical operation because of deterrence, and the other five cases finished their conservative treatment. 21 cases (70%) of individuals had GCS 15/15. Other studies have found a correlation between a lower GCS and a more unfavourable outcome, including **Pang et al.** ⁽¹²⁾, **Heinzelmann et al.** ⁽¹³⁾, **Mohanty et al.** ⁽¹⁴⁾, and **Kuday et al.** ⁽¹⁵⁾. **Dubey et al.** ⁽⁵⁾ observed that 86% of patients

had a GCS of 13–15, 7% had a GCS of 9–12, and 7% had a GCS of less than 9.

Patients with convexity lesions that do not have a major mass effect or midline shift are increasingly being treated with nonsurgical therapy of mild, asymptomatic EDH. Compared to 86.7% in our analysis, the proportion of patients handled non-surgically in clinical series has actually steadily increased from less than 1% to more than 60% ⁽¹⁶⁾.

Therefore, there are numerous causes of EDH, but the most common one is trauma that results in bleeding from diploic veins, the middle meningeal artery, dural venous sinuses, or bone fractures. The following symptoms are alarming because they may be followed by decelerate rigidity, arterial hypertension, cardio respiratory irregularity, apnea, and death: headache, restlessness, nausea, vomiting, dizziness, confusion, lack of responsiveness, seizures, and ipsilateral oculomotor nerve paresis. These are the clinical criteria to suspect EDH during the period of latency ⁽¹⁶⁾.

CONCLUSION

Surgery is the preferred method of treating EDH, while conservative treatment may also be used in individuals who meet certain criteria (volume < 30 mm, thickness 9) and meet the requirements for appropriate clinical follow-up and repeat CT brain imaging. After six hours, a second CT scan of the brain is required to make sure the EDH did not expand. After 24 hours, a third CT brain scan is performed, a fourth CT brain scan is performed when the patient is discharged, and a follow-up visit is permitted for six months.

Following the patient's GCS and the EDH volume, the conservative management of EDH produces positive outcomes when carried out in accordance with the protocol and careful neurological supervision in a hospital equipped with a CT brain scan.

- **No funding.**
- **No conflict of interest.**

REFERENCES

1. **Erşahin Y, Mutluer S, Güzelbag E (1993):** Extradural hematoma: analysis of 146 cases. *Child's Nervous System*, 9: 96-99.
2. **Zakaria Z, Kaliaperumal C, Kaar G et al. (2013):** Extradural haematoma to evacuate or not? Revisiting treatment guidelines. *Clinical Neurology and Neurosurgery*, 115(8): 1201-1205.
3. **Poon W, Rehman S, Poon C et al. (1992):** Traumatic extradural hematoma of delayed onset is not a rarity. *Neurosurgery*, 30(5): 681-686.
4. **Aromatario M, Torsello A, D'Errico S et al. (2021):** Traumatic epidural and subdural hematoma: epidemiology, outcome, and dating. *Medicina*, 57(2): 125-29.
5. **Dubey A, Pillai S, Kolluri S (2004):** Does volume of extradural hematoma influence management strategy and outcome?. *Neurology India*, 52(4): 443-445.
6. **Malik N, Makhdoomi R, Indira B et al. (2007):** Posterior fossa extradural hematoma: our experience and review of the literature. *Surgical Neurology*, 68(2): 155-158.
7. **Duthie G, Reaper J, Tyagi A et al. (2009):** Extradural haematomas in children: a 10-year review. *British Journal of Neurosurgery*, 23(6): 596-600.
8. **Bricolo A, Pasut L (1984):** Extradural hematoma: toward zero mortality: A prospective study. *Neurosurgery*, 14(1): 8-12.
9. **Miller C, Vespa P, McArthur D et al. (2007):** Frameless stereotactic aspiration and thrombolysis of deep intracerebral hemorrhage is associated with reduced levels of extracellular cerebral glutamate and unchanged lactate pyruvate ratios. *Neurocritical Care*, 6: 22-29.
10. **Wong C (1994):** The CT criteria for conservative treatment—but under close clinical observation of posterior fossa epidural haematomas. *Acta Neurochirurgica*, 126: 124-127.
11. **Roka Y, Kumar P, Bista P et al. (2008):** Role of repeat CT scan head in initially inoperable cases of traumatic head injury. *Nepal Med Coll J.*, 10(4): 225-229.
12. **Pang D, Horton J, Herron J et al. (1983):** Nonsurgical management of extradural hematomas in children. *Journal of Neurosurgery*, 59(6): 958-971.
13. **Heinzelmann M, Platz A, Imhof H (1996):** Outcome after acute extradural haematoma, influence of additional injuries and neurological complications in the ICU. *Injury*, 27(5): 345-349.
14. **Mohanty A, Sastry Kolluri V, Subbakrishna D et al. (1995):** Prognosis of extradural haematomas in children. *Pediatric Neurosurgery*, 23(2): 57-63.
15. **Kuday C, Uzan M, Hanci M (1994):** Statistical analysis of the factors affecting the outcome of extradural haematomas: 115 cases. *Acta Neurochirurgica*, 131: 203-206.
16. **Bejjani G, Donahue D, Rusin J et al. (1996):** Radiological and clinical criteria for the management of epidural hematomas in children. *Pediatric Neurosurgery*, 25(6): 302-308.