

## Outcomes of Complete Pars Plana Vitrectomy with Silicone Oil versus Pars Plana Vitrectomy Alone in Cases of Postoperative Endophthalmitis

Ehab Mohamed Saad \*, Abdelmonem Mahmoud Hamed, and Ahmed Abdelsahfy Tabl

Ophthalmology Department, Faculty of Medicine, Benha University, Benha, Egypt

\* Corresponding author: Ehab Mohamed Saad, Email: [ehab.saad@fmed.bu.edu.eg](mailto:ehab.saad@fmed.bu.edu.eg), Phone: +201008418667

### ABSTRACT

**Background:** Postoperative endophthalmitis is a severe and sight-threatening complication following ocular surgery. Pars plana vitrectomy (PPV) is a common intervention, and the use of silicone oil endotamponade may offer additional benefits.

**Objective:** To compare outcomes of complete PPV with silicone oil endotamponade versus pars plana vitrectomy alone in cases of postoperative endophthalmitis.

**Patients and Methods:** This prospective, randomized, controlled trial included 40 consecutive cases of postoperative endophthalmitis. Patients unresponsive to initial aspiration and intravitreal antibiotics were randomized into two groups: Group 1 (n=20) underwent PPV alone, and Group 2 (n=20) underwent PPV with silicone oil endotamponade. All patients received systemic and fortified topical antibiotics, with follow-up assessments at 1, 2, 4, and 12 weeks postoperatively. Silicone oil was removed from Group 2 eight weeks post-surgery. Primary outcome measures included visual acuity, intraoperative retinal breaks, and postoperative complications such as rhegmatogenous retinal detachment (RRD).

**Results:** The mean age of patients was 52 years, with 22 females (55%) and 18 males (45%). There was no significant difference in visual acuity outcomes between the two groups ( $p > 0.05$ ). However, intraoperative retinal breaks were significantly more common in Group 1 (45%) compared to Group 2 (0%) ( $p = 0.001$ ). Additionally, the incidence of RRD was significantly higher in Group 1 (35%) than in Group 2 (0%) ( $p = 0.008$ ).

**Conclusion:** PPV incorporating primary silicone oil endotamponade yields superior anatomical and functional results in postoperative endophthalmitis cases compared to PPV performed without silicone oil.

**Keywords:** Postoperative Endophthalmitis; Pars Plana Vitrectomy; Silicone Oil Endotamponade; Retinal Detachment; Visual Acuity.

### INTRODUCTION

Endophthalmitis represents a grave complication that may ensue from penetrating ocular injuries [1]. Post-traumatic endophthalmitis constitutes approximately 25% of all cases of infectious endophthalmitis [2]. Roughly 7% of incidents involving penetrating ocular trauma culminate in the onset of endophthalmitis [3].

The therapeutic outcomes of conventional vitrectomy for post-traumatic endophthalmitis have frequently been suboptimal [4]. This is attributable to a confluence of factors, including an increased incidence of polymicrobial infections, the involvement of more virulent and invasive microorganisms, complications arising from the associated penetrating ocular trauma, and the formation of vitreous membranes that can precipitate tractional retinal detachment [5]. These elements collectively contribute to the diminished efficacy of vitrectomy in such cases [6].

Moreover, the contraction of residual peripheral vitreous can precipitate retinal breaks, ultimately leading to retinal detachment. It is well-documented that the prognosis for retinal detachment occurring subsequent to vitrectomy for endophthalmitis remains unfavorable [7].

At present, there are no established evidence-based guidelines delineating the optimal management strategies for acute postoperative endophthalmitis, particularly concerning the utilization of vitrectomy and

silicone oil tamponade [8]. It has been frequently postulated that executing a comprehensive vitrectomy in individuals afflicted with traumatic endophthalmitis may facilitate the meticulous elimination of vitreoretinal traction and the microbial burden within the vitreous cavity [9].

Employing silicone oil endotamponade at the conclusion of vitrectomy may enable a more comprehensive and secure excision of the vitreous base, thereby substantially mitigating the risk of postoperative rhegmatogenous retinal detachment and decreasing the likelihood of retinal detachment arising from undetected breaks in such cases [10].

The aim of this study was to compare outcomes of pars plana vitrectomy with silicone oil versus pars plana vitrectomy alone in cases of postoperative endophthalmitis.

### PATIENTS AND METHODOLOGY

**Study Design:** This investigation was structured as a prospective, randomized, controlled trial.

**Study Population:** The study encompassed a cohort of 40 consecutive cases of postoperative endophthalmitis.

**Randomization:** Patients exhibiting no clinical improvement following initial aspiration and intravitreal administration of vancomycin and ceftazidime were subsequently allocated into two groups through a

randomization process. All surgical procedures were randomly conducted by A.A.T.

**Intervention Groups:**

**Group 1:** Patients in this group underwent pars plana vitrectomy alone. **Group 2:** Patients in this cohort underwent a comprehensive vitrectomy procedure accompanied by silicone oil endotamponade.

**Treatment Protocol:**

All patients were administered systemic and fortified topical antibiotics.

Follow-up assessments were conducted at 1, 2, 4, and 12 weeks postoperatively.

In Group 2, the silicone oil was extracted 8 weeks subsequent to the initial surgery.

**Outcome Measures:**

The primary outcome measures included: visual acuity outcomes at each follow-up visit, incidence of intraoperative retinal breaks and incidence of postoperative complications such as rhegmatogenous retinal detachment.

**Ethical Considerations:**

The study was done after being accepted by the Research Ethics Committee of Benha University. All patients provided written informed consents prior

to their enrolment. The consent form explicitly outlined their agreement to participate in the study and for the publication of data, ensuring protection of their confidentiality and privacy. This work has been carried out in accordance with The Code of Ethics of the World Medical Association (Declaration of Helsinki) for studies involving humans.

**Statistical Analysis**

Data management and statistical analysis were done using SPSS version 26 (IBM, Armonk, New York, United States). Quantitative data were presented as mean, standard deviation (SD), median, and range and were compared by independent t-test. Qualitative data were presented as frequency and percentage and were compared by Fisher's exact test. Statistical significance was determined by a p-value threshold of less than 0.05.

**RESULTS**

**Demographic data**

Regarding the demographic characteristics of the studied groups, there was no significant difference in age and sex. The mean age of all the included patients was 52 and they were 22 females and 18 males (Table 1).

**Table 1: Demographic Data of the studied groups**

	Demographic	Pars plana Vitrectomy Alone (n = 20)	Group 2 (Complete Pars Plana Vitrectomy + Silicone Oil) (n = 20)	Overall (N = 40)
<b>Age, years</b>	Mean (SD)	53 (10.2)	51 (8.8)	52 (9.5)
	Median	52	50	52
	Range	40-65	41-67	40-67
<b>Sex, n (%)</b>	Female	12 (60.0)	10 (50.0)	22 (55.0)
	Male	8 (40.0)	10 (50.0)	18 (45.0)

SD: Standard Deviation.

**Visual acuity outcomes**

The visual acuity outcomes were compared between two treatment cohorts. The difference did not attain statistical significance (Table 2).

**Table 2: Visual Acuity Outcomes**

	Pars Plana Vitrectomy Alone (n = 20)	Group 2 (Complete Pars Plana Vitrectomy + Silicone Oil) (n = 20)	P-Value
Visual acuity $\geq$ 20/400	1 (5%)	2 (10%)	1
Visual acuity <20/400	19 (95%)	18 (90%)	

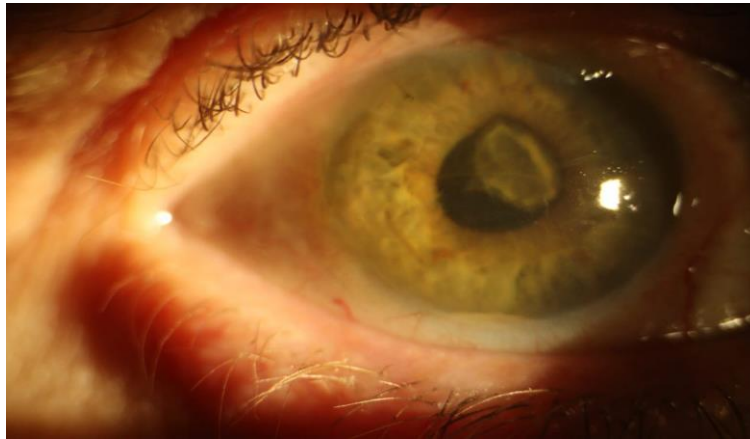
**Surgical and anatomical outcomes**

Table 3 demonstrates that 9 patients in group 1 had intraoperative breaks while group 2 didn't have any. The difference was significant.

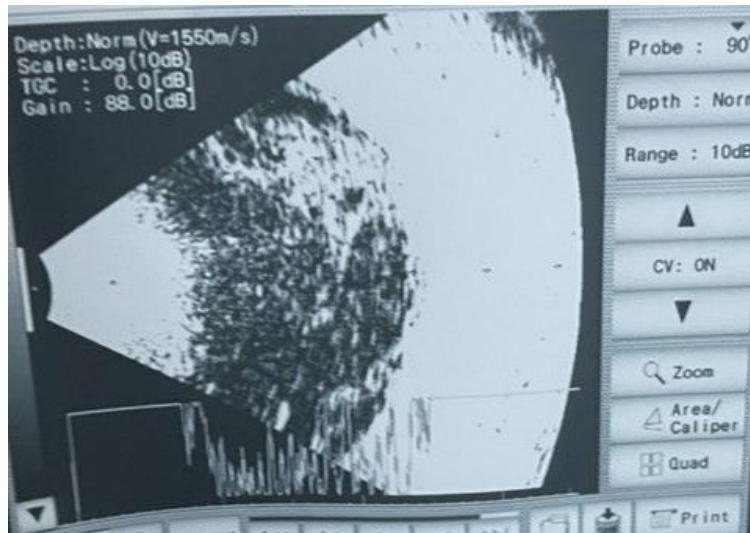
**Table 3: Intraoperative Retinal Breaks**

	Pars Plana Vitrectomy Alone (n = 20)	Group 2 (Complete Pars Plana Vitrectomy + Silicone Oil) (n = 20)	P-Value
Intraoperative breaks	9 (45%)	0 (0%)	0.001
No intraoperative breaks	11 (55%)	20 (100%)	

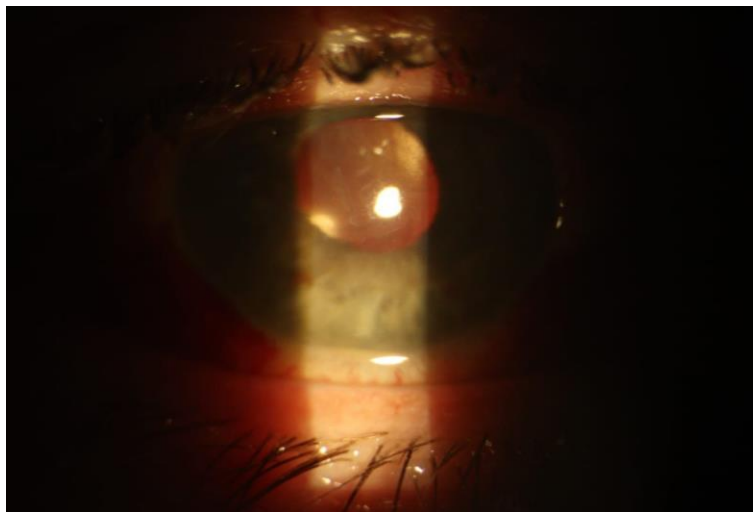**Figure 1** illustrates a case of postoperative endophthalmitis, displaying characteristic signs of infection within the eye. **Figure 2** presents a B-scan ultrasound image of the same case, revealing the extent of the endophthalmitis. **Figure 3** shows the same case 2 weeks after undergoing pars plana vitrectomy with silicone oil endotamponade, highlighting the initial postoperative changes. **Figure 4** captures the same case 12 weeks postoperatively, demonstrating the longer-term outcomes of the intervention.



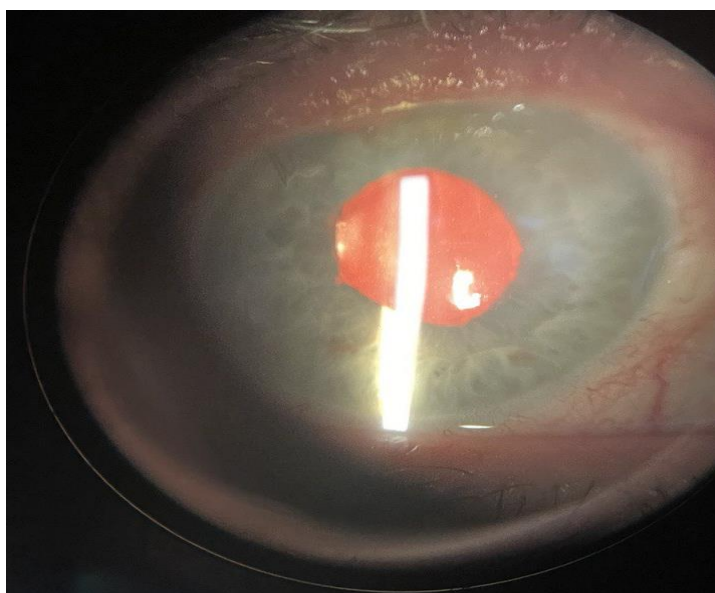
**Figure 1: A photo of a case of postoperative endophthalmitis**



**Figure 2: A B-scan of a case of postoperative endophthalmitis**



**Figure 3: A photo of the same case 2 weeks after pars plana vitrectomy with silicone oil endotamponade was performed**



**Figure 4: A photo of the same case 12 weeks after pars plana vitrectomy with silicone oil endotamponade was performed.**

Table 4 reveals a significant difference in the occurrence of rhegmatogenous retinal detachment (RRD) between the 2 studied groups. No instances of RRD were observed in Group 2.

**Table 4: Comparison of rhegmatogenous retinal detachment (RRD) incidence**

	Pars Plana Vitrectomy Alone (n = 20)	Group 2 (Complete Pars Plana Vitrectomy + Silicone Oil) (n = 20)	P-Value
RRD occurrence	7 (35%)	0 (0%)	0.008
No RRD occurrence	13 (65%)	20 (100%)	

RRD: Rhegmatogenous Retinal Detachment.

## DISCUSSION

The study compared demographic characteristics between two treatment groups undergoing different vitrectomy procedures: Pars plana vitrectomy alone and pars plana vitrectomy + silicone oil. Results showed similar age distributions, with a slightly higher mean age in the pars plana vitrectomy alone group. However, both groups had overlapping age ranges, indicating diversity in age representation. Sex distribution was comparable between the groups, with an equal male-to-female ratio in the pars plana vitrectomy + silicone oil group and a slightly higher female proportion in the pars plana vitrectomy alone group. These findings suggest that both treatment approaches attract similar demographic profiles, providing valuable context for interpreting study outcomes.

**Azad et al.** [9] found comparable demographic characteristics between both groups with similar age distributions and sex ratios. These findings provide valuable context for interpreting study outcomes.

The study meticulously compared visual acuity outcomes between the two studied groups. Notably, 5% of participants in Group 1 achieved a visual acuity of

$\geq 20/400$ , whereas this figure was 10% in Group 2. Despite this apparent disparity, the difference did not reach statistical significance ( $p=1$ ). Predominantly, participants in both groups exhibited a visual acuity of  $<20/400$ , with 95% in Group 1 and 90% in Group 2, underscoring the overall comparability of outcomes between the two treatment modalities.

**Nagpal et al.** [11] observed that the majority of patients initially presented with profound visual impairment, with 84.6% exhibiting a best corrected visual acuity (BCVA) of either hand movement (HM) or positive light perception/projection (LP/PR), and 13.8% displaying CF acuity. At the final follow-up, BCVA improved in 55.4% of eyes: 12.3% achieved a BCVA of 6/18 or better, 13.8% fell between 6/24 and 6/60, and 26.1% retained CF acuity. However, 16.9% experienced a deterioration in vision, and 3.2% required enucleation. For traumatic cases, 90.6% presented with HM/LP/PR, with 45.3% having CF at final follow-up. Overall, 87.5% showed improvement in BCVA at final follow-up.

The current study investigated the occurrence of intraoperative retinal breaks in two studied groups. Notably, 45% of participants in Group 1 experienced

intraoperative retinal breaks, contrasting with no observed breaks in Group 2. This significant disparity ( $p = 0.001$ ) underscores the effectiveness of silicone oil tamponade in reducing the risk of intraoperative retinal breaks. These findings underscore the crucial role of adjunctive techniques, like silicone oil tamponade, in improving surgical outcomes and minimizing intraoperative complications during vitrectomy procedures.

In group 1 of **Nagpal *et al.*'s** <sup>[11]</sup> study, involving silicone oil, 46.2% of eyes had clear media and an attached retina following the primary procedure, while 12.3% were deemed inoperable due to severely fibrosed retina. Additional procedures were required in 24.6% of eyes for persistent infection or retinal detachment (RD), with 16.9% needing further intervention for RD. At the final follow-up, 75.5% of eyes exhibited clear media with an attached retina, while 1.5% were phthisical, 3% had been enucleated, and 20% had a detached retina. Conversely, in Group 2, which did not utilize silicone oil, 86% of eyes achieved clear media and an anatomically attached retina post-primary intervention. A second pars plana vitrectomy (PPV) with silicone oil injection (SOI) was performed in 3.1% of eyes due to persistent infection and in 4.7% for unresolved retinal issues. At the final follow-up, 93.8% of eyes presented with clear media and an anatomically attached retina, whereas 6.2% had a detached retina. Additionally, **Kaynak *et al.*** <sup>[12]</sup> and **Bali *et al.*** <sup>[13]</sup> reported postoperative retinal detachment (RD) in 12.5% and 36% of cases, respectively, for eyes undergoing core vitrectomy alone. In contrast, only 3.5% and 7% of cases, respectively, developed RD following complete vitrectomy with silicone oil tamponade.

**Pinarci *et al.*** <sup>[8]</sup> underscored the antimicrobial efficacy of silicone oil against various pathogens, including *S. aureus*, *S. epidermidis*, *Pseudomonas aeruginosa*, *Candida albicans*, and *Aspergillus* spp. Utilizing pars plana vitrectomy coupled with silicone oil injection can reduce the incidence of retinal detachment by exerting a tamponade effect on the peripheral retina. Reports of endophthalmitis following silicone oil injection are sparse. Furthermore, silicone oil facilitates improved visualization of the fundus during follow-up examinations. Although intravitreal antibiotics were administered initially in all cases, vitrectomy became necessary for all patients due to either worsening conditions or lack of improvement.

**Sinisi *et al.*** <sup>[14]</sup> also determined that the anatomical and functional outcomes of pars plana vitrectomy with silicone oil tamponade were superior to those of vitrectomy alone combined with intravitreal antibiotic injection, especially in cases of post-traumatic or postoperative endophthalmitis, irrespective of the presence of retinal detachment. However, there is a

paucity of data regarding endophthalmitis following intravitreal injections.

**Pinarci *et al.*** <sup>[8]</sup> discovered that silicone oil was also optimal for enhancing fundus visibility during follow-up assessments. While intravitreal antibiotics served as the initial therapeutic approach in all instances, vitrectomy became necessary for every patient due to either clinical deterioration or lack of improvement.

This study has several limitations, including a small sample size of 20 patients per group, which limits generalizability, and a short follow-up period of 12 weeks, which may not capture long-term outcomes and complications. Additionally, being a single-center study, there may be biases related to specific surgical techniques and patient population characteristics. The lack of blinding introduces potential observer bias, and the heterogeneity of endophthalmitis cases was not accounted for, which could influence results. Furthermore, the study did not explore the impact of different adjunctive therapies or variations in antibiotic regimens, nor did it thoroughly investigate potential complications related to silicone oil use, such as increased intraocular pressure or emulsification.

## CONCLUSIONS

In conclusion this study emphasizes the potential advantages of using silicone oil tamponade as an adjunctive technique in vitrectomy for endophthalmitis, highlighting improved anatomical and functional outcomes compared to vitrectomy alone. Mentioning the need for further research and larger-scale studies adds depth to the conclusion, suggesting a direction for future investigations in this field. Overall, it effectively summarizes the main findings and implications of the study.

- **Financial support and sponsorship: Nil.**
- **Conflict of interest: Nil.**

## REFERENCES

1. **Bhagat N, Nagori S, Zarbin M (2011):** Post-traumatic infectious endophthalmitis. *Surv Ophthalmol.*, 56:214-51.
2. **Ma J, Yu Y, Zhong Y *et al.* (2021):** Outcomes and prognostic factors of posttraumatic endophthalmitis: a three-year retrospective study. *J Ophthalmol.*, 2021:5526998.
3. **Sabaci G, Bayer A, Mutlu F *et al.* (2002):** Endophthalmitis after deadly-weapon-related open-globe injuries: risk factors, value of prophylactic antibiotics, and visual outcomes. *Am J Ophthalmol.*, 133:62-9.
4. **Hapca M, Vesa Ş, Nicoară S (2023):** Visual outcomes and prognostic factors of traumatic endophthalmitis treated by pars plana vitrectomy: 11 years retrospective analysis. *J Clin Med.*, 12:353.

5. **Reginatto P, Agostinetti G, Fuentesfria R et al. (2023):** Eye fungal infections: a mini review. Arch Microbiol., 205:236.
6. **Feng X, Li C, Zheng Q et al. (2017):** Risk of silicone oil as vitreous tamponade in pars plana vitrectomy: A systematic review and meta-analysis. Retina, 37:1989-2000.
7. **Ay G, Akhan S, Toker SE et al. (2004):** Comparison of intravitreal ceftazidime and meropenem in treatment of experimental pseudomonal posttraumatic endophthalmitis in a rabbit model. Journal of Applied Research, 4:13.
8. **Pinardi E, Yesilirmak N, Bayar S et al. (2013):** The results of pars plana vitrectomy and silicone oil tamponade for endophthalmitis after intravitreal injections. Int Ophthalmol., 33:361-5.
9. **Azad R, Ravi K, Talwar D et al. (2003):** Pars plana vitrectomy with or without silicone oil endotamponade in post-traumatic endophthalmitis. Graefes Arch Clin Exp Ophthalmol., 241:478-83.
10. **Elwan M, Hagra S, Ellayeh A (2019):** Trimanual versus unimanual 23-gauge vitrectomy in patients with diabetes: Limitations and expectations. Ophthalmic Surg Lasers Imaging Retina, 50:42-9.
11. **Nagpal M, Jain P, Nagpal K (2012):** Pars plana vitrectomy with or without silicone oil endotamponade in surgical management of endophthalmitis. Asia Pac J Ophthalmol (Phila), 1:216-21.
12. **Kaynak S, Oner F, Koçak N et al. (2003):** Surgical management of postoperative endophthalmitis: comparison of 2 techniques. J Cataract Refract Surg., 29:966-9.
13. **Bali E, Huyghe P, Caspers L et al. (2003):** Vitrectomy and silicone oil in the treatment of acute endophthalmitis. Preliminary results. Bull Soc Belge Ophtalmol.,9-14.
14. **Sinisi F, Della Santina M, Loiudice P et al. (2022):** The role of silicone oil in the surgical management of endophthalmitis: A systematic review. J Clin Med., 11:97-9.