



Effects of Acrylonitrile Toxicity in Female Ovary and Teratological Abnormalities in Mice

Fatima J. Abd¹ and Bushra I. Al. Kaisi²

¹ Pathology and Poultry Department, Veterinary Medicine College, Tikrit University, Iraq.

² Pathology and Poultry Department, Veterinary Medicine College, Baghdad University, Iraq.

Abstract

ACRYLONITRILE (ACN) is recognised for its carcinogenic and toxic properties, but its impact on female reproductive health in mammals is poorly understood. This study aimed to elucidate the chronic zoopathological effects of ACN on ovarian function and reproductive hormones in female albino mice (*Mus musculus*), and assess its teratogenic effects in offspring. A total of 70 female albino mice were randomly divided into three groups as follows: Group 1 (n=20) served as a negative control, Group 2 (n=20) administrated ACN at 10.17 mg/kg BW (1/10 of the oral ACN LD50) twice a week orally for 120 days, Group 3 (n=30) administrated the same dose of ACN three times a week orally for 120 days. On days 45, 90, and 120 after ACN exposure, blood samples were collected for to evaluate serum levels of luteinizing hormone (LH), follicle-stimulating hormone (FSH), and oestradiol (E2) using enzyme-linked immunosorbent assay (ELISA) kits. After 120 exposure, Group 4 (n=12) were bred with adult males (n=6) to study teratogenic outcomes. The study found that there were significant reductions at all time points in LH, FSH, and E2 levels ($P < 0.05$) of ACN-treated groups compared with the control, with Group 3 generally showing the lowest levels. Histopathological analysis revealed necrosis, cystic changes, apoptosis, and haemorrhage in the ovaries of Groups 2 and 3. Group 3 offspring exhibited multiple congenital defects including dwarfism, rough skin, limb malformations, and anotia. All neonates from this group died postnatally, exhibited body and tail abnormalities, and presented with kyphosis. In conclusion, ACN exposure significantly impairs reproductive hormone levels and ovarian morphology, leading to severe teratogenic effects. The results of this study indicate that ACN exposure has significant adverse effects on female reproductive function in mice, characterized by reductions in sex hormone levels, infertility, and teratological abnormalities in offspring.

Keywords: Acrylonitrile, female reproductive toxicity, ovarian function, teratogenicity, mice.

Introduction

Acrylonitrile (ACN), a harmful substance [1] commonly known as vinyl cyanide, is a volatile and highly flammable substance widely used in the production of synthetic materials such as fibers, plastics, and resins [2,3]. Chemicals and their by-products can produce reactive oxygen species (ROS) ingested, inhaled, or absorbed, chemical pollutants and their metabolites can have harmful effects [4].

The industrial chemical acrylonitrile is formula (CH₂CHCN) a multisite carcinogen in rats and mice [5]. It causes cancers in the brain, stomach, Zymbal's gland, and Harderian gland four tissues with barrier function. commonly referred to as vinyl cyanide, is an organic substance that is extensively employed in

industry as a monomer for the manufacture of resins and polymers [6,7]. Acrylonitrile is a transparent, colorless, highly flammable, volatile liquid with an odor that is frequently likened to a strong onion and is moderately objectionable [8,9]. Polar cyano groups (ACN) were present in acrylonitrile units, increasing interchain tensions and softening points [10]. Acrylonitrile has two chemically active sites: the carbon-carbon double bond and the nitrile group [11], where it can react in a variety of ways,[7] and it considers one of the most dangerous industrial chemicals that has been widely used to produce a variety of synthetic materials such as drinking glasses, car parts, and appliances [12,13], including fibers, resins, plastics, and rubber [14]. It has also

*Corresponding authors: Fatima J. Abd, E-mail: fatima.abd2207m@covm.uobaghdad.edu.iq Tel.: 07709868051 (Received 14/06/2024, accepted 08/07/2024)

DOI: 10.21608/EJVS.2024.297705.2173

©National Information and Documentation Center (NIDOC)

been discovered that AN applications include nitrile rubbers, surface coatings, organic synthesis, home furnishings, polymers, acrylic and modacrylic fiber monomers, and as a modifier for natural polymers and insecticides [15,16] Acrylonitrile exposure in humans mostly happens by inhalation in work environments or through cigarette smoke [17, 18] oral and cutaneous exposures are rare. Burning plant material, such as biomass, can also release trace amounts [19] of acrylonitrile [20]. Numerous studies have been conducted on the carcinogenicity of acrylonitrile in rodents, and comprehensive epidemiological studies showed [21]. Some ACN investigations showed malformations caused by AN, such as an increased prevalence of tailless or short-tailed fetuses [22]. The total incidence of tailless pups in longer-term reproductive toxicity trials of ACN was too low and inconsistent to conclusively determine any possible link to ACN treatment [23] According to a weight-of-evidence analysis of the developmental toxicity and abnormalities observed in the animal research including ACN, very high maternally toxic exposure [24] levels cause fetotoxicity and may even result in teratogenicity [25].

ACN exposure at work has been linked to immunotoxicity [26] gastrointestinal toxicity, and neurotoxicity, according to studies [27,28]. Epidemiological studies have shown negative effects on reproduction, including sex hormone decrease [29], infertility, and birth abnormalities, after exposure to ACN [30].

In reproductively senescent mice, there was a higher frequency of ovarian atrophy, according to the sole long-term investigation on ACN in mice. More recently, animals given ACN (5–20 mg/kg day for 28 days) showed inflammation [31], apoptosis, and poor oocyte formation in their ovarian follicles [32].

Therefore, the primary aim of this study is to investigate the toxicological impact of ACN on the reproductive system of female mice, with a specific focus on evaluating hormonal levels (follicle-stimulating hormone (FSH), luteinizing hormone (LH), and estradiol (E2)), examining the potential pathological changes in ovarian tissue, and assessing the teratogenic effects on mice pregnancies and offspring.

Material and Methods

Ethics Approval

All procedures in this experiment were reviewed and approved by the local Committee of Use and Care of Animals at the University of Baghdad's Colleges of Veterinary Medicine. Approval Number 746 on April 2, 2024.

Chemicals and Reagents

ACN ($\geq 99\%$ purity, Lot# BCBX3607) was purchased from Sigma-Aldrich, Netherlands. Diethyl ether (C₄H₁₀O, Batch No.: DE383) for anesthesia was sourced from Alpha Chemika, India, and methylene blue for vaginal smear was obtained from Promega, USA. Enzyme-linked immunosorbent assay (ELISA) kits for measuring luteinizing hormone (LH; CEA441Mu), follicle-stimulating hormone (FSH; CEA830Mu), and estradiol (E2; CEA461Ge) were acquired from Cloud-Clone Corp., Wuhan, China.

Animals

In the present study male and female albino mice (*Mus musculus*) (n=76), weighted between 25-30 g and age about 9-10 weeks, were used and placed (n= 10 each cage) in a plastic cage (20×30×50 cm³). Mice were kept in the animal house of the College of Veterinary Medicine at University of Baghdad for 7 days for adaptation at 22 (± 3) °C, 50 (± 5) % relative humidity, and a 14/10-hour light/dark cycle [33]. The plastic cages contained hard-wood bedding and the bedding was changed continuously to ensure a clean environment. The mice were fed standard pellet and tap water *ad libitum*.

Experimental Design

To study the chronic toxicity and potential teratological effect of ACN, the female mice were randomly divided into three groups as follows: group 1 (G1, n=20) was received no ACN, administered distilled water, and considered as a negative control, female mice of group 2 (G2, n=20) were administered twice a week 10.17 mg/kg BW (1/10 of median lethal dose [LD50]) of ACN orally by gavage for 120 days, while mice of group 3 (G3, n=30) were administered the same dose three times a week of ACN orally by gavage for 120 days. After 120 days of ACN exposure, the female mice of G3 (n=12) were exposed to adult males (n=6, not exposed to any level of CAN). Pregnant mice were separated and teratological effects in offspring were reported. The ACN solution was administered freshly after distilled water dilution.

The selection of the ACN dose for this study was considered based on existing literature and aimed to balance between eliciting measurable toxic effects without causing excessive mortality. According to [34], doses used to assess the effects of ACN on various biological markers of female mice were 5, 10, and 20 mg/kg/day for 28-day gavage, with the study design based on previously established protocols, using male mice, by [35]. and further validated by [35]. These studies collectively underscore the suitability of this dose range for observing sub-lethal yet significant toxicological effects in mice. Additionally, the no-observed-adverse-effect levels (NOAELs) for oral exposure were determined to be 10 mg/kg/day [36].

Our choice of 10.17 mg/kg BW as the dose for ACN was positioned within this established range, reflecting a medium exposure level that aligns with Luo et al.'s framework. This dose is particularly relevant as it approximates 1/10th of the oral LD50 (101.68 mg/kg BW), a calculation based on our prior investigation using female mice [37]. This proportion was selected to investigate chronic exposure effects over an extended period without the complication of acute toxicity, thus allowing for the observation of potential reproductive and developmental impacts. Additionally, the review by [38] discussed various studies using different routes of administration (inhalation, drinking water, gavage) to administer ACN, illustrating the diversity in experimental approaches to assess its toxicity. Our decision to use oral gavage is in line with the need for precise dose administration that these studies advocate, particularly when evaluating systemic effects such as reproductive toxicity. Oral gavage ensures that the exact dose is delivered directly to the stomach, minimizing variability that can occur with other methods like dietary mixing or inhalation. Furthermore, [39] highlighted a gap in the literature regarding the specific impacts of ACN on the female reproductive system. By selecting a dose that is significant enough to potentially elicit reproductive toxicity but low enough to avoid acute lethality, our study aims to directly address this gap. The chronic administration schedule over 120 days provides an extended window to observe any delayed or cumulative effects, which is critical given the subtle nature of endocrine and reproductive disruptions.

Blood Sample Collection

Blood samples (about 1 mL/animal) were collected from anesthetized mice using diethyl ether via cardiac puncture on days 45, 90, and 120 post ACN administration. Collected blood was stored in gel tubes, and serum was separated by centrifugation at 3000 rpm for 15 minutes. Serum samples were then stored at -8 °C until analysis [40]

Hormone Analysis

Serum levels of LH, FSH, and E2 were measured using commercially available mouse-specific ELISA kits. Each assay employed a competitive inhibition enzyme immunoassay technique. Briefly, for each hormone, standards and samples were pipetted into pre-coated 96-well plates and incubated with the respective biotinylated detection reagent. After washing, avidin conjugated to horseradish peroxidase (HRP) was added to each well and incubated. Following additional washing steps, the TMB substrate solution was added, and the reaction was stopped with Stop Solution after sufficient color development. The absorbance was measured at 450 nm using a microplate reader. The concentration of each hormone in the samples was then determined by interpolation from the standard

curve generated with known concentrations of the respective hormone.

Pathological Examination

On days 45, 90, and 120, six female mice from each group were randomly selected, anesthetized, euthanized, and ovaries were carefully removed and fixed in 10% neutral buffered formalin for 48 h. The tissue samples were then processed and embedded in paraffin using a Histo-Line Laboratories HESTION TEC2900 system (Italy). Sections of 5 µm thickness were cut using a Histo-Line Laboratories MRS3500 rotary microtome (Italy) and stained with Hematoxylin and Eosin (H&E, Dakocytomation, Denmark). Stained sections were examined under an Olympus light microscope (Japan) at magnifications of ×200 and ×400, and photographed by 17-megapixel microscopic camera (Omax, China) [41].

Teratological Assay

After 120 days of ACN administration, 12 female mice from G4 were mated with six adult male mice to assess the teratological effects of ACN. The pregnant female rats were examined daily after conception, and vaginal smears stained with methylene blue were prepared to detect di-estrus phase. Pregnancy was detected by observation of pale mucous membrane of vagina in the third day after conception [39]

The offspring were monitored for teratological effects using the following parameters:

Prenatal Indices

The number of stillborn, number of live births, and number of absorbed fetuses were recorded.

Congenital anomalies: Developmental abnormalities observed in the offspring according to [42]

Postnatal Indices

Viability index: This index was calculated to evaluate the survival rate of neonates postnatally survived for 4 days or longer [43]. The formula used was:

$$\text{Viability index (\%)} = \frac{\text{Number of neonate surviving for 4 days or more}}{\text{Total number of neonate born}} \times 100\%$$

Lactating index: This index was calculated to evaluate the survival rate of neonates during the postnatal period from day 4 to day 21 of lactation [43]. The formula used was:

$$\text{Lactating index (\%)} = \frac{\text{No. of alive at day 4 - 21 lactating period}}{\text{Total number of neonate alive at day 4}} \times 100\%$$

Body weight and length of offspring: The body weight, length of each pup, and the tail were measured immediately after birth to assess any growth retardation or developmental delays.

Statistical Analysis

Statistical analysis was performed using Statistical Analysis System (SAS) software (version 2018) [44]. A two-way analysis of variance (ANOVA) with the least significant difference (LSD) post-hoc test was employed to compare the means between different experimental groups at $P \leq 0.05$.

Results

Serum Hormone Levels

The effects of ACN on serum levels of LH, FSH, and E2 in female mice were analyzed using a two-way ANOVA. The factors included in the analysis were the day of measurement (day 45, day 90, and day 120) and the treatment group (G1: negative control, G2: ACN twice a week, and G3: ACN three times a week), as well as their interaction. The results are presented in Table 1.

The two-way ANOVA revealed significant main effects of both day ($P < 0.001$) and group ($P < 0.001$) on LH levels, with a significant interaction effect between day and group ($P < 0.001$). Where serum LH levels by day 45 were highest in the G1 (6.55 ± 0.157 ng/mL), and significantly lower in the ACN-exposed groups, with G2 (4.32 ± 0.133 ng/mL) being higher than G3 (2.87 ± 0.0494 ng/mL).

This indicates a dose-dependent reduction in LH levels due to ACN exposure. On day 90, the trend continued with G1 (6.50 ± 0.132 ng/mL) showing the highest LH levels, followed by G2 (4.02 ± 0.0833 ng/mL) and G3 (3.03 ± 0.117 ng/mL).

The LH levels in G2 and G3 were significantly lower than G1, indicating the persistence of the ACN effect over time. By day 120, similar patterns were observed with G1 (6.47 ± 0.15 ng/mL) having the highest LH levels, G2 (3.33 ± 0.0989 ng/mL) lower, and G3 (2.75 ± 0.0764 ng/mL) the lowest ($P < 0.001$). This consistency across days suggests a sustained inhibitory effect of ACN on LH levels.

For serum FSH results, significant effects of day ($P < 0.001$), group ($P < 0.001$), and their interaction ($P < 0.001$) were observed. On day 45 of ACN exposure, serum FSH levels were highest in the G1 (6.23 ± 0.105 ng/mL), with significant reductions in female mice exposed to ACN twice a week (G2: 5.17 ± 0.0615 ng/mL) and three times a week (G3: 2.25 ± 0.0764 ng/mL).

The marked decrease in G3 compared to G2 indicates a stronger effect of more frequent ACN exposure. On day 90, G1 (6.35 ± 0.136 ng/mL) continued to show the highest FSH levels, with G2 (3.23 ± 0.0843 ng/mL) and G3 (2.22 ± 0.0872 ng/mL) significantly lower, demonstrating a sustained effect over time. By day 120, G1 (6.50 ± 0.153 ng/mL) maintained the highest FSH levels, while both ACN-exposed groups, G2 (3.30 ± 0.115 ng/mL) and G3 (1.47 ± 0.27 ng/mL), showed significant reductions, indicating prolonged suppression of FSH by ACN.

In terms of E2, the results revealed that there were significant effects of day ($P < 0.001$), group ($P < 0.001$), and their interaction ($P < 0.001$). Serum E2 levels on day 45 were highest in G1 (47.3 ± 0.091 pg/mL), with significant reductions in G2 (36.6 ± 0.577 pg/mL) and G3 (32.9 ± 0.338 pg/mL), indicating a dose-dependent decrease due to ACN exposure. On day 90, G1 (43.9 ± 0.846 pg/mL) continued to exhibit the highest E2 levels, followed by G2 (34.3 ± 0.549 pg/mL) and G3 (33.0 ± 0.145 pg/mL), showing the persistence of the ACN effect. By day 120, the G1 (47.7 ± 0.154 pg/mL) maintained the highest E2 levels, while G2 (33.8 ± 0.297 pg/mL) and G3 (33.2 ± 0.0931 pg/mL) showed significant reductions, indicating sustained suppression of E2 levels by ACN.

Teratological Results

The teratological effects of ACN exposure were assessed by examining the reproductive outcomes in female mice of G3 and the subsequent developmental characteristics of their offspring. A decrease in fertility was observed, with only 4 out of 12 female mice in G3 becoming pregnant, suggesting a substantial impact on reproductive capacity. The total number of pups born to these pregnant mice was 24, categorized as 8 live pups, 12 dead pups with congenital anomalies, and 4 absorbed fetuses. The postnatal viability and lactation indices for the G4 pups were 0%, signifying that all pups died shortly after birth. This suggests a severe impact on the viability and ability of the pups to survive the neonatal period.

Examination of the dead pups revealed a range of congenital anomalies, further highlighting the teratogenic potential of ACN. These anomalies included rough skin and remnant milk spot (Fig. 1A-C, 2B), dwarfism (Fig. 1C), incomplete forelimb toe (Fig. 2A, yellow arrow), anotia (lack of ears) (Fig. 4a), lacking frontal limbs (Fig. 4b), kyphosis (curvature of the spine) (Fig. 4c, 5), abnormal length and tail length (Fig. 5), pale color, and emaciated bodies (Fig. 3, 4).

Ovarian Histopathological Findings

Non-significant pathological changes were observed in G1 (Figure 6). In contrast, ovaries from the G2 group showed congestion, hemorrhage, and connective tissue hyaline degeneration with granulosa cell necrosis and apoptosis by day 45 (Figs. 7, 8). By day 90, ovary sections from G2 exhibited increased primordial cells, large luteal cysts surrounded by fibrous connective tissue (Figure 9), thick and congested blood vessels with interlacing fibrous tissue (Fig. 10). By day 120, G2 showed degeneration of primordial cells with necrosis, granulosa cell apoptosis, and a hyalinized cortex layer with large cystic ovaries (Figs. 11, 12). For G3, the ovaries displayed growing follicles with thick and hyalinized tunica theca interna and externa, and liquid follicles by day 45 (Fig. 13). By day 90, all

primordial cells appeared necrotic and clumped together (Fig.14), and the ovaries showed large cysts with hyalinized degeneration (Fig. 15). By day 120, G3 ovaries exhibited hemorrhage, inflammatory cells (mostly macrophages and epithelioid cells), and granulosa cell apoptosis (Fig.16).

Hormonal Disruptions

A significant finding of this study is the dose- and time-dependent reduction in serum LH, FSH, and E2 levels in ACN-exposed groups (G2 and G3) compared to the control group (G1), persisting across three observation periods (45, 90, and 120 days). This decline was more pronounced in the group receiving ACN three times a week, highlighting a clear dose-response relationship. These findings strongly suggest that ACN disrupts the hypothalamic-pituitary-gonadal (HPG) axis, potentially by directly impacting the hypothalamus or pituitary gland, or indirectly by interfering with feedback mechanisms. The observed reduction in E2 levels likely stems from both impaired HPG axis function and direct ovarian damage caused by CAN.

To the best of our knowledge, few studies on ACN toxicity have measured these hormones. [45] reported a significant increase in serum FSH levels and no change in LH concentrations three days after repeated intraperitoneal injections of 33 mg/kg BW ACN in male rats. [46] observed a significant reduction in serum levels of FSH and LH 90 days after oral administration of 40 mg/kg BW ACN to male Sprague-Dawley rats (n=15). Conversely, [46] reported that the estrous cycle of female Sprague-Dawley rats exposed to vapor atmospheres of ACN via whole-body inhalation at concentrations of 45 (across two offspring generations), and 90 ppm (one offspring generation), for 6 hours daily for day 28, was not affected. This implies that hormonal balances that control reproductive functions in female rats were not disrupted. The differences in doses, routes of ACN administration, time course, and sex of the rats might explain these divergent results. Folliculogenesis involves complex interactions among hormones from the hypothalamus, pituitary gland, and ovaries. LH and follicle-stimulating hormone FSH, triggered by gonadotropin-releasing hormone (GnRH), facilitate ovarian follicle development and ovulation. LH prompts androgen secretion in theca cells, which granulosa cells convert to estradiol. FSH primarily supports follicle growth, while LH also aids in their maturation. Inadequate LH and FSH can reduce fertility by disrupting gametogenesis and steroid production.

Ovarian Histopathology

Histopathological analysis of the ovaries provided further evidence of ACN-induced toxicity. The presence of necrosis, apoptosis, cystic changes, hemorrhage, and inflammation in the ACN-exposed groups points to significant cellular damage,

disrupted follicular development, vascular compromise, and inflammatory responses within the ovaries. These pathological changes directly contribute to impaired ovarian function and hormone production, ultimately affecting fertility.

Discussion

Our findings corroborate those of [47] who investigated the effects of CAN exposure on female Kunming mice 28-day treatment period at doses of 5, 10, or 20 mg/kg/day. They reported a higher proportion of atretic follicles (degenerating follicles) and a reduced number of preovulatory follicles in mice exposed to acrylonitrile. This suggests that acrylonitrile disrupts the normal development of follicles, which are crucial for oocyte development [48] further elucidated the molecular pathways affected by acrylonitrile, noting significant alterations in gene expressions related to apoptosis, oxidative stress, endoplasmic reticulum stress, and autophagy in oocytes. Their transcriptomic analysis revealed that acrylonitrile disrupted the expression of critical oocyte genes, which we also observed as increased DNA damage in ovarian cells. These disruptions can be directly linked to the decreased fertility rates and poor oocyte quality observed in our study, where treated groups showed decreased hormone levels and increased incidence of congenital anomalies in offspring.

However, these findings contrast with two-generation inhalation study in CrI®(SD) rats conducted by [48], who found no significant effects on histopathological changes in ovary at 45 and 90 ppm (6 h/day). This discrepancy might be due to different exposure methods and doses used. Notably, the current study and [49] employed methods that could potentially lead to higher localized acrylonitrile concentrations compared to inhalation.

The teratogenic potential of ACN was clearly demonstrated by the high incidence of congenital deformities in offspring from mothers exposed to ACN three times a week. These deformities, including dwarfism, limb defects, anotia, kyphosis, and rough skin, underscore the detrimental impact of ACN on fetal development. The complete postnatal mortality in this group further emphasizes the severity of ACN's toxic effects.

This aligns with previous studies that have demonstrated the embryotoxic and teratogenic potential of ACN in various animal models. [49] reported significant embryotoxicity and teratogenic effects in rats exposed to high doses of ACN (65 mg/kg/day by gavage; 80 ppm by inhalation), resulting in fetal malformations such as short trunk and tails, and missing vertebrae. They also reported a low incidence of the same alterations was seen at 25 mg/kg/day by gavage and at 80 ppm by inhalation. At 10 mg/kg BW per day and 20 ppm, no embryotoxicity or teratogenicity was found. Similarly [50] observed enhanced embryotoxic

effects of ACN in vitro when glutathione levels were depleted, indicating the role of oxidative stress in ACN-induced teratogenicity. They reported that ACN at concentrations of 304 μM reduced functional yolk sac circulation, a significant decrease in crown-rump length was observed at 152 μM , with a 16.5% reduction from the control value at 304 μM [51]. There was a significant reduction in yolk sac diameter at concentrations of 228 and 304 μM . Both head length and the number of somite pairs decreased significantly at 304 μM acrylonitrile. These findings highlight the sensitivity of embryonic development to ACN, where exposure can significantly disrupt normal fetal growth and development. Moreover, the role of cyanide, a byproduct of ACN metabolism, in exacerbating these effects cannot be overlooked. Studies suggest that cyanide may directly impact the embryo, contributing to the observed teratogenic outcomes [52]. However, the exact contribution of cyanide relative to other ACN metabolites remains to be fully elucidated, pointing to an area requiring further research.

Conclusion

The present study provides compelling evidence that ACN exposure has detrimental effects on the

female reproductive system in mice, manifested through disruptions in sex hormone levels, compromised fertility, and the induction of teratological abnormalities in offspring. These findings highlight the potential for ACN to impact human reproductive health, warranting further investigation and precautionary measures.

Acknowledgments

The authors thanks to Vet. Med. College, Baghdad University.

Conflict of interest

There are no conflicts of interest to be declared.

Funding statement

The article was not financially supported.

Author contributions

Conceptualization, study design and sample collection Fatima J. Abd.

Data analyses, Manuscript drafting, and Manuscript finalization: Bushra. I. al. Kaisi

Ethical approval

It was granted through the local committee of the animal care and use at the College of Veterinary Medicine/University of Baghdad (Number 746/P.G. at 2/4/2024).

TABLE 1. Effects of acrylonitrile on serum levels of luteinizing hormone (LH), follicle-stimulating hormone (FSH), and Estradiol E2) in female mice.

Variables		Hormones			
Day	Treatment	n	LH (ng/mL)	FSH (ng/mL)	E2 (pg/mL)
45	G1	6	6.55 \pm 0.157 ^a	6.23 \pm 0.105 ^a	47.3 \pm 0.091 ^a
	G2	6	4.32 \pm 0.133 ^b	5.17 \pm 0.062 ^b	36.6 \pm 0.577 ^c
	G3	6	2.87 \pm 0.049 ^d	2.25 \pm 0.076 ^d	32.9 \pm 0.338 ^e
90	G1	6	6.50 \pm 0.132 ^a	6.35 \pm 0.136 ^a	43.9 \pm 0.846 ^b
	G2	6	4.02 \pm 0.083 ^b	3.23 \pm 0.084 ^c	34.3 \pm 0.549 ^d
	G3	6	3.03 \pm 0.117 ^{cd}	2.22 \pm 0.087 ^d	33.0 \pm 0.145 ^e
120	G1	6	6.47 \pm 0.150 ^a	6.50 \pm 0.153 ^a	47.7 \pm 0.154 ^a
	G2	6	3.33 \pm 0.098 ^c	3.30 \pm 0.115 ^c	33.8 \pm 0.297 ^{de}
	G3	6	2.75 \pm 0.076 ^d	1.47 \pm 0.270 ^e	33.2 \pm 0.093 ^{de}
Main Effect					
Day					
		18	4.58 \pm 0.37 ^a	4.55 \pm 0.41 ^a	38.3 \pm 1.50 ^a
		18	4.52 \pm 0.36 ^a	3.93 \pm 0.43 ^b	37.1 \pm 1.22 ^b
		18	4.18 \pm 0.40 ^b	3.76 \pm 0.52 ^b	38.3 \pm 1.63 ^a
Treatment					
		18	6.51 \pm 0.08 ^a	6.36 \pm 0.08 ^a	46.3 \pm 0.49 ^a
		18	3.89 \pm 0.12 ^b	3.90 \pm 0.22 ^b	34.9 \pm 0.39 ^b
		18	2.88 \pm 0.05 ^c	1.98 \pm 0.13 ^c	33.0 \pm 0.12 ^c
P-values					
			0.001	<0.001	<0.001
			<0.001	<0.001	<0.001
			0.002	<0.001	<0.001

Values are means \pm SEM, n = 6 per treatment group. Means for each hormone with different capital letters in the same column (between groups) and lowercase letters in the same row (within a group) are significantly different ($P \leq 0.05$). Group 1 (G1, n=20): Negative control (no acrylonitrile exposure). Group 2 (G2, n=20): Received acrylonitrile twice a week (10.17 mg/kg BW, 1/10 of LD50) orally by gavage for 120 days. Group 3 (G3, n=30): Received the same acrylonitrile dose three times a week orally by gavage for 120 days.

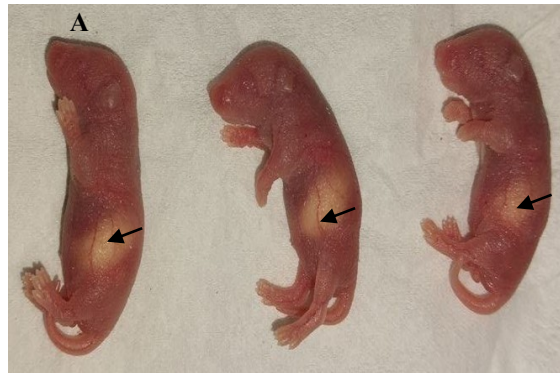


Fig. 1. Gross appearance pups after delivery in G3 showing remnant milk spot and rough skin (A, B, C, black arrows), dwarfism (C)

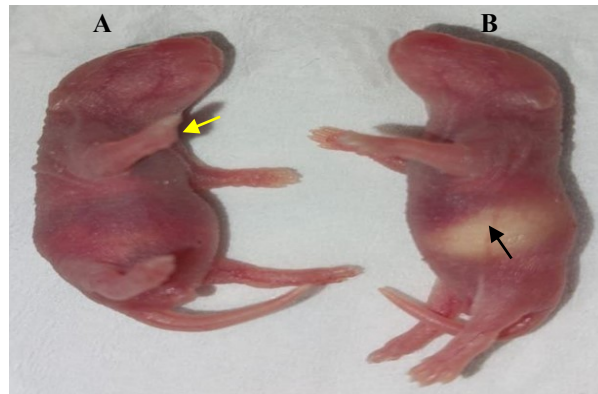


Fig.2. Gross appearance pups after delivery in G3 showing pups with incomplete fore limb toe) (A, yellow arrow), pups shows remnant milk spot. (B, black arrow)

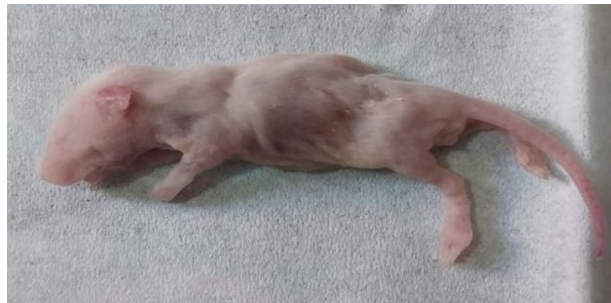

Fig.3. Gross appearance of dead pups in G3 showing emaciated dead pups, pale in colour, with multiple nodules about 20 mm on the rough skin.

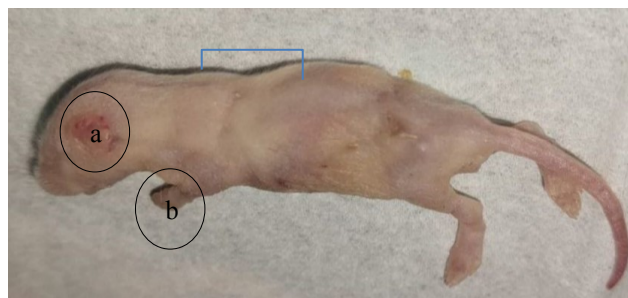


Fig. 4. Gross appearance of dead pups in G3 showing pale, emaciated, rough emaciated rough skin with bilateral anotia (a), lack of frontal limbs (b), and kyphosis (c)

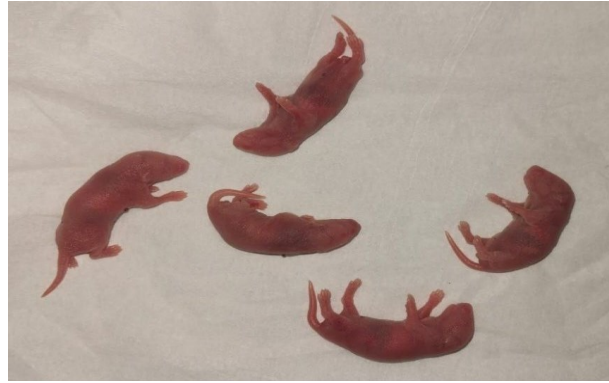

Fig. 5. Gross appearance of dead pups in G3 showing abnormal length, tail length, and kyphosis, with all pups dead

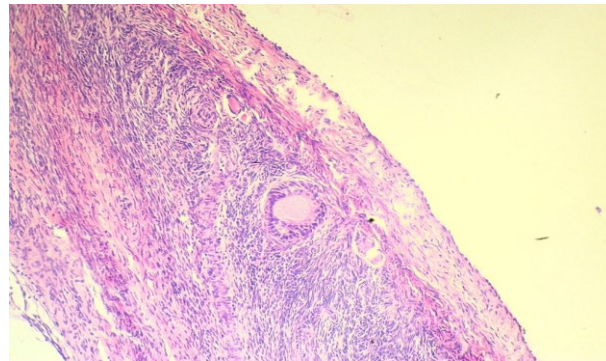


Fig. 6. Section in ovary from control group showing: (a) normal cortex consist secondary follicle, (b) normal granulosa cells (c). normal medulla tissue. H&E, ×200.

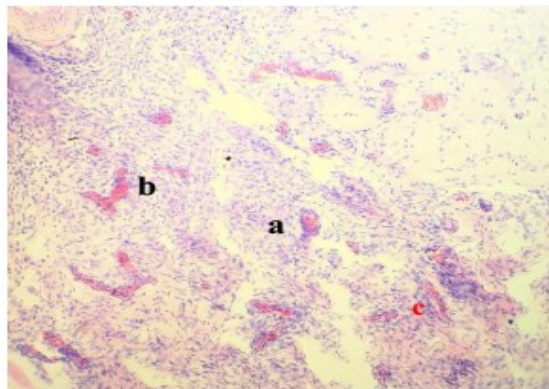


Fig. 7. Section in ovary from G2 mice at day 45 showing: (a) congestion blood vessels. (b) granulosa cells necrosis. H&E, ×200

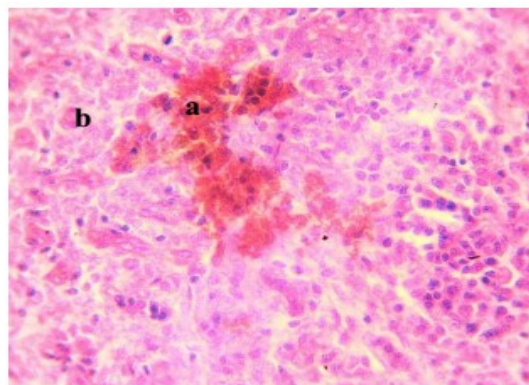


Fig. 8. Section in ovary from G2 mice at day 45 showing: (a) severe hemorrhage (b) apoptosis. H&E, ×400

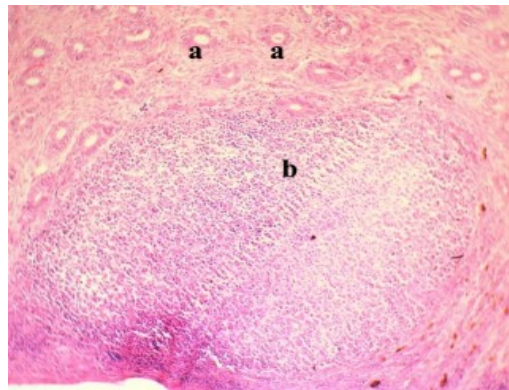


Fig. 9. Section in ovary from G2 mice at day 90 showing: (a) increase primordial cells (b) large luteal cyst surrounded by fibrous connective tissue. H&E, $\times 200$

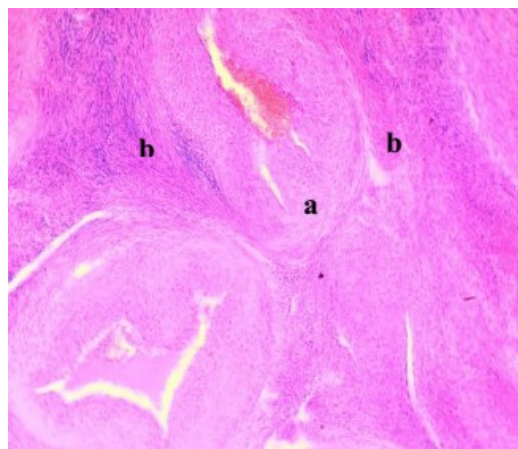


Fig. 10. Section in ovary from G2 mice at day 90 showing: (a) congested arterioles, (b) interlacing connective tissue. H&E, $\times 400$

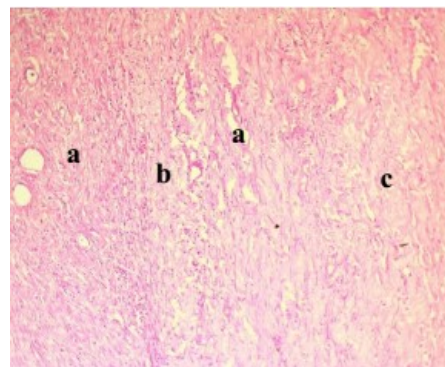


Fig. 11. Section in ovary from G2 mice at day 120 showing: (a) degenerated primordial cells, (b) necrotic granulosa cells, (c) hyaline degeneration. H&E, $\times 200$

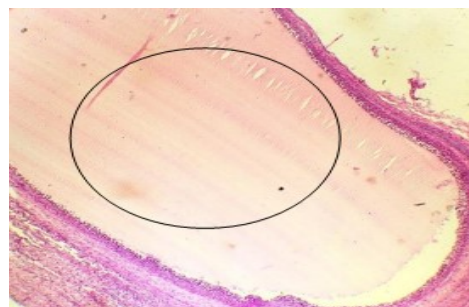


Fig. 12. Section in ovary from G2 mice at day 120 showing: (black circle) large cystic ovary. H&E, $\times 200$

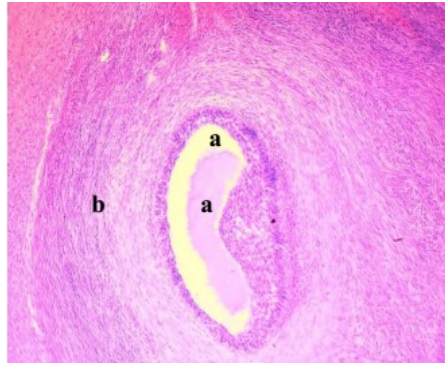


Fig. 13. Section in ovary from G3 mice at day 45 showing: (a) growing interna and externa follicle, (b) thick hyalinized tunica theca, (c) liquid follicle. H&E, $\times 400$

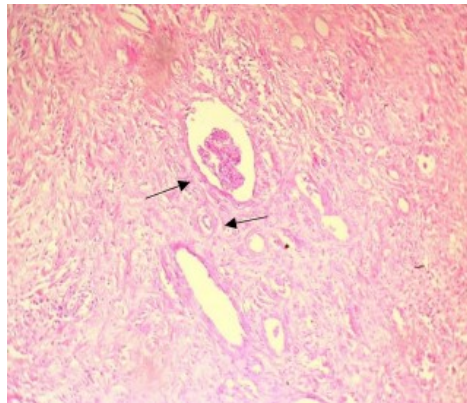


Fig. 14. Section in ovary from G3 mice at day 90 showing: necrotic with diminishes of primordial cells look as clump (black arrows). H&E, $\times 200$

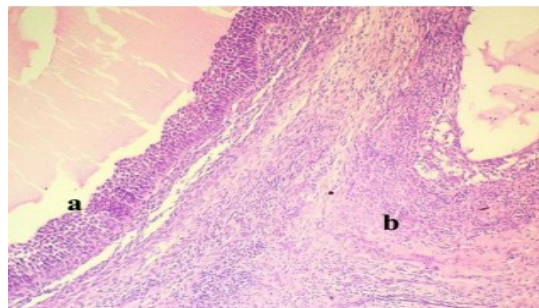


Fig. 15. Section in ovary from G3 mice at day 90 showing: (a) large cystic ovary, (b) hyaline degeneration. H&E, $\times 400$

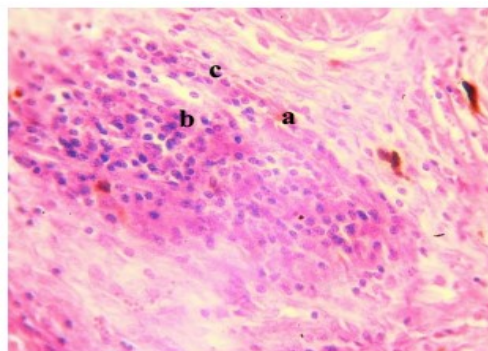


Fig. 16. Section in ovary from G3 mice at day 120 showing: (a) hemorrhage, (b) area of inflammatory cells (macrophage and epithelioid cell), (c) necrosis. H&E, $\times 400$

References

1. Abdallah, A. Protection of Resveratrol Against Nephrotoxicity in Rats Produced by 2, 3, 7, 8-Tetrachlorodibenzo-p-dioxin. *Egyptian Journal of Veterinary Sciences*, **56**(3), 605-616(2024).
2. Rezaie, F., Pirouzfard, V. and Alihosseini, A. Technical and economic analysis of acrylonitrile production from polypropylene. *Thermal. Sci. Eng. Prog.*; **16**,100463(2020).
3. Alshumary, H. O., Jumma, Q. S., Khorsheed, H. H. and AlKaisi, B. I. Assessment of The toxic Effect of Environmental Pollution by 2, 3, 7, 8-Tetrachlorodibenzo-p-dioxin (TCDD) on The Female Reproductive System by Pathological and Biochemical Assay in Albino Female Rats. *Egyptian Journal of Veterinary Sciences*, **55**(5), 1409-1415 (2024).
4. AL-Okaily, B. N. Role of alcoholic extract of Rocket (*Eruca sativa*) leaves on male reproduction of experimentally induced-oxidative stressed rats: Baraa Najim AL-Okaily and Ahmed Jasim Nowfel. *The Iraqi Journal of Veterinary Medicine*, **39**(2), 47-54(2015).
5. Walker, V. E., Walker, D. M., Ghanayem, B. I. and Douglas, G. R. Analysis of biomarkers of DNA damage and mutagenicity in mice exposed to acrylonitrile. *Chemical Research in Toxicology*, **33**(7), 1623-1632(2020).
6. Azeez, O. H. Evaluation of some male and female rats' reproductive hormones following administration of aspartame with or without vitamin C or E. *The Iraqi Journal of Veterinary Medicine*, **45**(2),14-20 (2021).
7. Rezaie, F., Pirouzfard, V. and Alihosseini, A. Technical and economic analysis of acrylonitrile production from polypropylene. *Thermal Science and Engineering Progress*, **16**, 100463(2020).
8. Humadi, A.A., AL-Kaisei, B.I. and Humadi, T.J. Acrylonitrile testicular seminoma in beagle male dogs (pathological and hormonal assay). *Plant Archives* , **20**(1), 09725210 (2020).
9. Mirkin, D. B. The special case of acrylonitrile (CH₂=CH-C≡N). *Toxicology of Cyanides and Cyanogens: Experimental, Applied and Clinical Aspects*, 181-194. (2015). <https://doi.org/10.1002/9781118628966.ch13>
10. Al-Azzawi, A.M., Al-Tamimi, E.O. and Ali, R.A. Synthesis and copolymerization of several Nsubstituted acrylamide. *Um-Salama Science Journal*, **5**(4),619-626 (2008).
11. Al-Azzawi, A.M. and Faiq, E. Synthesis and Polymerization of Several New Maleimides Linked to Schiff Bases and Their Copolymers with Acrylonitrile. *Iraqi Journal of Science*, **58**,1580- 1592 (2017).
12. Aghetaa, H. F. K., Dawood, R. A. and Aladhami, A. K. Resveratrol Administration Ameliorates Hepatotoxicity in Mercuric Chloride- eiv jiyduji eeviLdeudnI . *The Iraqi Journal of Veterinary Medicine*, **47**(2), 1-8(2023).
13. Adeola, F. O. Global impact of chemicals and toxic substances on human health and the environment. *Handbook of Global Health*, 1-30 (2020).
14. Abdulla J.M. and Al-Okaily, B.N. Histomorphometric and histopathological alterations of rat testis following exposure to hydrogen peroxide: Protective role of resveratrol supplement. *The Iraqi Journal of Veterinary Medicine*, **46**(1), 17-23(2022).
15. Brazdil, J.F. Acrylonitrile. In Kirk-Othmer Encyclopedia of Chemical Technology, vol.1 Online edition. *New York: John Wiley & Sons*. 397-414 (2010).
16. Yew, G. Y., Tham, T. C., Show, P. L., Ho, Y. C., Ong, S. K., Law, C. L. and Chang, J. S. Unlocking the secret of bio-additive components in rubber compounding in processing quality nitrile gl3-ove. *Applied Biochemistry and Biotechnology*, **191**, 1-28(2020).
17. Fritz, J. M. and Luke, A. M. Acrylonitrile. *Hamilton & Hardy's Industrial Toxicology*, 741-754. (2015).
18. Mahmood, W.S., Al-Jumaili, E.F. and Mohamad, N.B. Qualitative and Quantitative evaluation of the extracted flavonoids in Iraqi-Sumac (*Rhus coriaria* L.). *Iraqi Journal of Biotechnology*, **21**(1),50-60 (2022).
19. Robichaud, A. An overview of selected emerging outdoor airborne pollutants and air quality issues: the need to reduce uncertainty about environmental and human impacts. *Journal of the Air & Waste Management Association*, **70**(4), 341-378(2020).
20. Kobets, T., Iatropoulos, M. J., & Williams, G. M. Acrylonitrile induction of rodent neoplasia: Potential mechanism of action and relevance to humans. *Toxicology Research and Application*, **6**, 23978473211055363. (2022).
21. Albertini, R. J., Kirman, C. R., & Strother, D. E. Acrylonitrile's genotoxicity profile: mutagenicity in search of an underlying molecular mechanism. *Critical Reviews in Toxicology*, 1-48. (2023).
22. Shniakat, W.N., Al-Khateeb, E.H., Numan, N.A., Abbas, M.M. and Shakya, A. Cytotoxic Evaluation of Doxorubicin Combination with Baicalein and Resveratrol Against Hct116 and Hepg2 Cancer Cell Lines (Conference Paper). *Iraqi Journal of Pharmaceutical Sciences*, **31**, 92-99 (2022).
23. Khudair, N.T. and Al-Okaily, B.N. Renal ameliorating effect of resveratrol in hydrogen peroxide induced male rats. *Iraqi Journal of Veterinary medicine*, **36**(3), 571-577 (2022).
24. Caito, S.W., Yu, Y. and Aschner, M. Differential inflammatory response to acrylonitrile in rat primary astrocytes and microglia. *Neurotoxicology.*, **42**,1-7 (2014).
25. Li, X.J., Li, B., Huang, J.S., Shi, J.M., Wang, P., Fan, W. and Zhou, Y.L. Effects of acrylonitrile on lymphocyte lipid rafts and RAS/RAF/MAPK/ERK signaling pathways. *Genetics and Molecular Research*. **13**(3),7747-7756(2014).

26. Hamdy, N.M., Al-Abbasi, F.A., Alghamdi, H.A., Tolba, M.F., Esmat, A. and Abdel-Naim, A.B. Role of neutrophils in acrylonitrile-induced gastric mucosal damage. *Toxicology letters*, **208**(2),108-114 (2012).
27. Zhong, X.J., Wu, X., Zhou, Y.L., Jin, S.X. and Jin, T.Y. Epidemiological study of the effects of acrylonitrile on male reproductive health. *Occupational Health and Emergency Rescue*, **4**,173-177 (2004).
28. Hamdy, N.M., Al-Abbasi, F.A., Alghamdi, H.A., Tolba, M.F., Esmat, A. and Abdel-Naim, A.B. Role of neutrophils in acrylonitrile-induced gastric mucosal damage. *Toxicology letters*. **208**(2),108-114(2012).
29. Ali, A. A., Laith, S. Y. and Saad, T. R. Effect of polymorphism G(129)R in growth differentiation factor 9 gene (GDF9) on Awassi ewes that breed out of season. *Biochemical and Cellular Archives*, **19**(2), 4649-4653(2019).
30. Al-Sabaawy, H. B. and Al-Kaisie, B. I. Effects of sub lethal concentrations of sodium fluoride on sperm activity and on the level of sex hormones of adult male albino rats. *The Iraqi Journal of Veterinary Medicine*, **44** (2), 92–98 (2020).
31. Alrudainy, A.J. & Jumaa, Q.S. Effect Of Magnitized Water On Common Carp *Cyprinus Carpio* Rearing In Different Salinity Concentrations. *Iraqi Journal Of Agricultural Sciences*, **47**(2), 646-655(2016).
32. Zhong, X.J., Wu, X., Zhou, Y.L., Jin, S.X. and Jin, T.Y. Epidemiological study of the effects of acrylonitrile on male reproductive health. *Occupational Health and Emergency Rescue*, **4**,173-177 (2004).
33. Luo, Y. S., He, Q. K., Sun, M. X., Qiao, F. X., Liu, Y. C., Xu, C. L., & Liu, Y. Acrylonitrile exposure triggers ovarian inflammation and decreases oocyte quality probably via mitochondrial dysfunction induced apoptosis in mice. *Chemico-Biological Interactions*, **360**, 109934(2022).
34. Neal, B.H., Collins, J.J., Strother, D.E. and Lamb, J.C. Weight-of-the-evidence review of acrylonitrile reproductive and developmental toxicity studies. *Crit Rev Toxicol.*, **39**(7),589-612(2009).
35. Hashim, M. Obaid, Qusai Saleh Jumma , Hassan H.K. Al-Bayati and Bushra. I. al. Kaisi. Assessment of The toxic Effect of Environmental Pollution by 2 ,3 ,7 ,8 - Tetrachlorodibenzo-p-dioxin (TCDD) on The Female Reproductive System by Pathological and Biochemical Assay in Albino Female Rats. *Egypt. J. Vet. Sci.*, **55**(5),1409-1415 (2024)
36. Hussein, A. M. & Jumma, Q. S. Diagnosis of Infectious Bronchitis Infection in Broiler Chicken Farms in Salah Al-Din Governorate. *Egyptian Journal of Veterinary Sciences*, **55**(6), 1619-1626 (2024).
37. Al-Sabaawy, H. B., & Al-Kaisie, B. I. Histological effects of chronic sodium fluoride toxicity on some reproductive organs of male and female adult albino rats. *Iraqi Journal of Veterinary Sciences*, **35**(4), 705-711 (2021).
38. Hattat, A.T. Immunopathological, Histopathological and Genotoxicity in Glyphosate Exposed Mice Treated with Probiotics [Thesis].Baghdad: University of Baghdad; (2019).
39. Bancroft, J.D., Stevens, A. and Turner, D.R. Theory and practice of histological techniques. 4th ed. *Churchill Livingstone*; (1996).
40. Ajayi, A.F. and Akhigbe, R.E. Staging of the estrous cycle and induction of estrus in experimental rodents: an update. *Fertil Res Pract.*, **6**,5 (2020).
41. Klaassen, C.D., Amdur, M.O. and Doull, T. Gassartt. Toxicology. In *The Basic Science of Poisons* (7th Ed):Macmillan (Ed)Publishing company New York. (2008).
42. Nilsen, O.G., Toftgard, R. and Eneroth, P. Effects of acrylonitrile on rat liver, cytochrome P-450, benzo(a)pyrene metabolism and serum hormone levels. *Toxicol. Lett.*, **6**, 399-404(1980).
43. Abdulla, J. M. and Al-Okaily, B. N. Histomorphometric and histopathological alterations of rat testis following exposure to hydrogen jiredij virnj nduj irij rejIujidniri Iv ijejen.*The Iraqi Journal of Veterinary Medicine*, **46**(1), 17-23(2022).
44. Sabeeh, S.I. and Al-Awadi, A.Q. Prophylactic Role of Resveratrol against Testicular toxicity induced by Acrylonitrile in Rats. *Diyala J. Vet. Sci.*; **1**(3), 9-24(2023).
45. SAS. Statistical Analysis System, User's Guide. Statistical. Version 9.6th ed. SAS. Inst. Inc. Cary. N.C. USA. (2018).
46. Jumma, Q. S. Detection of ESBL E.coli That Carried STX1 and STX2 Form Common Carp (*Cyprinus carpio*) in Salhaldeen Province. *Egyptian Journal of Veterinary Sciences*, **55**(4), 1165-1170(2024)
47. Zaher, A. R., AL-Rekabi, F. M., & Hatif, S. A. Some teratogenic outcomes in rats exposed to zinc chloride pre and post pregnancy. *The Iraqi Journal of Veterinary Medicine*, **45**(2), 41-45 (2021).
48. Nemeč, M.D., Kirkpatrick, D.T. Sherman, J., Pershing, M.L. and Strother, D.E. Two-generation reproductive toxicity study of inhaled acrylonitrile vapors in Crl:CD(SD) rats. *Int. J. Toxicol.*, **27**,11–29 (2008).
49. Amin, F. A. M. Effects of Azorubine Food Additive on Female Reproductive Organs and Hormones in Sprague Dawley Rat. *The Iraqi Journal of Veterinary Medicine*, **42**(2), 67-72 (2018).
50. Khayoon, H. A. and Al-Rekabi, F. M. Cytotoxic effect of resveratrol on colorectal cancer cell line. *The Iraqi Journal of Veterinary Medicine*, **44**(1),68-74(2020).
51. Saillenfait, A.M. and Sabate, J.P. Comparative developmental toxicities of aliphatic nitriles: In vivo and in vitro observations. *Toxicol Appl Pharmacol.*, **163**(2),149–163 (2000).
52. Al-Okaily, B. N., & Ali, E. H. Effect of pomegranate seed oil against hepatotoxicity-induced by sodium fluoride in adult female rats (part II). *The Iraqi Journal of Veterinary Medicine*, **43**(1),480 (2019).

تأثير سمية الأكريلونيتريل على مبايض الاناث والتشوهات الخلقية في الفئران

فاطمة جليل عبد السادة و بشرى ابراهيم القيسي

فرع الفلسفة والكيمياء والحياتية والأدوية - كلية الطب البيطري - جامعة بغداد - العراق.

الخلاصة

يُعرف الأكريلونيتريل (ACN) بخصائصه المسرطنة والسامة، ولكن تأثيره على الصحة الإنجابية للإناث في الثدييات لا يزال غير مفهوم جيداً. هدفت هذه الدراسة إلى توضيح الآثار السمية المزمنة للأكريلونيتريل على وظيفة المبايض والهرمونات التناسلية في إناث الفئران البيضاء (*Mus musculus*) وتقييم آثاره المشوهة على النسل. تم تقسيم 70 من إناث الفئران البيضاء عشوائياً إلى ثلاث مجموعات: المجموعة 1 (العدد = 20) كانت بمثابة مجموعة ضابطة سلبية، المجموعة 2 (العدد = 20) تلقت الأكريلونيتريل بجرعة 10.17 مجم/كجم من وزن الجسم (10/1) من الجرعة المميتة النصفية عن طريق الفم) مرتين أسبوعياً عن طريق الفم لمدة 120 يوماً، والمجموعة 3 (العدد = 30) تلقت نفس جرعة الأكريلونيتريل ثلاث مرات أسبوعياً عن طريق الفم لمدة 120 يوماً. في الأيام 45 و90 و120 من التعرض للأكريلونيتريل، تم جمع عينات الدم لتقييم مستويات هرمون اللوتيني (LH) وهرمون المحفز للجريبات (FSH) والإسترايول (E2) في مصل الدم باستخدام مجموعات الاختبار المناعي المرتبط بالإنزيم (ELISA). بعد 120 يوماً من التعرض، تم تزاوج 12 أنثى من المجموعة 3 مع 6 ذكور بالغين لدراسة النتائج المشوهة. وجدت الدراسة انخفاضات معنوية في مستويات LH و FSH ($P < 0.05$) في جميع الفترات الزمنية في المجموعات المعالجة بالأكريلونيتريل مقارنة بالمجموعة الضابطة، مع إظهار المجموعة 3 بشكل عام أدنى المستويات. كشف التحليل النسيجي المرضي عن نخر وتغيرات كيسية وموت الخلايا المبرمج ونزيف في مبايض المجموعتين 2 و3. أظهر نسل المجموعة 3 تشوهات خلقية متعددة، بما في ذلك القزامة والجلد الخشن وتشوهات الأطراف وانعدام الأذنين. توفي جميع المواليد من هذه المجموعة بعد الولادة، وأظهروا تشوهات في طول الجسم والذيل، وظهر عليهم حذب الظهر. يؤدي التعرض للأكريلونيتريل إلى إعاقة كبيرة في مستويات الهرمونات التناسلية ومورفولوجيا المبايض، مما يؤدي إلى آثار مشوهة شديدة. تسلط هذه النتائج الضوء على المخاطر التناسلية المحتملة للأكريلونيتريل وتؤكد على الحاجة إلى تدابير رقابية صارمة للحد من التعرض، لا سيما في البيئات التي قد تكون فيها الإناث الحوامل معرضات للخطر. تشير نتائج هذه الدراسة إلى أن التعرض للأكريلونيتريل له آثار سلبية كبيرة على وظيفة الجهاز التناسلي للإناث في الفئران، والتي تتميز بانخفاض مستويات هرمونات الجنس والعقم والتشوهات الخلقية في النسل.

الكلمات المفتاحية: الأكريلونيتريل ، السمية التناسلية للإناث ، وظيفة المبايض ، التأثيرات المشوهة، الفئران