

## LAPROSCOPIC ULTRASONOGRAPHY IN EVALUATION OF THE BILIARY TREE DURING LAPAROSCOPIC CHOLECYSTECTOMY

By

Mosaad Morshed M.D., Saleh El-Aawady MD; Talal Amer, M.D.\*\*, and Hany Al-Henawy

Department of General Surgery & Diagnostic Radiology Department \*\*, Faculty of Medicine, Mansoura University, Egypt.

**Objective:** *This study assessed the effectiveness of laparoscopic ultrasonography during laparoscopic cholecystectomy*

**Method:** *From Jan. (2000) to May (2001), ninety patients treated by laparoscopic cholecystectomy were included in a prospective study using laparoscopic ultrasonography during laparoscopic cholecystectomy.*

**Results:** *The feasibility of laparoscopic ultrasonography was 98.9 % with full visualization in 90% and time taken for laparoscopic ultrasonography was 8.5 min. Variations in the anatomy of bile ducts was observed in 25.5% while vascular variations were seen in 30% of cases. Lastly the sensitivity, specificity, and accuracy to detect common bile duct stones were 80%, 98%, and 97.2% respectively.*

**Conclusion:** *Laparoscopic ultrasonography proves safe, effective, repeatable, and non invasive method to detect vascular anomalies, bile duct anomalies, and ductal stones during laparoscopic cholecystectomy*

**Key words:** *Laparoscopic ultrasonography, laparoscopic cholecystectomy, common bile duct, bile duct injury, endoscopic retrograde cholangio-pancreatography.*

### INTRODUCTION

Since the first successful laparoscopic cholecystectomy in the late 1980s, laparoscopic cholecystectomy had significant merits and now not only accepted as a treatment of choice for gall stone disease but replaced the conventional open cholecystectomy. Moreover, 75% or more of cholecystectomies are now performed laparoscopically <sup>(1)</sup>.

Several studies have shown the efficacy and safety of laparoscopic cholecystectomy as well as the advantages such as reduced hospital stay, earlier recovery, less intraabdominal adhesions, and a better cosmetic results <sup>(2)</sup>.

Yet unfortunately laparoscopic cholecystectomy is associated with a higher incidence of bile duct injury approximately two to four times as open surgery <sup>(3)</sup>, that catastrophe is strongly related to the surgeon's experience

as during this procedure the anatomy is distorted due to extreme traction at the Hartman's pouch, so with a short cystic duct, the common bile duct is tented and simulate the cystic duct <sup>(4)</sup>. Also, it has been found that the bile duct injury. is caused by inadequate exposure of the critical structures in the Calot's triangle, dissection of the common hepatic duct or common bile duct as the cystic duct <sup>(5)</sup> or excessive use of diathermy <sup>(6)</sup>.

Similarly, the retained common bile duct stones represent another important problem as 2-8% of cases has retained common bile duct stones and the exact technique to exclude ductal stones still controversial <sup>(7)</sup>, that is although several predictors for the possibility of ductal stones has been known as age  $\geq 55$  years, bilirubin  $>30$  mol/L, and positive ultrasound findings (dilated common bile duct and/or common bile duct stones), and if all

predictors are positive the possibility of ductal stones nearly 95% and reach 8% if all are negative (8).

Also, bleeding during laparoscopic cholecystectomy is still the most common cause for conversion to open procedure leading to poor laparoscopic field facilitating bile duct injury, or other vascular injury, so the best way to handle that bleeding and to prevent its occurrence is the clear understanding of the laparoscopic anatomy of the biliary tree, identifying the risky factors that predispose to bleeding and careful surgical dissection (9). Lastly although the decision to convert to open surgery is not considered as a complication (10), but it is the patient's right and surgeon's duties to perform successful procedure.

Recently laparoscopic ultrasonography is a new technology in evolution of hepatic, pancreatic, and biliary system using the same principle as endoscopic instruments and the recent endoscanners has flexible tips that allow better tissue contact thus optimizing acoustic coupling, so the surgeon can scan organs in multiple planes (11). In addition, it has been found that laparoscopic ultrasonography is highly accurate, safe, simple, replacing and exceeding the tactile sense of open surgery with avoiding the misinterpretation and complications of intraoperative cholangiography (12).

Moreover, the laparoscopic ultrasonography serves as a road map to the biliary system so, it help to prevent bile duct injury through demonstration of the relationship of the circular images of common bile duct, nearby hepatic artery and the portal vein described as Micky Mouse head (13). Also, laparoscopic ultrasonography plays a major role in detection of ductal stones during laparoscopic cholecystectomy especially when Endoscopic retrograde cholangio-pancreatography failed, or contraindicated (14).

Lastly, laparoscopic ultrasonography can not only handle and minimize intraoperative bleeding through facilitating accurate dissection and minimizing electrocautery dissection, but also can help to distinguish ductal and vascular structures (15). So decrease the conversion rate of laparoscopic cholecystectomy to open surgery.

## PATIENTS AND METHODS

This study includes 90 patients who attended Mansoura University Hospital between January, (2000) and May (2001), all patients were submitted to full detailed history, clinical, laboratory, radiological investigations in addition to upper gastrointestinal endoscopy.

All patients are prepared for laparoscopic cholecystectomy and laparoscopic ultrasonography was done as follow soon after insulation, placement of telescope, fundic cephalic traction and Hartman's pouch

traction of gall bladder, the laparoscopic ultrasonography probe is placed through the epigastric port, the probe is placed **Firstly** over segment (4) of the liver to visualize the intrahepatic ducts, next under liver edge to visualize the right, left, and the common hepatic ducts. **Secondly** the probe is placed over the Calot's triangle to visualize with confidence the gall bladder neck, cystic duct, common bile duct junction and once the common bile duct is identified its anatomic relation to the portal vein, hepatic artery is noticed and the common bile duct wall thickness, diameter and calculi are measured and in difficult cases duplex assessment is used to differentiate the three main structures. **Thirdly** to image the intrapancreatic, ampullary portion of common bile duct the probe is placed over the lateral duodenal wall and compressed to provide a cross sectional view of common bile duct, pancreatic duct and ampulla of Vater. Following that full visualization of the biliary system, dissection of gall bladder is started at the safe zone (gall bladder neck) and completed followed by its extraction from the epigastric port. **Lastly** after gall bladder removal the laparoscopic ultrasonography probe is used again to visualize the biliary system (16).

### *Follow up:-*

The patients were followed in the inpatient department by clinical assessment and ultrasound on the second postoperative day and the fifth postoperative day then monthly at the outpatient clinic for at least six months.

## RESULTS

For (90) unselected elective patients with chronic calcular cholecystitis laparoscopic ultrasonography was performed during laparoscopy using 10 mm diameter, linear array scan head with 5-9 M.H.Z transducer.

Both the epidemiologic criteria and the abdominal ultrasound findings are shown in table (I). While table (II) summarized the laparoscopic ultrasonography findings and the procedures was unsuccessful in a single patient with extensive abdominal adhesions with full visualization of the biliary system in 90% of cases (Fig. A) (sequential (Fig. A-1) Rt. main hepatic duct, (Fig. A-2) Lt. main hepatic duct, Fig. 3 cystic duct, (Fig. A-4) common bile duct, (Fig. A-5) Lower end common bile duct) while (Fig. B) demonstrates the duplex assessment of common bile duct.

Surprisingly the laparoscopic ultrasonography of gall bladder showed higher incidence of multiple gall bladder stones (77.7%) versus (66.6%) for abdominal ultrasound.

Interestingly, the laparoscopic ultrasonography revealed 5 cases with common bile duct stones two with common bile duct diameter <5mm as in Fig. (C) and three with common bile duct >5mm as in Fig.(D). Moreover, the

biliary system anomalies were found in 23 cases (25.5%) with 6 cases had short cystic duct necessitating ligation not clipping and there were 6 cases had accessory hepatocystic ducts that were clipped, but the vascular anomalies were found in 27 cases (30%) with caterpillar anomalies in 13 cases (14.4 %).

The outcome of these patients were summarized in table (III) with no cases of common bile duct injuries but a single case with cystic duct leak (1.1%) diagnosed one week postoperative for her E.R.C with stinting after interventional intraperitoneal drainage.

The E.R.C. revealed stone retrieval in 4 cases out of the 5 cases but another case presented during follow up by jaundice for her E.R.C revealed missed lower end common bile duct stone managed by sphincterotomy and extraction (Fig. E).

Although no cases of major bleeding, only 4 cases developed minor bleeding intraoperatively that managed by clipping or electrocautery.

The laparoscopic cholecystectomy was successful in all cases with only 2 cases of gall bladder perforation.

The mean time of laparoscopic ultrasonography in the first half of cases was 9.2 min., but in the second half it was 7.3 min. (mean 8.25 min.).

Lastly table IV described the efficacy of laparoscopic ultrasonography to detect ductal stones, which was highly specific (98.9%), of strong negative value (98.9%) and profound accuracy (97.2%).

**Table (I): Preoperative criteria.**

		<i>Clinical assessment</i>	
	<i>Criteria</i>		<i>No. of patients (%)</i>
<b><u>Age:</u></b>			
	<45		40 (44.4)
	>45		50 (55.6)
<b><u>Sex:</u></b>			
	>		24 (26.6)
	+		66 (73.4)
<b><u>Abdominal adhesions:</u></b>			
	+ve		12 (13.3)
	-ve		78 (76.7)
		<i>Biliary ultrasound</i>	
	<i>Criteria</i>		<i>No. of patients (%)</i>
<b><u>Gall bladder:</u></b>			
Size:	Contracted		4 (4.4)
	Average		86 (85.6)
Wall:	Thick		75 (83.3)
	Normal		15 (6.7)
Stones:	Single		30 (33.3)
	Multiple		60 (66.6)
<b><u>Common bile duct:</u></b>			
Stones:	+ve		9 (0)
	-ve		90 (100)
Diameter:	<5 mm		79 (87.7)
	>5 mm		11 (12.3)

**Table (II): Laparoscopic ultrasound findings**

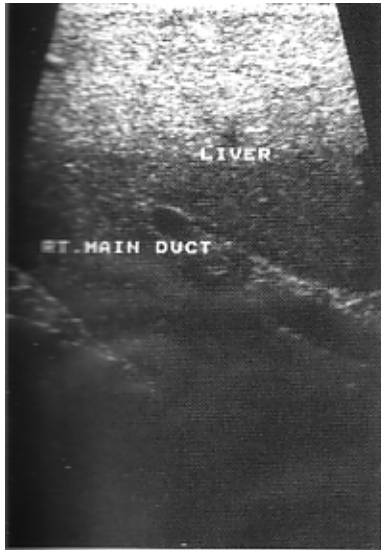
	No.	%
Success of laparoscopic ultrasonography:		
+ve	89	(98.9)
-ve	1	(1.1)
Visualization of B.S:		
Full	81	(90)
Intrapancreatic part	9	(10)
<b>Gall bladder:</b>		
Size: Contracted	4	(4.4)
Average	86	(85.6)
Wall: Thick	75	(83.3)
Normal	15	(6.7)
Stones: Single	20	(22.2)
Multiple	70	(77.8)
<b>Common bile duct:</b>		
Stones: +ve	5	(5.5)
-ve	85	(94.5)
<b>Biliary system anomalies:</b>	23	(25.5)
Cystic duct: Short	6	(6.6)
Long	2	(2.2)
Low insertion	4	(4.4)
High insertion	5	(5.5)
Accessory ducts	6	(6.6)
<b>Vascular anomalies:</b>	27	(30)
Caterpillar	13	(14.4)
Ant. cystic artery	3	(3.6)
Accessory cystic artery	6	(6.6)
Absent cystic artery	4	(4.4)
Middle hepatic vein	1	(1.1)

**Table (III): Outcome of laparoscopic cholecystectomy using laparoscopic ultrasonography**

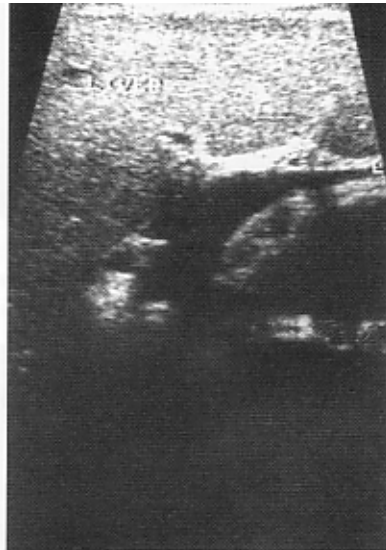
	No.	%
Bile duct injuries:		
+ve	0	(0)
-ve	90	(100)
Cystic duct leak:		
+ve	1	(1.1)
-ve	89	(98.9)
Minor bleeding:		
+ve	4	(4.4)
-ve	24	(85.6)
Major bleeding:		
+ve	0	(0)
-ve	90	(100)
Gall bladder perforation:		
+ve	2	(2.2)
-ve	88	(97.8)
Missed stones:		
+ve	1	(1.1)
-ve	84	(93.4)
ERCP + stone removal:		
+ve	4	(4.4)
-ve	1	(1.1)
Conversion to open surgery:		
+ve	0	(0)
-ve	90	(100)

**Table (IV): Efficacy of laparoscopic ultrasonography in detection of common bile duct stones**

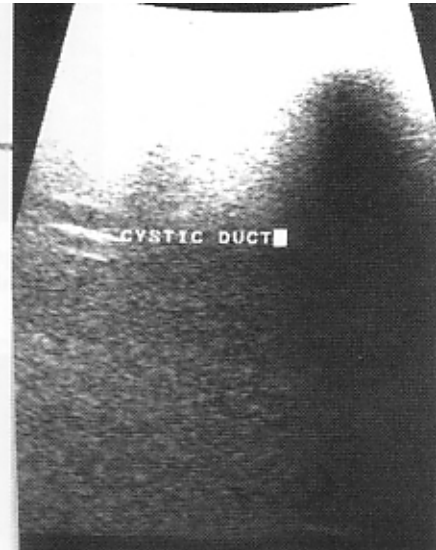
	%
Sensitivity	80
Specificity	98.9
Positive predictive value	80
Negative predictive value	98.9
Accuracy	97.2



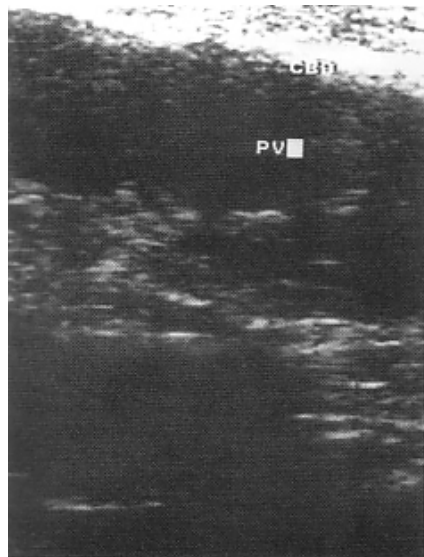
*Fig (A-1)*



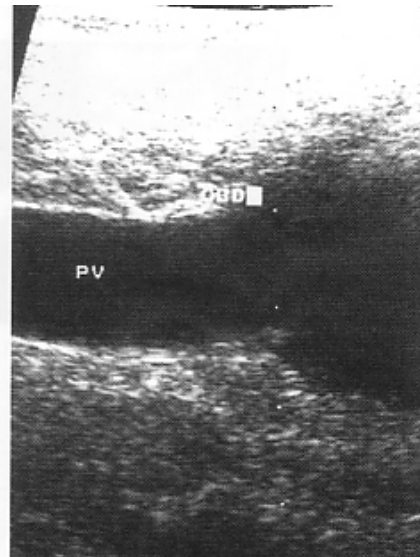
*Fig (A-2)*



*Fig (A-3)*



*Fig (A-4)*



*Fig (A-5)*

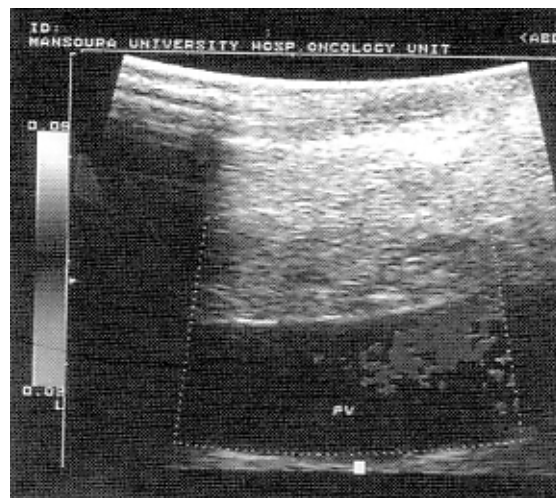


Fig. (B)

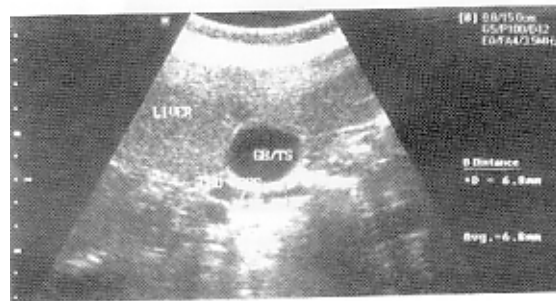


Fig. (C)

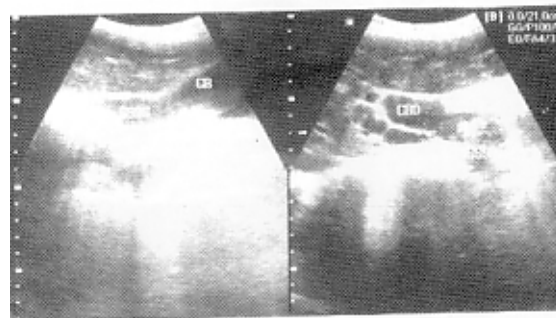


Fig. (D)

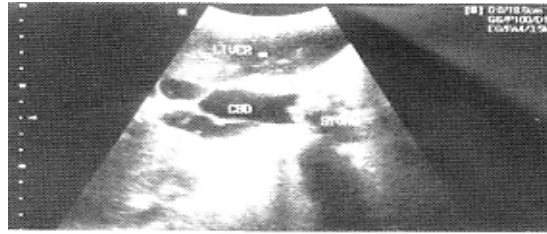

Fig. (E)

## DISCUSSION

It has been found that the laparoscopic ultrasound evaluation of the biliary system is accurate, with favorable image qualities, reduced invasion, more safe, avoidance of contrast material with its complications but more expensive<sup>(17)</sup>.

During this study the laparoscopic ultrasonography procedure success rate and full visualization of the biliary system similar to other reports as Rothlin, et al. <sup>(18)</sup> but the incidence of multiple gall stone cases has been raised from 66.6% to 77.6%, which is related to the ability of laparoscopic ultrasonography to detect minor stones even microlith similar to that reported by Dahan et al., <sup>(19)</sup> thus implicating sound dissection of the gall bladder and avoidance of gall bladder perforation to avoid intraperitoneal spillage of gall stones with its sequelae.

Moreover the laparoscopic ultrasonography facilitate safe dissection of the gall bladder through accurate visualization of the biliary system so no reported cases of bile duct injury had been found similar to Siperstein et al. <sup>(20)</sup> but only one case with cystic duct leak (1.1%) similar to Machi et al. <sup>(21)</sup> who reported an incidence of (0.2%-1.5%).

There were 2 cases of gall bladder perforation (2.8%) similar to that reported by De Simone et al. <sup>(22)</sup>, and those two patients one had thick walled gall bladder and the other had recent attack of cholecystitis.

Interestingly the incidence of accidental stones were 5.5 % of cases in contrast to Cardone, et al. <sup>(23)</sup> who was found that an incidence of 11.2 % which may be related to small number of patients in our series. Surprisingly the Endoscopic retrograde cholangiography revealed only 4 positive cases and the follow up revealed only one case of missed stones in the common bile duct.

So, the laparoscopic ultrasonography detection of ductal stones is highly specific, of strong negative value and extremely accurate as follow (98.9%-98.9% -97.2%) respectively nearly similar to that reported by Catheline, et

al. <sup>(24)</sup>, thus nullify the incidence of negative common bile duct exploration with its complications.

Clearly the laparoscopic ultrasonography revealed the biliary anomalies in 25.5% and vascular anomalies in 30% of cases allowing safe dissection and prevention of intraoperative bleeding thus facilitating easy and safe laparoscopy cholecystectomy. Through preventing major vascular bleeding that occurred in 0.11% of cases are reported by Usal et al. <sup>(25)</sup>. So the net outcome of laparoscopic cholecystectomy has been largely improved using the laparoscopic ultrasonography as evident by complete negative conversion in contrast to Sharma et al. <sup>(26)</sup> who reported 4% conversion rate, that is related to absence of significant intraoperative bleeding.

So in conclusion not only laparoscopic ultrasonography is safe, simple, reproducible procedure of no side effects but also has the following advantages:

- Roadmap the bile ducts to prevent bile ducts injury.
- Exclude ductal stones thus nullify negative common bile ducts exploration.
- Define precise vascular anatomical relation so handle intraoperative bleeding.
- Allow sound gall bladder dissection from the its bed to avoid iatrogenic gall bladder perforation with the hazards of intraperitoneal spillage of bile and stones.
- The above advantages lead to safe laparoscopic cholecystectomy thus minimize the conversion rate.
- So the net result is safe successful laparoscopic cholecystectomy.

In future for surgical groups with experience in laparoscopic ultrasonography this technique appears to become the standard primary technique to identify the anatomy of common bile duct and assessment of common bile duct stones.

## REFERENCES

1. Fletcher DR, Hobbs MST, Tan P et al. (1999): Complications of cholecystectomy. *Ann. Surg.* (299):449-457.
2. Deziel DJ, Millikan KW, Exnomou SG et al. (1993): Complications of lap. Cholecystectomy. *Am. J. Surgery* (165): 9-14.
3. Ooi LI, Goh YC, Chew SP et al. (1999): Bile duct injuries during laparoscopic cholecystectomy. *Aust-N-Z-J Surg.* Dec, 69 (12): 844-846.
4. Nair RG, Dunn DC, Fowler S et al. (1997): Progress with cholecystectomy. *Br. J. Surg.* (89): 1396-1398.
5. Filizhanko VN, Lobakov AI, Avash-Iub et al. (1999): Diagnosis and treatment of biliary complications of laparoscopic cholecystectomy. *Khirurgiia-Mosk*, 12:33-36.
6. Davidoff AM, Passas TN, Murray et al (1992): Mechanism of bile duct injury. during laparoscopic cholecystectomy *Ann. Surg.*, 215:196-202.
7. Sarli L, Pietra N, Franze A et al. (1999): Routine I.V.C, selective ERCP and endoscopic treatment of duct stones before laparoscopic cholecystectomy. *Gastrointest. Endosc.*, 50 (2): 200-8.
8. Bergamaschi R, Tuech JJ, Braconier L et al. (1999): Selective ERCP prior to laparoscopic cholecystectomy. *Am. J. Surg.*, 178 (1): 46-49.
9. Misawa T, Koike M, Suzukik et al. (1999): Ultrasonographic assessment of the risk of injury to branches of the middle hepatic vein during laparoscopic cholecystectomy. *Am. J. Surg.*, 178 (5): 418-421.
10. Crist DW, and Gadacz TR (1993): Complications of laparoscopic surgery. *Surg. Clinics of North America*, 732:265-289.
11. Norton SA, and Alderson D (1998): Endoscopic and laparoscopic ultrasonography. *Recent advances in surgery*, 21:17-31.
12. Rijna H, Eigsbouts QA, Barkhof F et al. (1999): Assessment of the biliary tract by ultrasonography and cholangiography during laparoscopic cholecystectomy. *Eur. J. Ultrasound*, 9 (2): 127-133.
13. Falcone RA, Fegelman EJ, Brown DL et al. (1999): A prospective comparison of laparoscopic ultrasound versus intravenous cholangiography during laparoscopic cholecystectomy. *Surg. Endosc.*, 13 (8): 784-788.
14. Prat F, Amouyal G, Amouyal P et al. (1996): Prospective controlled study of endoscopic ultrasound and endoscopic retrograde cholangiography in patients with suspected lithiasis. *Lancet*, 347:75-79.
15. Yamamoto M, Stiegmann GV, Durham J et al. (1996): Laparoscopy-guided intracorporeal ultrasound accurately delineates hepatobiliary anatomy. *Surg. May*, 119 (5): 534-7.
16. Michael J and Menac K (2000): Laparoscopic sonography of biliary tree and pancreas. *Surgery*, 80:1151-1167.
17. Thompson DM, and Arregui ME (1998): A comparison of laparoscopic ultrasonography with digital fluoro-cholangiography during laparoscopic cholecystectomy *Surg. Endoscopy*, 12 (7): 929-932.
18. Rothlin MA, Schob O, Schlumpf, R et al. (1996): Laparoscopic ultrasonography during cholecystectomy. *Br. J. of Surg.*, 83 (11):1512-6.
19. Dahan P, Andant C, Levy P et al. (1996): Prospective evaluation of endoscopic ultrasonography and microscopic of duodenal bile in the diagnosis of cholecystolithiasis in 45 patients with normal conventional ultrasonography. *Gut*, 38:277-281.
20. Siperstein A, Pearl J, Macho J (1999): Comparison of laparoscopic ultrasonography and fluorocholangiography in 300 patients undergoing laparoscopic cholecystectomy. *Surg. Endosc.*, 13 (2): 113-7.
21. Machi J, Tateishi T, Oishi AJ et al. (1999): Laparoscopic ultrasonography versus operative cholangiography. *J. Am. Coll. Surg.*, 188 (4): 360-7.
22. De-Simone P, Donadio R and Urbano D (1999): The risk of gall bladder perforation during laparoscopic cholecystectomy. *Surg. Endosc.*, 13 (11): 1099-102.
23. Cardone G, Girolamo DI, Lomanto D, et al. ( 1995): The role of intraoperative echography in laparoscopic cholecystectomy. *Radiol.Med.(Torinto)*, Sept.88 (3): 233-7.
24. Catheline, J Rizk, N and Champault G (1999): Comparison of laparoscopic ultrasound versus cholangiography in the evaluation of the biliary tree during laparoscopic cholecystectomy. *Eur. J. of Ultrasound* (10):1-9.
25. Usal H, Sayad P, Hayek N et al. (1998): Major vascular injuries during laparoscopic cholecystectomy. An institutional review of experience with 2589 procedures and literature review. *Surg. Endosc.*, 12 (7): 960-2.
26. Sharma AK, Rangan HK, Choubey RP (1998): Mini-lap cholecystectomy: a viable alternative to laparoscopic cholecystectomy for the third world?. *Aust-N-Z-J-Surg.*, 68 (11): 1147.