

SENTINEL LYMPHADENECTOMY IN BREAST CANCER: TECHNIQUE AND RESULTS

By

Sherif Ismail Maamoun

Ass. Prof. Surgical Oncology ,National Cancer Institute ,Cairo University, Egypt

Axillary lymphatic mapping and sentinel lymphadenectomy is becoming an important surgical technique for assessing axillary nodal status in breast cancer. The sentinel lymph node procedure enables selective targeting of the first draining lymph node avoiding unnecessary axillary dissection in selected cases.

Material and methods: 120 patients with operable breast cancer were included in the study period November 1996-June 2000. Patent blue dye was used to map the axilla and identify the sentinel lymph node, which was dissected separately and submitted for histopathologic examination. Completion axillary node dissection was carried out in all cases. Success and accuracy of the technique were evaluated.

Results: Sentinel lymph node was identified in 100 cases (83%) and accurately predicted axillary status in 99 cases (99/100 or 99%). All failures occurred in the first half of the study with none encountered in the second half. There was one false negative case (1%). The positive and negative predictive values of the technique were (100%) and (90.9%) respectively. Anatomic level of sentinel lymph node was recorded and 20% of patients (20/100) had the sentinel node located at level II only, which could have been missed by axillary sampling techniques.

Conclusion: The technique of axillary sentinel lymphadenectomy is accurate providing detailed information about axillary status in breast cancer. It could avoid complete axillary dissection in node negative breast cancer patients.

Key Words: Sentinel Lymph Node, Breast Cancer

INTRODUCTION

Axillary lymph nodes together with tumor size remain the two most important prognostic factors in breast cancer (1). Current standard of care for management of breast cancer entails complete tumor removal with documented negative margins either by lumpectomy or mastectomy followed by complete axillary dissection (2). Total axillary dissection has always been carried out as an integral part of any breast cancer operation. However, such procedure is associated with morbidity in 15-20% of cases namely lymphoedema, paraesthesia and arm motor dysfunction (3). With increasing evidence that axillary dissection is primarily a staging procedure alternatives to total axillary dissection were introduced e.g. axillary sampling, node picking and low axillary dissection. All these techniques,

however, remain inaccurate with reported failures of 15-25% (5). The concept of the sentinel node as the first lymph node in the direct drainage pathway from primary tumors was first developed in melanoma patients by Morton & Colleagues (4). Several investigators have since demonstrated that the concept of lymphatic mapping and sentinel lymph node (SLN) biopsy applies equally well to breast cancer. Such procedure could with high degree of accuracy predict status of axillary lymph nodes (1). The following work was carried out to evaluate the validity of the procedure.

PATIENTS AND METHODS

120 patients with potentially curable breast cancer were included in the study period November 1996-June

2000. Criteria for patients' selection included those with operable breast cancer where initial therapy entailed surgical resection. Preoperative tissue diagnosis was obtained either by FNAC (fine needle aspiration cytology) (30 patients), open biopsy (25 patients), lumpectomy (22 patients), or frozen section examination (43 patients). All patients underwent technique of SLND (Sentinel Lymph Node Dissection) followed immediately by completion axillary evacuation removing levels I, II & III.

Technique:

The technique has been described in detail elsewhere⁽¹⁾. Our technique varied during the study period. Initially, 5 cc of patent blue dye (Azul Patente V, 2.5% solution, Guerbet, France) was injected intraparenchymally around the tumor or tumor bed (lumpectomy patients) followed by completion to modified radical mastectomy. Following flap elevation and as axilla was approached, any blue stained cluster of tissue was carefully dissected, examined for the presence of blue lymph nodes, which were submitted as separate specimen for histopathology. This technique was adopted in the first twenty cases and was performed through the standard mastectomy incision. The aim was to get acquainted with the technique and to get better understanding of different patterns of dye spread within breast parenchyma and axilla. In the remaining one hundred patients, technique was modified; following the dye injection a lag period of about 10 minutes was allowed, during which firm massage was constantly applied to the tumor region. The axilla was entered through a separate transverse incision below the hairline in the planned mastectomy incision. Any blue lymph tract was traced proximally to verify its origin from the breast, thence followed to its draining node which was dissected free (Figures 1, 2, 3); a completion modified radical mastectomy was carried out.

In all cases the anatomic level of sentinel node was recorded. All specimens were examined with routine pathologic techniques using H&E (Haematoxylin and Eosin) stain. Repeat sectioning from sentinel nodes was required in three cases and Immunohistochemistry (Cytokeratin) was used in two cases, where the sentinel lymph node was negative while one or more axillary nodes were positive. The Statistical Package for Social Science (SPSS) was used in analysis.

RESULTS

One hundred twenty patients were included in the study. The median age was 50 years (range 30-65). Seventy-five patients (62.5%) were premenopausal (Table 1).

Ninety patients (75%) had preoperative clinically positive axillary nodes. Twenty patients (22.2%) turned out negative on histopathologic examination. Of the thirty patients (25%) with clinically negative nodes, twenty patients (66.7%) converted to positive at final pathological examination. Sensitivity of clinical examination was 78% with a specificity of 33%. Blue stained nodal tissue was identified in 100 patients (83.3%). In the remaining 20 patients (16.7%), either the whole axilla was stained blue (15 patients) and no definite localized area could be identified or no dye at all could be visualized (5 patients). All failures were encountered in the first 60 patients and were primarily related to time lag from dye injection until axilla was dissected, or to failure to inject the dye in the parenchyma around the lesion due to previous scarring. Total number of sentinel nodes identified was 150 with an average of 1.5 nodes per case.

Comparing pathologic data of SLND (Sentinel Lymph Node) to those obtained from NSLN (Non-Sentinel Lymph Node) assessed accuracy of technique. SLND accurately detected axillary nodal status in 97 patients (97/100, 97%). The overall sensitivity of SLND was 97.1% with a specificity of 100%. Positive and negative predictive values were 100 % and 90.9% respectively.

In three cases, the SLND was negative while at least one axillary node was positive. Further pathologic study of these negative nodes revealed one positive node when multiple sections were examined. In the remaining two cases immunohistochemistry using antibodies to Cytokeratin was used, which could identify metastatic disease in one case thus total failure was (1/100) (1%).

Twenty patients had only one positive axillary node and at least one SLND. These cases were further analyzed. There were a total of 240 nodes examined in these patients of which 25 were sentinel. Of the 25 sentinel nodes examined, tumor cells were identified in 15/25 (60%) and only in 2/215 non-sentinel nodes (0.93%) ($P < 0.00001$). It is thus extremely unlikely that dye uptake by involved nodes is due to chance.

In the twenty patients with clinically negative and histologically positive nodes, a total of 300 nodes were examined, sixty were sentinel and two hundred forty were non-sentinel. There were 110 positive nodes; forty were sentinel and seventy non-sentinel. Thus in clinically negative axillae, the incidence of getting positive node on routine sampling was 70/240 (29%) versus 67% (40/60) for sentinel node identification ($p < 0.0001$).

The anatomic level of sentinel node was recorded for all cases, and in twenty patients (20%) the dye was detected in level II only, while level I nodes were negative.

Table1: Patient's Characteristics

<i>Total No. Of Cases</i>	<i>120</i>
Mean Age	50 (range 30-65)
Premenopausal	75 (62.5%)
Postmenopausal	45 (37.5%)

Table 2: Tumor characteristics

T1	10 cases (8%)
T2	70 cases (58%)
T3	40 cases (34%)
Histologically positive nodes	90 cases (75%)
Histologically negative nodes	30 cases (25%)

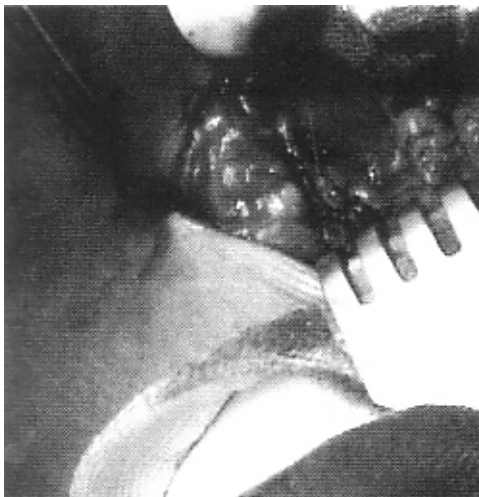

Fig. (1) : Blue-stained lymph Tract is followed down into the Axilla.

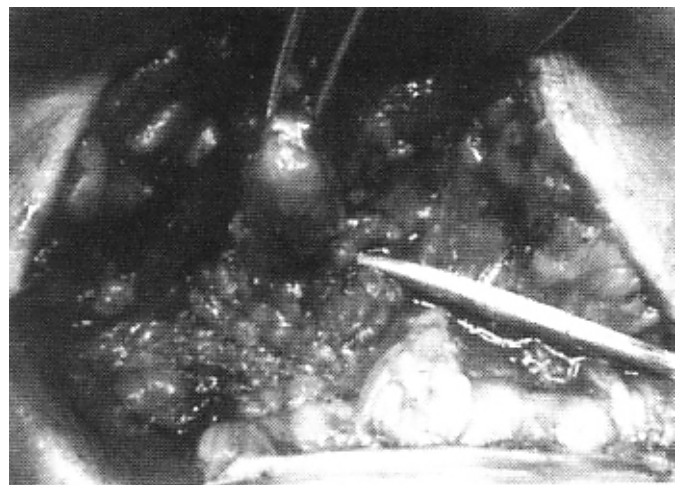


Fig. (2) : Blue Lymph node is dissected separately.

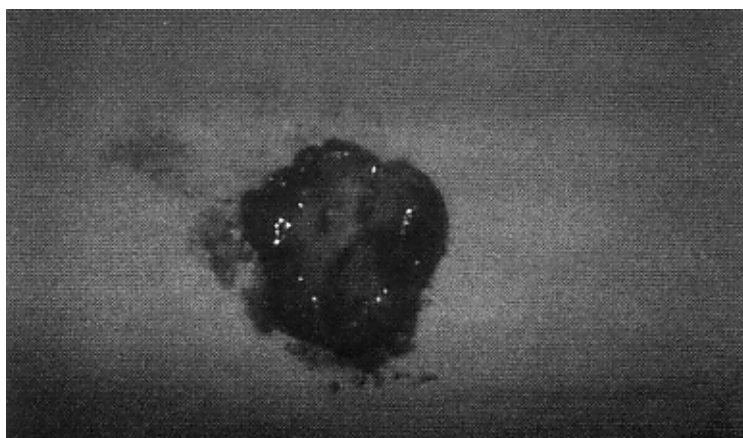


Fig. (3) : The Lymph node is bisected showing the blue dye uptake.

DISCUSSION

Treatment decisions in breast cancer are primarily related to tumor size and axillary nodal status⁽⁵⁾. Complete tumor extirpation with documented negative margins by mastectomy or lumpectomy is the current standard for management of breast cancer patients². The role of axillary dissection may be the most controversial topic in treatment of breast cancer. Total axillary dissection has always been the gold standard for management of the axilla. However, such paradigm is currently being scrutinized⁽⁶⁾. Whereas the biologic importance of axillary breast cancer nodal metastases is paramount, the benefit of axillary nodal dissection is controversial. Advocates of the procedure contend survival benefit for breast cancer patients with surgical removal of axillary nodes without adjuvant therapy⁽⁷⁾. Recent critics of axillary dissection maintain that overall survival in breast cancer depends on development of distant metastases and is not influenced by axillary dissection. Adjuvant chemotherapy and/or radiation therapy could control micrometastatic disease⁽⁸⁾. Challenging the historically held axillary dissection defies logic, as nodal status is the most statistically pertinent criteria of outcome. In addition, disregard of surgical staging combined with the use of adjuvant therapies in all patients may result in greater long term morbidity to the entire population of patients (leukemia, heart failure)⁽³⁾

Current consensus is that in node positive patients total axillary dissection should be done to avoid loco regional recurrences depicted in the range of 25% with less procedure⁽⁸⁾. In node negative patients, axillary dissection could be avoided since no survival benefit has been demonstrated⁽⁹⁾. In our series 30/120 patients (25%) could have been spared such procedure. It thus remains a challenge to find a technique that could accurately determine axillary nodal status.

Clinical examination of the axilla is far from being accurate, reported sensitivity and specificity range between 30-40%⁽⁵⁾; in our series it was 78% and 33% respectively. A high sensitivity ratio simply reflects increased number of patients with locally advanced disease in the current study. Total axillary dissection (TAD) remains the most accurate staging technique of axilla. The procedure, however, entails high morbidity, namely lymphoedema, arm dysfunction and paraesthesia⁽¹⁰⁾. Alternative procedures were introduced; nodal picking, level I & II dissection and axillary sampling¹. The inherent problems of such techniques, in addition to lack of sensitivity and specificity, are mainly absence of precise anatomic landmarks to unify procedures. 20% false negative rate is the average cited for such procedures⁽⁵⁾.

When Morton et.al (1992) reported their experience with identification of sentinel node in cutaneous malignant melanoma with dye injection technique, the same principle was adopted in breast cancer patients¹. Lymphatic mapping and sentinel node evaluation has now provided an effective tool to more efficiently define that subset of patients with micrometastatic disease and therefore may redefine the role of adjuvant chemotherapy⁽¹¹⁾. This technique would accurately stage the axilla, allowing total axillary dissection to be done only when indicated⁽¹²⁾.

Reported sensitivity and specificity of such technique was in the range of 95-100% respectively with no false negatives^(1,9). In the current series, sensitivity was 97.1% with 100% specificity. The procedure definitely carries a learning curve⁽¹³⁾. In the first half of our series, failures were high but in the second half the procedure was 100% successful. Principal points in the technique include timing of the sampling as too much time could result in complete staining of axilla defying detection of sentinel node (15 patients). Time lag of 5-10 minutes is appropriate¹. Previous lumpectomy did affect outcome (5 patients), as surrounding fibrosis and lymphatic obstruction could prevent dye dispersion. Caution should be experienced in injecting the dye in healthy tissue⁽⁷⁾. We had three false negative cases. Further sectioning could detect metastases in one case and Immunohistochemistry using antibodies to Cytokeratin confirmed presence of metastatic disease in one case, thus only one false negative case was reported in current series. Immunohistochemistry could be an added technique that will help the pathologist with further focusing on small amount of tissue instead of the whole axilla⁽¹⁴⁾.

The positive and negative predictive values of the technique were extremely significant (100% and 90.9% respectively) and compared well with those reported by others^(1,15,16). In 20% of cases, skip lesions were detected in level II only. Such would have been missed with nodal picking or sampling techniques⁽⁵⁾.

Perhaps the most essential aspect for the technique is that by providing a small specimen for focusing histopathology, accurate examination of axillary nodes would enhance detection rates for presence of macro- or micrometastases⁽¹⁷⁾. This is particularly important as more and more early cases are being diagnosed. Excellent studies have clearly demonstrated outcome differences with micrometastatic disease. Patients with early breast cancer still experience distant metastases in 10-15% of cases and such figures could reflect missed metastatic disease as pathologist could not apply detailed techniques on all axillary specimens⁽¹⁸⁾. The primary contention that micrometastatic disease has no therapeutic significance is flawed². In the current study, only two patients had their

sentinel nodes negative on routine pathological examination that later turned positive with repeat sectioning (one patient) and use of immunohistochemistry stains. Other series reported figures over 30% for detection of micrometastases in negative sentinel nodes by immunohistochemistry^(19,20). The low figure in our series is related to advanced disease stage at first presentation. However, with increasing numbers of early breast cancer, such technique would ultimately prove most valuable for staging such patients.

Axillary lymphatic mapping with sentinel lymphadenectomy provides an accurate technique that could stage the axilla, provide a small focused specimen for proper histopathology and could avoid morbidity of total axillary dissection in node negative breast cancer patients. Further studies should be directed to more refinement in the technique (combined use of radioactive isotope and dye injection), follow-up to determine rate of axillary recurrence when such technique is adopted in node-negative patients and to study effect on survival.

REFERENCES

1. Giuliano AE, Dale PS, Turner RR, Morton DL, Evans SW, and Krasne DL: Improved Axillary Staging of Breast Cancer with Sentinel Lymphadenectomy. *Ann. Surg.* 222 (3) 394-401, 1995
2. Cox CE, Bass SS, Reintgen: Techniques for Lymphatic Mapping in Breast carcinoma. *Surg Oncol Clin N Am.* 8 (3) 447-468, 1999
3. Borgstein PJ, Pijpers R, Comans EF, Van-Diest PJ, Boom RP, and Meijer S: Sentinel Lymph Node Biopsy in Breast Cancer. Guidelines and Pitfalls of Lymphoscintigraphy and Gamma Probe Detection. *J. Am. Coll. Surg.* 186 (3) 275-283, 1998
4. Morton DL, Wen DR, Wong JH: Technical Details of Intraoperative Lymphatic Mapping for Early Stage Melanoma. *Arch Surg.* 127:392-399, 1992
5. Veronesi U, Galimberti V, Zurrada S, Pigatto F, Veronesi P, Robertson C: Sentinel Lymph Node Biopsy as an Indicator for axillary dissection in Early Breast Cancer. *Eur J Cancer.* 37: 454-458. 2001
6. Dees EC, Shulman LN, Souba WW, and Smith BL: Does Information from Axillary dissection Change Treatment in Clinically Node-Negative Patients with Breast Cancer? "An Algorithm for Assessment of Impact of Axillary Dissection". *Ann. Surg.* 226 (3) 279-287, 1997
7. Giuliano AE, Kirgan DM, Guenther JM, and Morton DL: Lymphatic Mapping and Sentinel Lymphadenectomy for Breast cancer. *Ann. Surg.* 220 (3) 391-401, 1994
8. Haffy BG, Ward B, Pathare P: Re-appraising of the Role of Axillary Lymph Node Dissection in Conservative Treatment of Breast Cancer. *J Clin Oncol.* 15:691-700, 1997
9. Miner TJ, Shriver CD, Jaques DP, Maniscalco-Theberge ME, and Krag DN: Sentinel Lymph Node Biopsy for Breast Cancer: The Role of Previous Biopsy on Patient Eligibility. *Ann. Surg.* 65 (6) 493-499, 1999
10. Kern KA: Breast Lymphatic Mapping Using Subareolar Injection of Blue Dye and Radiocolloid: Illustrated Technique. *J Am Coll Surg.* 192: 545-550. 2001
11. Orr RK, Hoehn JL, and Col NF: The Learning Curve for Sentinel Node Biopsy in Breast Cancer: Practical Considerations. *Arch. Surg.* 134 (7) 764-767, 1999
12. Bedrosian I, Reynolds C, Mick R, Callans LS, Grant CS, Donohue JH: Accuracy of Sentinel Lymph Node Biopsy in Patients with Large Primary Breast Tumors. *Cancer.* 88: 2540-5. 2000
13. Pendas S, Dauway E, Cox CE, Giuliano R, Ku NN, Schreiber RH, and Reintgen DS: Sentinel Node Biopsy and Cytokeratin Staining for the Accurate Staging of 478 Breast Cancer Patients. *Ann. Surg.* 65 (6) 500-506, 1999
14. Shaw JHF and Rumball: Complications and Local Recurrence Following Lymphadenectomy. *Br. J. Surg.* 77, 760-764, 1990
15. Turner RR, Ollila DW, Krasne DL, and Giuliano AE: Histopathologic Validation of the Sentinel Lymph Node Hypothesis for Breast carcinoma. *Ann. Surg.* 266(3) 271-278, 1997
16. Veronesi U, Paganelli G, Galimberti V: Sentinel Node Biopsy to Avoid Axillary Dissection in Breast Cancer with Clinically Negative Lymph Nodes. *Lancet* 349:1864, 1997
17. Viale G, Bosari S, Mazzarol G, Galimberti V, Luini A, Veronesi P, Paganelli G, Bedoni M, and Orvieto E: Intraoperative Examination of Axillary Sentinel Lymph Nodes in Breast Carcinoma Patients. *Cancer* 85 (11) 2433-2438, 1999
18. White RE, Vezeridis MP, Konstadoulakis M: Therapeutic Options and Results for the Management of Minimally Invasive Carcinoma of the Breast: Influence of Axillary Dissection for Treatment of T1a and T1b lesions. *J Am Coll Surg.* 183:575-582, 1996
19. Noguchi M, Tsugawa K, Miwa K, Yokoyama K, Nakjama KI, Michigishi T: Sentinel Lymph Node Biopsy in Breast Cancer Using Blue Dye with or without Isotope Localization. *Breast Cancer.* 7: 287-96, 2000
20. Motomura K, Inaji H, Komoike Y, Kasugai T, Nagumo S, Noguchi S: Intraoperative Sentinel Lymph Node Examination by Imprint Cytology and Frozen Sectioning during Breast Surgery. *Br J Surg.* 87: 597-601. 2000