



Effect of Synbiotic Supplementation on The Growth and Hematological Attributes of Broiler Chicken (*Gallus Gallus*) Infected with Coccidiosis

Parveen S.¹, Nawaz M.^{1*}, Saleem M.U.², Gulzar S.¹, Maqsood A.¹, Gulzar M.³, Farooq A.A.⁴, Javaid M.A.² and Basit A.²,



¹Department of Environmental Sciences, Bahauddin Zakariya University, Multan, Pakistan.

²Department of Bioscience, Faculty of Veterinary Sciences, Bahauddin Zakariya University, Multan, Pakistan.

³Department of Botany, Women University, Multan, Pakistan.

⁴Department of Clinical Sciences, Faculty of Veterinary Sciences, Bahauddin Zakariya University, Multan, Pakistan.

Abstract

THIS STUDY was conducted to examine the effects of synbiotics against coccidiosis infected broilers based on growth performance, and selected hematological attributes (RBCs, WBCs, hemoglobin, ALT, AST, uric acid, triglyceride, and glucose). The main objectives of this study were to evaluation the negative impacts of coccidiosis, and amelioration of its harmful effects by using synbiotic (dicladox 1ml/5l and protexin 1mg/5l of water in a ratio of 1:1). The whole experiment was conducted in an environmentally control shed. A total number of 120-day old broiler chickens were selected, and on 21st day were equally divided into four groups with each group having 3 replicates (n=10). The details of the grouping are T₀ (negative control), T₁ (Positive control), T₂ (supplemented with synbiotic, and basal diet while T₃ treated with basal diet, synbiotic, and infection (3.0 ×10⁴ oocytes). Results revealed that supplementation of synbiotic significantly improved broilers' growth performance, and hematological attributes during 5th, 10th, and 15th days of samplings. The T₁ group exhibited significant decrease in growth, and selected hematological parameters however, after treating with synbiotic the negative effects of coccidiosis were significantly decreased. Moreover, T₃ showed positive improvements in all parameters under study. Maximum growth of organs on 15th days of sampling was found higher in infected group of birds as in spleen (109.09%), kidney (15.79%), gizzard (21.60%) and liver (44.09%) at (P ≤ 0.05). Furthermore, no lesions and oocyte shedding were observed in T₀ but the aforementioned parameters were found higher in T₁. It was concluded that supplementation of synbiotic improved production performance of broilers and selected blood indices of broilers infected with coccidiosis.

Keywords: Coccidiosis, synbiotic, growth, hematological parameters.

Introduction

Coccidiosis is among the major diseases of broilers causing great economic loss to the poultry industry [1], which has been reported to be up to 11.2% in Economic Survey of Pakistan 2020-21 [2]. It is a protozoan disease, which causes a loss of almost three billion dollars worldwide [3] Coccidiosis is caused by genus *Eimeria* and phylum apicomplexan. The transmitting agent of this disease are the oocytes that are excreted in the feces of infected birds, which enter healthy birds through oral route [4]. Sporulated oocytes are responsible for the transmission of disease, which is more contagious [5]. Coccidiosis has been reported to exhibit clinical as well as sub clinical symptoms in infected birds. Subclinical

infection includes the suppression of feed intake [6], while clinical infection includes diarrhea, anorexia, depression, weakness, continent pain, dehydration, pallid mucous surfaces, higher mortality, and sudden loss of weight. Most common season for breakout of this disease is monsoon [7]. The most common species include *E. brunetti*, *E. maxima*, *E. necatrix*, *E. mitis*, *E. praecox*, *E. tenella* and *E. acervuline*. More likely these species are site specific and causes infections on different parts of small intestines [8]. Broilers of any stage of life are susceptible to coccidiosis but higher frequency of this disease is observed among young broilers whereas, mortality rates are higher among 3rd week [9].

*Corresponding authors: Nawaz M., E-mail: mnawaz@bzu.edu.pk, Tel.: 03007197054

(Received 13 May 2024, accepted 05 August 2024)

DOI: 10.21608/EJVS.2024.289256.2087

©National Information and Documentation Center (NIDOC)

Many methods have been applied for treating this disease and initially antibiotics were used. However, the use of antibiotics was banned by European Union. After the ban on the use of antibiotics, antibiotic growth promoter (AGP) were used to minimize the economic loss to the industry by certain diseases, which also includes coccidiosis [10]. Several authors have investigated the potential effects of some natural substances that can replace antibiotics for overcoming the hazardous effects of coccidiosis, which mainly include probiotics, prebiotics, phytobiotics, engineered peptides, enzymes and organic acids [11] however, according to the results reported the till now the efficacy of AGPs is far less as compared to antibiotics. When compared with antibiotics, AGPs are cost effective and have pronounced beneficial effects on gut flora, liver, kidney thus, increasing body weight, and certain histo-physiological parameters. The AGPs also prevent infection, inflammation, lower intestinal pH, inhibit the growth of pathogenic bacteria of intestine, and reduce *Eimeria* oocysts shedding [12]. Synbiotics are combination of prebiotics, and probiotics having the potential to decrease the harmful effects of stressors exposed to broilers. Moreover, synbiotic increases the number of gut friendly bacteria. Keeping in view of harmful effects of coccidiosis on broiler health and the potential of synbiotic to overcome it, this study was designed to investigate the potential of synbiotic in ameliorating the harmful effects of coccidiosis by investigating certain growth, and hematological aspects.

Materials and Methods

Experimental setup

The experiment was conducted in an environmentally control shed whereas the examination of selected parameters was executed in the laboratory of Department of Environmental Science, Bahauddin Zakariya University (BZU) Pakistan. For this experiment, 150-day old broiler chicks (*Gallus gallus*) were purchased from a commercial hatchery, having average body weight of 40 g, which were kept under environmentally controlled conditions [13]. All the procedures related to animals were conducted according to the Animal Care, and Ethical guidelines of the university.

Experimental design

A total of 150-day old chicks (*Gallus gallus*) with uniform body weight of (40gm) were selected for experiment, which were given basal diet (TABLE 1), and normal water randomly for 14 days. After 21 days of supplementation these 120 chicks were screened for experiment based on their average body weight i-e-800g, equal size, and uniform health conditions. These chicks were divided in four groups with each group having three replicates (n=10). Samples were taken for analysis of selected parameters on 5th, 10th, and 15th day of treatment

respectively. The treatment design for each group was set as:

Group 1 (Negative Control) = Basal diet + No *E. tenella* infection + No synbiotics named as T₀

Group 2 (Positive Control) = Basal diet + *E. tenella* infection + No synbiotic kept as T₁

Group 3= Basal diet + No *E. tenella* infection + synbiotics kept as T₂

Group 4= Basal diet + *E. tenella* infection + synbiotics kept as T₃

Preparation of Synbiotic and Basal diet

By following the method of [14] synbiotic was prepared by mixing the diClacox (Prebiotic), and protexin (probiotic) by 1:1 in 5 ml of distilled water. DiClacox manufactured by UM enterprises was purchased by Asghar poultry medicine store near clock tower Ghanta Ghar Multan, Pakistan containing diClazuril 10mg in liquid solution. While Protexin manufactured by Hillton Pharma (pvt) Ltd. was also purchased by scientific store Multan Cant. Protexin contains *Lactobacillus plantarum*, *Lactobacillus bulgaricus*, *Lactobacillus acidophilus*, *Lactobacillus rhamnosus*, *Bifidobacterium bifidum*, *Streptococcus thermophilus*, *Enterococcus faecium*, *Aspergillus oryzae* and *Candida pintolopesi*. 5 ml of prepared solution of synbiotic was applied to each chicken on daily basis through 10CC syringe. The percentage composition of the ingredients for basal diet was set in line as in previously used by [15] given in (TABLE 1).

Disease development and exposure

Eimeria species were identified by a combination of oocyst size, location in the gut, appearance of the lesions, and schizont size [16, 17]. Mucosal scrapings, and tissues were examined using a light microscope. *Eimeria* oocysts were isolated from caecal, and lower intestinal mucosa using saturated sodium chloride floatation solution following the procedures mentioned by [18].

Assessment of selected parameters

Sampling was done on the 5th, 10th and 15th days of exposure to coccidiosis and synbiotic. On each day of sampling three broiler of uniform sized from each replicate were slaughtered, and analyzed for respective parameters. For analysis of growth parameters, organ weight (g) of liver, gizzard, spleen, gastrointestinal tract, and kidney were measured by using digital electronic balance. As coccidiosis induces equal impacts on internal, and external body conditions of broilers therefore, lesion spots on intestines, oocyst shedding, feed intake (FI), and live body weight (BW) were measured by following the method [19]. Blood sample (5ml) was also taken on each day of sampling for the hematological parameters. RBCs

(10^6 /UL) and WBCs (10^3 /UL) were measured with the help of Neubauer hematological chamber technique [20] while blood serums quantities (Glucose (mg/dL), Uric acid (mg/dL), Total protein (g/L), Aspartate transaminase (AST) (IU/L), Alanine transaminase (ALT) (IU/L), Hemoglobin (g/dL), Triglycerides (mg/dL), and Albumin (g/dL)) were analyzed by using standard Miura Kit (One I.S.E S.r.l) according to the method of [20].

Statistical analysis

The collected data was analyzed statistically by using excel sheets, and statistix 8.1 version. For the calculation of mean, and standard error, MS office-2010 was used, while Analysis of variance (One Way ANOVA) was done through statistical software statistix 8.1. Significant difference between the treatments was also observed through the Duncan Multiple Range Test (DMRT) [21]. The differences were considered significant at $P \leq 0.05$.

Results

Effect of coccidiosis and synbiotic supplementation on growth parameters

Significant differences were observed between the groups treated with synbiotics and group T1. Notable variations in the organ weights of broiler chickens were observed across all groups during the three-day sampling period. In our study, the intestinal weight, as depicted in Fig 1 ("Graph a"), was found to increase in the infected group (T1) compared to T0, and the other groups. Significant results were observed on the 5th day of sampling, with a 16.11% increase noted, followed by increases of 19.94%, and 29.44% on the 10th, and 15th days of sampling, respectively, compared to T0. The supplemented group (T2) exhibited a similar significant pattern of changes to T0 in terms of intestinal weight, while T3 showed a significant recovery, with increases of 13.02%, 15.34%, and 4.23%, respectively, compared to the infection group.

Kidney weight, as shown in Fig 1 ("Graph b"), also exhibited a significant increase in surface area in T1, with increases of 41.86%, 21.57%, and 26.32%, significantly higher than T0. In comparison, T2 showed normal kidney growth weights, with reductions of 2.33%, 7.85%, and 1.32% compared to T1. In contrast, T3, exposed to the infection, displayed a significant recovery rate, with increases of 13.95%, 1.96%, and 15.79%, respectively, compared to T1.

Spleen weight Fig 1 ("Graph c") followed a similar pattern of results, with increases of 109.09%, 68.42%, and 62.50%, respectively, compared to T0. Conversely, T3 showed a significant decrease in spleen weight, with reductions of 63.64%, 47.37%, and 33.33%, respectively, compared to T0.

As shown in Fig 1 ("Graph d"), gizzard weight significantly increased in the T1 group, with increases of 21.60%, 13.11%, and 17.95%, respectively, compared to T0. The results for T2 were similar to those of T0. However, the gizzard weight of T3 significantly decreased, indicating a recovery rate of 4.32%, 7.65%, and 8.55%, respectively, compared to T1.

In Fig 1 ("Graph e"), the liver weight (in grams) was notably increased by 20.08%, 16.24%, and 23.10% due to infection in T1 when compared to the other groups. In contrast, T2 exhibited a significant decrease of 7.79%, 2.87%, and 5.58% in the liver weight compared to T0. Meanwhile, T3 showed significant improvements of 5.04%, 5.09%, and 15.99% respectively, compared to T1.

Effect of coccidiosis and synbiotic on physical and internal body conditions

The impact of synbiotic treatment and infection had a significant effect on the body weight, and feed intake of broiler chickens. As depicted in Fig 2 ("Graph a"), the body weight of T1 decreased significantly compared to the other groups. There was a notable reduction in body weight, with decreases of 38.95%, 22.97%, and 27.95%, respectively, while T2 exhibited a significant increase in body weight, with gains of 16.34%, 9.53%, and 18.73%, respectively, compared to T0. The decrease in body weight in the infected group, and the increase in the synbiotic-supplemented group can be attributed to protozoan illness, which leads to metabolic disruption, gastrointestinal tract disturbances, and reduced organ efficiency. In contrast, T3 showed a significantly higher rate of recovery, with increases of 32.61%, 10.36%, and 16.46%, respectively, compared to T1.

Feed intake in T1 was significantly reduced by 23.93%, 21.65%, and 24.38%, respectively, due to infection compared to the control group, as shown in Fig 2 ("Graph b"). Conversely, in the group (T2) supplemented with synbiotic, feed intake significantly increased by 11.82%, 7.50%, and 9.08%, respectively, compared to the other groups. When compared to T1, T3, treated with both infection, and synbiotic, displayed a significant recovery rate of 17.8%, 4.37%, and 8.31%, respectively. Throughout the experiment, it was observed that body weight, and feed intake in T3 were positively influenced by synbiotic treatment, even in the presence of infection. Our results also indicate that synbiotic treatment, and infection had significant effects on lesion formation, and oocyte shedding during all three sampling phases.

There were no lesions, and oocyte shedding in T0, but T1 exhibited a significant increase in lesion production, with increases of 472.30%, 796.77%, and 1136.25%, respectively, as presented in Fig 2 ("Graph c").

In contrast, T3 showed a significant reduction in lesion formation by 2.52%, 1.74%, and 0.00%, respectively, compared to T1, and no lesions were found in the synbiotic-treated group of chickens. As shown in Fig 2 ("Graph d"), there were no cases of oocyte shedding in T0 or in the synbiotic-treated groups of chickens. However, T2 displayed a significant increase in oocyte shedding by 6.65%, 8.78%, and 9.40%, respectively, compared to T0. Meanwhile, T3 exhibited a reduced number of oocyte shedding compared to both T0, and T1, with reductions of 235.08%, 111.27%, and 0.07%, respectively.

Effect of coccidiosis and synbiotic on hematological parameters

As shown in Fig 3 ("Graph a"), both infection, and synbiotic supplementation had a significant impact on the red blood cell (RBC) counts in broiler chickens. In group T1, there was a substantial decrease in RBC counts, with reductions of 71.23%, 42.99%, and 39.32%, respectively, compared to T0. Conversely, in T2, there was an increase in RBC counts by 29.86%, 20.93%, and 14.41%, respectively, compared to the other groups. T3 exhibited a significant recovery in RBC counts, with increases of 52.32%, 34.77%, and 19.72%, respectively, compared to T0 and T2.

The white blood cell (WBC) count also exhibited a pattern similar to RBCs, influenced by both infection, and synbiotic supplementation, as depicted in Fig 3 ("Graph b"). In T1, there was a significant decrease in WBC counts, with reductions of 48.37%, 38.63%, and 54.49%, respectively, compared to T0. On the other hand, T2 displayed a significant increase in WBC counts, with elevations of 12.72%, 15.35%, and 12.28%, respectively, compared to the rest of the groups. T3 showed a notable recovery rate in WBC counts, with increases of 12.22%, 24.15%, and 24.32%, respectively, compared to the infected and synbiotic-treated groups.

In this study, liver enzymes aspartate aminotransferase (AST), and alanine aminotransferase (ALT) were significantly increased in infected chickens compared to the uninfected group. As illustrated in Fig 4 ("Graph a"), AST levels significantly increased in T1, with elevations of 10.52%, 9.25%, and 10.74%, respectively, compared to T0. Conversely, T2 exhibited results nearly equal to T0, with minimal variations of 0.79%, 0.93%, and 0.22%, respectively. T3 demonstrated a recovery rate, with decreases of 4.46%, 5.70%, and 7.20%, respectively, compared to T1.

Regarding ALT levels, shown in Fig 4 ("Graph b"), there was a significant increase of 89.40%,

55.64%, and 44.93%, respectively, in T1 compared to T0. However, in T2, ALT levels were within the range observed in T0. In contrast, T3 showed significantly lower ALT levels, reduced to 49.23%, 30.70%, and 28.24%, respectively, compared to T1. Uric acid levels, presented in Fig 4 ("Graph c"), were increased by 59.23%, 45.70%, and 38.24%, respectively, in T1 compared to T0, while no significant increase was observed in T0. In T3, uric acid levels were significantly lower, reduced by 39.23%, 25.70%, and 18.24%, respectively.

There was also a significant impact of infection, and synbiotic supplementation on blood serums. As seen in Fig 5 ("Graph a"), glucose levels (mg/dL) were significantly affected by infection. In T1, there was a substantial reduction of approximately 36.50%, 15.28%, and 15.09%, respectively, in blood glucose levels. In contrast, administration of synbiotic in T2 significantly increased glucose levels by 10.41%, 4.83%, and 4.39%, respectively, compared to the other groups. T2, and T3 showed a minor decrease compared to T1, with recovery rates of 22.17%, 6.68%, and 11.62%, respectively. Hemoglobin levels (g/dL), as shown in Fig 5 ("Graph b"), decreased significantly by 50.70%, 41.82%, and 30.11%, respectively, due to infection in T1 compared to the other groups. However, T2 exhibited a significant increase of 11.95%, 20.01%, and 8.63%, respectively, in hemoglobin levels compared to the other groups, while T3 showed significant improvement of 31.80%, 16.26%, and 17.20%, respectively, compared to T1.

Total protein levels (g/dL) in the blood, as illustrated in Fig 5 ("Graph c"), significantly decreased by 20.08%, 16.24%, and 23.10%, respectively, due to infection in T1 compared to the other groups. T2 showed a significant increase of 7.79%, 2.87%, and 5.58%, respectively, in total protein levels compared to T0. In contrast, T3 exhibited significant improvement of 5.04%, 5.09%, and 15.99%, respectively, compared to T1. Similar trends Fig 5 ("Graph d") were observed for albumin (g/dL) in the blood serum. In T1, there was a decrease of 14.12%, 19.44%, and 24.36%, respectively, compared to T0 and the other groups. T2 displayed normal albumin levels in the blood, with variations of 5.65%, 5.5%, and 4.73%, respectively, compared to the other groups. T3 demonstrated significant improvement of 9.04%, 13.42%, and 22.91%, respectively, compared to T1.

However, the case of triglyceride levels (mmol/L) in the blood, as shown in Fig 5 ("Graph e"), was different from other blood serum parameters. In T1, there was an increase of about 2.71%, 5.01%, and 5.41%, respectively, compared to T0. While in T2, there was a significant decrease of

0.97%, 0.45%, and 0.83%, respectively, in triglyceride levels compared to T0. Likewise, T3 triglyceride levels showed improvement of 0.86%, 3.91%, 2.63%, respectively, compared to T1.

Discussion

The results obtained in current study were also supported by the findings in previous literature. In the infectious groups, organ weights were found to be higher than normal due to inflammation, as previously reported by [22]. Coccidiosis leads to inflammation of the inner intestinal walls, resulting in hemorrhages and a collapsed epithelial wall, often leading to death. These results are parallel to those of El-Maddawy et al. [23], who found limited improvement with nanoparticle supplementation, while highly positive outcomes were observed in synbiotic+diclazuril group. The present study aligns with previous research by Ahmad et al. [24], who treated coccidian-infected chickens with aloe vera, observing reductions in caecal, and intestinal lesions, as well as caecal, and intestinal oocysts. Similarly, Chalorsuntisakul et al. [25] found that synbiotics can mitigate the harmful effects of coccidiosis, albeit not completely eliminating symptoms, as indicated by reduced lesion scores, and oocyst shedding. Györke et al. [26] also reported comparable results, noting extreme bloody diarrhea, and high oocyst shedding in infected chickens. These findings collectively underscore the potential protective effects of aloe vera, and synbiotics in ameliorating the impacts of coccidiosis in poultry. The results of the current experiment showed that coccidiosis increased the height of villus, reflecting structural damage to the intestinal mucosa. This is similar to research by [15], who found that intestinal inflammation was caused by pathogenic activity, and toxins, which led to increased villus height in coccidiosis. The administration of nutritional supplements, and organic acids resulted in a rise in the number of jejunal goblet cells, hence increasing the growth of mucus membranes.

This study demonstrates that synbiotic supplementation significantly stimulated body weight and feed intake, in accordance with the findings of Duff et al. [27], where fructo-oligosaccharide, and synbiotic feed supplements improved body weight, and feed intake in broilers exposed to infection. The findings from Hussein et al. [19], observed decreased growth parameters in broilers challenged with *Clostridium perfringens*. Similarly, [28] noted a significant decrease in growth performance of chickens infected with *E. tenella*, but supplementation with zinc oxide, and nanoparticles improved feed utilization, and growth.

Prior studies by Yan et al. [29] have also explored the impact of various interventions on RBCs, and WBCs, observing similar trends of reduction in RBCs, and increase in WBCs during

infection. [20,30] found that synbiotics influenced RBCs, and WBCs, tending to improve their counts. Furthermore, Al-Baadani et al. [31] studied broilers exposed to *clostridium perfringens*, and found improvements in hematological parameters when treated with synbiotics.

Gilbert et al. [22] reported an increase in AST, and ALT levels in broilers infected with *Eimeria* species. Hussein et al. [19] also observed increased AST, and ALT levels during infection. Al-Baadani et al, Ali et al. [31, 32] found increases in glucose, total protein, hemoglobin, triglycerides, and albumin levels in infected birds. M ALI et al. [33] noted that severe loss caused by *E. tenella* infection was influenced by synbiotic supplementation.

Our research's findings showed that using a synbiotic supplement allowed uric acid levels to return to a normal range because, the *Eimeria tenella* species is the one that causes uric acid to rise. While in previous study of [32], there was non-significant increase in uric acid was observed this may be due to *E. acervulina* species oocysts.

According to Ali et al. [32], synbiotics enhanced the gut environment, improving digestion, and nutritional absorption while lowering parasitic damage and raising the bioavailability of vital minerals. The current research found that globulin levels had decreased in infected groups. However, Klasing et al. [34] did not find any variations in globulin levels between the positive, and negative control birds. This might be because *Clostridium perfringens* was less active or the damage had changed from acute to chronic. Comparably, Abdel-Azeem et al. [35] found that birds undergoing abiotic treatment had increased globulin concentrations, suggesting better food absorption and utilization.

Conclusion

It is concluded that coccidiosis adversely effects the health of broilers by decreasing growth performance, and negatively altering the hematological parameters. Our results reveal that the detrimental effects of coccidiosis can be minimized with synbiotic supplementation. The results of this study are indicative that coccidia infected birds exhibited significant recovery in growth performance, and hematological parameters after synbiotic supplementation. The above results reveal that synbiotics (diclazox and protexin) alleviate negative effects of coccidiosis. Nexus to the above it can be concluded that synbiotic (diclazox and protexin) reduces the harmful effects of coccidiosis in broilers.

Conflict of Interest

All authors declares no any conflict of interest

Acknowledgement : Not applicable

Funding Source : No fund received in this regard

TABLE 1. Percentage composition of ingredients for basal diet given to broilers (Saleem et al. 2019).

	Starter Diet (1-10 days)	Grower diet (11-21 days)	Finisher Diet (21-35days)
Ingredients (%)			
Corn	56.2	59.9	63.34
Soyabean oil	2.26	3.3	3.94
Soyabean meal	37.11	32.55	28.71
Dicalcium phosphate	1.92	1.86	1.74
Oyster shell	1.16	1.12	1.06
Common salt	0.3	0.3	0.3
Vitamin premix 1	0.25	0.25	0.25
Mineral premix 2	0.25	0.25	0.25
L-Lysine hydrochloride	0.24	0.21	0.18
DL-Methionine	0.31	0.26	0.23
Nutrient Composition			
ME, kcal/kg	3000	3105	3180
CP, %	21.23	19.46	18
AP, %	0.50	0.48	0.45
Ca, %	1	0.96	0.9
Lysine, %	1.32	1.19	1.06
Methionine + cysteine, %	0.98	0.89	0.82

ME, metabolizable energy; AP, available phosphorus; CP, crude protein. 1Vitamin premix supplied the following per kg of diet; vitamin A, 18000U; vitamin D3, 4000U; vitamin E, 36mg; vitamin K3, 4mg; vitamin B12, 0.03mg; thiamine, 1.8mg; riboflavin, 13.2mg; pyridoxine, 6mg; niacin, 60mg; calcium pantothenate, 20mg; folic acid, 2mg; biotin, 0.2 mg; choline chloride, 5000mg. 2Mineral premix supplied the following per kg of diet; Cu, 20mg; Fe, 100mg; Mn, 100mg; Se, 0.4mg; Zn, 169.4mg.

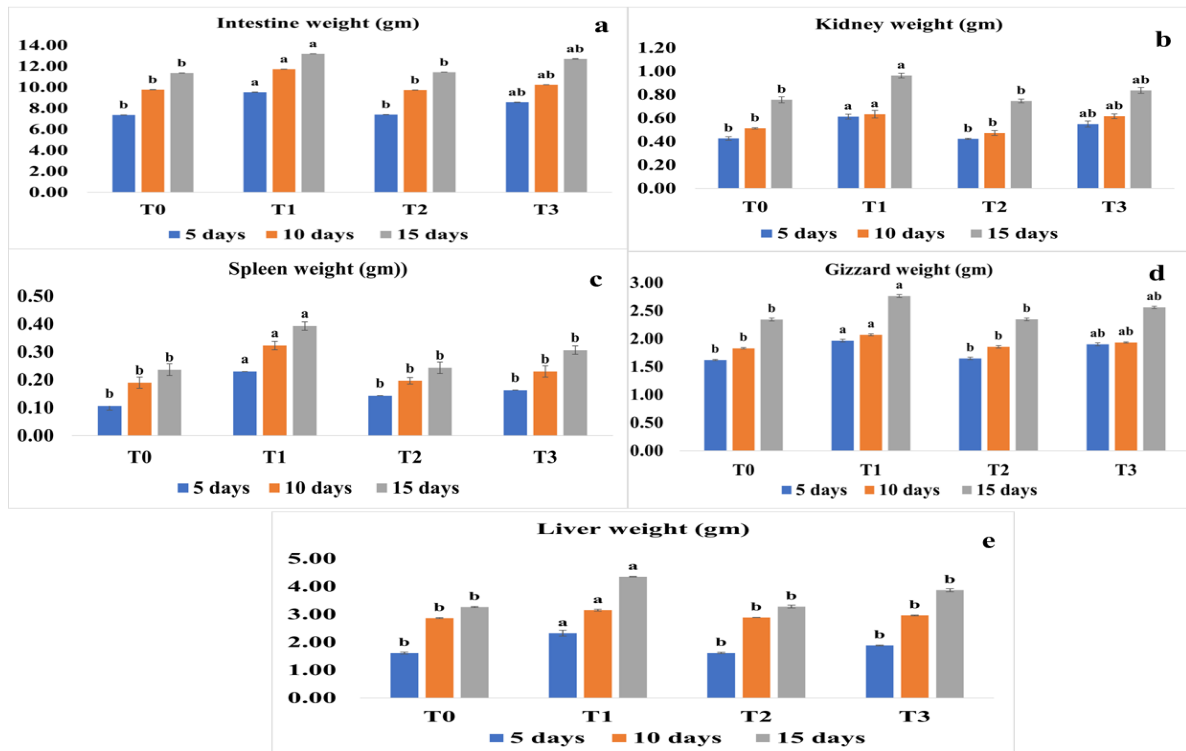


Fig. 1. Effect of infection and synbiotic on the weight (g) of organs of broiler on the 5th, 10th and 15th days of analysis (a) Intestinal weight (b) Kidney weight (c) Spleen weight (d) Gizzard weight (e) Liver weight. While significance value of all parameters is (P<0.05)

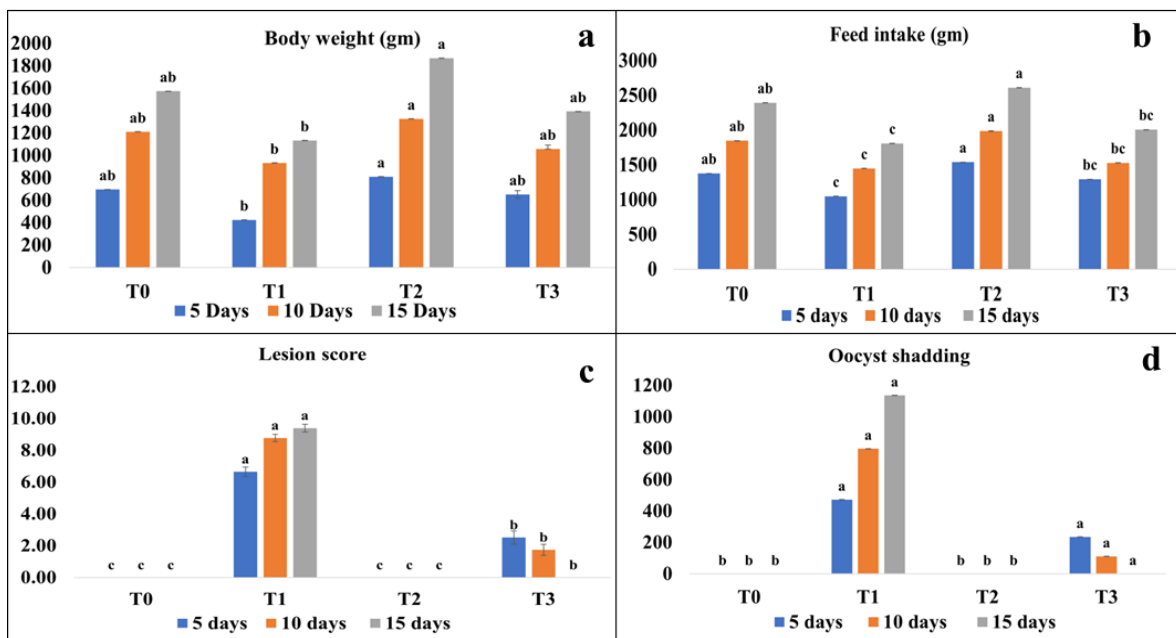


Fig. 2. Effect of symbiotic & infection on body conditions (physical & internal) of broiler on 5th, 10th and 15th days analysis (a)Body weight(g) (b)Feed intake (g) (c)Lesion score (d) Oocytes shedding. While significance value of all parameters is (P<0.05)

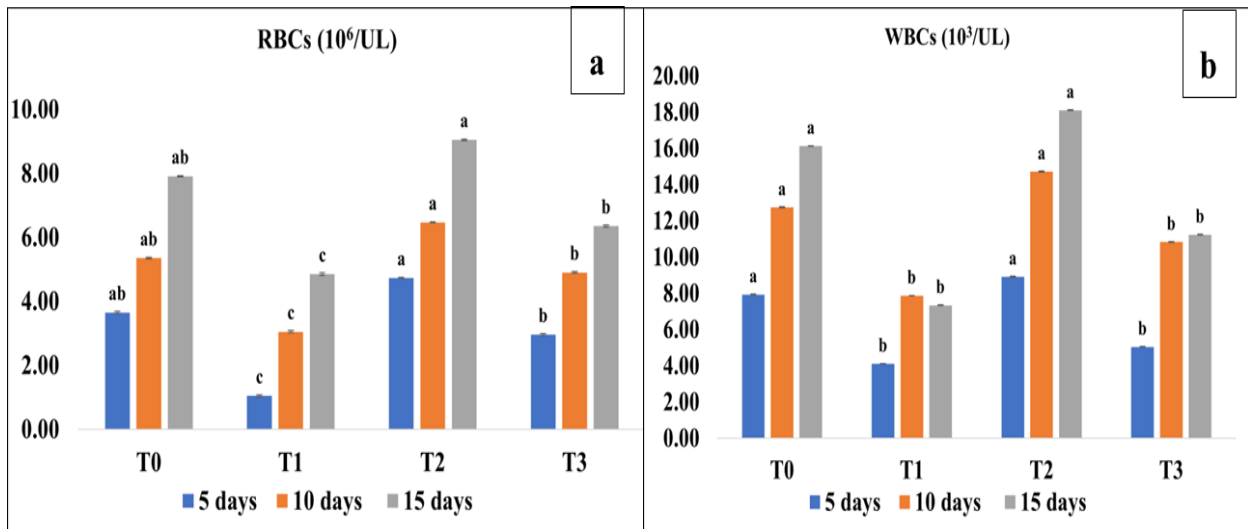


Fig. 3. Effect of infection and synbiotic on RBCs and WBCs on 5th, 10th and 15th days of analysis (a) RBCs count ($10^6/\text{UL}$) (b) WBCs count ($10^3/\text{UL}$). While significance value of all parameters is ($P < 0.05$)

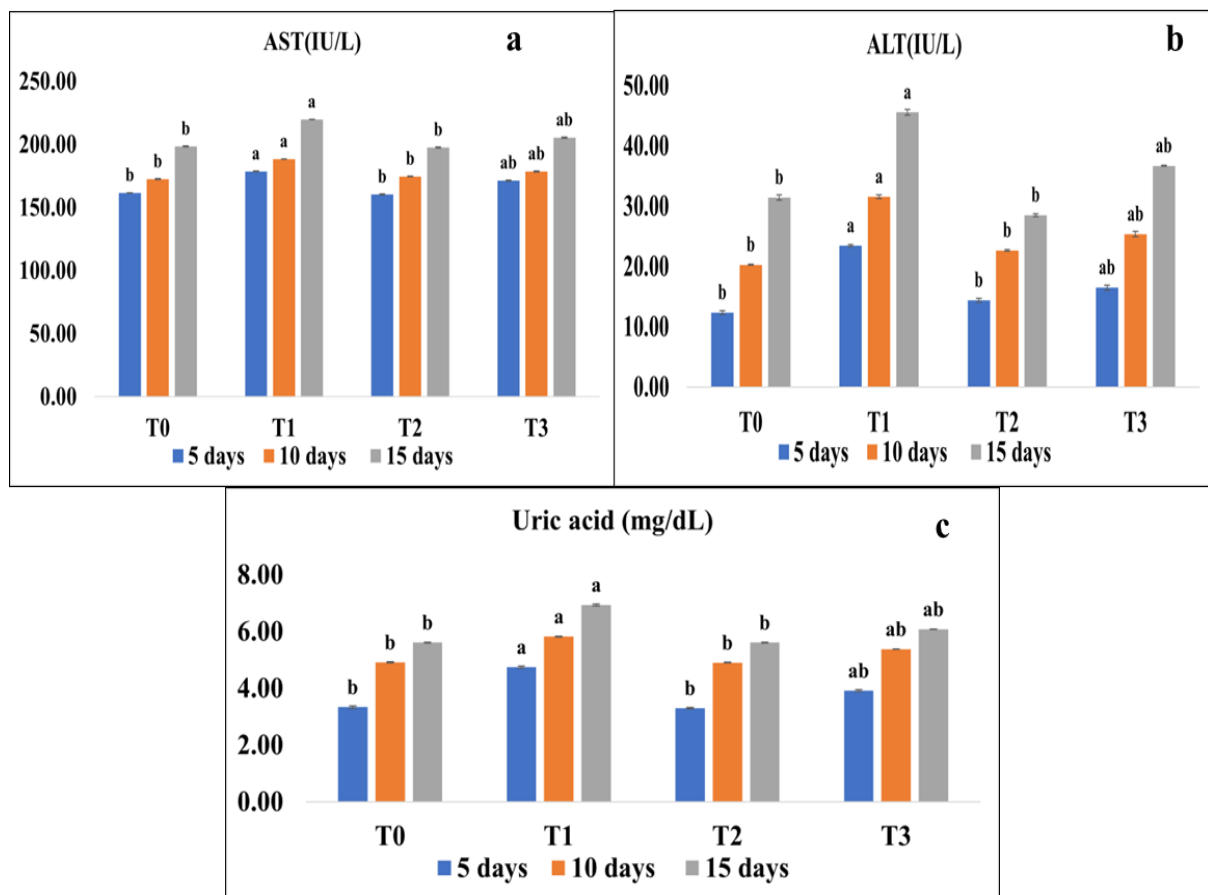


Fig. 4. Effect of infection and synbiotic on liver enzymes and uric acid on 5th, 10th and 15th days of analysis (a) AST (IU/L) (b) ALT (IU/L) (c) uric acid (mg/dL). While significance value of all parameters is ($P < 0.05$)

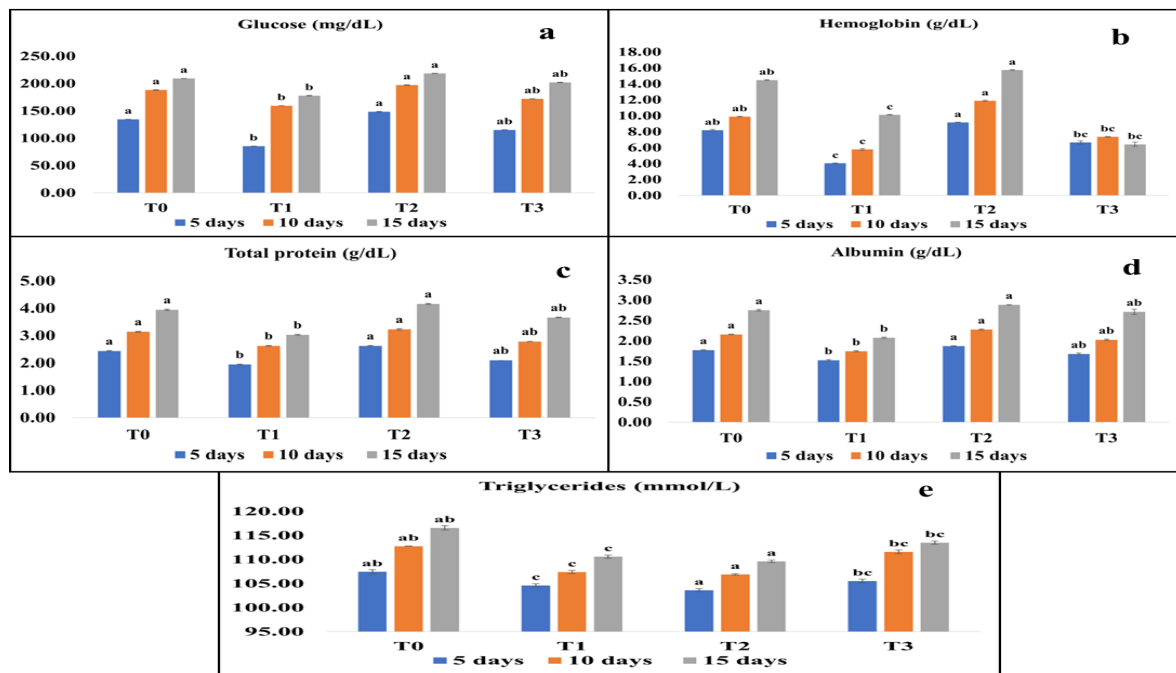


Fig. 5. Effect of infection and synbiotic blood serum on 5th, 10th and 15th days of analysis (a) glucose (gm/dL) (b) hemoglobin (g/dL) (c) total protein (g/dL) (d) albumin (g/dL) (e) triglyceride (mmol/L). While significance value of all parameters is ($P < 0.05$)

References

1. Abbas, A., Iqbal, Z., Abbas, R. Z., Khan, M. K. and Khan, J. A. Immunomodulatory activity of *Pinus radiata* extract against coccidiosis in broiler chicken. *Pak. Vet. J.*, **37**(1), 145-9 (2017).
2. Khan, I., Nawaz, M., Anjum, A.A., Tanvir, R., Sarwar, N., Ashraf, M.A., and Aqib, M. *Limosilactobacillus fermentum* IKP 111 reduces pathogen load and improves immunity of broilers when challenged with *Salmonella enteritidis*. *Microbial Pathogenesis*, **185**, 106-120 (2023).
3. Blake, D. P., Knox, J., Dehaeck, B., Huntington, B., Rathinam, T., Ravipati, V. and Tomley, F. M. Re-calculating the cost of coccidiosis in chickens. *Veterinary Research*, **51**, 1-14 (2020).
4. Mai, K., Sharman, P.A., Walker, R.A., Katrib, M., Souza, D. D., McConville, M. J. and Smith, N. C. Oocyst wall formation and composition in coccidian parasites. *Memorias do Instituto Oswaldo Cruz*, **104**, 281-289 (2009).
5. Lal, K., Bromley, E., Oakes, R., Prieto, J.H., Sanderson, S.J., Kurian, D. and Tomley, F. M. Proteomic comparison of four *Eimeria tenella* life-cycle stages: unsporulated oocyst, sporulated oocyst, sporozoite and second-generation merozoite. *Proteomics*, **9**(19), 4566-4576 (2009).
6. Taylor, M.A. and Bartram, D.J. The history of decoquinate in the control of coccidial infections in ruminants. *Journal of Veterinary Pharmacology and Therapeutics*, **35**(5), 417-427 (2012).
7. Bachaya, H.A., Abbas, R.Z., Raza, M.A., Zafar Iqbal, Z.I., Tauseef-ur-Rehman, T.U.R., Wasim Baber, W. B. and Riaz Hussain, R. H. Existence of coccidiosis and associated risk factors in broiler chickens in Southern Punjab, Pakistan. *Pakistan Veterinary Journal*, **35**(1), 253-831835(2015).
8. Chapman, H.D. Milestones in avian coccidiosis research: a review. *Poultry Science*, **93**(3), 501-511 (2014).
9. Morris, G.M. and Gasser, R.B. Biotechnological advances in the diagnosis of avian coccidiosis and the analysis of genetic variation in *Eimeria*. *Biotechnology Advances*, **24**(6), 590-603 (2006).
10. Cervantes, H.M. Antibiotic-free poultry production: is it sustainable?. *Journal of Applied Poultry Research*, **24**(1), 91-97 (2015).
11. Biagini, L., Galosi, L., Roncarati, A., Attili, A. R., Mangiaterra, S. and Rossi, G. The role of nutraceuticals and phytonutrients in chickens' gastrointestinal diseases. *Animals*, **12**(7), 892 (2022).
12. Adhikari, P., Kiess, A., Adhikari, R. and Jha, R. An approach to alternative strategies to control avian coccidiosis and necrotic enteritis. *Journal of Applied Poultry Research*, **29**(2), 515-534 (2020).
13. Awais, M.M., Jamal, M.A., Akhtar, M., Hameed, M.R., Anwar, M.I. and Ullah, M. I. Immunomodulatory and ameliorative effects of *Lactobacillus* and *Saccharomyces* based probiotics on pathological effects of eimeriasis in broilers. *Microbial Pathogenesis*, **126**, 101-108 (2019).

14. El-Sawah, A. A., Aboelhadid, S. M., El-Nahass, E. N., Helal, H. E., Korany, A. M., & El-Ashram, S. Efficacy of probiotic *Enterococcus faecium* in combination with diclazuril against coccidiosis in experimentally infected broilers. *Journal of Applied Microbiology*, **129**(4), 1020-1028 (2020).
15. Mustafa, A., Bai, S., Zeng, Q., Ding, X., Wang, J., Xuan, Y. and Zhang, K. Effect of organic acids on growth performance, intestinal morphology, and immunity of broiler chickens with and without coccidial challenge. *AMB Express*, **11**, 1-18 (2021).
16. Conway, D. P. and McKenzie, M. E. Poultry coccidiosis: diagnostic and testing procedures. *John Wiley & Sons* (2007).
17. McDougald, L.R., and S.H. Fitz-Coy, Protozoal infection, In Y.M. Saif, (ed.). *Disease of Poultry*. 12th ed. Blackwell Publishing. Ames, IA, USA **22**, 1068–1080 (2008).
18. FAW, Animal Health Manual. Permin, A. and Hansen, J. W. *Epidemiology, diagnosis and control of poultry parasites*. FAO Animal Production and Health Division (1998).
19. Hussein, E.O., Ahmed, S.H., Abudabos, A.M., Aljumaah, M.R., Alkhulafaifi, M.M., Nassan, M.A. and Swelum, A. A. Effect of antibiotic, phytobiotic and probiotic supplementation on growth, blood indices and intestine health in broiler chicks challenged with *Clostridium perfringens*. *Animals*, **10**(3), 507 (2020).
20. Żbikowski, A., Pawłowski, K., Ślizewska, K., Dolka, B., Nerc, J. and Szeleszczuk, P. Comparative effects of using new multi-strain synbiotics on chicken growth performance, hematology, serum biochemistry and immunity. *Animals*, **10**(9), 1555 (2020).
21. Elbahy, N., AbouLaila, M., ElKhatam, A., Mater, M. and El-Bahrawy, A. Evaluation the Anticoccidial Efficacy of Oregano Oil and Allicin against *Eimeria tenella* in Experimentally Infected Broiler Chickens. *Journal of Current Veterinary Research*, **5**(2), 245-255(2023).
22. Gilbert, W., Bellet, C., Blake, D. P., Tomley, F. M., & Rushton, J. Revisiting the economic impacts of *Eimeria* and its control in European intensive broiler systems with a recursive modeling approach. *Frontiers in Veterinary Science*, **7**, 558182 (2020).
23. El-Maddawy, Z. K., El-Sawy, A. E. S. F., Ashoura, N. R., Aboelenin, S. M., Soliman, M. M., Ellakany, H. F. and El-Shall, N. A. Use of zinc oxide nanoparticles as anticoccidial agents in broiler chickens along with its impact on growth performance, antioxidant status, and hematobiochemical profile. *Life*, **12**(1), 74 (2022).
24. Ahmad, Z., Hafeez, A., Ullah, Q., Naz, S. and Khan, R. U. Protective effect of Aloe vera on growth performance, leucocyte count and intestinal injury in broiler chicken infected with coccidiosis. *Journal of Applied Animal Research*, **48**(1), 252-256 (2020).
25. Chalorsuntisakul, S., Sirithunyulug, J., Chaiyasut, C., Aengwanich, W., and Pewnim, T. Effect of synbiotics on caecal morphology and lesion score in broilers infected with *Eimeria tenella*. *Avian Biology Research*, **3**(4), 187-190 (2010).
26. Györke, A., Pop, L., & Cozma, V. Prevalence and distribution of *Eimeria* species in broiler chicken farms of different capacities. *Parasite*, **20**(50), 1-8 (2013).
27. Duff, A. F., Briggs, W. N., Chasser, K. M., Lilburn, M. S., Syed, B., Ramirez, S. and Bielke, L. R. Effect of dietary synbiotic supplementation on performance parameters in turkey poults administered a mixed *Eimeria* species inoculation I. *Poultry Science*, **99**(9), 4235-4241 (2020).
28. Lail, N. U., Sattar, A., Omer, M. O., Hafeez, M. A., Khalid, A. R., Mahmood, S. and Almutairi, M. M. Biosynthesis and characterization of zinc oxide nanoparticles using *Nigella sativa* against coccidiosis in commercial poultry. *Scientific Reports*, **13**(1), 65-68 (2023).
29. Yan, W., Chen, X. R., Li, S. Q., Li, Y., Wang, J., Chang, W. and Yang, M. Effects of Compound Probiotics Administration on the Growth Performance, Immunity, Rumen Microbiota and Coccidial Infection of Weaned Lambs. *Immunity, Rumen Microbiota and Coccidial Infection of Weaned Lambs*. College of Veterinary Medicine, Henan Agricultural University, Zhengdong New District Longzi Lake#15, 450046 Zhengzhou, Henan province, People's Republic of China.
30. Ellakany, H.F., Abuakkada, S.S., Oda, S.S. and El-Sayed, Y. S. Influence of low levels of dietary aflatoxins on *Eimeria tenella* infections in broilers. *Tropical Animal Health and Production*, **43**, 249-257 (2011).
31. Al-Baadani, H.H., Abudabos, A.M., Al-Mufarrej, S. I., Al-Baadani, A. A. and Alhidary, I. A. Dietary supplementation of *Bacillus subtilis*, *Saccharomyces cerevisiae* and their symbiotic effect on serum biochemical parameters in broilers challenged with *Clostridium perfringens*. *Journal of Applied Animal Research*, **46**(1), 1064-1072 (2018).
32. Ali, A. M., Seddiek, S. A. and Khater, H. F. Effect of butyrate, clopidol and their combination on the performance of broilers infected with *Eimeria maxima*. *British Poultry Science*, **55**(4), 474-482 (2014).
33. Ali M. Ali, Hanem F. Khater, Shaker A. Seddiek and Mai O. Nada Comparative efficacy of synbiotic and diclazuril on broilers experimentally infected with *Eimeria acervulina*. *Assiut Veterinary Medical Journal*, **61**(146), 24-33(2015).
34. Klasing, K.C. and Austic, R.E. Changes in protein synthesis due to an inflammatory challenge. *Proceedings of the Society for Experimental Biology and Medicine*, **176**(3), 285-291 (1984).
35. Abdel-Azeem, F. Digestion, neomycin and yeast supplementation in broiler diets under Egyptian summer conditions. *Egypt Poult. Sci.*, **22**, 235-257 (2002).