

ORIGINAL ARTICLE

Doppler ultrasound for prediction of the diagnosis of placenta accreta spectrum

Ibrahim Mohamed Shahat Mohamed* , Mohamed Salah El Din Fahmy, Nahla Waer El Sayed Shady , Aly Abdel-Bagy Mohamed, Sherif Salah Eldeen Fahmy, Hossam Ramadan Abdulwahab

Department of obstetrics and gynecology, Faculty of Medicine- Aswan University.

ABSTRACT

Keyword: placenta accrete spectrum, Doppler ultrasound, antepartum hemorrhage.

***Corresponding author:** Ibrahim Mohamed Shahat Mohamed

Email:
ibrahim.mohamedz5050@gmail.com

Phone: 01110070419

Background: Antenatal diagnosis of placenta accreta spectrum should be set up for planning location, timing and specialized staffing delivery to decrease maternal mortality and morbidity rate. **Objectives:** Evaluation of Doppler ultrasound in prediction of the diagnosis of placenta accreta in cases of placenta previa with previous history of uterine surgery. **Methodology:** The study included 120 cases diagnosed as placenta previa (after 28 weeks of gestation) with previous uterine surgery. The diagnosis of placenta accreta was regarded as positive when any two of these color Doppler criteria is present, Diffuse or focal lacunar flow pattern, Hypervascularity of the uterine-bladder interface with abnormal blood vessels linking the placenta to the bladder, Markedly dilated vessels over the peripheral subplacental region with turbulent flow typified by high velocity (peak systolic velocity >20 cm/s) and low resistance waveform and Cervical hypervascularity. **Results:** The color Doppler ultrasonography examined that the sonographic diagnostic sensitivity in detecting the placenta accreta was 87.0% and specificity was 93.0%. **Conclusion:** Doppler ultrasound has diagnostic efficacy and clinical utility in prediction of the diagnosis of placenta accreta spectrum.

INTRODUCTION

Placenta accreta is defined as abnormal trophoblast invasion of part or all of the placenta into the myometrium of the uterine wall. Placenta accrete spectrum, formerly known as morbidly adherent placenta, refers to the range of pathologic adherence of the placenta, including placenta increta, placenta percreta, and placenta accrete. (1). Prenatal detection of PAS is a key goal in obstetric care, since it can substantially reduce maternal mortality and serious morbidity (2).

In literature, cesarean delivery is associated with an increased risk of placenta praevia in subsequent pregnancies. This risk rises as the number of prior caesarean sections increases and the estimated incidence of placenta praevia at term Assisted reproductive technology and maternal smoking increase the risk of placenta previa.(3). Qualified ultrasound screening for PAS should be widely available, focusing on risk factors and placental position on ultrasound. Referral pathways to PAS specialized centers should be set up to ensure prompt assessment and confirmation of a high-risk PAS situation. Trained providers should assess these pregnant women. All efforts should be made to start the topographical classification of PAS antenatally and assist in the surgical planning, which must be carried out in the specialized referral center to manage PAS (4).

MATERIALS AND METHODS

This prospective observational study was conducted at the department of obstetrics and gynecology, Aswan university hospital. The study included 120 cases diagnosed as placenta previa (after 28 weeks

of gestation) with previous uterine surgery. Women with placenta previa found eligible for the study underwent trans-abdominal and transvaginal ultrasound by using the Voluson® S8 ultrasound machine (GE Healthcare, Chicago, Illinois, USA) and the whole placenta was scanned in a systematic fashion using color Doppler ultrasound for all cases. The diagnosis of placenta accreta was regarded as positive when any two of these color Doppler criteria is present: (1) Diffuse or focal lacunar flow pattern. (2) Hypervascularity of the uterine–bladder interface with abnormal blood vessels linking the placenta to the bladder. (3) Markedly dilated vessels over the peripheral subplacental region with turbulent flow typified by high velocity (peak systolic velocity >20 cm/s) and low resistance waveform. (4) Cervical hypervascularity. The final diagnosis of accreta clearly be established according to the patient’s birth and intraoperative clinical conditions.

Statistical analysis:

Data were verified, coded by the researcher and analysed using IBM-SPSS 24.0 . Descriptive statistics: Means, standard errors, medians and percentages were calculated. Test of significances: Chi square/Monte Carlo exact test was used to compare the difference in distribution of frequencies among different groups. Test of normality, Shapiro-Wilk / Kolmogorov Smirnov was used to test the normality of continuous variables. For continuous variables with more than two categories; ANOVA test was calculated to test the mean differences of the data that follow normal distribution and independent sample Kruskal-Wallis was used to compare the median difference between groups that don’t follow normal distribution, post-hoc test was calculated using Bonferroni corrections. ROC curve was depicted to explore the diagnostic performance of placenta accrete scoring system for placenta accreta prediction, analyzed as area under the curve (AUC), standard error (SE) and 95% CI. Validity statistics (sensitivity, specificity, positive and negative predictive value –PPV & NPV-) were calculated. A p-value equals or less than 0.05 was considered significant.

RESULTS:

Table (1). Previous Uterine Surgery of the Study group

Parameter	n = 120(%)	
Types of Previous Surgery	D & C	17 (14.2%)
	CS	82 (68.3%)
	D & C + CS	21 (17.5%)
Previous CS	Median (IQR)	2 (0 - 7)
	No	17 (14.2%)
	One	23 (19.1%)
	Two	41 (34.2%)
	≥ 3	39 (32.5%)
D and C	Median (IQR)	0 (0 - 3)
	None	82 (68.3%)
	One	23 (19.2%)
	≥ 2	15 (12.5%)

Table (2). Sonographic findings of the Color Doppler US

Parameter (n=120)	Trans-abdominal	Trans-vaginal	P.Value
Diffuse or focal lacunar flow pattern	40 (33.3%)	42 (35.0%)	=0.94*
Hypervascularity of serosa bladder interface	44 (36.7%)	47 (39.2%)	
Markedly dilated vessels over peripheral sub-placental zone	41 (34.2%)	41 (34.2%)	
Cervical hypervascularity	34 (28.3%)	38 (31.7%)	
Initial diagnosis:			
Focal accreta	30 cases	41 (34.2%)	
Total accrera	11 cases		

Table 2 shows that 47 (39.2%) of cases had hypervascularity of the uterine–bladder interface was the most common finding, 42 (35.0%) of cases had diffuse or focal lacunar flow pattern, 41 (34.2%) of cases had markedly dilated vessels over the peripheral subplacental region, while 38 (31.7%) of cases had cervical hypervascularity, 80 (65.8%) of cases was initially diagnosed as no placenta accreta while 41 (34.2%) of cases were initially diagnosed as placenta accrete, 30 cases as focal accrete and 11 cases as total accreta.

Table (3). Relationship between Findings of Color Doppler US and operative diagnosis of placenta accreta:

Parameter	Color Doppler US findings	Operative diagnosis of placenta accreta (n=46)	PPV
Diffuse or focal lacunar flow pattern	43	37 (80.4%)	86.0%
Hypervascularity of serosa bladder interface	49	45 (97.8%)	91.8%
Markedly dilated vessels over peripheral sub-placental zone	43	36 (78.3%)	83.7%
Cervical hypervascularity	39	28 (60.9%)	71.8%
Initial diagnosis: Placenta Accreta	41	40 (87.0%)	97.6%

Table 3 shows that the PPV for findings of the 2D color Doppler US and operative diagnosis of placenta accrete was 97.6%, the highest PPV for findings of the 2D color Doppler US was for hypervascularity of serosa bladder interface 91.8%, the lowest PPV for cervical hypervascularity 71.8%

Table (4). Diagnostic criteria of Color Doppler US Data for diagnosis of placenta accreta, analyzed as area under the curve (95% CI)

	AUC*	95% CI+	P-value***
1- Diffuse or focal lacunar flow pattern	0.883	0.811 - 0.956	< 0.001
2- Hypervascularity of bladder interface	0.983	0.955 - 1.000	< 0.001
3- Markedly dilated vessels	0.885	0.811 - 0.959	< 0.001
4- Cervical hypervascularity	0.773	0.679 - 0.876	< 0.001

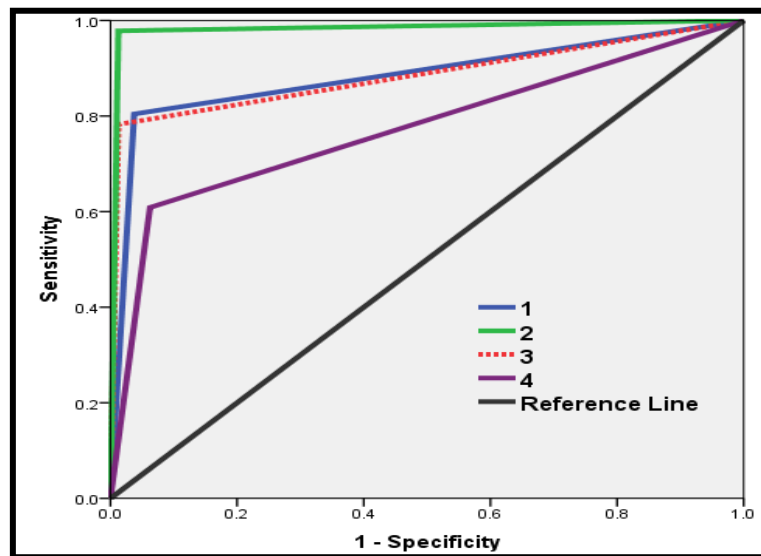


Figure (1). ROC curve for diagnosis of Placenta Accreta (by 2D Color Doppler US)

DISCUSSION:

PAS is one of the most dangerous conditions of the pregnancy as it is significantly associated with maternal morbidity and mortality (5). Maternal and neonatal outcomes are generally improved when diagnosis is made before delivery, and the woman is managed by a multidisciplinary team with expertise in the condition (6).

In this study, the cases with a history of previous CS, 23 (19.1%) cases with previous one CS, 41 (34.2%) cases with previous two CS, and 39 (32.5%) cases with previous three or more CS. According to history of D and C, 82 (68.3%) cases without history of previous D and C, 23 (19.2%) cases with previous one D and C and 15 (12.5%) cases with previous two or more D and C.

In the current study the color Doppler ultrasonography examined that the sonographic diagnostic sensitivity in detecting the placenta accreta was 87.0% and *Kamankash et al., 2020* 97.7%, *Hussein et al., 2019* 84.06% and *Pilloni et al., 2016* 81.1% (7,8,9) .

While the most prominent 2D color Doppler ultrasonography sign was hypervascularity of serosa bladder interface with sensitivity 97.8% and this following *Kamankash et al., 2020* 84.06%, *Cali et al., 2013* 90%, and against *Hussein et al., 2019* as the sonolucent vascular lakes with turbulent flow had the highest sensitivity (84.06%) (7,10,8).

The hypervascularity of serosa bladder interface with the highest NPV of 98.7% and this against *Kamankash et al., 2020*, *Hussein et al., 2019*, and *Shih et al., 2009* as the sonolucent vascular lakes with turbulent flow had the highest NPV (100%, 83.5%, and 75% respectively) (7,9,11).

The present work showed that as regards 2D color Doppler ultrasonography, cervical hypervascularity should not be used as a single diagnostic criterion as had the lowest sensitivity, accuracy, PPV, and NPV but should be combined with other criteria with greater PPV as low PPV for cervical hypervascularity was detected. *Kamankash et al., 2020* also cervical hypervascularity had the lowest NPV 61.3% (7).

As regards the current study found that vascularity of uterine serosa-bladder wall interface had the highest PPV 91.8 % this was in accordance with the study of *Hussein et al., 2019*, *Pilloni et al., 2016* (86.0%, and 100% respectively) but this finding was against *Kamankash et al., 2020*, and the study of *Shih et al., 2009* showed that sonolucent vascular lakes with turbulent flow had the highest PPV of 91% (8,10,7,11).

CONCLUSION

Doppler ultrasound has diagnostic efficacy and clinical utility in prediction of the diagnosis of placenta accreta spectrum.

REFERENCES

1. **ACOG, Usta IM. , Hobeika EM., et al. (2018):** Placenta previa-accreta: risk factors and complications. *Am J Obstet Gynecol*;193:1045–9.
2. **Buca D. , Liberati M. , Cali G. , Forlani F. , Caisutti C., et al. (2018):** influence of prenatal diagnosis of abnormally invasive placenta on maternal outcome: systematic review and meta-analysis *Ultrasound Obstet Gynecol*;52:304-9.
3. **RCOG, Jauniaux ERM, Alfirevic Z, Bhide AG, Belfort MA, et al. (2018):** Placenta Praevia and Placenta Accreta: Diagnosis and Management. Green-top Guideline No. 27a
4. **Conrado Milani Coutinho, Alexia Viegas Georg, Ligia Conceição Assef Marçal , et al. (2023):** Placenta Accreta Spectrum Disorders: Current Recommendations from the Perspective of Antenatal Imaging, *The Revista Brasileira de Ginecologia e Obstetrícia* .<https://doi.org/10.1055/s-0043-1770917>.
5. **Fitzpatrick K, Sellers S, Spark P, Kurinczuk J, et al. (2014):** The management and outcomes of placenta accreta, increta, and percreta in the UK: a population-based descriptive study. *BJOG Int J Obstet Gynaecol*. 2014;121(1):62–71.
6. **Shamshirsaz AA. , Fox KA. , Salmanian B. , et al. (2015):** Maternal morbidity in patients with morbidly adherent placenta treated with and without a standardized multidisciplinary approach. *Am J Obstet Gynecol*. 2015;212(2):218.e1-218.e9.
7. **Kamankesh, R., Hanafi, MG., Bakhtiari, Z., Masihi, S., (2020):** Evaluation of the sensitivity and specificity of 2D and color Doppler sonography in the detection of placenta accreta in pregnant women. *J Family Med Prim Care*;9:1009-12
8. **Hussein, M., Ramadan, M.F., Abu-Elhassan, A.M., (2019):** Evaluation of Different Ultrasonographic Modalities in the Diagnosis of Morbidly Adherent Placenta: A Cross-Sectional Study. *Open Journal of Obstetrics and Gynecology*, 9, 405-416
9. **Pilloni, E., Alemanno, M., Gaglioti, P., Sciarrone, A., Garofalo, A., et al. (2016).** Accuracy of ultrasound in antenatal diagnosis of placental attachment disorders. *Ultrasound in obstetrics & gynecology*, 47(3), 302-307 .
10. **Cali, G., Giambanco, L., Puccio, G., and Forlani, F., et al. (2013):** Morbidly adherent placenta: evaluation of ultrasound diagnostic criteria and differentiation of placenta accreta from placenta percreta. *Ultrasound Obstet Gynecol*; 41: 406-412.
11. **Shih, JC., Palacios, Jaraquemada, JM., Su, YN., Shyu, MK., et al. (2009):** Role of three-dimensional power Doppler in the antenatal diagnosis of placenta accreta: comparison with gray-scale and color Doppler techniques. *Ultrasound Obstet Gynecol*; 33: 193–203.