



Official Journal Issued by
Faculty of
Veterinary Medicine

Benha Veterinary Medical Journal

Journal homepage: <https://bvmj.journals.ekb.eg/>



Since 1990

Original Paper

Genetic features of P4b gene of recent Fowl Pox virus strains from Al-Sharkia Governorate Egypt 2021.

Manal K.H. Abd-Allah¹, Ibraheim El-boraie², Abdel-Fattah I. EL-Zanaty³, Saad Sh.A. Sharawi¹

¹Department of Virology, Faculty of Veterinary Medicine, Benha University

²Department of Avian and Rabbit Diseases, Faculty of Veterinary Medicine, Benha University

³Avian Pathology Unit, Poultry Disease Diagnosis and Research Department, Animal Health Research Institute, Agriculture Research Center.

ARTICLE INFO

Keywords

AGPT
FWPV
Histopathology
PCR

Sequence analysis
SPF-ECE

Received 09/07/2024

Accepted 26/07/2024

Available On-Line

01/10/2024

ABSTRACT

Avian poxvirus (APV) is a global disease that affects birds, resulting in both pathological and financial losses for the poultry industry. Avian poxvirus belongs to the genus *Avipoxvirus* under the family *Poxviridae*. Viral lesions typically occur in the featherless parts at the head and around the eye. Samples were collected from six commercial layer chicken populations in the Al-Sharkia Governorate, Egypt during the period from May to June 2021. The virus was successfully detected by PCR targeting P4b gene at 578 bp and gave positive results in 5 out of 6 samples. Fowl Pox virus infection was characterized by histopathology and isolation on specific pathogen free-embryonated chicken eggs (SPF-ECEs) followed by serological identification of the viral isolates using AGPT. Phylogeny of a 300 bp of P4b gene showed a high homology (99.99%) of our isolates with most of the local reference strains and vaccinal FPV strain from Egypt and lower homology with other Avian poxvirus strains from other species and was grouped within subclade A1 within Clade A in the phylogenetic tree. Amino acid sequence analysis of Avipoxvirus-Egy-f1086-2-P4b (OQ385208) acquired mutations as E120K and N121D while Avipoxvirus-Egy-f1086-3-P4b (OQ385207) acquired mutations as H83P and S93N. Therefore, more research is needed to determine the effectiveness of the current vaccine against FWPV.

1. INTRODUCTION

Fowl poxvirus (FWPV) is characterized by considerable size and complexity, belongs to the genus *Avipoxvirus*, subfamily *Chordopoxvirinae*, family *Poxviridae*, in addition to pigeon poxvirus (PPV) and turkey poxvirus (TPV) (Fauquet et al., 2005; Weli and Tryland, 2011). Fowl poxvirus results in an infectious illness in both domestic and untamed avian species, causing mild to severe lesions and high infection and death rates (Zhao et al., 2014).

There are two variations of the disease, namely the cutaneous nodular (dry) form with a low mortality rate characterized by nodular skin lesions primarily observed on the eyelids, combs, and thighs, and the diphtheritic (wet) form as fibronectin proliferative lesions on the mucous membranes of the upper respiratory tracts, mouth, and esophagus (Masola et al., 2014). Wild birds (Parker et al., 2011; Atkinson and La Pointe 2009) and insects (Van Riper and Forrester 2007) have a significant impact on the transmission of pox infection.

The FWPV genome is composed of a double-stranded DNA that contains a central coding region, which is flanked by two identical inverted terminal repeat regions. The genome is around 288 kbp in size and contains 260 open-reading frames. The P4b protein gene of Avi-pox encodes a 75.2 kDa core protein that is commonly utilized for comparative genetic identification (Manarolla et al., 2010).

Poxviruses exhibit a distinct characteristic compared to other DNA viruses as they undergo replication and maturation within the cytoplasm of the host cells (Wagner et al., 2008). Histopathological analysis is an essential diagnostic method for identifying and detecting APV infection in various avian species (Abdallah & Hassanin, 2013; Offerman et al., 2013; LebDAH et al., 2019). Conversely, PCR amplification of the P4b gene was employed to identify avian poxviruses (Manarolla et al., 2010).

The definitive diagnosis is established through PCR testing and the isolation of FWPV in the Chorio-Allantoic membrane (CAM) of embryonated chicken eggs (ECEs) (OIE, 2018). Proliferative pock lesions are produced by FWPV on CAM of ECE within 4 to 6 days post-infection (Weli and Tryland, 2011).

A restricted study was conducted in Egypt along with an initial phylogenetic examination based on the sequences of the P4b and fpv140 locus (Abdallah and Hassanin 2013). The diagnosis of APV infections relies on the amplification of a conserved 578-base pair (bp) region of fpv167 (P4b), which is universally present in all poxviruses (Binns et al., 1989). The P4b gene has previously been documented in other phylogenetic investigations as a means to differentiate between clades of APVs (Jarmin et al., 2006).

The current investigation involved analyzing the sequences of the fpv167 (P4b) and fpv140 loci obtained from Fowl poxvirus samples collected from commercial layer chicken populations in the Al-Sharkia Governorate of Egypt in 2021.

* Correspondence to: manalrabea2016@gmail.com

2. MATERIAL AND METHODS

Ethical statement:

The experiment was conducted following the guidelines of the animal welfare committee, and the authorized Research Ethics Board of the Faculty of Veterinary Medicine at Benha University, registered at the national level under the code BUFVTM 07-11-22.

2.1. Sampling and sample processing:

This study was carried out from May to June 2021 for isolation, pathological, and molecular characterization of a recent strain of Fowl poxvirus among commercial layer Rosy Chicken flocks in Al-Sharkia Governorate, Egypt. Six-layer flocks showing skin lesions on the head, comb, wattle, and legs were selected for collection of samples with their data on breed, age, morbidity, and mortality. The affected layer of chicken had skin lesions on the head, comb, wattle, and legs. The afflicted flocks suffered a morbidity percent of 23% – 40% and a mortality rate of 3% – 6% (Table 1 and Fig 1).

Table 1 Data of 6 farms sampled for detection and isolation of Fowl poxvirus from Al-Sharkia Governorate, Egypt 2021.

Sample No.	Age/day	Number of chicken/flock	Morbidity rate %	Mortality rate %
1	85	1200	34%	3%
2	80	1200	32%	2%
3	90	1500	33%	4%
4	75	1500	40%	6%
5	100	1800	35%	5%
6	95	1800	36%	6%

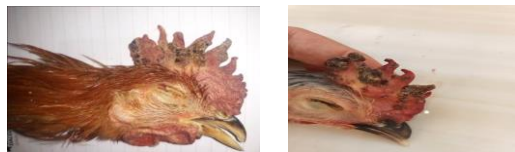

Fig 1 Head of suspected clinical cases of chickens (crusts formation and nodular lesions on the comb).

Skin nodules on the non-feathered parts of the skin were collected as pooled samples from each farm. The sample was divided into 2 parts; the first part was placed in 10% formalin and was used for histopathological study, whereas the second part was kept in a sterile plastic bottle containing phosphate buffer saline (PBS) with antibiotics (100 IU/ml penicillin, 100ug/ml streptomycin and 100 µg mycostatin/ml) at –20 °C till used for sample processing. Specimens were processed to be ready for trials for virus isolation following Tripathy (1989).

2.2. Histopathological examination:

Specimens for the histopathological study were collected from the skin with nodular lesions of chicken, cut by microtome, kept in 10% neutral buffered formalin for fixation then dried and embedded in paraffin wax. To examine them histopathologically, these slices were stained with H&E and microscopic detection of histological changes and intra-cytoplasmic inclusion bodies (Bollinger bodies) as described by Suvana et al. (2013).

2.3. Trials for virus isolation on CAM of SPF-ECEs:

It was carried out following OIE (2016). Using the dropped membrane method, 0.2 ml of prepared field tissue nodules were inoculated onto the CAM of 11-12 days old SPF-ECEs (3 eggs for each sample). During five to seven days, the inoculated eggs were kept in a horizontal position in the incubator at 37°C and 60% humidity, with daily candling. Within the first 24 hours, eggs with dead embryos were discarded.

For every sample, CAMs exhibiting pock lesions were collected and pooled until the sixth day. CAMs are harvested under aseptic conditions into a petri dish, washed with PBS, and checked for distinctive lesions. After CAMs were minced in sterile PBS containing antibiotics at each stage, a 10% w/v suspension was formed, centrifuged for 10 minutes at room temperature at 3000 rpm and the virus-containing supernatant was collected aliquoted then kept at - 20°C for further passages. For every sample, four serial egg passages were conducted.

2.4. Serological identification of isolated FPV using AGPT

The isolated FWPV on SPF-ECE was identified by AGPT according to OIE (2016) using a specific hyperimmune serum against FWPV that was kindly supplied by the Pox Vaccines Research department, VSVRI, Egypt.

2.5. Extraction of the viral DNA

Using a commercial QIAamp DNA Mini Kit (Cat. no.51304), total viral DNA was isolated from the field samples. It provides silica-membrane-based nucleic acid purification from different types of samples. This process was carried out in compliance with the manufacturer's guidelines and DNA was stored at – 85°C.

2.5.1. Primers of virus core protein P4b gene PCR amplification

A primer pair P1-F 5` CAG CAG GTG CTA AAC AAC AA-3`, P2-R 5` - CGG TAG CCT TAA CGC CGA ATA -3` were manufactured in Midland Certified Reagent Company_oilgos (USA) and used for amplification of 578 bp PCR product of FPV167 gene in tissue specimens (Prukner-Radovcić et al., 2006).

2.5.2. Polymerase chain reaction

The DNA (100ng/ul) in the premix (Bioneer®-Korea) tubes was mixed with primers (10 pmol of each one), and the final volume was raised to 25 µl using distilled water. According to Prukner-Radovcić et al. (2006), PCR was performed in a thermocycler using DNA that had been denatured for 10 minutes at 94 °C. Thereafter, it went through 35 cycles of denaturation for 45 seconds at 94 °C, annealing for 45 seconds at 53 °C, extension for 45 seconds at 72 °C, and a final single extension cycle for 10 minutes at 72 °C. Electrophoresis using agarose gel 1.5%, 100 bp marker and a Redsafe® stain was used for DNA electrophoresis and the Gel-documentation system was used to take pictures of the gel.

2.6. Phylogenetic analysis

Samples from the positive PCR were forwarded for Sanger sequencing. Using the NCBI Blast tool, the nucleotide sequences were aligned with additional sequences that were published at the GenBank database. Rather than using amino acid sequences to determine the genetic diversion, nucleotides were employed. The analysis of the two sequences of the study has been applied to the alignment of different species of avi-poxviruses downloaded from the Genbank including turkey poxviruses, Canary poxviruses, and fowl poxviruses from different countries all over the world. All nucleotides were aligned using the Clustal W algorithm and trimmed to 300 bp using MEGA-X software. In order to determine the most appropriate mathematical model for limiting the Neighbor-Joining (NJ) tree, sequences were tested. With a gamma distribution parameter value of 0.38 and 1000 replicate bootstrap values, the Tamura 3-parameter model was chosen.

3. RESULTS

3.1. Detection of FPV by PCR in nodular skin samples from layer chicken flocks

Five pooled samples were positive for FWPV using PCR out of six pooled samples collected from layer chicken farms at Al-Sharkia Governorate, Egypt 2001. Positive samples (numbers 1, 2, 3, 5 and 6) displayed distinct band amplicon size (578 bp) for P4b gene (Fig 2).




Fig 2 Electrophoresis of the amplified products 578 bp of P4b gene for detection of FWPV (Lane 1-6). Lane M: marker, Lane P: commercial fowl poxvirus vaccine as positive control, Lane N: negative control.

3.2. Detection of histopathological changes in chicken tissues caused by FPV

Cutaneous lesions collected from chicken infected with fowl poxvirus that were ascertained using conventional PCR were prepared for histopathological examination by staining with H&E. There was found marked thickening (hyperplasia) of the epidermis layer and epithelial cells became more eosinophilic. It was noted that marked thickening of the epidermis of the skin due to proliferated fibrous tissue and infiltration of lymphocytes, histiocytes, and other materials. The most pathognomonic histopathological lesions intracytoplasmic inclusion bodies (Bollinger bodies) with different size were noted in infected skin lesions (Fig 3).

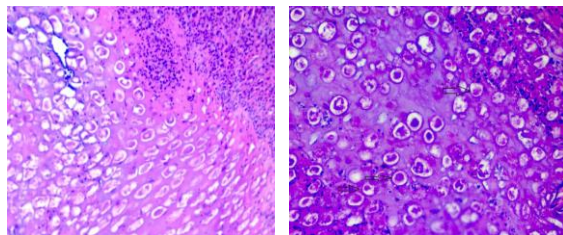


Fig 3 Chicken skin showing eosinophilic intracytoplasmic inclusion bodies arrows. X400.

3.3. Isolation of FPV on CAM of SPF-ECE

The five positive FWPV samples using PCR were isolated on CAM of SPF-ECE. Examination of the harvested egg CAM showed thickening and development of focal white opaque small pock lesions when compared with normal control CAM after the fourth passage of the field samples (Fig 4).

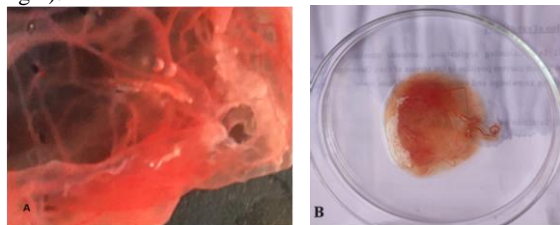


Fig 4 A- Focal white opaque small pock lesions and thickening the membrane when compared with normal control CAM of 17 days old SPF-embryo chicken egg inoculated by Fowl pox virus (after 4th passage of field samples). B- Normal CAM of 17- days' old-SPF-embryo chicken egg.

3.4. FWPV isolate serologically identified with AGPT

The isolated FWPV was identified using AGPT. A precipitation line appeared after 48 hours between the reference hyperimmune serum and prepared CAMS of SPF-ECE of the 4th egg passage (Fig. 5).




Fig. 5: AGPT for viral isolates identification, (1 & 2) 3rd isolate of samples that gave no precipitin line, (3 & 4) the Precipitin line for 4th isolate for samples, (5) is control negative sample (6) the Precipitin line for the control positive (FWPV vaccine). (HIS) is a reference hyperimmune FWPV serum.

3.5. Sequencing and phylogenetic analysis of p4b gene of detected FPV strains

Two positive samples on PCR with strong bands on electrophoresis were chosen for sequencing and genetic characterization. The obtained P4b gene sequences were submitted to Gene Bank as Sequence ID Avipoxvirus-Egy-f1086-2-P4b (OQ385208) and Avipoxvirus-Egy-f1086-3-P4b (OQ385207).

Sequence analysis of the P4b gene of FWPV isolates [Avipoxvirus-Egy-f1086-2-P4b (OQ385208) and Avipoxvirus-Egy-f1086-3-P4b (OQ385207)] showed higher homology (99.99%) with local reference and vaccinal strains of FWPV from chicken host in Egypt. High homology percent but with noticeable divergence was showed with reference and vaccinal strains of APV from other fowl species like Turkey, Oostertch, Pigeon, Canary, Sparrow, Falcone, Starling, and Albatros in India, Germany, and United Kingdom (Figures 6 and 7). Amino acid sequence analysis of Avipoxvirus-Egy-f1086-2-P4b (OQ385208) acquired mutations as E120K and N121D while Avipoxvirus-Egy-f1086-3-P4b (OQ385207) acquired mutations as H83P and S93N (Figure, 7).

Phylogeny and phylogenetic tree of Fowl Pox Virus (FWPV) from chicken at Al-Sharkia, Egypt 2021 based on P4b gene sequence showed that both Avi-poxvirus-Egy-f1086-2-P4b (OQ385208) isolate and Avipoxvirus-Egy-f1086-3-P4b (OQ385207) isolate were clustered within sub clade A1 with other local reference and vaccinal strains of FWPV from chicken and turkey hosts in Egypt (Figure, 8).

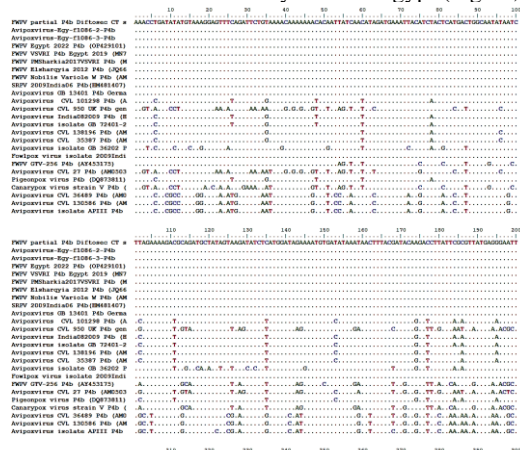


Fig 6 Nucleotide alignment analysis of P4b gene of fowl pox virus (FWPV) isolates compared to other selected reference and vaccinal strains.




Fig 7 Amino acid alignment analysis of P4b gene of fowl pox virus (FPV) isolates compared to the reference and vaccinal strains. The isolated fowl pox virus from Al-Sharkia Governorate Avipoxvirus-Egy-f1086-2-P4b (OQ385208) acquired mutations as E120K and N121D while Avipoxvirus-Egy-f1086-3-P4b (OQ385207) acquired mutations as H83P and S93N compared with Egyptian FWPV and FWPVD reference strain.

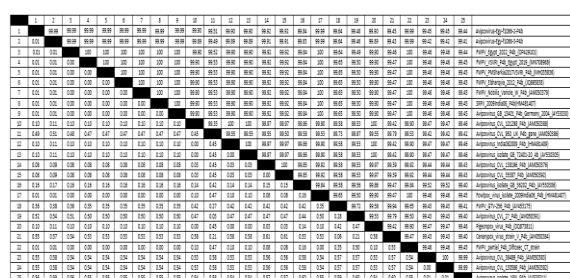


Table 2 Homology percent of the P4b gene of fowl pox virus (FPV) from Al-Sharkia, Egypt compared to other reference and vaccinal strains.

PCR was the most sensitive technique for the detection of FWPV PCR with the results available within a few hours (Williams et al., 2014). Although intracytoplasmic inclusion bodies are histologically pathognomonic of infection with the avian poxvirus (Mubarak and Mahmoud, 2000; Manarolla et al., 2010; Williams et al., 2014), PCR should be used to confirm the diagnosis (Abdel-Moneim et al., 2014). As shown in table2 Homology showed 99.99% similarity between Avipoxvirus-Egy-f1086-2-P4b (OQ385208) and Avipoxvirus-Egy-f1086-3-P4b (OQ385207) and other local references and vaccinal strains of FWPV from the chicken host in Egypt. Lower homology was seen between Avipoxvirus-Egy-f1086-2-P4b (OQ385208), Avipoxvirus-Egy-f1086-3-P4b (OQ385207), reference, and vaccinal strains of APV from other fowl species.

When FWPV is isolated through the CAMs of ECE, the first egg passage produces the recognizable white pock lesions that are indicative of FWPV and show that the virus was tailored to fit embryonated chicken eggs. (Diallo et al., 2010; Manarolla et al., 2010; Abdallah and Hassanin, 2013). FWPV was identified by AGPT. Clear white precipitin lines were obtained with the isolates after the third egg passage using FWPV hyperimmune serum. These results agreed with those recommended AGPT for diagnosis of FWPV (Ohore et al., 2007; El-Kenway et al., 2017).

Alignment of nucleotide sequences of P4b gene of FWPV strains from Al-Sharkia Governorate revealed a close homology (99.99%) with most of local strains [FWPV Egypt 2022 (OP429101), FWPV PM Sharkia2017VSVRI (MH035836), FWPV Al-Sharkia 2012 (JQ665838)], local vaccinal FPV strain [FWPV VSVRI P4b Egypt 2019 (MN708968)] and reference and vaccinal strains recorded in the GenBank [FWPV Diftosec CT (AM050380), FWPV Nobilis Variole W (AM050379)], which suggests that among FWPV isolates, the P4b gene is largely conserved (Abdallah and Hassanin, 2013; Lebdah et al., 2019). Moreover, nucleotide sequences-based phylogenetic tree of 4b gene showed that Avipoxvirus-Egy-f1086-2-P4b (OQ385208) and Avipoxvirus-Egy-f1086-3-P4b (OQ385207) FWPV isolates from Sharkia 2021 were grouped within subclade A1 within Clade A (Abdallah and Hassanin, 2013; Lebdah et al., 2019). Also, the amino acid sequence analysis of Avipoxvirus-Egy-f1086-2-P4b (OQ385208) acquired mutations as E120K and N121D while Avipoxvirus-Egy-f1086-3-P4b (OQ385207) acquired mutations as H83P and S93N (Yehia et al., 2023).

5. CONCLUSION

It is concluded that the efficacy of the existing vaccination against FWPV has to be further investigated.

CONFLICT OF INTEREST

No conflict of interests.

6. REFERENCES

1. Abdallah, F.M. and Hassanin, O. 2013. Detection and molecular characterization of Avipoxviruses isolated from different avian species in Egypt. Virus Genes 46 (1): 63-70.
2. Abdel-Moneim A.A., Shima M.G., Ashraf, M.F. and Eid, A.A.M. 2014. Detection of avian poxvirus in an Egyptian goose (*Alopochen aegyptiaca*). Global Anim Sci J 1:64-8.
3. Atkinson, C.T. and La Pointe, D.A. 2009. Introduced avian Conclusion diseases, climate change, and the future of hawaiian honeycreepers. J. Avian Med. Surg.23, 53-63.

4. DISCUSSION

Fowl poxvirus infection was suspected among 75 – 100 days age layer chicken flocks from Al-Sharkia Governorate, Egypt 2021. Suspected chicken showed skin lesions on the head, comb, wattles, and featherless areas with mortalities ranging from 30 40 % and mortality percent 2-6 % (Abdallah and Hassanin, 2013).

Molecular detection of FPV in suspected samples was done using specific primers for the P4b gene of Avian poxvirus that gave positive results with 5 out of 6 pooled samples from (representative sample for each flock), (Pruker-Radovcic et al., 2006).

4. Binns, M.M., Bournsnel, M.E., Tomley, F.M. and Campbell, J. 1989. "Analysis of the Fowlpoxvirus Gene Encoding the 4b Core Polypeptide and Demonstration that It Possesses Efficient Promoter Sequences." *Virology* 170 (1): 288–291.
5. Diallo, I.S., Taylor, J., Gibson, J., Hoad, J., De Jong, A., Hewitson, G., Corney, B.G., Rodwell, B.J. 2010. Diagnosis of a naturally occurring dual infection of layer chickens with fowlpox virus and gallid herpesvirus 1 (infectious laryngotracheitis virus). *Avian Pathol.*; 39(1):25-30.
6. El-Kenawy, A.A.; Abou El-Azm, K.I. and Awad, S.S.A. 2005. An atypical fowl pox outbreak in broiler flock in Dakahlia Governorate. *Beni-Suef Vet Med J*, 15 (2): 139-144.
7. El-Kenway, A. A., El-Bohy, O.A. and Abd El Rahman, S.E. 2017. Virological studies on Fowl Pox Virus (FPV) isolated from chickens in Dakahlia and Damietta governorates, Egypt. *Mansoura Veterinary Medical Journal* Vol. 18, No. 2, pp 317 – 328.
8. El-Mahdy, S.S.; Awaad, M.H.H. and Soliman, Y.A. 2014. Molecular identification of local field isolated fowl poxvirus strain from Giza Governorate of Egypt. *Vet World*, 7 (2): 66-71.
9. Fauquet, C.M., Mayo, M.A., Maniloff, J. and Desselberger, U., 2005. *Virus Taxonomy: Eighth Report of the International Committee on Taxonomy of Viruses* (p. 1259). Elsevier Academic Press, San Diego, California, USA, 1259.
10. Jarmin, S., Manvell, R., Gough, R.E., Laidlaw, S.M. and Skinner, M.A. 2006. "Avipoxvirus Phylogenetics: Identification of a PCR Length Polymorphism that Discriminates between the Two Major Clades." *Journal of General Virology* 87 (Pt 8): 2191–2201.
11. Lebdah, M.A., Hassanin, O.A. and Ali, A.M.I. 2019. Avipoxvirus in Egypt and African continent: A review. *Zagazig Veterinary Journal*, Volume 47, Number 4, p. 364-377.
12. Manarolla, G., Pisoni, G., Sironi, G., Rampin, T. 2010. Molecular biological characterization of Avian Poxvirus strains isolated from different avian Species. *Vet Microbiol* 140:1-8.
13. Masola, S.N., Mzula, A., Tuntufye, H.N., Kasanga, C.J. and Wambura, P.N. 2014. Isolation and molecular biological characterization of fowl poxvirus from specimen of cutaneous nodular lesions from chickens in several regions of Tanzania. *Microbiol. Res. J. Int.* 4:759–771
14. Mubarak, M. and Mahmoud, M. 2000. Sequential pathological changes in turkeys experimentally infected with chicken pox virus. *Pak Vet J* 20:1-9.
15. Offerman, K.; Carulei, O.; Gous, T.A.; Douglass, N. and Williamson, A.L. 2013. Phylogenetic and histological variation in avipoxviruses isolated in South Africa. *J Gen Virol*, 94: 2338- 2351.
16. Ohore, O.G.; Emikpe, B.O.; Oluwayelu, D.O.; Adeyemi, R.O. and Ockiya, M.A. (2007). Seroprofiling of antibodies to fowl pox in commercial and indigenous chicken in Southwestern Nigeria, *Journal of Animal and Veterinary Advances*, 6(5): 697-701.
17. Office International Des Epizootic (OIE) 2016. *Fowl poxvirus. Manual of Diagnostic Tests and vaccines for Terrestrial Animals. Office International des Epizooties (OIE)*, Chapter 2.3.10:1-8.
18. Office International Des Epizootic (OIE) 2018. *Recommended Diagnostic Technique and Requirements for biological products, Volume 1* (chapter 3.3.10. pp. 907-913).
19. Parker, P.G., Buckles, E.L., Farrington, H., Petren, K., Whiteman, N.K., Ricklefs, R.E., Bollmer, J.L. and Jimenez-Uzategui, G. 2011. 110 years of Avipoxvirus in the Galapagos Islands. *PloSone*. 6.1:e 15989.
20. Prukner-Radovčić, E., Lüscho, D., Ciglar Grozdanić, I., Tisljar, M., Mazija, H., Vranesić D. and Hafez, H.M. 2006. Isolation and molecular biological investigations of avian poxviruses from chickens, a turkey, and a pigeon in Croatia. *Avian Dis.*; 50(3):440-444.
21. Suvarna, S.K., Layton, C. and Bancroft, J.D. 2013. *Bancroft's Theory and Practice of Histological Techniques*. 7th Edition, Churchill Livingstone, Elsevier, England.
22. Tripathy, D.N. 1989. Pox. In Purchase, H.G.; Arp, L.E. Domermuth, C.H. and Pearson, J.E. (Eds). *A laboratory Manual for isolation and identification of avian pathogens*. 3rd Edition.
23. Van Riper, C. and Forrester, D.J. 2007. Avian Pox. In: Thomas, N., Hunter, D.B., Atkinson, C.T. (Eds.). *Infectious Diseases of Wild Birds*. Black well publishing Professional, Ames, Iowa, USA, pp.131-176.
24. Wangner, E.K., Hewlett, M.J., Bloom, D.C. and Camerini, D. 2008. *Basic virology*. Blackwell Pub., Malden, MA, pp.97-137,359-379,435-495.
25. Weli S.C. and Tryland M., 2011. Avipoxviruses: Infection biology and their use as vaccine vectors. *Virology*; 8:49.
26. Williams, R.A., Escudero Duch, C., Pérez-Tris, J. and Benítez, L. 2014. Polymerase chain reaction detection of avipox and avian papillomavirus in naturally infected wild birds: comparisons of blood, swab and tissue samples. *Avian Pathol.* 2014;43(2):130-4.
27. Yehia, N., Elsayed, S., Al-Saeed, F.A., Ahmed, A.E., El-Tarabily, K.A., El-Saadony, M.T., El-Halem, M.A.A. 2023. Current situation and genomic characterization of fowlpox virus in lower Egypt during 2022. *Poultry Science*. Vol. 102(8):102769- 102777.
28. Zhao, K., He, W., Xie, S., Song, D., Lu, H., Pan, W., Zhou, P., Liu, W., Lu, R., Zhou, J. and Gao, F. 2014. Highly pathogenic fowlpox virus in cutaneously infected chickens, China. *Emerg Infect Dis.*; 20(7):1208-1210.