

Enhancing Augmentation Mastopexy with Breast Implant by Extended Superior Pedicle Flap

NIVEEN FATHY AL MAHMOUDY, M.D.; HANY SAAD SETTA, M.D. and MOHAMED OSAMA, M.D.

The Department of Plastic, Burn, Reconstructive and Maxillofacial Surgery, Faculty of Medicine, Ain Shams University

Abstract

Introduction: Augmentation mastopexy is a challenging operation which involves a fine balance between augmentation; expanding the breast volume and mastopexy; reducing the skin envelope. In implant augmentation mastopexy, many authors proposed the use of designed dermoglandular flaps, incorporating tissues from the inferior margin of the breast, it clarifies the idea of using other designed dermoglandular flaps in implant augmentation mastopexy as a tool to augment the coverage of the implant.

Objective: Is to enhance the coverage of implant in augmentation mastopexy using dermoglandular extension of superior pedicle flap.

Patients and Methods: This prospective clinical study was performed in Ain Shams University Hospitals from December 2020 – June 2023, with an average follow-up time of 9 months. 16 women complaining of ptotic hypoplastic breasts, underwent augmentation mastopexy.

Results: All patients underwent augmentation mastopexy with superior based pedicles with extended dermoglandular flap, the breast implants used were smooth rounded implants. The patients had no NAC complications or hematoma. And there were no complications related to the implant either extrusion or infection. However minor complications have occurred as one case with disrupted sutures, two cases with seroma and one case of hypertrophic scarring and they were managed conservatively.

Conclusion: Utilizing the extended dermoglandular flap to cover the implant in superiorly based augmentation mastopexy offers a reliable method with minor complications and high satisfaction scores.

Key Words: Mastopexy – Breast augmentation – Superior pedicle.

Disclosure: No conflict of interest.

Ethical Committee Approval: The study was approved by the Ethical Committee of the Faculty of Medicine, Ain Sham University on 28/10/2020.

Introduction

Breast ptosis is a natural consequence of aging and breastfeeding. It also occurs in cases of weight loss. It involves simultaneous laxity with inelastic skin envelope with a resultant low-profile breast with a nipple-areolar complex (NAC) tending to descend caudal to the inframammary crease [1].

Single stage augmentation and mastopexy is theoretically and technically challenging, as augmentation implies expansion of the breast whereas the mastopexy implies reduction of the skin envelope of the breast, seemingly in conflict with each other [2].

Conventional mastopexy as described by several authors conveys certain goals; raising the central mound of the breast, refashioning and redraping the skin envelope and setting the NAC in an optimal position in relation to the inframammary crease [3]. Breast augmentation with mastopexy, should be approached cautiously. It is of great risk to place the implant through the midline in mastopexy, as it represents the area of the greatest tension, and increasing the risk of implant exposure [4].

In implant augmentation mastopexy, many authors proposed the use of designed dermoglandular flaps [5,6], incorporating tissues from the inferior margin of the breast, therefore, it clarifies the idea of using other designed dermoglandular flaps in implant augmentation mastopexy as a tool to augment the coverage of the implant.

Aim of the study is to enhance the coverage of implant in augmentation mastopexy using dermoglandular extension of superior pedicle flap.

Correspondence to: Dr. Niveen Fathy Al Mahmoudy,
E-Mail: neveenoos@hotmail.com

Patients and Methods

This prospective clinical study was performed in Ain Shams University hospitals from December 2020 – June 2023, with an average follow-up time of 9 months. 16 women (aged between 30 and 49 years) (40 ± 2.374) complaining of ptotic hypoplastic breasts, were included in the study. With exclusion of women who were lactating or had a history of breast disease. Pre-operative mammography was done for all patients to exclude tumours before going to surgery. An informed written and oral consent was obtained from all women, according to the guiding criteria of the ethical committee of Ain Shams University Hospitals.

All patients had implant augmentation mastopexy, where superior pedicle technique was done with extended dermoglandular flap caudal to the pedicle. Standard photographs were obtained pre operative and post operative at 6 months. The breast implant was placed in the dissected pocket subglandular and suprafascial, all participant women were evaluated subjectively by a questionnaire adopted from Spears [7] and objectively through preoperative and postoperative measurements of the sternal notch-nipple (SN-N) and nipple – inframammary fold (N-IMF) distances and statistically analysed. Preoperative and Post-operative photos were taken. All complications were recorded and managed.

Surgical technique:

Marking the superior pedicle using Lejour technique 8 while the patient is in the standing position. All patients were operated upon under general anaesthesia while they were in the supine position

with both arms in abduction. Perioperative one shot of cefotaxime antibiotic prophylaxis was administered and continued orally for 10 days. Following sterilization and after the de-epithelialization of the superior pedicle, extension of the deepithelization was continued caudally to the nipple areola complex with width 6-8cm and length of 8-10cm in the breast meridian.

Full thickness skin incision was made through out the vertical limbs of the dermoglandular flap through breast parenchyma until reaching the pectoral fascia. Dissection was carried out superiorly until the level of the second rib with creation of lateral and medial pillar. A breast sizer was used to determine the best fitting implant in each case. This was done in the smaller breast first in case of breast size discrepancy, thus choosing the best fitting size of implant, which will also be used in the other breast with further refashioning and excision of excess skin.

The breast implant was placed in the dissected pocket subglandular and suprafascial. The caudal edge of the extended dermoglandular flap is tackled to the pectoral fascial, holding the implant in its dissected pocket. Then suturing the medial and lateral edges of the dermoglandular flap to the inferior surface of the medial and lateral pillar respectively (Fig. 1).

Then suturing of the medial and lateral pillars was done over the extended dermoglandular flap, and closure of skin in layers with application of a drain. The same technique was done to the other breast.

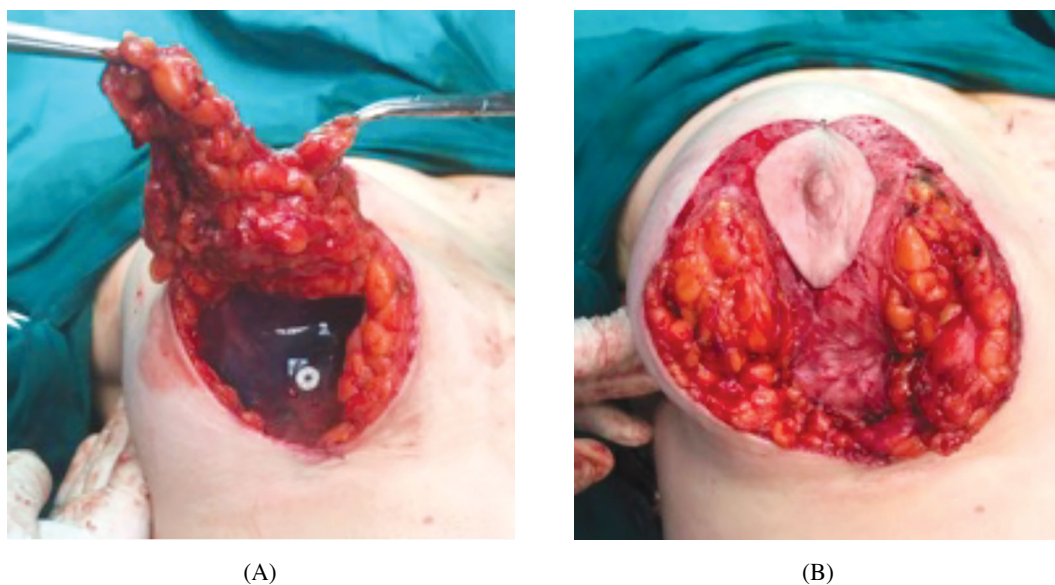


Fig. (1): (A): Intraoperative photo show implant placement in subglandular pocket.
(B): Intraoperative photo after suturing of the extended dermoglandular superior pedicle flap.

Post-operative care and dressing was done, patients were discharged after one to two days for antibiotic intake and close follow-up to NAC and drain removed after minimal drainage with average three days, and instructions were given to the patients not to carry heavy objects or carry on any vigorous exercise for at least one month. Patients were followed up until one year.

Results

16 female patients were included in this study, aged (30-49 years) with average (40±2.374). All patients had ptotic hypoplastic breasts, all patients underwent augmentation mastopexy with superior based pedicles with extended dermoglandular flap, the breast implants used were smooth rounded implants; ranging from 280 cc-375 cc.

None of the patients received intraoperative or post-operative blood transfusion, patients were

discharged after average 3 days, and the patients had no NAC complications (nipple necrosis, or sloughing) or hematoma. And there were no complications related to the implant either extrusion or infection.

However minor complications have occurred as one case with disrupted sutures in the upper part of the vertical line, was recorded and it was managed conservatively with dressing and topical creams. Other two cases with seroma which were managed conservatively and resolved after two months with ultrasound confirmation. And one case of hypertrophic scarring, which was also managed conservatively with topical creams containing silicone, and resolved completely after 6 months.

Post-operative photos were taken (Figs. 2-5). All patients were followed-up to one year.

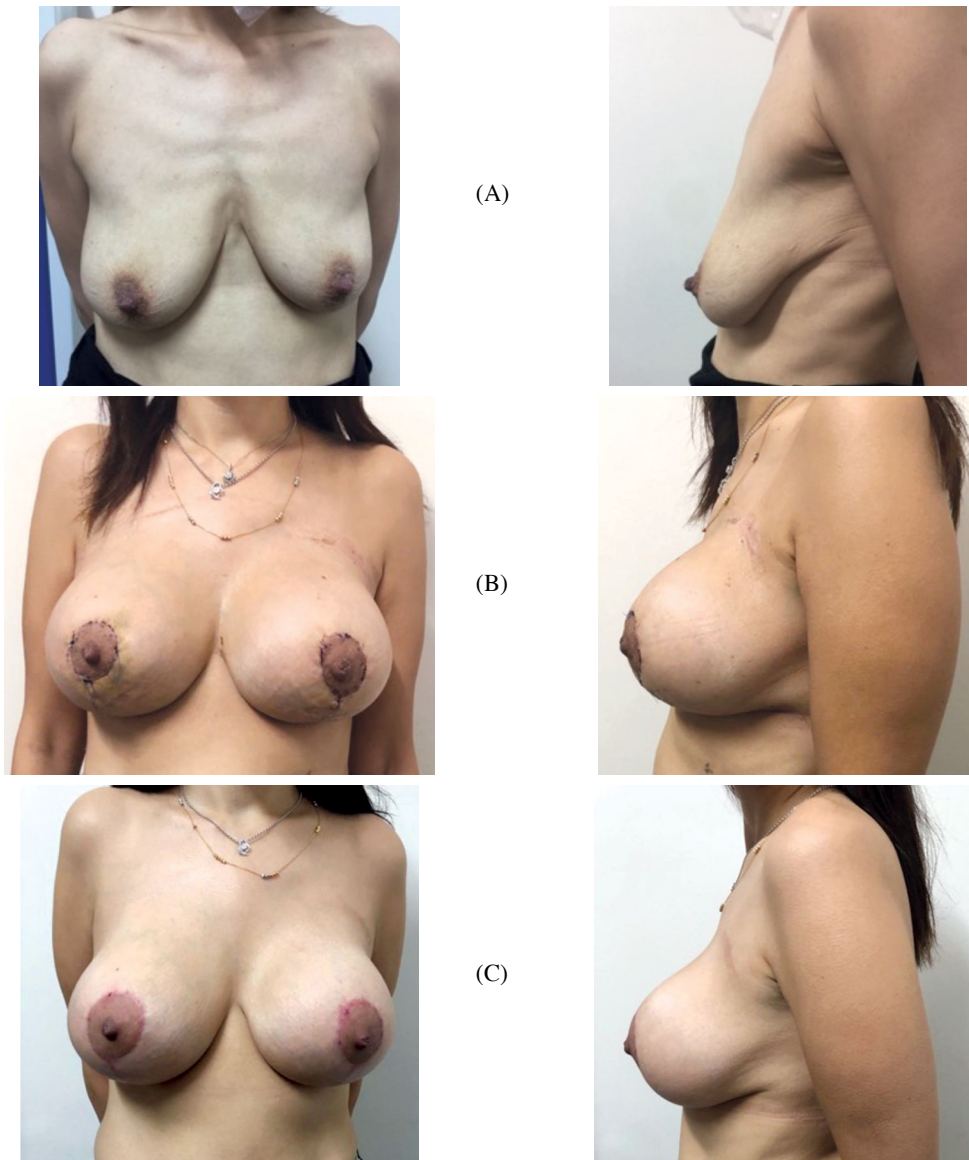


Fig (2): (A): Pre-operative photo anterior and lateral view of 35 years old female patients with ptotic hypoplastic breast, (B) Anterior and lateral view 3 weeks post-operative, (C) Anterior and lateral view 6 month post-operative.

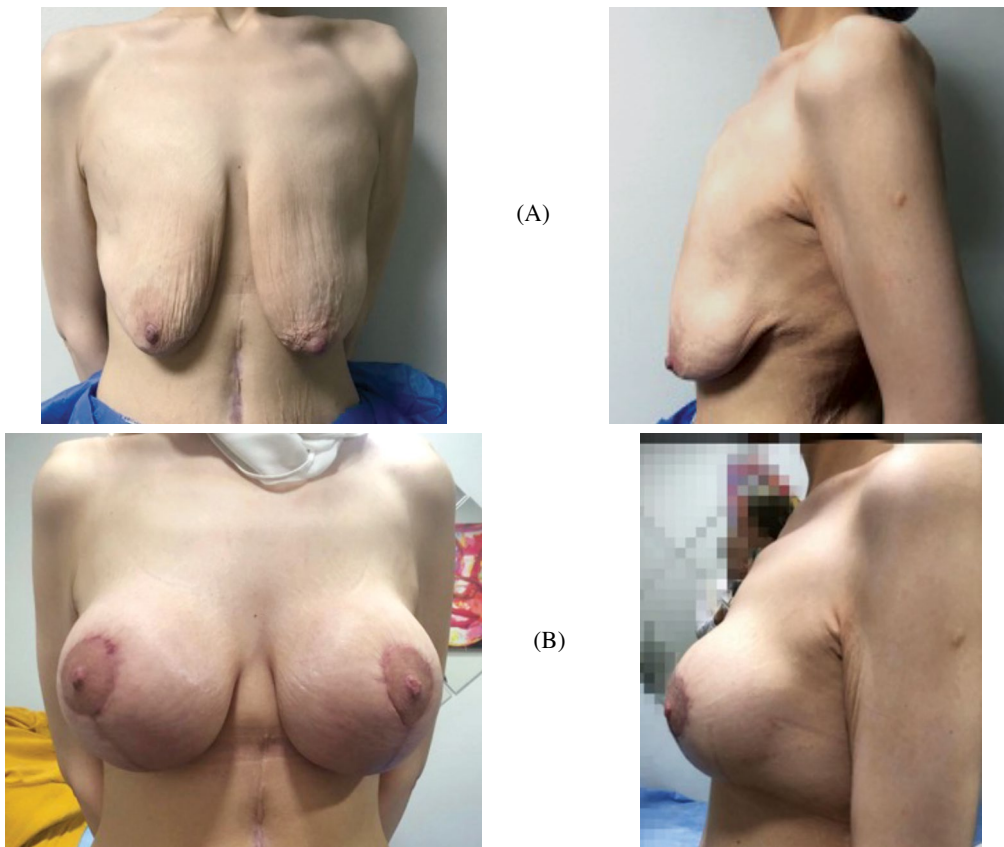


Fig (3): (A): Anterior and lateral view pre-operative photo of 44 years old female patient with ptotic hypoplastic breast, (B): Anterior and lateral view 3 month post-operative photo.

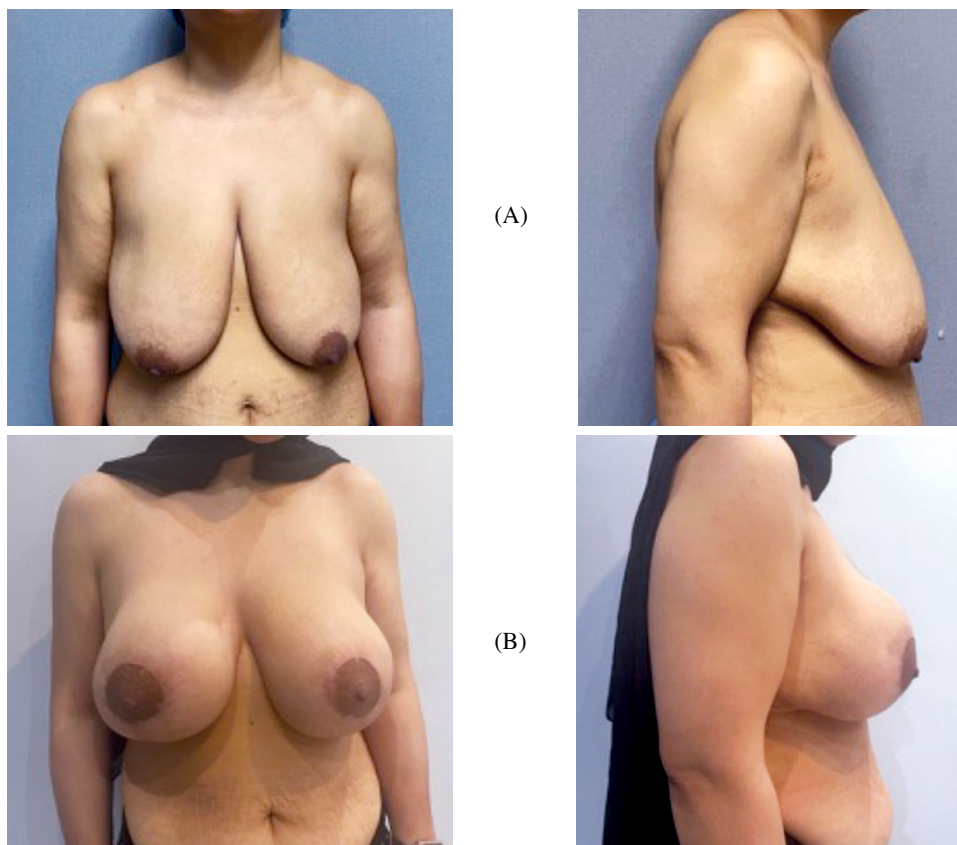


Fig (4): (A): Anterior and lateral view preoperative photo of 42 years old female patient with ptotic hypoplastic breast, (B) Post-operative photo after 9 months anterior and lateral view.

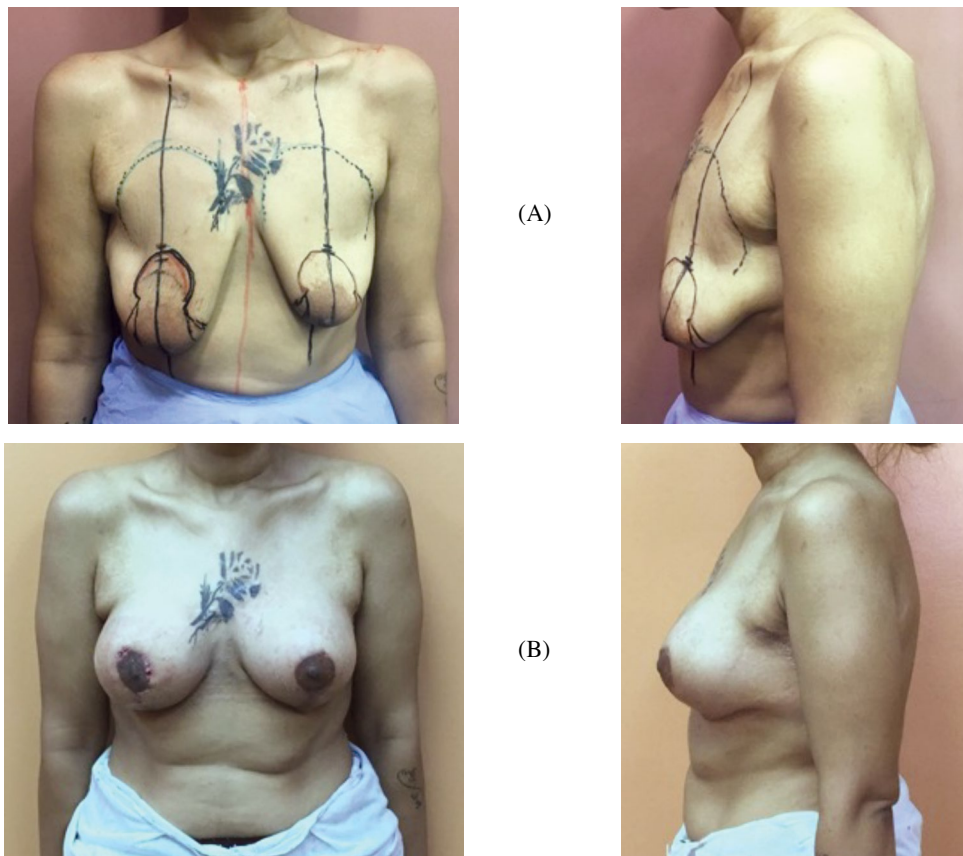


Fig (5): (A) Anterior and lateral view photo of 38 years old female patient with ptotic hypoplastic breast, (B): 2-month post-operative photo, anterior and lateral view.

Results were evaluated subjectively by a questionnaire adapted from Spears 7, where the scale ranged from 1-4, where 4 represents extremely satisfied, 3 represents satisfied, 2 represents neutral and 1 represents dissatisfied. 10 patients had the score of 4 (extremely satisfied), 4 patients had the score of 3 (satisfied) and 2 had the score of 2 (neutral) with no dissatisfied patients.

Measurements of both the sternal notch to nipple and nipple to the infra-mammary fold were noted (Pre-operative and Post-operative). The results show the average SN-N distance pre-operatively was 32.125 ± 2.8 cm and post-operatively 22.75 ± 1.3 cm ($p < 0.0001$). While the average N-IMF distance preoperatively was 14.312 ± 0.79 cm and postoperatively was 8.5 ± 0.73 cm ($p < 0.0001$). There was a highly significant statistical difference between the pre-operative and post-operative measurements.

Discussion

Augmentation mastopexy is a challenging operation which involves a fine balance between augmentation; expanding the breast volume and mastopexy; reducing the skin envelope [9]. Breast reduction or mastopexy alone as described by Swanson [10] 2011, doesn't improve breast projection or upper pole fullness significantly. Breast im-

plants, however do address this. The use of rounded implants gives more pleasing results because such patients are looking for increased volume where they have had a deficit for years.

In this study, rounded implants were the choice for surgery matching with other studies for optimal satisfactory results for the patients.

There are usually concerns about the outcomes of the operation. Concerning the presence of breast implant and incisions of mastopexy increase the possibility and likelihood of wound complications. Moreover, with the presence of implant, and changing the volume of the breast, with repositioning of the inframammary fold makes mastopexy, a more complex operation to adapt the skin envelope precisely [11].

In this study, it was of high concern to plan properly starting from the precise marking, choice of rounded implants, placing a sizer for implant to ensure choosing the proper size that entails tension free closure of wound. Also, in planning for the operation, it was highly considered to do both procedures of mastopexy and augmentation at the same time to minimize the hospital stay and cost for the patient, with minimal complications with highly satisfied patients.

The use of deepithelialized flaps for coverage of breast implants in breast reconstruction surgery was stated in studies which highlighted the success of using them [12,13]. Losken in 2013, described the extended superior medial pedicle technique in breast surgery [14]. Moreover, other articles have described the use of dermal grafts and dermoglandular flaps in aesthetic breast surgery [5,6]. Furthermore, recent studies specified the use of acellular dermal matrix (ADM), either augmentation mastopexy or in revision breast surgeries [15].

In this study, the extended dermoglandular flap of the superior pedicle was used to ensure and enhance the coverage of the implant, with high success rates matching the success of other authors whether in reconstruction or aesthetic breast surgeries. Also, matching successful results of ADM, but with no added cost and with no synthetics used. And this was shown with the results of high satisfaction scores and optimal measurements.

There are certain forewarnings in the augmentation mastopexy operation; increased risk of nipple loss, nipple malposition, central mound devascularization and implant related concerns from seroma, infections up to implant extrusion [1,16]. However, in other studies about augmentation mastopexy in one stage procedure, there was a 17% complication rate in primary cases and 23% in secondary cases, with revision rate 8.7% for primary cases and 16.6% for secondary cases [17]. Also, in a study [18] conducted on 321 cases by 2 surgeons over a period of 14 years, there were 63 cases with complications with 14.6% revision rates.

In this study, there were no major complications, only one case of wound disruption which was managed conservatively, one case with hypertrophic scar which was managed also conservatively with silicon cream, and two cases with seroma which resolved spontaneously within two months and no revision cases.

Conclusion:

Utilizing the extended dermoglandular flap to cover the implant in superiorly based augmentation mastopexy offers a reliable method with minor complications and high satisfaction scores.

References

- 1- Kim P., Kim K.K. and Casas L.A.: Superior Pedicle Autoaugmentation Mastopexy: A Review of 34 Consecutive Patient, *Aesthetic Surgery Journal*, 30 (2): 201–210, 2010.
- 2- Khavanin N., Jordan S.W., Rambachan A. and Kim J.Y.: A Systematic Review of Single-Stage Augmentation-Mastopexy, *Plast. Reconstr. Surg.*, 134 (5): 922–931, 2014.
- 3- Biggs T.M., Graf R. and Taneja A.: Maintaining shape in mastopexy, *Aesthet. Surg. J.*, 23 (5): 391–392, (2003)
- 4- Lazaro Cardenas-Camarena and Roberto Ramirez-Macias: Augmentation/Mastopexy: How to Select and Perform the Proper Technique, *Aesth. Plast. Surg.*, 30: 21–33, 2006.
- 5- Roy de Vita, Giovanni Zoccali and Ernesto Maria Buccheri: The Balcony Technique of Breast Augmentation and Inverted-T Mastopexy With an Inferior Dermoglandular Flap, *Aesthetic Surgery Journal*, 37 (10): 1114–1123, 2017.
- 6- Eduardo Melero Forcada, Miguel Calderon Fernandez, Jorge Vizan Aso, Israel Pena Iglesias and Augmentation Mastopexy: Maximal Reduction and Stable Implant Coverage Using Four Flaps, *Aesth. Plast. Surg.*, 38: 711–717, 2014.
- 7- Scott L. Spear, Christopher V. Pelletiere and Nathan Menon: One-Stage Augmentation Combined with Mastopexy: Aesthetic Results and Patient Satisfaction. *Aesth. Plast. Surg.*, 28: 259–267, 2004.
- 8- Lejour M.: Vertical mammoplasty: Early complications after 250 personal consecutive cases. *Plast. Reconstr. Surg.*, 104 (3): 764–770, 1999.
- 9- Persoff M.M.: Vertical mastopexy with expansion augmentation. *Aesth. Plast. Surg.*, 27: 13–19, 2003.
- 10- Swanson E.: A retrospective photometric study of 82 published reports of mastopexy and breast reduction. *Plast. Reconstr. Surg.*, 128: 1282–1301, 2011.
- 11- Scott L. Spear, Mervin Low and Ivica Ducic: Revision Augmentation Mastopexy: Indications, Operations, and Outcomes, *Ann. Plast. Surg.*, 51: 540–546, 2003.
- 12- Mestak J., Sukop A. and Mestak O.: Use of deepithelialized flap in mammoplasties: Simple method with excellent results. *Aesthetic Plast. Surg.*, 35: 1106–1111, 2011.
- 13- Ladizinsky D.A., Sandholm P.H., Jewett S.T., Shahzad F. and Andrews K.: Breast reconstruction with the Bostwick autoderm technique. *Plast. Reconstr. Surg.*, 132 (2): 261–270, 2013.
- 14- Albert Losken and Christopher D.: Funderburk, Claire Duggal. The Extended Superomedial Pedicle: Advancing Mammoplasty Techniques. *Modern Plastic Surgery*, 3: 20–27, 2013.
- 15- Spear S.L., Sinkin J.C. and Al-Attar A.: Porcine acellular dermal matrix (Strattice) in primary and revision cosmetic breast surgery. *Plast. Reconstr. Surg.*, 131 (5): 1140–1148, 2013.
- 16- Spear S.L., Boehmler J.H. IV and Clemens M.W.: Augmentation/ mastopexy: A 3-year review of a single surgeon's practice. *Plast. Reconstr. Surg.*, 118 (Suppl): 136S–147S, 2006.
- 17- Gonzalez R.: The PAM method periareolar augmentation mastopexy: A personal approach to treat hypoplastic breast with moderate ptosis. *Aesthet. Surg. J.*, 32: 175–185, 2012.
- 18- Stevens W.G., Freeman M.E., Stoker D.A., Quardt S.M., Cohen R. and Hirsch E.M.: One-stage mastopexy with breast augmentation: A review of 321 patients. *Plast. Reconstr. Surg.*, 120: 1674–1679, 2007.