

Intra-articular injection of Hyaluronic acid-Botox mixture versus Hyaluronic acid alone for Treatment of Anterior Disc Displacement of the Temporomandibular Joint: A Randomized Clinical Trial.

Original
Article

Ahmed Khalil Fawzi¹, Riham Fliefel²

¹ Department of Oral and Maxillofacial Surgery, Faculty of Dentistry, Horus University, New Damietta, Egypt. ² Department of Oral and Maxillofacial Surgery, Faculty of Dentistry, Alexandria University, Alexandria, Egypt.

ABSTRACT

Background: Anterior disc displacement without reduction (ADDWOR) is one of the most annoying temporomandibular disorders (TMDs). Several medications have been used for intra-articular injection in temporomandibular joint (TMJ) for treatment of ADDWOR. One of the widely used medications is Hyaluronic acid (HA) due to its biological functions inside body joints. Botox also has a very crucial role for pain relief in joints and has never been intra-articularly injected for treatment of any TMD.

Aim: To compare the intra-articular injection of HA-Botox mixture versus HA alone for the treatment of Anterior disc displacement of TMJ.

Methods: 28 patients seeking treatment of ADDWOR were randomly divided into two groups, group I injected with HA-Botox mixture, while group II injected with HA only. The two groups were evaluated at 1 week, 1 and 3 months post-operatively.

Results: A significant difference was found between the two groups in any of the evaluation variables. At the end of the treatment, a general improvement of the clinical status was noticed; MRI, however, showed some degrees of condyle-disc incoordination in some patients.

Conclusion: Addition of Botox to Hyaluronic acid in intra-articular injection of TMJ has a significant improvement in the treatment of ADDWOR

Key Words: Temporomandibular Disorder, Botox, Hyaluronic acid, Intra-articular injection.

Received: 11 September 2024, **Accepted:** 13 September 2024.

Corresponding Author: Riham Fliefel, 2Department of Oral and Maxillofacial Surgery, Faculty of Dentistry, Alexandria University, Alexandria, Egypt. , **Mobile:** 01024267642

E-mail: riham.fliefel@alexu.edu.eg

ISSN: 2090-097X, October 2024, Vol. 15, No. 4

INTRODUCTION:

Temporomandibular issues (TMD) are a set of musculoskeletal and neuromuscular situations affecting the masticatory muscle groups, the temporomandibular joint (TMJ) and the opposite associated systems [1]. According to the Diagnostic Criteria for TMD (DC/TMD) Axis I, TMD was divided in intra-articular disorders, together with disc displacement, arthralgia, arthritis, and arthrosis, and muscle problems [2].

Various interventions have been proposed for the control of anterior disc displacement with reduction (ADDWR) including non-invasive (conservative), comprising education, self-management, splint therapy, physiotherapy or intra-articular injections; in addition to minimally invasive techniques, containing arthrocentesis; or invasive (surgical), with arthroscopic and open joint surgeries [3].

Many agents were proposed as an intra-articular injection material for remedy of anterior disc displacement with reduction which includes corticosteroids, hyaluronic acid (HA), non-steroidal anti-inflammatory drugs

(NSAIDs), dextrose, blood concentrates like platelet rich fibrin (PRF) or platelet rich plasma (PRP), ozone gas or even botulinum toxin type A (Botox A) [4-6].

Hyaluronic acid (HA) is taken into consideration as one of the handiest retailers that is commonly used in intra-articular injection for treatment of temporomandibular joint disorders (TMD) signs and symptoms. Its motion comes from its several organic capabilities in joint space together with lubrication, scavenging free radicals, regulating mobile hobby and filling joint areas. In addition to its unusual rheological homes which permit HA to be injected through small pore needle [7, 8]

Botulinum toxin is the exotoxin of a gram-positive aerobic bacterium called *Clostridium botulinum* with eight different types. Botulinum toxin type A (Botox A) is a biologic variant that temporarily inhibits the skeletal muscle through hindering the production of acetylcholine and inactivation of calcium channels in the nerve endings [9]. Botox A specificity for cholinergic neurons within the presence of particular receptors makes it inhibit the effect

of other neurotransmitters, including norepinephrine, epinephrine and calcitonin gene-associated peptide, so Botox-A can also be used to alleviate pain [10, 11].

Temporomandibular disorders (TMD) and related pain are becoming an increasingly common social problem. Patients suffering from TMJ pain seek help from specialists in various fields of medicine, including prosthodontists, orthodontists, neurologists, and physiotherapists. Importantly, the effects of monotherapies are often insufficient due to the interdisciplinary nature of the problem [12].

Given the unsatisfactory results of current medical solutions and the scarcity of research, thus, the aim of the present study was therefore to compare the effect of the intra-articular injection of Hyaluronic acid-Botox mixture versus Hyaluronic acid alone for Treatment of Anterior Disc Displacement of the Temporomandibular Joint. up to 3 months post injection.

PATIENTS AND METHODS

Ethical approval and Registration

This study was performed at the Department of Oral and Maxillofacial Surgery, Faculty of Oral and Dental Medicine, Horus University, New Damietta, Egypt from January 2024 to July 2024. The study protocol was approved by the Research Ethics Committee of Horus University, New Damietta, Egypt under the number D-2024002-

Study Participants

Twenty-eight patients were included in the study for the treatment of the treatment of Anterior Disc Displacement of the Temporomandibular Joint. All patients were informed about the nature of the study and gave their written consent. The follow-up of the patients was at least 3 months.

The minor complications were reported as the sensation of pain after injection while the major complication the patient might suffer of is paralysis in the masseter muscle due to the injection. The patients have the right to withdraw at any time of the procedure.

Inclusion Criteria

The patients were included in the study after fulfilling the following inclusion criteria: a) Age range between 18-40 years with no gender predilection; b) unilateral anterior disc displacement with limited mouth opening; c) TMJ pain with tension in the masticatory muscle; d) Reduced maximal interincisal opening (MIO); e) Minor or no radiological bone changes; f) Unsuccessful conservative treatments within the last three months.

Exclusion Criteria

The patients were excluded if: a) Pregnant females prior TMJ surgery or Botox-A treatment; b) Having systemic diseases as myasthenia gravis, fibromyalgia, peripheral neuropathy or some other sickness, which could intervene with neuromuscular, feature.

Randomization and allocation concealment

The patients were randomly allocated into two groups (n=14 per group): Group I treated with intra-articular injections of Botox and Hyaluronic mixture in the TMJ while Group II treated with intra-articular injection of Hyaluronic acid alone. Randomization was performed using an online service (<https://www.randomizer.org/>) [13]. After obtaining informed consent, the participants were randomly allocated using sequentially numbered, opaque, sealed, and stapled envelopes (SNOSE). At the time of intra-articular injection, the envelope was opened by the maxillofacial surgeon to determine the assigned treatment group.

Intra-articular injection

The patient's face was prepared in the usual and sterile manner using BETADINE (Povidone Iodine antiseptic Solution 10%, Mundipharma, Cairo, Egypt). Next, local anesthesia (2% lidocaine, Alexandria Company for Pharmaceuticals and Chemical Industries, Alexandria, Egypt) was applied to the auriculotemporal nerve. The puncture site was located by manipulating the mandible antero-inferiorly and marked on the skin. The articular fossa is located 7-10 mm anteriorly from the tragus and 1-2 mm inferiorly from the tragal-canthal line. At this location, a 19-gauge needle was inserted into the posterior part of the upper joint compartment of the TMJ; the correct location of the needle was confirmed by moving the mandible during the fluid injection. Botox-A (100 units/vial, Xeomin; Clostridium botulinum type A, Merz Pharma, Germany) was diluted with 5 ml of 0.9% normal saline to obtain a 20 U/0.1 ml solution. Botox-A was then prepared for injection in a 1 ml insulin syringe with 30-gauge needle and injected intra-articularly into the superior joint space in the marked points. After injection, an ice pack was placed to injection areas. Later, 1ml of HA (Refinal max syringe, Koru pharmaceuticals, South Korea) was slowly injected to the point of injection into the SJS. After that, the needle was slowly withdrawn and the patient was asked to gently manipulate his mandible in protrusive, vertical and lateral excursions to free up the disc.

Postoperative care

The patients were given Instructions for soft diet and home physical therapy (moist heat and mandibular exercises 4 times daily for 1 month). The patients have been prescribed 1g of antibiotic tablet three times daily for prophylaxis of any joint space infection for 5 days (Amoxicillin + clavulanic acid; Augmentin 625 mg, GlaxoSmithKline, Malta). Ibuprofen (BRUFEN 600 mg, Abbott Egypt, Cairo, Egypt) was also prescribed three times daily as an anti-inflammatory when needed. Patients were evaluated at 1 week, 1 month and 3 months from the time of the injection, for improvement of signs and symptoms.

Assessment of Pain

Pain was assessed pre-injection and at 1 week, 1 and 3 months from the time of the injection. Joint pain was assessed with 100 mm VAS with end points marked „no pain“ and „worst pain ever experienced“. The absence of pain was scored as 0. If pain was present the patient was asked to select a marked field from 1mm to 100 mm.

Assessment of Maximal interincisal opening (MIO)

MIO refers to the distance between maxillary and mandibular incisors edges when the patient opened the mouth as widely as possible. MIO was assessed pre-injection and at 1 week, 1 and 3 months from the time of the injection.

Magnetic Resonance scanning and image analysis

The subjects were asked to remove metal objects on the body, and taught to use the wooden mouth-opener. The layer at which condyle and articular disc were most clearly displayed was selected. The middle location of the condyle was set as an intermediate layer, and we adjusted the appropriate echo time, repetition time, scanning range, layer thickness, and spacing. We saved the settings to open the scan, which can complete a TMJ imaging at closed-mouth position. With the head unmoved, the subjects slowly opened the lower jaw and scanning was performed at the first grid (5 mm), the second grid (15 mm), the third grid (25 mm) and a maximum opened-mouth position. Image analysis included determination of articular disc position at closed-mouth position, disc-condyle relationship during the opening process, measurement of joint disc thickness, and measurement of condylar activity and intra-articular effusion.

Primary Outcomes

Postoperative pain following the intra-articular injection of the medications assessed for 3 months using the Visual Analogue Scale (VAS) as well as measuring the maximal interincisal opening (MIO).

Statistical Analysis

Data was fed to the computer and analyzed using IBM SPSS software package version 20.0. (Armonk, NY: IBM Corp). Categorical data were represented as numbers and percentages. Chi-square test was applied to compare between two groups. Alternatively, Fisher Exact correction test was applied when more than 20% of the cells have expected count less than 5. For continuous data, they were tested for normality by the Shapiro-Wilk test. Quantitative data were expressed as range (minimum and maximum), mean, standard deviation and median for normally distributed quantitative variables Student t-test was used to compare two groups while ANOVA with repeated measures was used to compare between more than two periods and Post Hoc Test (adjusted Bonferroni) for pairwise comparisons. On the other hand for not normally distributed quantitative variables Mann Whitney test was used to compare two groups while Friedman test was used to compare between more than two periods and Post Hoc Test (Dunn's) for pairwise comparisons. Significance of the obtained results was judged at the 5% level.

RESULTS

Clinical Outcomes

This study included twenty-eight patients, 7 males and 21 females, with a mean age of 24.57 ± 3.22 years (ranging from 19 to 31 years) who completed the study and randomly allocated into either of the two groups. The patients have undergone intra-articular injection of HA-Botox A or HA alone in the TMJ. The anterior disc displacement was on the right for 15 patients while on the left side for 13 patients. The CONSORT flowchart of the randomized controlled clinical trial was presented in Figure 1.

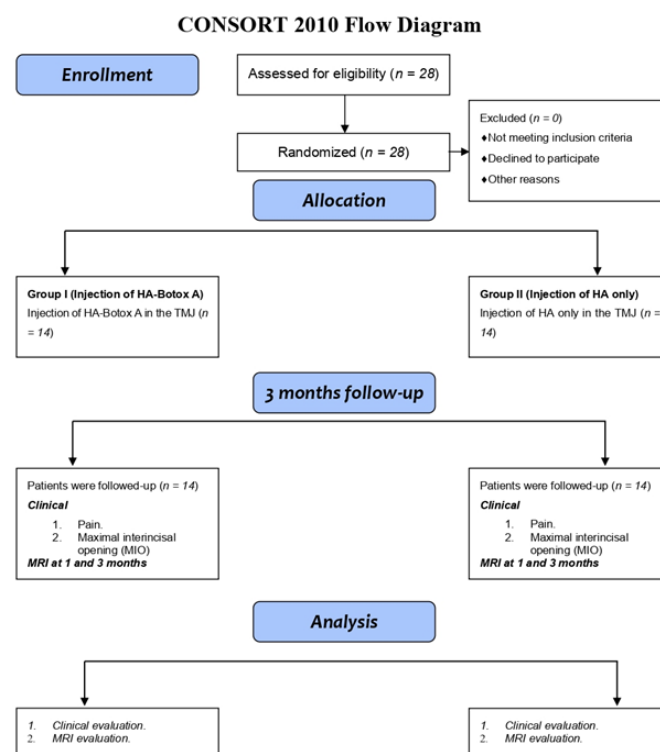


Figure 1: CONSORT 2010 Flow Diagram of the study.

Regarding pain, in group I, there was a significant improvement among all intervals ($P < 0.001$) when pre-operative pain was compared to that of 1 week ($P < 0.003$), 1 month ($P < 0.001$) and three months ($P < 0.001$) after the second injection. In group II, there was a significant difference between all intervals in group II ($P < 0.001$) when preoperative pain was compared at 1 week ($P < 0.001$), 1 month ($P < 0.001$) and three months ($P < 0.143$). Also, when group I and group II were compared for improvement of pain there was a significant difference ($P < 0.05$) in the degree of pain at any of three post-operative follow up intervals 1 week ($P < 0.014$), 1 month ($P < 0.001$) and 3 months ($P < 0.001$) (Table 1)

Table 1: Pain assessment by Visual Analogue Scale (VAS) before and after intra-articular injection

	Pre-injection	1 week	1 months	3 months	P-Value
Group I (n=14)					
Mean±SD	6.1±1	2.3±0.83	1.8±0.58	1.6±0.51	<0.001*
P-Value		0.003*	<0.001*	<0.001*	
Group II (n=14)					
Mean±SD	6.8±0.89	3.1±0.62	4.2±0.70	5.6±0.65	<0.001*
P-Value	0.114	0.014*	<0.001*	<0.001*	

*: Statistically significant at p ≤ 0.05

Regarding maximal interincisal opening (MIO), in group I, there was an overall improvement in mouth opening with a significant difference at all intervals (P < 0.001). In group II, there was also an improvement in the mouth opening at all intervals with a significant difference ((P < 0.001). When group I and group II were compared for improvement of mouth opening there was no preoperative significant difference, while there were significant differences after intra-articular injections between the two groups after 1 week (P=008), 1month (P< 0.001) and 3 months (P< 0.001) (Table 2)

Table 2: Maximal interincisal opening (MIO) before and after intra-articular injection

	Pre-injection	1 week	1 months	3 months	P-Value
Group I (n=14)					
Mean±SD	29.1±2.8	35.9±3.0	39.3±2.3	40.9±2.1	<0.001*
P-Value		<0.001*	<0.001*	<0.001*	
Group II (n=14)					
Mean±SD	29.2±2.7	32.7±2.8	33±1.6	31.7±1.8	<0.001*
P-Value	0.892	0.008*	<0.001*	<0.001*	

*: Statistically significant at p ≤ 0.05

Regarding MRI findings, in group I, there were improvements in most of cases from anterior disc displacement without reduction (ADDWOR) to anterior disc displacement with reduction (ADDWR) or even no abnormality detected (NAD) with a significant difference after 1 month (P < 0.001), 3 months (P <0.001) and 6 months (P <0.001) of injections. In group II, also there were improvements in most of cases from anterior disc displacement without reduction (ADDWOR) to anterior disc displacement with reduction (ADDWR) or even no abnormality detected (NAD) with a significant difference after 1 moth (P< 0.001), 3 months (P<0.001) and 6 months (P <0.001) of injections. While when comparing group I and II together, there was no statistical difference after 1 month (P= 0.326), but there was a statistical differences after 3 months (P= 0.018) and after 6 months (P= 0.002) of injections (Table 3)

Table 3: Magnetic resonance imaging (MRI) findings before and after intra-articular injection

	Pre-injection	1 week	1 months	3 months	P-Value
Group I (n=14)					
ADDWOR (n,%)	14(100)	0(0)	0(0)	0(0)	<0.001*
NAD (n,%)	0(0)	4(28.6)	8(57.1)	10(71.4)	
ADDWR (n,%)	0(0)	10(71.4)	6(42.9)	4(28.6)	
P-Value		<0.001*	<0.001*	<0.001*	
Group II (n=14)					
ADDWOR (n,%)	14(100)	0(0)	0(0)	0(0)	<0.001*
NAD (n,%)	0(0)	1(7.1)	2(14.3)	2(14.3)	
ADDWR (n,%)	0(0)	13(92.9)	12(85.7)	12(85.7)	
P-Value		0.326	0.018*	0.002*	

*: Statistically significant at p ≤ 0.05

DISCUSSION

Temporomandibular disorders (TMD) are a significant public health problem affecting approximately 5-12% of the population, and the second most prevalent musculoskeletal condition resulting in pain with disc displacement (DD) being a major type of internal derangement, of patients with symptomatic TMD [14].

TMDs are associated with joint sounds, restricted mouth opening, impairing functional mandibular movements, and negatively affecting the patient's quality of life^[15].

Because intra-articular injection has previously been demonstrated to be effective for relieving durable pain in patients suffering from internal derangement of the TMJ, the present study was designed for assessing the effectiveness of viscosupplementation for the treatment of anterior disc displacement of the Temporomandibular Joint.

Various epidemiologic studies have indicated the prevalence of TMD varies substantially, depending on age, gender, population, and method of assessment of TMD. From the results of our study, TMDs appearing to be quite common among young and middle-aged adults, with a peak of occurrence between 20 and 40 years of age. This was in accordance to a study published^[16] supporting our findings that adults/elderlies have a higher prevalence of TMJD than older patients.

In our study, females were found to have a higher risk of TMD than males, yet the results were not significant. This might be attributed to behavioral, psychosocial, hormonal, and constitutional factors^[17]. This was in accordance with some studies^[18, 19].

Intra-articular injections and arthrocentesis are the current minimally invasive techniques used to treat TMJ internal derangement that failed to improve following a reasonable course of non-surgical therapy^[20]. Substances ranging from steroids to hyaluronic acid have been injected successfully into various joints of the body in an attempt to provide relief for chronic joint pain^[21]. Hyaluronic acid (HA) is a non-sulfated glycosaminoglycan, a polysaccharide, physiologically occurs within the articular cartilage and the synovial fluid. HA forms a layer which not only covers but also penetrates the articular surfaces. It has been proven that HA plays a significant role in the nutrition and lubrication of the TMJ articular surfaces^[22].

Botulinum toxin is a bacterial metalloproteinase produced by *Clostridium botulinum*. This neurotoxin specifically blocks the release of acetylcholine in the presynaptic membrane of neuromuscular junctions^[8]. Botox A is injected into masticatory muscles (masseter and temporalis) to treat trismus, bruxism, masticatory muscle myalgia, temporomandibular joint disorders or muscle hypertrophy^[23].

From the results of our study, HA had improved the pain after the intra-articular injection than the pre-injection. This improvement was limited in time as joint washing and hyaluronic acid infiltration are no longer significant at 1 and 3 months. This is due to the short term effect of the HA injection. This was in accordance with the data published by Sikora et al [12]. The study confirmed the short-term effectiveness of intra-articular administration of hyaluronic acid on reducing joint and muscle pain in patients with articular disc displacement.

The same results goes for the MIO, this study showed a significant increase in MIO measurements between the pre-injection and the 1 month post-injection. This was in line with another study^[24]. However, at 3 months, the maximal interincisal opening was decreased again indicating the washing away of the HA.

Botulinum toxin has been implemented in the medical area for several years by weakening or paralyzing certain muscles or by blocking certain nerves is intended to restore relief to the pain area^[25]. In our study, 14 patients were injected with a combination of Botox A together with HA. From our results, the combination of the two viscosupplementation had improved not only pain but also the maximal interincisal opening. Freund et al. in 1999^[31] were the first to report preliminary results on the benefits of BTX on pain, function and mouth opening. Subsequently, these same investigators, in an expanded sample of 46 patients, demonstrated that intramuscular injections of Botox A produced significant improvements in pain, function and mouth opening, reducing the severity of symptoms and improving the functional abilities of patients with TMDs, and that these effects would extend beyond its capacity as a muscle relaxant^[26]. In accordance to our results, some other studies have proved the efficiency of Botox in the relief of pain and increasing the mouth opening^[27, 28].

CONCLUSION:

The intra-articular injection of a mixture of Botox A and HA proved to be less invasive, less painful, less time consuming and showed more patient compliance compared to the injection of HA alone in the management of TMJ internal derangement with reduction.

Conflicts of interest

The authors declare no conflict of interest.

Funding

This research received no external funding.

REFERENCES

- Palmer J and Durham J. Temporomandibular disorders. *BJA Educ* 2021; 21: 44-50.
- Schiffman E, Ohrbach R, Truelove E, Look J, Anderson G, Goulet JP, Lišt T, Svensson P, Gonzalez Y, Lobbezoo F, Michelotti A, Brooks SL, Ceusters W, Drangsholt M, Ettlin D, Gaul C, Goldberg LJ, Haythornthwaite JA, Hollender L, Jensen R, John MT, De Laat A, de Leeuw R, Maixner W, van der Meulen M, Murray GM, Nixdorf DR, Palla S, Petersson A, Pionchon P, Smith B, Visscher CM, Zakrzewska J, and Dworkin SF. Diagnostic Criteria for Temporomandibular Disorders (DC/TMD) for Clinical and Research Applications: recommendations of the International RDC/TMD Consortium Network* and Orofacial Pain Special Interest Group†. *J Oral Facial Pain Headache* 2014; 28: 6-27.

3. Al-Baghdadi M, Durham J, Araujo-Soares V, Robalino S, Errington L, and Steele J. TMJ Disc Displacement without Reduction Management: A Systematic Review. *J Dent Res* 2014; 93: 37s-51s.
 4. Gencer ZK, Özkiriş M, Okur A, Korkmaz M, and Saydam L. A comparative study on the impact of intra-articular injections of hyaluronic acid, tenoxicam and betametazon on the relief of temporomandibular joint disorder complaints. *J Craniomaxillofac Surg* 2014; 42: 1117-21.
 5. Pihut M and Gala A. The Application of Intra-Articular Injections for Management of the Consequences of Disc Displacement without Reduction. *Int J Environ Res Public Health* 2020; 17.
 6. Bahgat MM, El-Helw NR, Abdelhamid AM, and Emam MH. Botulinum Toxin Type A: An Evolving Treatment Modality in the management of Temporomandibular Joint Disc Displacement. *Alexandria Dental Journal* 2018; 43: 57-61.
 7. Tamer TM. Hyaluronan and synovial joint: function, distribution and healing. *Interdiscip Toxicol* 2013; 6: 111-25.
 8. Goiato MC, da Silva EV, de Medeiros RA, Túrcio KH, and Dos Santos DM. Are intra-articular injections of hyaluronic acid effective for the treatment of temporomandibular disorders? A systematic review. *Int J Oral Maxillofac Surg* 2016; 45: 1531-1537.
 9. Ataran R, Bahramian A, Jamali Z, Pishahang V, Sadeghi Barzegani H, Sarbakhsh P, and Yazdani J. The Role of Botulinum Toxin A in Treatment of Temporomandibular Joint Disorders: A Review. *J Dent (Shiraz)* 2017; 18: 157-164.
 10. Aoki KR and Guyer B. Botulinum toxin type A and other botulinum toxin serotypes: a comparative review of biochemical and pharmacological actions. *Eur J Neurol* 2001; 8 Suppl 5: 21-9.
 11. Dressler D and Benecke R. Autonomic side effects of botulinum toxin type B treatment of cervical dystonia and hyperhidrosis. *Eur Neurol* 2003; 49: 34-8.
 12. Sikora M, Czerwińska-Niezabitowska B, Chęciński MA, Sielski M, and Chlubek D. Short-Term Effects of Intra-Articular Hyaluronic Acid Administration in Patients with Temporomandibular Joint Disorders. *J Clin Med* 2020; 9.
 13. Urbaniak GC and S P, Research Randomizer. 2013.
 14. Li J, Zhang Z, and Han N. Diverse therapies for disc displacement of temporomandibular joint: a systematic review and network meta-analysis. *British Journal of Oral and Maxillofacial Surgery* 2022; 60: 1012-1022.
 15. Rady NA, Bahgat MM, and Abdel-Hamid AM. Promising minimally invasive treatment modalities for symptomatic temporomandibular joint disc displacement with reduction: a randomized controlled clinical trial. *BMC Oral Health* 2022; 22: 547.
 16. Casanova-Rosado JF, Medina-Solís CE, Vallejos-Sánchez AA, Casanova-Rosado AJ, Hernández-Prado B, and Ávila-Burgos L. Prevalence and associated factors for temporomandibular disorders in a group of Mexican adolescents and youth adults. *Clinical Oral Investigations* 2006; 10: 42-49.
 17. Bagis B, Ayaz EA, Turgut S, Durkan R, and Özcan M. Gender difference in prevalence of signs and symptoms of temporomandibular joint disorders: a retrospective study on 243 consecutive patients. *Int J Med Sci* 2012; 9: 539-44.
 18. Manfredini D, Chiappe G, and Bosco M. Research diagnostic criteria for temporomandibular disorders (RDC/TMD) axis I diagnoses in an Italian patient population. *J Oral Rehabil* 2006; 33: 551-8.
 19. Bueno CH, Pereira DD, Pattussi MP, Grossi PK, and Grossi ML. Gender differences in temporomandibular disorders in adult populational studies: A systematic review and meta-analysis. *Journal of Oral Rehabilitation* 2018; 45: 720-729.
 20. Marzook HAM, Abdel Razek AA, Yousef EA, and Attia AAMM. Intra-articular injection of a mixture of hyaluronic acid and corticosteroid versus arthrocentesis in TMJ internal derangement. *Journal of Stomatology, Oral and Maxillofacial Surgery* 2020; 121: 30-34.
 21. Lavelle W, Lavelle ED, and Lavelle L. Intra-articular injections. *Anesthesiol Clin* 2007; 25: 853-62, viii.
 22. Derwich M, Mitus-Kenig M, and Pawlowska E. Mechanisms of Action and Efficacy of Hyaluronic Acid, Corticosteroids and Platelet-Rich Plasma in the Treatment of Temporomandibular Joint Osteoarthritis-A Systematic Review. *Int J Mol Sci* 2021; 22.
 23. Kahn A, Bertin H, Corre P, Praud M, Paré A, and Kündarbois J-D. Assessing the effectiveness of botulinum toxin injections into masticatory muscles in the treatment of temporomandibular disorders. *J Oral Med Oral Sug* 2018; 24: 107-111.
 24. Lewandowski L. The management of some temporomandibular joints diseases with intra-articular administration of medicines. *Polish Journal of Stomatology* 2006; 59: 266-271.
 25. Nigam PK and Nigam A. Botulinum toxin. *Indian J Dermatol* 2010; 55: 8-14.
 26. Freund B, Schwartz M, and Symington JM. Botulinum toxin: new treatment for temporomandibular disorders. *Br J Oral Maxillofac Surg* 2000; 38: 466-71.
 27. Pihut M, Ferendiuk E, Szweczyk M, Kasprzyk K, and Wieckiewicz M. The efficiency of botulinum toxin type A for the treatment of masseter muscle pain in patients with temporomandibular joint dysfunction and tension-type headache. *J Headache Pain* 2016; 17: 29.
 28. Hosgor H and Altindis S. Efficacy of botulinum toxin in the management of temporomandibular myofascial pain and sleep bruxism. *J Korean Assoc Oral Maxillofac Surg* 2020; 46: 335-340.
-