

Different modalities of nasolabial flaps in nasal-defect reconstruction: clinical experience in 40 cases and review of literature

Ayman M. Abdelmofeed^a, Refaat S. Salama^b

^aDepartment of General Surgery, Plastic Surgery Unit, ^bDepartment of General Surgery, Benha University, Benha, Egypt

Correspondence to Ayman M. Abdelmofeed, MD, Department of General Surgery, Benha University Hospital, 1 Farid Nada Street, Benha, 13511; Egypt. Tel: 01061627850; Fax: 0133231012; e-mail: aymanabdelmofeed@yahoo.com

Received: 10 June 2021

Accepted: 5 July 2021

Published: xx Month 2021

The Egyptian Journal of Surgery 2021, 40:1192–1204

Background

Nasal-defect reconstruction is a challenging subject, nasolabial flaps are common methods for nasal reconstruction. Different modalities of nasolabial flaps were identified as V–Y advancement, superiorly or inferiorly based, freestyle perforator based, interpolated flap, and propeller types are commonly used.

Objective

The objective of the study is to evaluate the different modalities of nasolabial flaps in nasal-defect reconstruction and review of literature about nasal reconstructions with nasolabial flaps defining the advantages and disadvantages for each subunit.

Patients and methods

The study included 40 patients presented with nasal defects admitted to Benha University Hospital in the period from December 2018 to December 2020. Patients were reconstructed with different nasolabial flap types.

Results

In total, 40 patients whose nasal defects were reconstructed with nasolabial flaps were included in this study. The most frequent lesion was basal-cell carcinoma (73.3%). The most frequent flap type was superiorly based flap (60.0%), followed by inferiorly based flap (23.3%), and freestyle perforator nasolabial island flap was the least frequent one (16.7). All patients (100.0%) reported good functional outcomes such as normal breathing and no airway obstruction. About half of the patients reported excellent outcomes (53.3%). Partial wound dehiscence in three (7.5%) patients and alar distortion in two (5%) patients.

Conclusion

V–Y-advancement flap and freestyle perforator-based flap may be preferred for sidewall-and dorsum-defect reconstruction. Two-stage interpolation type gives the best results for tip-region defects. Propeller and transposition (superior or inferior based) type flaps may be the choice for treatment in alar-region defects.

Keywords:

nasal reconstruction, nasolabial flap, perforator flap, propeller flap, V–Y flap

Egyptian J Surgery 40:1192–1204
© 2021 The Egyptian Journal of Surgery
1110-1121

Introduction

Nasal-wall defects can occur for many reasons. Common etiology includes neoplasm ablation, infection, trauma, and congenital malformation. The most common nonmelanoma skin cancer is basal-cell carcinoma, 80% occurring on the face, among which 25% involving the nose. Surgical excision with an adequate safety margin of around 0.5 cm to achieve a 95% cure rate is the main line of treatment, resulting in a defect that may require coverage if too large and primary closure is not feasible [1,2].

The nose plays a role in face identification by being in the center of the face. The central location and projection play a role in its esthetic importance and frequency of injury [3].

Nasal tissue may be divided into cover (skin, subcutaneous tissue, and muscle), framework

(cartilage and bones), and internal lining (vestibular skin and nasal mucosa). The key to a successful nasal reconstruction is a careful evaluation of the defect and nearby tissue status. The most critical aspects to investigate are the size, depth, and location of the defect [4].

Generally, small nasal-skin defects of less than 1.5 cm can be closed primarily or reconstructed with a local flap or full-thickness skin graft (FTSG). Medium defects of 1.5–2.5 cm can be reconstructed with a flap (regional or local tissue) or FTSG. When the defects are large, that is, more than 2.5 cm, a flap (regional tissue) or FTSG should be used [5,6].

This is an open access journal, and articles are distributed under the terms of the Creative Commons Attribution-NonCommercial-ShareAlike 4.0 License, which allows others to remix, tweak, and build upon the work non-commercially, as long as appropriate credit is given and the new creations are licensed under the identical terms.

The nasal wall is divided into nine subunits from the esthetic point of view, according to Burget and Menick [7].

Nasal reconstruction is a challenging plastic surgery. It is the most prominent and esthetic feature of the face [8].

Local skin flaps provide an excellent choice for coverage of nasal-skin defects with good texture, color match, and success rate. It has the additional advantage of well-vascularized tissue coverage for the nasal skeleton resisting contracture and infection. The reconstructive option varies according to the defect site, defect size, skin laxity, tissue availability, age of patient, and general condition. Flap selection is individualized based on the previous mentioned factors as no single flap can be considered universal for the nasal defect [9].

The nasolabial flap is ideal for nose reconstruction. Easy harboring and ability to operate under local anesthesia with relative minimal scar make it the most used flap in reconstruction of nasal defects. Nasolabial flaps have various modifications to achieve the best result [10].

Nasolabial flaps can be classified into:

- (1) Interpolation flap-2 stage is lifted over the area of normal skin.
- (2) Superiorly based nasolabial flap.
- (3) Inferiorly based nasolabial flap.
- (4) Nasolabial island flaps:
 - (a) V-Y-advancement flap.
 - (b) Freestyle perforator-based nasolabial flap.
 - (c) Nasolabial propeller flap [7].

Figures 1 and 2.

Anatomy of the vascular supply

The angular artery and its perforating branches supply the paranasal cheek area medially. The perforating branches of the internal maxillary artery, as well as extensions of the transverse facial branch of the superficial temporal artery, supply the central cheek. The nasolabial flap can be lifted as an axial-pattern flap or as a random-pattern flap. The subdermal vascular plexus and dermal plexus, which are ultimately fed by musculocutaneous arteries, provide circulatory supply to random flaps. As a result, the appropriate dissection plane is subcutaneous fat [12].

The three varieties of branching patterns of the facial artery, according to the Nakajima categorization system, are:

Figure 1

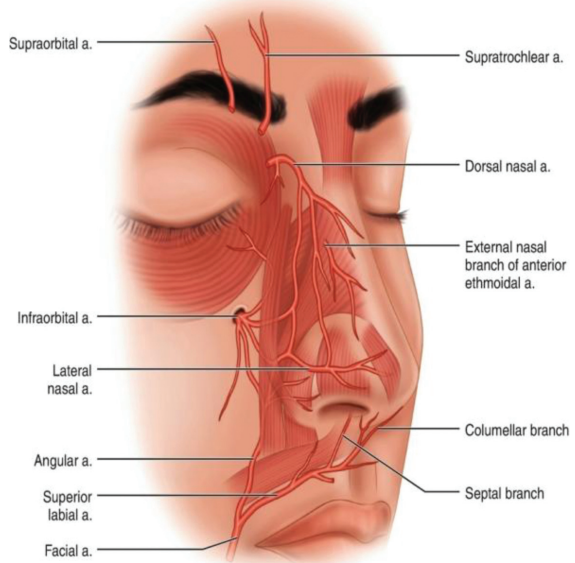
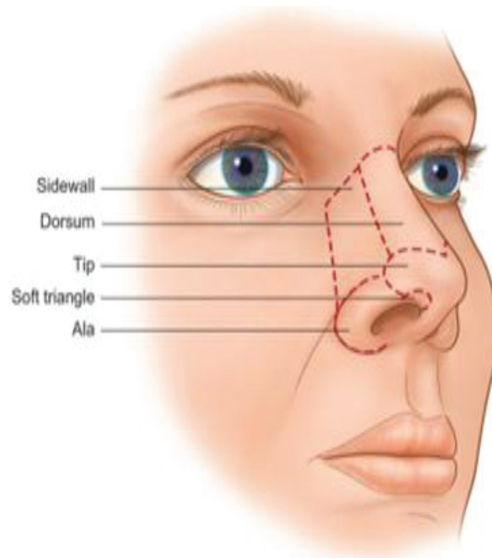


Diagram showing arterial supply of external nose [11].

Figure 2



Nasal subunits [2].

- (1) Type A (in which the facial artery bifurcates into the lateral, nasal, and superior labial arteries at the angle of the mouth), the most common (77.8%).
- (2) Type B (in which the facial artery branches off into the superior labial artery and lateral nasal arteries to finish as the angular artery).
- (3) Type C (in which the facial artery terminates as the angular artery, but the lateral nasal artery branches off from the superior labial artery).

Cutaneous perforators were usually located over three zones (zones 1-3), as illustrated in Fig. 3. Zone 2 was

Figure 3

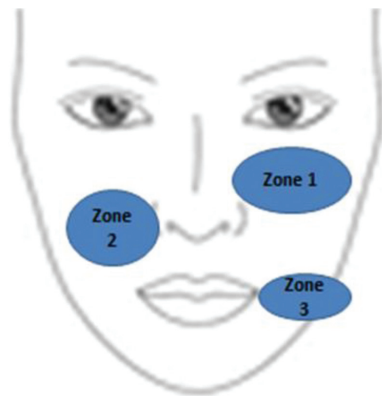


Diagram showing zones of perforators of the facial artery [13].

the most common location of the perforators, particularly at 3 mm inferior to the nasal alar base and 25 mm above this point. The perforator lengths varied from 3 to 6 mm, and the diameters varied from 1 to 1.5 mm, so only the perforators on that particular zone region are useful for designing the nasolabial propeller perforator flap [13].

Restoring nasal contour and support:

A complete cartilage and bone framework must extend from the nasal bone above to the base of the columella inferiorly and from one alar base and sidewall to the other horizontally [14].

Restoring nasal lining

It is important to regain nasal lining as if a raw area heals secondarily, the external shape of the nose becomes distorted by scar, and the airway becomes contracted [15].

The aim of the study is to evaluate the outcome and complications of the different modalities of nasolabial flaps in nasal reconstruction.

Patients and methods

This prospective, clinical study included 40 patients presented with nasal lesions requiring management of the resulting defects, admitted to Benha University Hospital in the period from December 2018 to December 2020. Following approval from the Benha Faculty of Medicine's Research Ethics Committee and fully informed written consent from all patients regarding surgical procedure in this research, absolute confidentiality with regard to the patients' names and addresses was given special care and attention, photographing, and follow-up period.

Inclusion criteria

All patients presented with different nasal lesions.

- (1) Age: any age.
- (2) Sex: males and females.
- (3) Cooperative, fit for surgery.

Exclusion criteria

- (1) Patient with large defects more than one subunit.
- (2) Smoking.
- (3) Patients with post-burn nasal defects.
- (4) Severe chronic illness such as chronic renal failure, chronic liver disease, etc.
- (5) Mentally or psychologically disordered patients.

All patients were subjected to a detailed thorough history taking, clinical examination, investigations, operative procedure, and postoperative assessment and follow-up.

Nasal lesions were specified regarding the site, size, depth of defects, and the previous medical or surgical treatment.

- (1) Local examination:
 - (a) Type of nasal lesion.
 - (b) Anatomical site of defect in the nose.
 - (c) Size of the lesion.
 - (d) Thickness and involvement of lining mucosa.
 - (e) Examination of regional lymph node.

Investigation

Routine

Complete blood count, random blood sugar, coagulation profile, and kidney-function and liver-function tests.

Local

Incisional biopsy and histopathological examination to detect the nature of the lesion.

- (1) All patients were operated on by the same surgeons.
- (2) Oral broad-spectrum antibiotic was started one day before surgery.
- (3) Preoperative marking.
- (4) Intraoperative analysis of nasal defects:
 - (a) Anatomical site of the defect in nose, involvement of esthetic unit.
 - (b) Size of the defect.
 - (c) Depth of the defect (skin only or skin and cartilage or full-thickness defect).

Operative technique

General anesthesia or local anesthesia with intravenous sedation according to the patient's general condition.

Supine position, head at 20–30° with the head in the midline or turned to the opposite side.

The tumors were resected with 4–5-mm lateral safety margins in basal-cell carcinoma, 10 mm in squamous-cell carcinoma.

Flap design

- (1) A foil-pattern template of the defect was used for the flap design.
- (2) Injection with 1 : 200 000 epinephrines for hemostatic control and to aid in flap dissection.
- (3) The flaps were designed according to the nasal-defect pattern.
- (4) In some alar defects, the normal nasal tissue between the defects and the flap is removed in one-stage nasal reconstruction.

The nasolabial fold was marked preoperatively on all patients. A template was positioned immediately adjacent to the nasolabial fold, ensuring an appropriate arc of rotation from the donor to the recipient site. A distal dog-ear excision was outlined.

The flap was elevated sharply to the level of the mid-cheek and dissected bluntly with care to the base of the flap. The flap was advanced onto the nose, carrying the distal extension to cover the defect. Hemostasis was done with electrocautery.

The flap was then contoured and shaped to be smaller than the defect. This allows the flap to be inset under a degree of tension. This is the most important step when using the nasolabial flap for nasal-tip reconstruction.

The flap was fixed with sutures to the recipient site, taking care to ensure wound-edge closure with eversion. To minimize prominent donor-site scarring, the flap design was never extended above the level of the alar lobule.

The flap donor sites were closed carefully with multiple layers of deep dermal suture followed by skin sutures over subcutaneous drain, and then dressing was done.

In superiorly based flap

The flap was designed, so that the lower end of the flap narrows down to a point, to allow for the closure of the

donor site with the least amount of undermining. The flap is elevated from the distal tip toward the base by first making an incision deep into the dermis along the marked width of the flap.

The flap is elevated in a plane superficial to the muscles. Care should be taken to avoid injury of the branches of the facial artery as they penetrate the muscle on their way to perfuse the overlying skin. The surrounding area is undermined to improve the rotation of the flap without causing distortion of the tissues around the base of the flap.

The inferiorly based flap

The medial edge of the flap was constructed to run in the nasolabial fold and widen laterally to accommodate the desired breadth. The flap design is superiorly incised, and the incision is then carried deep into the dermis. Depending on the superior extent and depth of the flap, the terminal branches of the facial artery as it becomes the angular artery may be encountered.

Nasolabial freestyle perforator flap

A handheld Doppler was used to localize the vessel in the nasolabial region. The defect was marked, measured, and the flap size planned. To look for perforators, the incision and flap dissection were usually started from the medial side. After identifying the perforator, the flap was incised circumferentially, and the vein, which usually lies laterally, was identified. The perforators were freed from the surrounding tissue by further blunt dissection, so that torsion and kinking may be avoided. The flap was then transposed, advanced, or tunneled to be inserted into the defect. The donor defect was closed primarily and the scar hidden in the nasolabial sulcus.

Interpolation flap

The difference between interpolation and transposition flaps is that the interpolation flap is lifted over a normal skin area to reach the defect. The recipient location is not precisely near to the flap's base. A tissue bridge, or pedicle, forms between the flap base and the defect as a result of this arrangement. When the neighboring skin has no mobility, an interpolation flap is a two-stage surgery. The bridge must be disconnected in a second stage when the new vascular supply is established (usually after 3 weeks). This method is very suitable for nasal tip or columella reconstruction, often in combination with cartilaginous grafts, mucosal flaps, or skin grafts.

Advancement-flap V-Y flap

Advancement flap from the nasolabial fold in a V-Y fashion is well suited for reconstructing the area where the lower or middle third of the nose meets the cheek.

V-Y flap usually slid into the defect on a subcutaneous pedicle [7,16].

Nasolabial propeller flap

A handheld Doppler was used to locate the skin perforator and the flap island was designed in an eccentric manner over the perforator.

Dissection started over the anterior border of the flap, located in the nasolabial fold, in order to hide the donor scar. The perforator was chosen, and 1–2 mm of surrounding subcutaneous adipose tissue was left intact to minimize the risk of iatrogenic injury and vasospasm. Finally, the flap was rotated 180°, to reach the defect.

- (1) Cartilage harvested from ear concha in 14 patients.
- (2) Mucosa reconstructed in six patients by undermining of the adjacent nasal mucosa.

Postoperative care and follow-up

Patients were managed in the General Surgery Department, cases discharged from the hospital at the same day of operation or one day after surgery. Further evaluation of postoperative outcome was performed in the outpatient clinic. All patients received antibiotics for 7 days, anti-edematous drugs, and analgesics.

- (1) All patients were advised to avoid trauma to flap.
- (2) Flap viability was checked (color – temperature) 6, 12, and then 24 h postoperative.
- (3) Postoperative wound care, cleaning with saline, and antibiotic ointment twice daily for a week.
- (4) Sutures were removed 7–10 days postoperative.

The results were assessed by clinical examination and postoperative photographs weekly for the first month and monthly for the next 3 months.

The postoperative outcome was evaluated according to the esthetic appearance of the flap reconstruction, patient satisfaction regarding overall improvement, and complications of the procedure.

Patients were asked to assess their level of satisfaction on a scale from 1 to 4. Poor results were given 1°, fair were given 2°, good 3°, and excellent were given 4°.

Results

This study was done in Benha University Hospital on 40 patients with different nasal defects after evaluating the site, size, and depth of the defects, reconstruction was done by nasolabial flaps. The flaps were designed according to the measured nasal defects.

- (1) The mean age of the study participants was 57 years, with a SD of 10 years. Regarding sex, 57.5% were males, while 42.5% were female (Table 1).
- (2) Diabetes and hypertension were present in 35 and 20% of patients, respectively (Table 2).
- (3) The most frequent lesion was basal-cell carcinoma (67.5%), followed by squamous-cell carcinoma (25%). Traumatic lesions were present in only 7.5% of patients (Table 3 and Fig. 4).
- (4) The most frequent lesion site was ala (50%), followed by sidewall (30%). Lesions were present in tip only (20%) of patients (Table 4 and Fig. 5).
- (5) More than two-thirds of patients had lesions sized less than 2 cm. Lesions sized more than 2 cm represented 26.7% of the studied patients. Regarding the depth of lesions, most of the lesions were skin only (53.3%), while 26.7% were skin+cartilage, and 20.0% were full-thickness lesions (Table 5 and Fig. 6).
- (6) Regarding early complications.
 - (a) Partial distal flap necrosis in two (5%) cases of the superiorly based flap requiring excision and healed by secondary intention.

Table 1 Demographic characteristics of the studied patients

Demographics	
Age (years)	
Mean±SD	57±10
Sex [n (%)]	
Males	23 (57.5)
Females	17 (42.5)

Table 2 Comorbidities in the studied patient

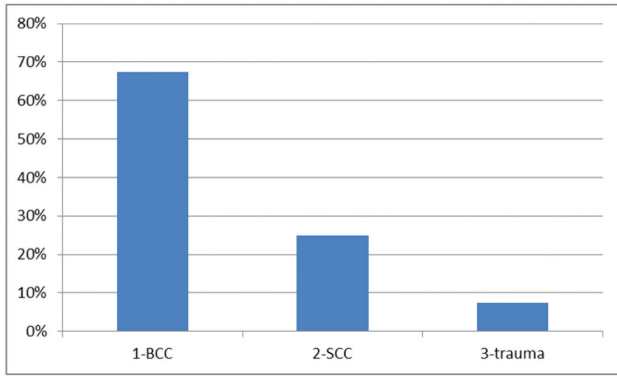
	n (%)
Diabetes	14 (35)
Hypertension	8 (20)

Table 3 Types of lesions in the studied patients

	n (%)
Type of lesion	
BCC	27 (67.5)
SCC	10 (25)
Trauma	3 (7.5)

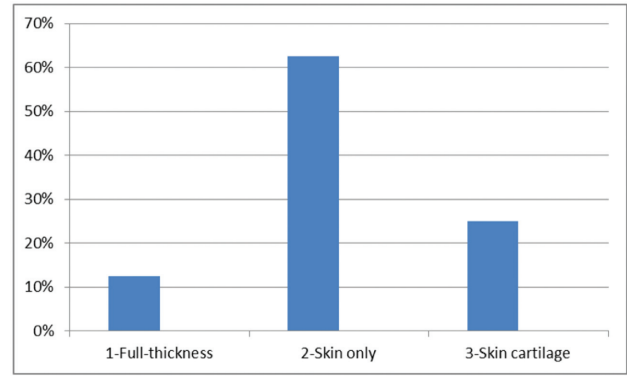
BCC, basal-cell carcinoma; SCC, squamous-cell carcinoma.

Figure 4



Types of lesions in the studied patients.

Figure 6

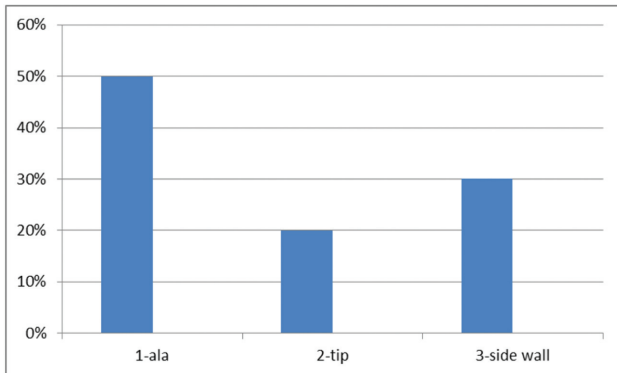


Depth of lesions in the studied patients.

Table 4 Site of lesions in the studied patients

Site of lesion	n (%)
Ala	20 (50)
Tip	8 (20)
Sidewall	12 (30)

Figure 5



Site of lesions in the studied patients.

Table 5 Size and depth of lesions in the studied patients

	n (%)
Size (cm)	
≤2	28 (70)
≥2	12 (30)
Depth of defect	
Full thickness	65 (12.5)
Skin only	25 (62.5)
Skin and cartilage	10 (25)

(b) Partial wound dehiscence in three (7.5%) cases healed by secondary intention.

(7) Regarding late complications (Table 6):

(a) Alar distortion in two (5%) cases and the patient refused any further interference.

Table 6 Donor-site and recipient-site morbidity in the studied patients

	Early [n (%)]	Late [n (%)]
Donor-site morbidity		Hypertrophic scar 5 (12.5)
Recipient-site morbidity	Partial distal-flap necrosis 2 (5)	Alar distortion 2 (5)
	Partial wound dehiscence 3 (7.5)	Tip deformity 1 (2.5)
		Trap-door scar 4 (10)

(b) Tip deformity in one (2.5%) patient.

(c) Trap-door scar in four (10%) patients managed by multiple Z plasty after 6 months.

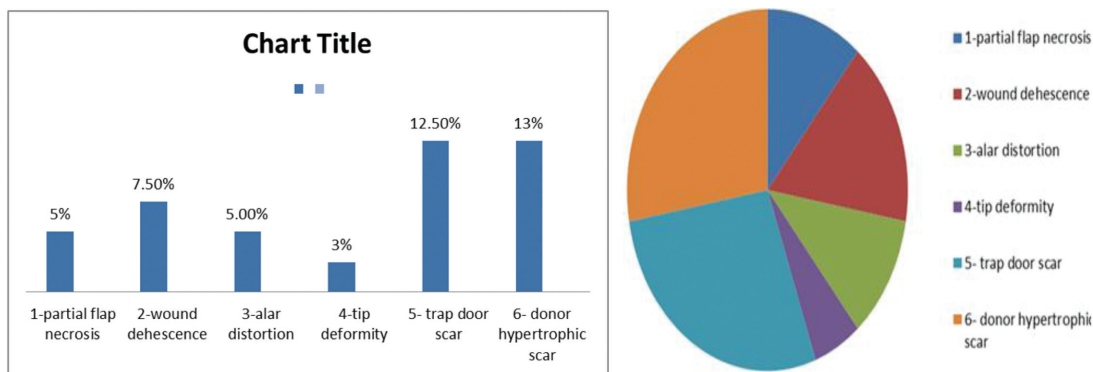
(d) Donor-site hypertrophic scar in five (12.5%) patients managed medically (Fig. 7).

(8) All patients (100.0%) reported good functional outcomes such as normal breathing and no airway obstruction.

(9) Esthetic outcomes were judged by the final postoperative photographs by a panel of three plastic surgeons. The results were judged as excellent, good, fair, and poor. The result was judged as excellent when the review showed no asymmetry, good shape, and invisible scars. A good result shows minimal asymmetry or minimal visibility of scar in a photograph. Fair results show equivocal judgment on symmetry, scars, and shape. A poor result shows asymmetry or complicated scars. About half of the patients reported excellent outcomes (53.3%), 36.7% reported good outcomes, and 10.0% reported poor outcomes (Table 7 and Fig. 8).

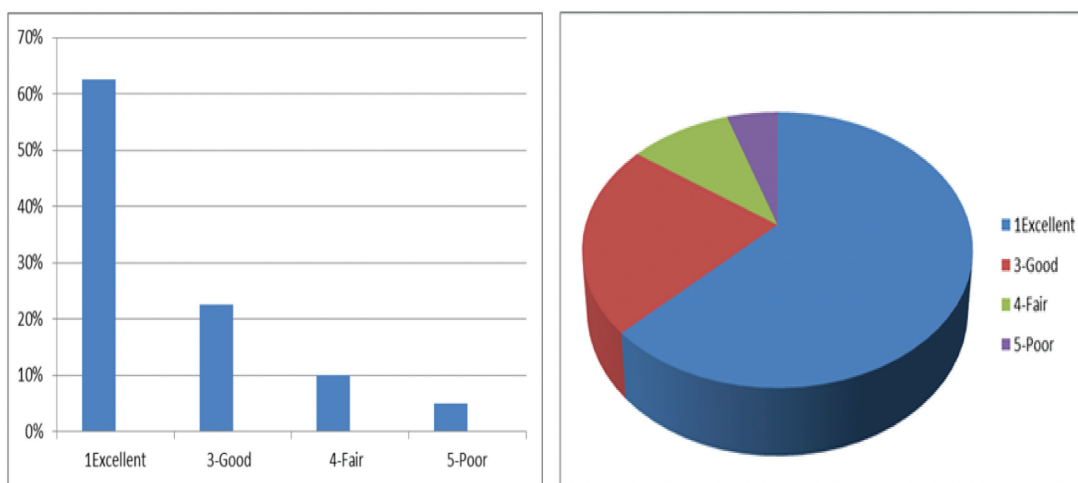
The most frequent flap type was superiorly based flap (60.0%), followed by inferiorly based flap (23.3%), and freestyle perforator nasolabial island flap was the least frequent one (16.7) (Table 8 and Fig. 9).

Figure 7



Donor-site and recipient-site morbidity in the studied patients.

Figure 8



Esthetic outcomes in the studied patients.

Table 7 Esthetic outcomes in the studied patients

Esthetic outcome	n (%)
Excellent	25 (62.5)
Good	9 (22.5)
Fair	4 (10)
Poor	2 (5)

Table 8 Types of flaps in the studied patients

Type of flap	n (%)
Superiorly based flap	14 (35)
Inferiorly based flap	6 (15)
Freestyle perforator-based flap	4 (10)
V-Y flap	6 (15)
Propeller-based flap	6 (15)
Interpolated 2-staged flap	4 (10)

Statistical methods

Data management and statistical analysis were done using SPSS vs.2. (IBM, Armonk, New York, USA).

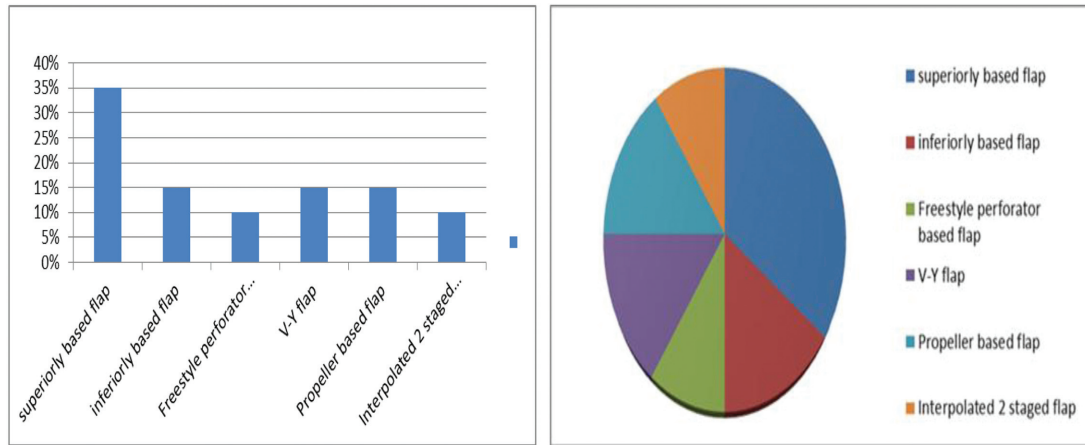
Numerical data were summarized as means and SDs. Categorical data were summarized as numbers and percentages (Figs 10–20).

Discussion

The most common causes of nasal defect include tumor resection, burns, and trauma. Tumor excision is the usual cause of the nasal defect presenting for reconstruction. Nasal reconstruction is not an easy job in the field of plastic surgery, although the nasolabial flap cannot cover or repair severe nasal defects, but it has a great role in mild-to-moderate nasal-defect reconstruction [17].

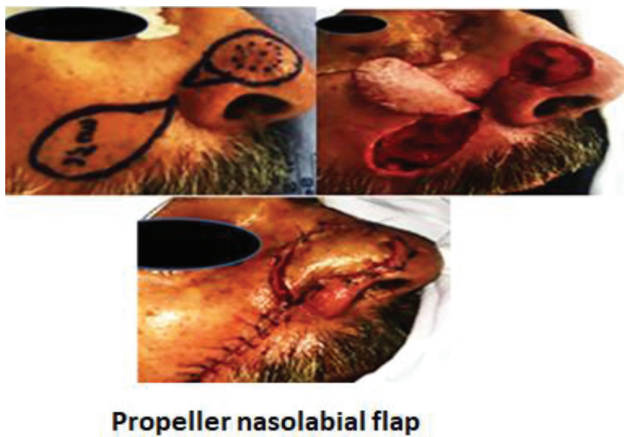
Nasal reconstruction after excision of a neoplasm is a challenging target due to its complex three-dimensional structure, and it is critical to consider esthetic subunits of the nose when planning the reconstruction [18].

Figure 9



Types of flaps in the studied patients.

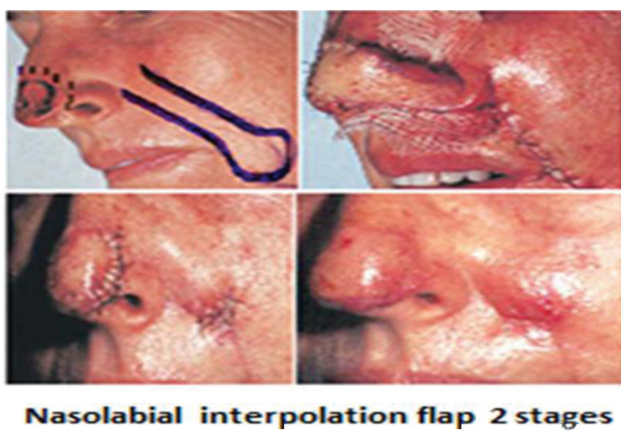Figure 10



Propeller nasolabial flap

Propeller nasolabial flap.

Figure 11



Nasolabial interpolation flap 2 stages

Interpolation nasolabial flap 2 stages.

Figure 12

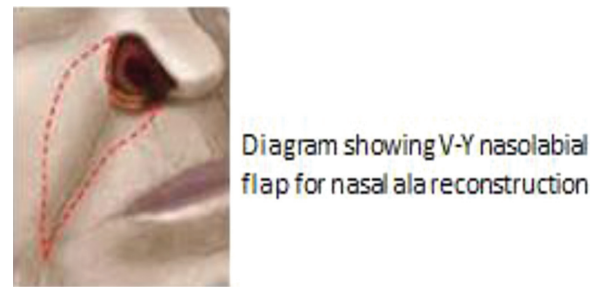
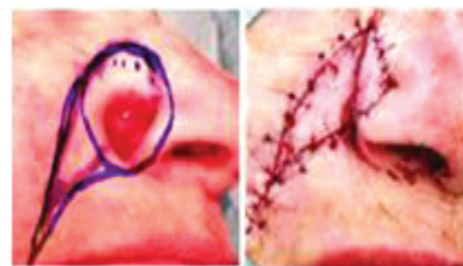
Diagram showing V-Y nasolabial flap for nasal ala reconstruction



V-Y nasolabial flap

V-Y-advancement nasolabial flap.

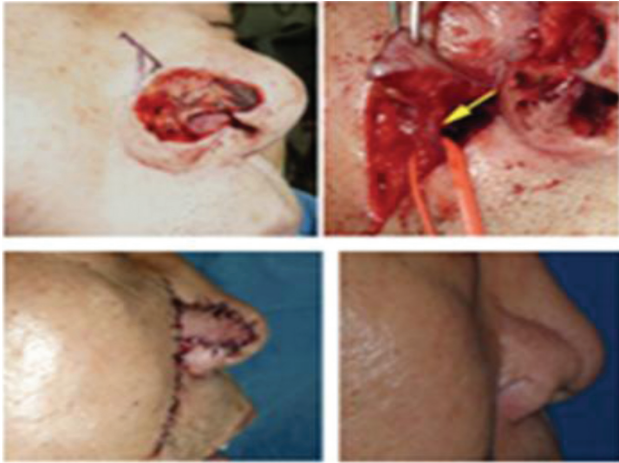guided by the topographical characteristics of each subunit [7]. This was the first time the subunit principle was applied to nasal reconstruction, and it played an important role in the preoperative plan.

Nonetheless, several researchers reformed the approach [19]. They advised that nasal repair should focus on the defect itself instead of the whole subunit. Native tissue should be conserved as much as possible.

Reconstructive technique or a combination of them must be selected according to the size and location of the defect and tissue availability. Anatomical

The nose is traditionally divided into nine esthetic subunits. The reconstructive procedures should be

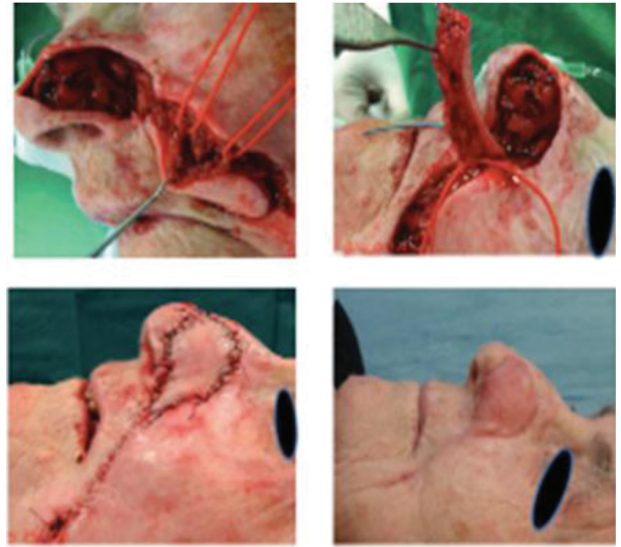
Figure 13



Freestyle perforator based nasolabial flap for nasal ala reconstruction (full thickness)

Freestyle perforator-based nasolabial flap.

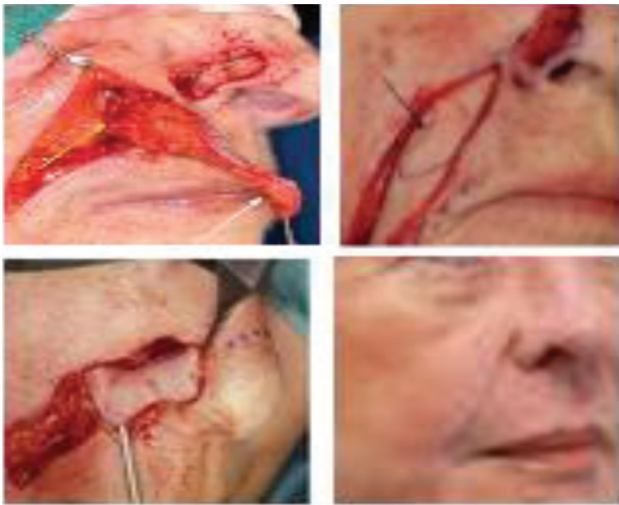Figure 15



Propeller nasolabial flap

Propeller nasolabial flap.

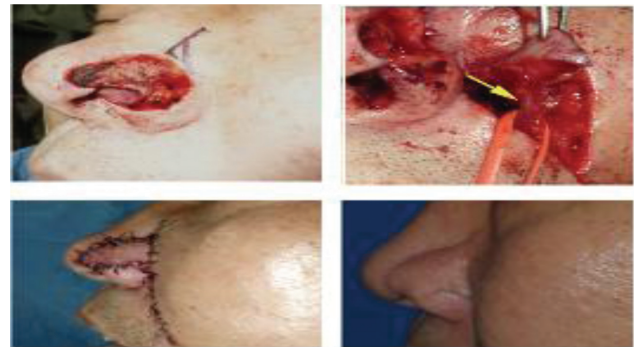Figure 14



Complete subunit excision and reconstruction with perforator based flap

Propeller nasolabial flap.

Figure 16



Complete full thickness reconstruction

Full-thickness nasal-wall reconstruction.

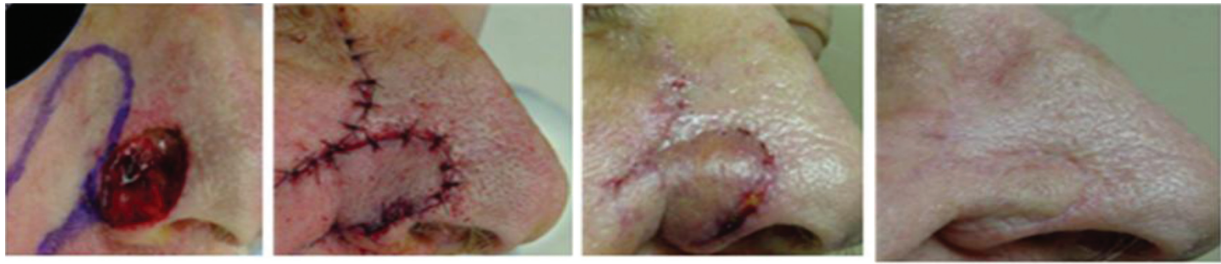restoration must be completed as possible, trying to restore the nasal lining, osteocartilaginous framework, and skin cover [20].

The desired outcomes cannot be achieved by skin grafting, but local flaps are required for reconstructing defects of the nose, such as the forehead flap and nasolabial flap [21].

Weathers *et al.* [22] declared that the nasolabial flap is one of the most commonly used reconstructive options for nasal defects.

The proximity of the nasolabial region, having a good blood supply and a hidden donor scar, are the key advantages of nasolabial flaps. The perforators of the angular branch of facial artery nourish the nasolabial region and give many flap options for nasal reconstruction. However, the limitations of the flap use include the limited size, width, and the limited arc of rotation. This restricts its use for small- and medium-sized defects. A hypothesis supported by El-marakby [23] experience.

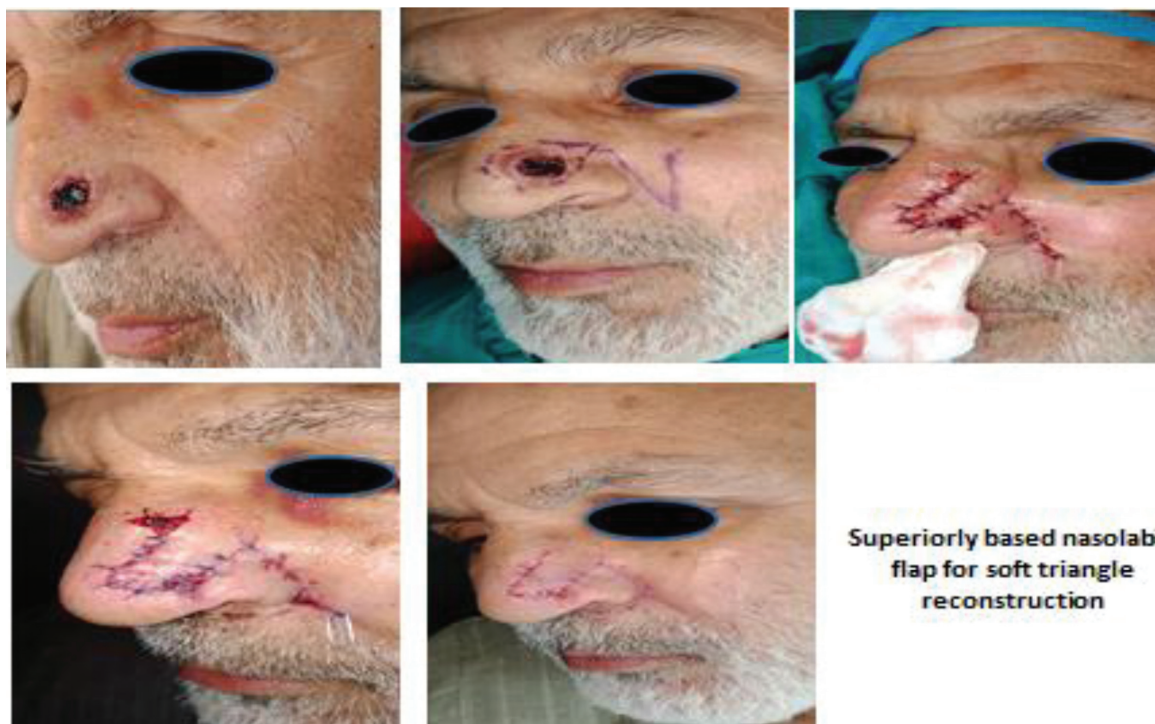Figure 17



Inferiorly based nasolabial flap for nasal ala reconstruction

Inferior-based pedicled nasolabial flap.

Figure 18



Superiorly based nasolabial flap for soft triangle reconstruction

Superior-based pedicled nasolabial flap.

This flap can be used unilaterally or bilaterally in the form of superiorly, inferiorly, or centrally based pedicle flap [22].

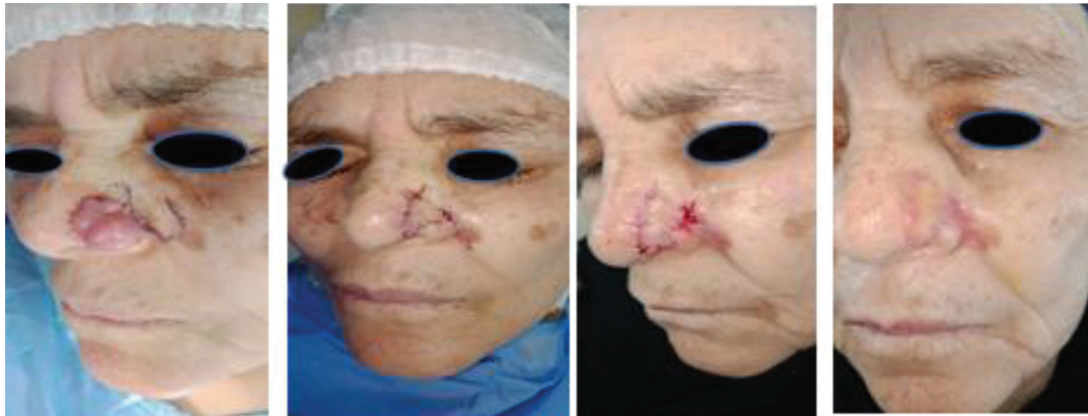In the superiorly based nasolabial flap, the base of the flap is near the ala and the apex is in line with the oral commissure [24].

Sometimes, when an extra length is needed, it can be extended to the skin over the mandibular border. This variant of the superiorly based nasolabial flap is called the extended nasolabial flap. In the inferiorly based nasolabial flap, the apex of the flap is about 5–7 mm lateral to the medial canthus [25].

Most of the nasolabial flaps are random pattern, but can be planned to have an axial-pattern blood supply from the inferiorly based axial nasolabial flap that is nourished by facial artery and the superiorly based reverse-flow nasolabial flap containing angular artery [26].

In this study, we repaired the ala by using a nasolabial flap as a single-stage procedure, but this flap can be used in many ways. In his case report, Fujiwara [27] used this flap as a bilobed nasolabial flap, whereas Spear *et al.* [28] twisted the nasolabial flap to repair ala. In our study, we used it as a single-stage procedure superiorly, inferiorly based, or perforator-based flap. In the current

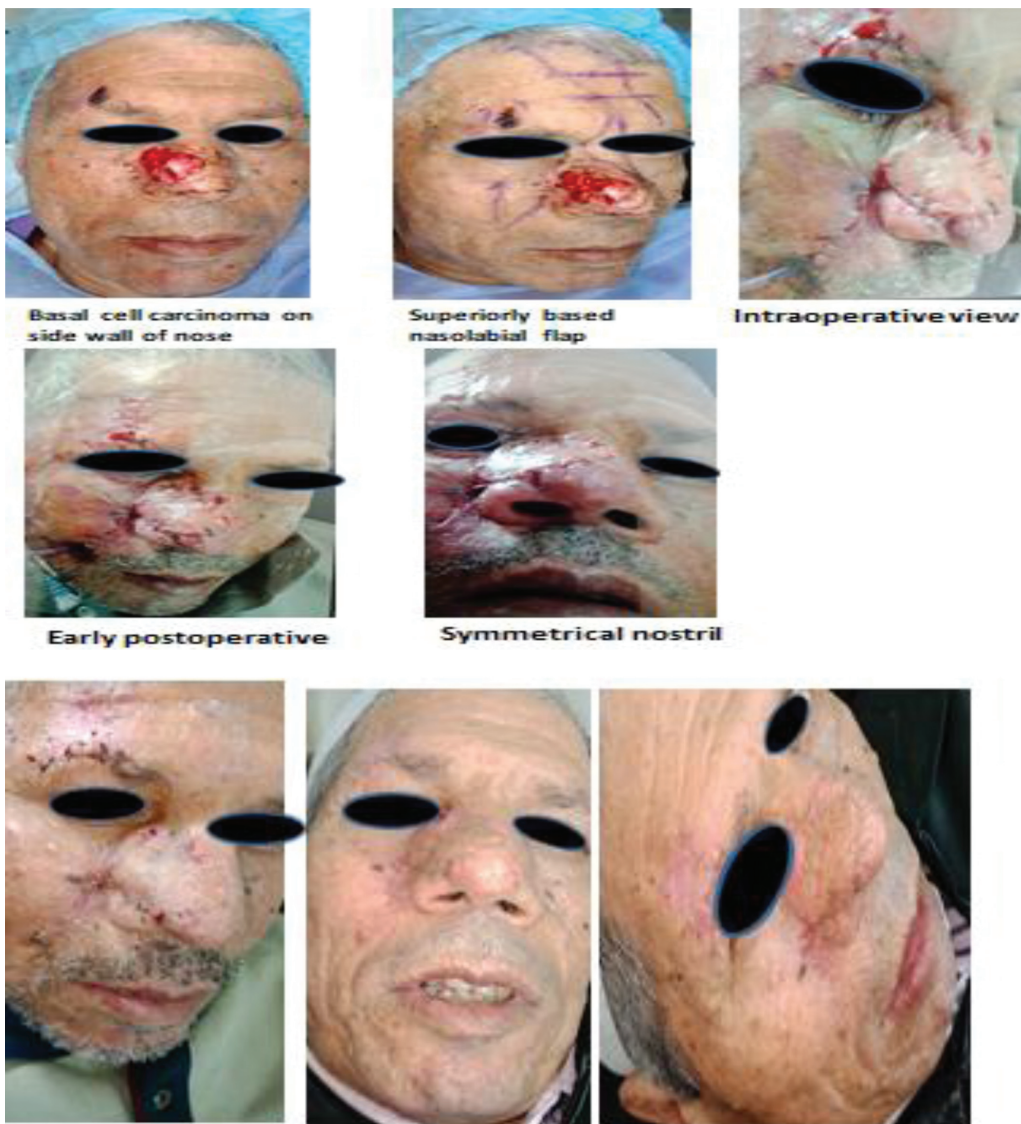Figure 19



Superiorly based nasolabial flap for nasal ala reconstruction flap

Superior-based pedicled nasolabial flap.

Figure 20



Basal cell carcinoma on side wall of nose

Superiorly based nasolabial flap

Intraoperative view

Early postoperative

Symmetrical nostril

Late postoperative views

Superior-based pedicled nasolabial flap.

study, most of the nasolabial flaps were raised under local anesthesia, with a short procedure time (26–46 min), a result that matches El-Marakby [23] experience.

In our study, we encountered two patients suffering from partial flap necrosis, three patients had partial wound dehiscence, and five patients had hypertrophic scar out of 40 cases. In a study conducted by Silistreli *et al.* [29], one patient suffered partial nasolabial flap necrosis and two had a hypertrophic scar in a total of 10 cases. However, the study of Burget [30] and Hassan [31] revealed almost no complications with this flap.

In Javaid *et al.* [32] study, they reported the outcome of nasolabial flap in reconstruction of nasal alar defects. Although they achieved good results with the flap, alar distortion occurred in 5.71% of patients and flap-tip deformity in 2.86% of patients. In the present study, these complications represent 5 and 2.5% of the cases, respectively. In this study, the color match was good in all cases of nasolabial flap. The donor site healed well with no functional morbidity. This is similar to the results obtained by Irfanullah *et al.* [33].

In this study, there was no need for a second-stage procedure, except in the cases of interpolated flaps. In El-Marakby [23], one of the few side effects of flap use is the loss of the nasal cheek junction as a result of recruiting such area in the nasolabial flap design, as well as donor-site morbidity (dog ear). However, in our study, donor-site late morbidity in the form of hypertrophic scar had occurred.

In this study and of Bilal *et al.* [34], no venous congestion was observed postoperatively, and this is not comparable to Hassan [31] experience in which superiorly based flap is more liable for developing pin cushioning and edema than inferiorly based because flap-design lymphatic and venous drainage are more liable for congestion, and this congestion is more if the patient is wearing eye glasses as it may aggravate flap edema.

Massoud [35] reported a 50% rate of revision surgery to reduce the bulk of the ala and to seat the alar side wall in a more medial location. This fact was also noted in the current study, Massoud [35].

Cartilage grafts support the nose and its airway, shape its external appearance, and brace the repair against gravity, tension, and wound contraction. In our experience and that of Kim *et al.* [36], conchal cartilage was the workhorse of ala reconstruction.

Septal cartilage can provide ULC. However, according to the work of Iwao [37], where he noted that a cartilage graft produced less support to the alar rim than a folded nasolabial flap.

We achieved a good contour and color match in our patients with no major complications. Donor-site scar is not evident, since the scar rests in the nasolabial sulcus. The operation time, short hospital stay, compatibility of the tissue color, donor-site scar location, patient comfort, secondary procedures, and cost-effectiveness are reasons to prefer this technique over other flap techniques.

Regarding the choice of the type of flap in the present study, we found that V–Y-type advancement flaps and freestyle perforator-based flap type should be preferred for sidewalls and dorsum defects, respectively. Two-stage interpolation type gives the best results for tip-region defects. Propeller-type and transposition-type flaps (superiorly or inferiorly based) should be the choice of treatment in alar-region defects and this matched the result done by Aksam *et al.* [38] on 142 patients.

Conclusions

From this study, we concluded that the nasolabial flap is a reliable flap for the soft-tissue coverage of nasal defects. The flap can be manipulated according to the depth of the defect and it possesses an excellent texture and color. Also, a well-vascularized flap along the whole length of the nasolabial fold, in combination with the wide arc of rotation and the proximity to the recipient defects. The flap donor site lies in the same operating field and can be closed primarily. The least donor-site morbidity and a hidden scar have made it the preferred choice for nasal reconstruction.

Financial support and sponsorship

Nil.

Conflicts of interest

There are no conflicts of interest.

References

- 1 Spira M, Netsher DT. Basal cell carcinoma: an overview of tumor biology and treatment. *Plast Reconstr Surg* 2004; 113:70–94.
- 2 Zitelli JA, Wolf DJ. Surgical margins for basal cell carcinoma. *Arch Dermatol* 1987; 123:340–344.
- 3 Langford FPJ. Nasal reconstruction following soft tissue resection (on line article). 2004. Available at: <http://www.emedicine.com/ent/TOPI6555HTM>. [Accessed April 10, 2010].
- 4 Weber SM, Baker SR. Management of cutaneous nasal defects. *Facial Plast Surg Clin N Am* 2009; 17:395–417.

- 5 Moolenburgh S, McLennan L, Levendag PC, Munte K, Scholtemeijer M, Hofer SOP, Mureau MAM. Nasal reconstruction after malignant tumor resection: an algorithm for treatment. *Plast Reconstr Surg* 2010; 126:97–105.
- 6 Yong JS, Christophel JJ, Park SS. Repair of intermediate-size nasal defects. *JAMA Otolaryngol Neck Surg* 2014; 140:1027–1033.
- 7 Burget GC, Menick FJ. The subunit principle in nasal reconstruction. *Plast Reconstr Surg* 1985; 76:239–247.
- 8 Sing DJ, Bartlett SP. Aesthetic considerations in nasal reconstruction and the role of modified nasal subunits. *Plast Reconstr* 2003; 111:639–648.
- 9 Fazio MJ, Zitelli JA. Reconstruction of the nose with local flaps. *J Dermatol Surg Oncol* 1991; 17:184–189.
- 10 Langford FPJ. Nasal reconstruction following soft tissue resection (on line article). 2004. Available at: www.emedicine.com/ent/TOPI655HTM. [Accessed April 10, 2010].
- 11 Niekraash CE. Anatomy of the nose and paranasal sinuses. January 2021, in book: *Applied Head and Neck Anatomy for the Facial Cosmetic Surgeon* (pp.79–84). DOI: 10.1007/978-3-030-57931-9_9.
- 12 Asano T, Shiota N, Ohtsuka H. Clinical experience with nasolabial flaps. *Ann Plast Surg* 1981; 6:207–212.
- 13 Nakajima H, Aiso S, Imanishi N. Facial artery in the upper lip and nose: anatomy and a clinical application. *Plast Reconstr Surg* 2002; 109:862–863.
- 14 Menick FJ. Nasal reconstruction. *CME Plast Reconstr Surg* 2010; 125:138e–150e.
- 15 Menick FJ. The modified folded forehead flap for nasal lining – the Menick method. *J Surg Oncol* 2006; 94:509–514.
- 16 Menick FJ. *Nasal reconstruction* head and neck. Neligan P. *Plastic surgery*. 3rd ed. London, New York: Elsevier Publisher 3:2013; 125–180.
- 17 Lee RG, Baskin Z. Improving outcomes of locoregional flaps: an emphasis on anatomy and basic science. *Curr Opin Otolaryngol Head Neck Surg* 2006; 14:260–264.
- 18 Arora A, Attwood J. Common skin cancers and their precursors. *Surg Clin North Am* 2009; 89:703–712.
- 19 Rohrich RJ, Griffin JR, Ansari M, Beran SJ, Potter J. Nasal reconstruction—beyond aesthetic subunits: a 15-year review of 1334 cases. *Plast Reconstr Surg* 2004; 114:1405–1416.
- 20 Ahmad M, Hussain S, Malik S. Reconstructive rhinoplasty. *J Surg Pak* 2008; 13:79–81.
- 21 Chu EA, Byrne PJ. Local flaps I: bilobed, rhombic, and cervicofacial. *Facial Plast Surg Clin North Am* 2009; 17:349–360.
- 22 Weathers WM, Wolfswinkel M, Nguyen H, Thornton JF. Expanded uses for the nasolabial flap. *Semin Plast Surg* 2013; 27:104–109.
- 23 El-Marakby HH. The versatile naso-labial flaps in facial reconstruction. *J Egypt Natl Cancer Inst* 2005; 17:245–250.
- 24 Field LM. Design concepts for the nasolabial flap. *Plast Reconstr Surg* 1983; 71:283–285.
- 25 Ducic Y, Burye M. Nasolabial flap reconstruction of oral cavity defects: a report of 18 cases. *J Oral Maxillofac Surg* 2000; 58:1104–1110.
- 26 Hynes JB, Boyd B. The nasolabial flap. Axial or random? *Arch Otolaryngol Head Neck Surg* 1988; 114:1389–1391.
- 27 Fujiwara M. One-stage reconstruction of an alar defect using bilobed nasolabial-nasal tip flap based on the aesthetic subunits in orientals; case report. *Aesthetic Plast Surg* 2004; 28: 13–16.
- 28 Spear SL, Kroll SS, Romon S. A new twist to the nasolabial flap for reconstruction of lateral alar defects. *Plast Reconstr Surg* 1987; 79:915–920.
- 29 Silistreli OK, Demirdover C, Ayhan N. Prefabricated nasolabial flap for reconstruction of full thickness distal nasal defects. *Dermatol Surg* 2005; 31:546–550.
- 30 Burget GC. Aesthetic reconstruction of the nose. In: Maths SJ, editors. *Plastic surgery*. 2nd ed Philadelphia: Elsevier 2006. 2:573–648.
- 31 Hassan J. 2016 reconstruction of the nasal defects by nasolabial flaps. *J US-China Med Sci* 2016; 13:64–79.
- 32 javaid M, Ahmad A, Khan Q, Wahid F, Afridi HR. Outcome of nasolabial flap in reconstruction of the nasal alar defect. *J Med Sci* 2011; 19:163–166.
- 33 Irfanullah XX, Khan A, Khan N, Shah SA, Tahmeedullah XX. Indications and outcome of nasolabial flap: experience at a plastic surgical facility. *Ann Pak Inst Med Sci* 2012; 8:168–171.
- 34 Bilal M, Ullah I, Ehsanullah XX. Nasolabial flap: a workhorse for the reconstruction of nasal ala after tumor resection. *JKCD* 2014; 5:1.
- 35 Massoud SK. Reconstruction of full-thickness alar defect by the turnover nasolabial flap: improving the outcome by primary flap thinning and unilateral alar base suturing. *Egypt J Plast Reconstr Surg* 2009; 33:15–19.
- 36 Kim JH, Song JW, Park SW, Oh WS, Lee JH. 10th rib cartilage: another option of the costal cartilage graft for rhinoplasty. *Arch Aesthetic Plast Surg* 2015; 21:4753.
- 37 Iwao F. Alar reconstruction with subcutaneous pedicled nasolabial flap; difficulties, consideration, and conclusion for this purpose. *Dermatol Surg* 2005; 31:1351–1354.
- 38 Aksam E, Aksam B, Karaaslan O, Durgun M. Nasolabial flaps for nasal reconstruction: pros and cons. *Turk J Plast Surg* 2018; 26:151–155.