

Comparison between the coagulation depth of bipolar plasma vaporization of the prostate, bipolar resection of the prostate, and monopolar resection of the prostate

Mohamed Kotb, Ahmed Ezzat Hashim, Mohamed Elmoazen, Hassan Sayed Shaker

Department of Urology, Faculty of Medicine, Ain-Shams University, Cairo, Egypt

Correspondence to Mohamed Kotb, MD, 16 Tayaran Street Nasr City, Cairo 11759, Egypt. Tel: 01004622675; e-mail: m.kotb@med.asu.edu.eg

Received: 10 July 2021

Accepted: 28 July 2021

Published: xx Month 2021

The Egyptian Journal of Surgery 2021, 40:1295–1299

Introduction

One of the commonest diseases in elderly men is benign prostatic hyperplasia. Recently, the gold standard for treatment of symptomatic benign prostatic hyperplasia is transurethral resection of the prostate. Monopolar transurethral resection of the prostate (MTURP) was the first to be used. Bipolar transurethral resection of the prostate (BTURP) and bipolar plasma vaporization of the prostate (BPVP) are mainly used nowadays rather than MTURP, as they proved a similar efficacy to the MTURP with less morbidity.

Aim

To evaluate the in vivo coagulation depth of the prostatic tissue specimen following BPVP, MTURP, and BTURP.

Patients and methods

The study was performed on 10 patients, where superficial resection of three different areas was done using the three different techniques in each patient followed by deep biopsy from each area using monopolar resectoscope. These three biopsies were examined using light microscopy. The depths of the coagulation zones were measured at 10 sites at equal intervals in each prostatic chip to assess the coagulation depth in each specimen.

Results

The coagulation depth induced by BPVP was greater than that of BTURP and it was the least with MTURP.

Conclusion

In vivo coagulation depth of BPVP is deeper than that of MTURP, which may correlate between the coagulation depth and clinical outcome of postoperative dysuria.

Keywords:

Benign prostatic hyperplasia, bipolar resection, coagulation depth, monopolar resection, plasma vaporization

Egyptian J Surgery 40:1295–1299
© 2021 The Egyptian Journal of Surgery
1110-1121

Introduction

One of the commonest diseases in elderly men is benign prostatic hyperplasia (BPH). It is a histological diagnosis with an excess proliferation of the connective tissue, smooth muscles, and glandular epithelium that may lead to lower urinary tract symptoms with or without bladder outlet obstruction [1,2].

Recently, the gold standard for treatment of symptomatic BPH is transurethral resection of the prostate (TURP). Monopolar transurethral resection of the prostate (MTURP) was the first to be used. Complications of using this technique such as bleeding and transurethral resection syndrome (TUR syndrome) had been reported [3–5].

Bipolar transurethral resection of the prostate (BTURP) and bipolar plasma vaporization of the prostate (BPVP) are mainly used nowadays rather

than MTURP, as they proved a similar efficacy to the MTURP with less morbidity [3,6].

The major advantage of BPVP is that it allows tissue resection together with simultaneous coagulation by using a specially designed surgical loop. This feature decreases the need for fulguration and enhances the visibility for clinicians. However, the loss of tissue for histopathological examination is a relative disadvantage [6–8].

The coagulation depth of both MTURP and BTURP was more than the mean diameter of prostatic microvessels. The coagulation depth of BTURP was

This is an open access journal, and articles are distributed under the terms of the Creative Commons Attribution-NonCommercial-ShareAlike 4.0 License, which allows others to remix, tweak, and build upon the work non-commercially, as long as appropriate credit is given and the new creations are licensed under the identical terms.

larger than that of MTURP that leads to a lower complication rate compared with MTURP with better hemostasis and deeper coagulation depth [9]. However, that variation in coagulation depth could not be translated to a certain clinical outcome [10]; on the other hand, BPVP showed a longer duration of resection with better hemostasis and was as effective as the conventional MTURP [11,12].

Coagulation depth of the resection technique and the energy dispersion is assumed to be related to a variable clinical outcome like postoperative dysuria and morbidities like capsular perforation, urethral stricture, or bladder neck contracture [12]. This study aims to compare the coagulation depth in tissue specimens following these three different techniques.

Patients and methods

Study design

This cross-sectional study was held between September 2016 and September 2019. The patients were recruited from the Urology Department and Clinic at Ain-Shams University, while the microscopic examination was performed in the Pathology Department at Ain-Shams University. The study was approved by the research ethics committee of Ain-Shams University. An informed signed consent was obtained from all patients.

Confidentiality: all research discussions with patients were conducted in a closed room in the outpatient clinic. We ensured that no one other than the investigators was present in the room during the study.

Declaration of interests: no interest other than the information gained and data obtained from participants for the research study.

Data availability: the data associated with this study are confidential and only available via the corresponding author upon reasonable request.

Ancillary and posttrial care: the study does not involve any physical, psychological, or social risks. The study could be stopped if any unexpected complaints were reported by the patients during the study.

Dissemination policy: reports and results were sent by e-mail to each participant individually.

Participants

A comparison between the coagulation depth of BPVP, MTURP, and BTURP techniques was achieved in 10 patients during routine management

of BPH surgical intervention at Ain-Shams University Hospitals.

Monopolar and bipolar resectoscopes were from Karl Storz Co. (Tuttlingen, Germany). The high-frequency generator was ERBE VIO 300 D ESU generator (Tubingen, Germany).

Superficial resection of three different areas of each prostate was done using the three different techniques followed by a deeper biopsy from each area using a monopolar resectoscope. These three biopsies were examined using light microscopy.

Three chips were obtained from each prostate in our 10 patients. After using each energy source, a deeper resection using a monopolar resection included an adequate depth below the resected area. Finally, we obtained 10 chips for each energy source and the chips were sent for microscopical evaluation to determine the coagulation depth in each chip.

All prostatic chips were fixed in 10% buffered formalin, then embedded in paraffin, sliced perpendicular to the cutting surface of the chips, and stained with hematoxylin and eosin.

The depths of the coagulation zones were measured at 10 sites at equal intervals in each prostatic chip under an image analyzer microscopic field, using high-power lens and zooming technology, and the mean depth was calculated and considered as the coagulation depth of each specimen.

The deep surface of all chips was marked to be excluded from coagulation-depth analysis, so the coagulation depth to be analyzed is the one that was produced on the superficial surface.

Statistical methodology

Analysis of the data was done by IBM computer using Statistical program for social science version 12 (SPSS) (Statistical analysis was done using IBM SPSS statistics for windows, Version 23.0. Armonk, NY: IBM Corp). Description of the quantitative variables as mean, SD, and range. Paired *t* test was used to compare quantitative variables in one group versus the other groups. *P* value of less than 0.05 was considered as statistically significant.

Results

The coagulation depth induced by BPVP (mean=169.6±54 μm; range, 109–262 μm) (Fig. 1) was greater than that induced by BTURP

(mean=148.8±72 μm; range, 49–262 μm) (Fig. 2) and by MTURP (mean=139±81 μm; range, 59.1–294 μm) (Fig. 3) as shown in Table 1.

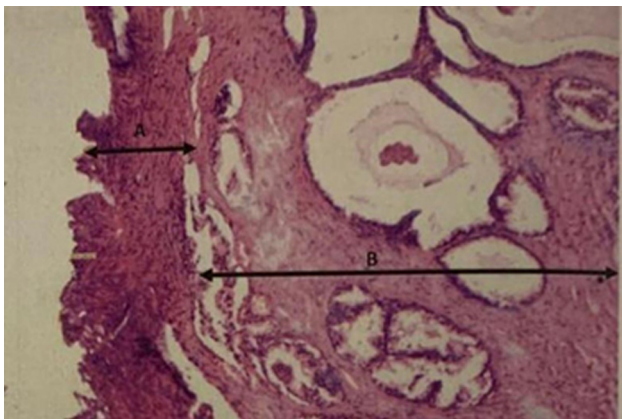
There was no significant difference between BPVP and BTURP (% of change 11.8%, $t=0.8$, $P>0.05$ NS) as shown in Table 2.

There was a significant difference in coagulation depth between BPVP and MTURP (% of change 17.5%, $t=2$, $P<0.05$ S) as shown in Table 3.

The coagulation depth induced by BTURP was greater than that induced by MTURP but with no significant difference (% of change 6.5%, $t=0.54$, $P>0.05$ NS) as shown in Table 4.

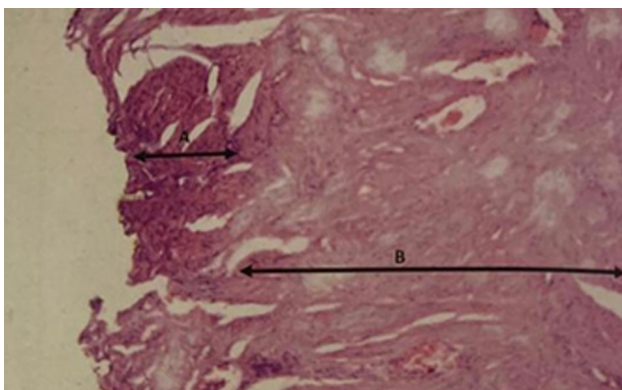
In other words, the coagulation effect induced by BPVP was deeper than that induced by BTURP and MTURP. Coagulation depth was noticed to be less

Figure 1



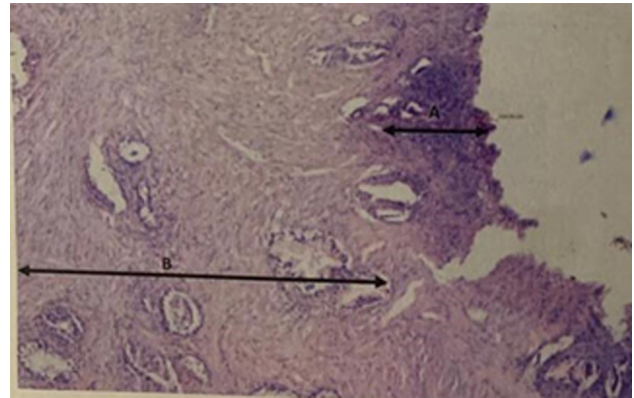
Prostatic tissue specimen after BPVP: (a) the coagulation depth (169.6±54 SD; range, 109–262). (b) The normal prostatic tissue. BPVP, bipolar plasma vaporization of the prostate.

Figure 2



Prostatic tissue specimen after BTURP: (a) the coagulation depth (148.8±72 SD; range, 49–292). (b) The normal prostatic tissue. BTURP, bipolar transurethral resection of the prostate.

Figure 3



Prostatic tissue specimen after MTURP: (a) the coagulation depth (139±81 SD; range, 59.1–294). (b) The normal prostatic tissue. MTURP, monopolar transurethral resection of the prostate.

Table 1 Distribution of the studied group as regards the penetration depth

Range	Mean±SD	Variables
109–262	169.6±54	BPVP
49–292	148.8±72	BTURP
59.1–294	139±81	MTURP

BPVP, bipolar plasma vaporization of the prostate; BTURP, bipolar transurethral resection of the prostate; MTURP, monopolar transurethral resection of the prostate.

Table 2 Comparison between bipolar plasma vaporization of the prostate versus bipolar depths among the studied group

Variables	Mean±SD	% of change	t	P value
BPVP	169.6±54	11.8	0.8	>0.05
BTURP	148.8±72			NS

BPVP, bipolar plasma vaporization of the prostate; BTURP, bipolar transurethral resection of the prostate; NS, nonsignificant; t , t test.

Table 3 Comparison between bipolar plasma vaporization of the prostate versus monopolar transurethral resection of the prostate depths among the studied group

Variables	Mean±SD	% of change	t	P value
BPVP	169.6±54	17.5	2	<0.05
MTURP	139±81			S

BPVP, bipolar plasma vaporization of the prostate; MTURP, monopolar transurethral resection of the prostate; S, significant; t , t test.

Table 4 Comparison between bipolar versus monopolar transurethral resection of the prostate penetration depths among the studied group

Variables	Mean±SD	% of change	t	P value
BTURP	148.8±72	6.5	0.54	>0.05
MTURP	139±81			NS

BTURP, bipolar transurethral resection of the prostate; MTURP, monopolar transurethral resection of the prostate; NS, nonsignificant; t , t test.

with MTURP compared with both BPVP and BTURP. However, a statistically significant difference was only noted between MTURP and BPVP ($P=0.04$). No statistically significant difference was noted between BPVP and BTURP or between MTURP and BTURP.

Discussion

The coagulation depth generated by the energy source during endoscopic resection is related to the hemostatic probabilities. The deeper the coagulation depth, the better the hemostasis and less intraoperative bleeding, especially if the coagulation depth is larger than the prostatic microvascular diameter that leads to blood vessel sealing [9]. However, this advantage is associated with unpleasant side effects due to heat dispersion and collateral damage to the sphincter or the urethra and may lead to postoperative dysuria, stress urinary incontinence, or delayed complication in the form of urethral stricture or bladder neck contracture [2]. An additional drawback is the histopathological changes from the heat-induced tissue charring that may affect the proper diagnosis [13].

Although both BPVP and MTURP remove tissue by direct heating of tissue, the coagulation depth of BPVP samples was deeper than those generated by MTURP, which resulted in better hemostasis with BPVP as it provides a longer duration of contact between active electrode and tissue giving a constant drag speed that increases the amount of energy penetrating the tissue, also being coupled with a higher baseline power output that is converted into thermal energy that creates thorough coagulation of tissue, especially when the coagulation depth exceeds the prostatic microvascular diameter [9,11].

In our study, the coagulation depth induced by BPVP was greater than that induced by BTURP and TURP, also the coagulation depth induced by BTURP was greater than that induced by MTURP. No significant statistical difference between BPVP and BTURP nor between BTURP and MTURP was found. On the other hand, there was a significant difference between BPVP and MTURP.

Similar results were reported by Reich *et al.* [14] using a novel ex vivo model to compare BPVP, BTURP, and MTURP in which they found that there were no apparent carbonization effects. Huang and colleagues and found that BTURP has deeper coagulation zones compared with MTURP from their studies that were performed on animals. Huang and colleagues reported

coagulation depths with MTURP and BTURP of 127.6 ± 27.8 and 148.5 ± 31.6 , respectively. This deeper coagulation depth was translated clinically into better hemostasis [15,16]. Ko *et al.* [13] on his animal study reported a coagulation depth of BTURP of 0.149 mm compared with 0.59 mm in the MTURP that was deeper compared with all the reported studies and this difference generated significantly less heat and histopathological evidence of thermal damage compared in BTURP in comparison with the MTURP in the present canine model.

Akgül *et al.* [8] performed their study to evaluate the electrocautery-induced tissue artifact and coagulation depth in a prostate specimen after open prostatectomy using BPVP and TURP, it revealed that TURP causes more artifacts in the tissue specimen with more coagulation depth compared with BPVP, this study was performed by application of electrocautery resection on 10 patients following open prostatectomy.

Our study is unique to evaluate the coagulation depth in vivo since the blood flow can impact the results by the heat-damping effect, which cannot be evaluated in vitro. Also, it was done on human prostates as they differ histologically from animal prostates limiting the translation of the results from animal studies to human beings.

Although the difference in coagulation depth between BPVP and MTURP is statistically significant, we cannot confirm a direct correlation related to the clinical outcome.

The limitations in our study are represented in the small number of cases; thus, we recommend that further studies to be performed on a larger number of cases with much detailed pathological evaluation. Further experimental and clinical studies, including long-term follow-up, are needed as well to build a direct correlation between the method of resection, the deeper coagulation zone, and the impact on clinical outcome of the patient symptomatology like postoperative dysuria and the development of delayed complications like urethral stricture or bladder neck contracture.

Conclusion

Our study showed that in vivo coagulation depth of BPVP is deeper than that of TURP, this may contribute to the clinical outcome and patient symptomatology. However, this correlation can be confirmed yet; thus, more clinical studies with a

larger sample size and longer duration of follow-up are recommended.

Financial support and sponsorship

Nil.

Conflicts of interest

There are no conflicts of interest.

References

- 1 Auffenberg GB, Helfand BT, Mcvary KT. Established medical therapy for benign prostatic hyperplasia. *Urol Clin North Am* 2009; 36:443–459.
- 2 Higazy A, Tawfeek AM, Abdalla HM, Shorbagy A, Mousa W, Radwan Al. Holmium laser enucleation of the prostate versus bipolar transurethral enucleation of the prostate in management of benign prostatic hyperplasia: a randomized controlled trial. *Int J Urol* 2021; 28:333–338.
- 3 Radwan A, Farouk A, Higazy A, Samir YR, Tawfeek AM, Gamal MA. Prostatic artery embolization versus transurethral resection of the prostate in management of benign prostatic hyperplasia. *Prostate Int* 2020; 8:130–133.
- 4 Welch G, Weinger K, Barry MJ. Quality-of-life impact of lower urinary tract symptom severity: results from the health professionals follow-up study. *Urology* 2002; 59:245–250.
- 5 Cox HT. Endoscopic resection of prostate. *BMJ* 1941; 2:860–860.
- 6 Bucuras V, Bardan R. Bipolar vaporization of the prostate: is it ready for the primetime? *Ther Adv Urol* 2011; 3:257–261.
- 7 Pasha MT, Khan MA, Jamal Y, Wahab F, Naeemullah XX. Postoperative complications with glycine and sterile distilled water after transurethral resection of prostate. *J Ayub Med Coll Abbottabad*; 27:135–139.
- 8 Akgül T, Nuhoglu B, Polat O, Ayyıldız A, Astarıcı M, Germiyanoglu C, *et al.* An in vitro study comparing the coagulation and cautery effects of bipolar and unipolar cutting modalities on prostatic tissue. *Urol Int* 2009; 83:458–462.
- 9 Huang X, Wang L, Wang X, Shi H, Zhang X, Yu Z. Bipolar transurethral resection of the prostate causes deeper coagulation depth and less bleeding than monopolar transurethral prostatectomy. *Urology* 2012; 80:1116–1120.
- 10 Michielsen DPJ, Coomans D, Van Lersberghe C, Braeckman JG. Comparison of the haemostatic properties of conventional monopolar and bipolar transurethral resection of the prostate in patients on oral anticoagulants. *Arch Med Sci* 2011; 7:858–863.
- 11 Li S, Kwong JSW, Zeng XT, Ruan XL, Liu TZ, Weng H, *et al.* Plasmakinetic resection technology for the treatment of benign prostatic hyperplasia: evidence from a systematic review and meta-analysis. *Sci Rep* 2015; 5:12002.
- 12 Sinanoglu O, Ekici S, Balci MBC, Hazar AI, Nuhoglu B. Comparison of plasmakinetic transurethral resection of the prostate with monopolar transurethral resection of the prostate in terms of urethral stricture rates in patients with comorbidities. *Prostate Int* 2014; 2:121–126.
- 13 Ko R, Tan AHH, Chew BH, Rowe PE, Razvi H. Comparison of the thermal and histopathological effects of bipolar and monopolar electrosurgical resection of the prostate in a canine model. *BJU Int* 2010; 105:1314–1317.
- 14 Reich O, Corvin S, Obermeder R, Sroka R, Muschter R, Hofstetter A. In vitro comparison of transurethral vaporization of the prostate (TUVP), resection of the prostate (TURP), and vaporization-resection of the prostate (TUVRP). *Urol Res* 2002; 30:15–20.
- 15 Mamoulakis C, De La Rosette JJMCH. Bipolar transurethral resection of the prostate: Darwinian evolution of an instrumental technique. *Urology* 2015; 85:1143–1150.
- 16 Huang X, Wang X, Wang H, Qu L. Comparison of the microvessel diameter of hyperplastic prostate and the coagulation depth achieved with mono- and bipolar transurethral resection of the prostate: a pilot study on hemostatic capability. *Scand J Urol Nephrol* 2008; 42:265–268.