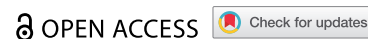



CASE REPORT



Case report: successful prophylactic use of intravenous lipid emulsion to prevent local anesthetic systemic toxicity after inadvertent intravenous administration of bupivacaine

Reham Mahrous , Ahmed Kareem, Ayman M. Hussam and Omnia A. Mandour

Department of Anesthesia, surgical ICU and Pain Management, Cairo University, Giza, Egypt

ABSTRACT

Bupivacaine is a local anesthetic drug that carries catastrophic adverse effects. On exceeding the toxic dose significant cardiotoxic and neurotoxic consequences emerge. The maximal toxic dose of Bupivacaine for local applications is 2 mg.kg⁻¹. The exact hazardous dose for intravenous administration is unknown. Abdominal hysterectomy was scheduled for our 57-year-old patient. She received 20 mg of Bupivacaine intravenously by accident and showed no evidence of cardiac or neurological toxicity. The explanation for this is unknown, although it could be owing to the very low dose, which was less than the toxic amount, or to our patient's early lipid emulsion prophylaxis.

ARTICLE HISTORY

Received 14 June 2021
Revised 26 June 2021
Accepted 5 July 2021

KEYWORDS

Local anesthetic toxicity;
bupivacaine; lipid emulsion;
hysterectomy

1. Introduction

Hysterectomy is a common surgical procedure. It may be performed through laparotomy, laparoscopy, or vaginally [1]. For several years, neuraxial techniques have been used in gynecologic surgery as a primary anesthetic or combined with general anesthesia. These neuraxial techniques, however, may be complicated by local anesthetic systemic toxicity (LAST). The incidence of LAST for peripheral nerve blocks is up to 1 per 500. For epidural procedures, the incidence is approximately 4 per 10,000 [2].

The local anesthetic agent works by blocking sodium channels in all types of tissues, including brain and heart, when absorbed intravenously. This results in a dose dependent attenuation of action potential in these organs and tissues. The binding of bupivacaine to sodium channel receptors will decrease the maximum speed of the depolarization of the action potential, as well as cardiac contractility. This may produce bupivacaine cardiotoxicity [3].

The effects on cardiac contractility and action potential can result in re-entrant arrhythmias, conduction delays through the myocardium, and bradycardia. Symptoms of neurotoxicity include circumoral numbness, ringing in the ears, and a metallic taste in the mouth. Symptoms may then progress to twitches in the upper and lower limb, grand mal seizures, coma, and eventual respiratory arrest [4].



Intravenous lipid emulsion (ILE) therapy can be used in the treatment and management of LAST. The mechanism of action of ILE is suggested as the lipid

sink effect by binding to local anesthesia (LA). This binding prevents the binding of the LA to its tissue receptors. The method of use involves administration of intralipid 20%, given as a bolus of 1.5 mL.Kg⁻¹ intravenous over one minute. It should then be followed by an infusion at a rate of 0.25 mL.Kg⁻¹.min⁻¹, for the management of LAST [5].

A written consent for publication was obtained from the patient.

2. Description of the case

A 57-years-old female patient, with a history of controlled hypertension, was presented to our hospital for elective abdominal hysterectomy. The patient weighed 90 kg, while their vital signs were within normal range. Her preoperative laboratory values were within the normal range. The anesthetic plan was discussed with the patient, and spinal anesthesia was chosen upon her request. Standard monitors including electrocardiogram, non-invasive blood pressure monitoring, and pulse oximeter were placed. The patient was given an IV infusion of 30 ml/kg of lactated ringer which was started for the purpose of intravascular preloading. While in the sitting position, the patient was injected with 2 mg of midazolam intravenously, by the anesthetic nurse as ordered by the anesthesiologist. The skin and subcutaneous tissue overlying the L4–L5 interspace was infiltrated with 2 mL of 1% lidocaine. A 25-gauge spinal needle was then slowly advanced to reach subarachnoid space. Cerebrospinal fluid (CSF)

CONTACT Reham Mahrous  dr_memoo2003@hotmail.com  Department of Anesthesia, Surgical ICU and Pain Management, Cairo University, Giza, Egypt

Abbreviations: LAST: local anesthetic systemic toxicity; ILE: Intravenous lipid emulsion; LA: local anesthesia; CSF: Cerebrospinal fluid; IV: Intravenous

© 2021 The Author(s). Published by Informa UK Limited, trading as Taylor & Francis Group.

This is an Open Access article distributed under the terms of the Creative Commons Attribution License (<http://creativecommons.org/licenses/by/4.0/>), which permits unrestricted use, distribution, and reproduction in any medium, provided the original work is properly cited.

flow through the spinal needle was confirmed. It was then observed that the syringe containing bupivacaine was injected intravenously, instead of midazolam by error. The spinal needle was then withdrawn, and the patient was kept in the sitting position. The syringe had contained 3.5 ml hyperbaric bupivacaine 0.5% (17.5 mg) and 25 mic fentanyl. Conscious level and vital signs were assessed immediately, and they were found to be within normal limits. An oxygen mask was applied; the presence of resuscitation equipment was confirmed. Intralipid emulsion 20% was then given, 10 minutes after the administration of Bupivacaine, a bolus of 1.5 ml.kg⁻¹ followed by 0.25 ml/kg/min for 15 min were provided. The patient was placed under close monitoring, to detect any signs and symptoms of LAST, including neurotoxicity and cardiotoxicity. Fortunately, there were no observed abnormalities with regards to hemodynamics or conscious level for 1 hour. After that, the decision was taken to proceed with the surgery under spinal anesthesia. No further remarkable events occurred.

3. Discussion

Local anesthetic toxicity usually happens when injecting a relatively large dose of local anesthetic drugs through the neuro-axial approaches, nerve blocks, or local infiltration. Systemic local anesthetic toxicity is associated with relatively smaller doses when the local anesthetic drugs are injected systematically. The exact toxic dose of Bupivacaine on intravenous injection is not accurately determined as intravenous injection of Bupivacaine is contraindicated. It has only ever been injected intravenously by error in very few care reports. The maximum dose of bupivacaine for local purposes should not exceed 2 mg/kg [6].

Our case received about 0.2 mg/kg intravenous bupivacaine that was discovered very early. Immediately upon discovery, a prophylactic dose of intravenous lipid emulsion was administered. The patient showed no signs of cardiovascular, or neurological local anesthetic toxicity.

George Albright, in the year 1979, described five cases of cardiac arrest which followed regional anesthesia with bupivacaine. These cases developed simultaneous convulsions and cardiac arrest after presumed intravascular injection. Their prolonged resuscitation was, unfortunately, unsuccessful. A narrow margin exists for bupivacaine-induced cardio and neurotoxicity, as depicted in these cases [7].

Another case of LAST was reported by Karaca S et al. in which there was an accidental injection of intravenous 0.25 mg/kg bupivacaine. The patient was a 53-years-old female and weighed 60 kg. The patient was scheduled for an elective total knee replacement. An epidural catheter was inserted preoperatively for

postoperative analgesia. The patient had requested epidural analgesia after which, the nurse, by error, had injected a mixture of bupivacaine 0.25% and morphine 2 mg in 6 mL solution I.V. The patient had developed mild symptoms of toxicity in the form of dizziness and ringing in the ears. Her vital signs showed sinus tachycardia of 120 beats/min. The patient's blood pressure was normal. The patient did not receive ILE; she was monitored only, with no occurrence of remarkable events [8].

Levsky and Miller reported on a patient who suffered from cardiovascular collapse, during a lumbar sympathetic ganglion radiofrequency ablation, after the administration of less than 1.1 mg/kg of Bupivacaine. The patient's history showed a previously sustained non-Q-wave myocardial infarction, while their preoperative electrocardiogram revealed first-degree atrioventricular block [9].

Rosenblatt et al. [10] and Litz et al [11] in the year 2006, described the first clinical application of ILE therapy in humans. Rosenblatt's patient had undergone an interscalene block with 20 ml bupivacaine, 0.5%, and 20 ml mepivacaine, 1.5%. Litz's patient received an axillary block with a total of 40 ml of 1% ropivacaine. In both cases after the failure of routine cardiopulmonary resuscitation (CPR) measures lipid emulsion therapy was initiated. Lipid emulsion therapy was associated with a quick reversal of the patient's cardiac arrhythmias, as well as successful resuscitation.

In 2007, Spence A. used ILE for the management of a primigravida patient who had developed signs of neurotoxicity, such as restlessness, agitation, and some twitching of her face and limbs. These symptoms were followed by unresponsiveness after injecting bupivacaine in the epidural catheter. It was suggested that the patient's epidural catheter may have migrated into an epidural vein, which caused the symptoms [12].

Another case of using ILE was in 2008 by McCutchen and Gerancher. The patient was an 82-years-old woman admitted for right total knee arthroplasty. She received 30 mL of 0.5% ropivacaine with 1:200,000 epinephrine through a femoral perineural catheter in 5 ml doses and 30 mL of 0.5% bupivacaine with 1:200,000 epinephrine for sciatic nerve block. Twenty seconds later, a tonic-clonic seizure occurred with ventricular tachycardia at a rate of 200 bpm, and her blood pressure was 114/64 mm Hg. Clinicians decided to administer 100 mL of 20% Intralipid, 150 mg of intravenous amiodarone, and 3 mg of midazolam. As ventricular tachycardia persisted, 120 J counter-shock was administered with immediate return to normal sinus rhythm [13].

Another study described a case of accidental intravascular injection of 15 ml of 0.5% bupivacaine with

1:200,000 epinephrine in an axillary block. The patient had developed circulatory collapse and seizures after the bupivacaine intravascular injection; however, they were successfully resuscitated with ILE, after only one ineffective dose of epinephrine [14].

Another study done by Shih Y-H et al. reported the occurrence of cardiotoxicity in a 69-year-old, woman, who was scheduled for carpal tunnel surgery. The patient was diabetic, hypertensive, and on regular hemodialysis due to end-stage kidney disease. She received an ultrasound-guided infraclavicular brachial plexus block with 15 mL 1.5% lidocaine, followed by 10 mL 0.375% bupivacaine. The patient became unresponsive, and the ECG showed severe junctional bradycardia with a ventricular rate of 30 beats/min. Atropine 1 mg was administered but failed to improve the patient's condition. After administration of 50 mL of 20% Intralipid, her heart rate started to increase and her consciousness returned to normal [15].

Our case had received a relatively small dose of a local anesthetic drug known for its high systemic toxicity and showed no signs of cardiac or neurological toxicity. The reason for this is unknown but may be due to the very small dose which was less than the toxic dose, or due to our patient having received very early prophylaxis with lipid emulsion, which has previously shown efficacy in the management of local anesthetic toxicity.

Disclosure statement

No potential conflict of interest was reported by the author(s).

ORCID

Reham Mahrous  <http://orcid.org/0000-0001-8884-5689>

References

- [1] Pandey D, Sehgal K, Saxena A, et al. An audit of indications, complications, and justification of hysterectomies at a teaching hospital in India. *Int J Reprod Med.* 2014;2014:1–6.
- [2] Dun-Chi Lin J, Sivanesan E, Horlocker TT, et al. Two for one: a case report of intravenous lipid emulsion to treat local anesthetic systemic toxicity in term pregnancy. *A A case reports* [Internet]. 2017 May 1 [cited 2021 Jun 26];8(9):235–237. Available from: <http://pmc/articles/PMC6484440/>
- [3] Fallin HA, Burns DA. Consider lipid emulsion rescue for local anesthetic overdose. In: Marcucci C, Cohen NA, DG KJ M, editors, *Avoiding common anesthesia errors* [Internet]. First edn. Philadelphia: Lippincott Williams and Wilkins; 2008 [cited 2021 Jun 26]. p. 473–479. Available from: <https://www.scribd.com/document/430933081/Avoiding-Common-Anesthesia-Errors-2008>
- [4] Mulroy MF. Systemic toxicity and cardiotoxicity from local anesthetics: incidence and preventive measures. In: editor, Saunders WB. *Regional anesthesia and pain medicine* [Internet]; 2002 [cited 2021 Jun 26]. p. 556–561. Available from: <https://pubmed.ncbi.nlm.nih.gov/12430104/>
- [5] Weinberg GL. Lipid infusion therapy: translation to clinical practice [Internet]. *Anesth Analg.* Lippincott Williams and Wilkins; 2008 [cited 2021 Jun 26]; 106:1340–1342. Available from: https://journals.lww.com/anesthesia-analgesia/Fulltext/2008/05000/Lipid_Infusion_Therapy__Translation_to_Clinical.3.aspx
- [6] Rosenberg PH, Veering BT, Urmey WF. Maximum recommended doses of local anesthetics: a multifactorial concept [Internet]. *Reg Anesth Pain Med.* 2004;29:564–575. [cited 2021 Jun 26]. Available from: <https://pubmed.ncbi.nlm.nih.gov/15635516/>
- [7] Albright GA. Cardiac arrest following regional anesthesia with etidocaine or bupivacaine [Internet]. *Anesthesiology* 1979;51:285–287. cited 2021 Jun 26]. Available from <https://pubmed.ncbi.nlm.nih.gov/484889/>
- [8] Karaca S, Ünlüsoy EÖ. Accidental injection of intravenous bupivacaine. *Eur J Anaesthesiol* [Internet]. 2002 Aug [cited 2021 Jun 26];19(8):616. Available from: <https://pubmed.ncbi.nlm.nih.gov/12200956/>
- [9] Levisky ME, Miller MA. Cardiovascular collapse from low dose bupivacaine. *Can J Clin Pharmacol.* 2005;12:3.
- [10] Rosenblatt MA, Abel M, Fischer GW, et al. Successful use of a 20% lipid emulsion to resuscitate a patient after a presumed bupivacaine-related cardiac arrest. *Anesthesiology* [Internet]. 2006 Jul [cited 2021 Jun 26];105(1):217–218. Available from: <https://pubmed.ncbi.nlm.nih.gov/16810015/>
- [11] Litz RJ, Popp M, Stehr SN, et al. Successful resuscitation of a patient with ropivacaine-induced asystole after axillary plexus block using lipid infusion. *Anaesthesia* [Internet]. 2006 Aug [cited 2021 Jun 26];61(8):800–801. Available from: <https://pubmed.ncbi.nlm.nih.gov/16867094/>
- [12] Spence AG. Lipid reversal of central nervous system symptoms of bupivacaine toxicity [8] [Internet]. *Anesthesiology* 2007 [cited 2021 Jun 26];107:516–517. Available from <https://pubmed.ncbi.nlm.nih.gov/17721262/>
- [13] McCutchen T, Gerancher JC. Early intralipid therapy may have prevented bupivacaine-associated cardiac arrest. *Reg Anesth Pain Med* [Internet]. 2008 Mar [cited 2021 Jun 26];33(2):178–180. Available from: <https://pubmed.ncbi.nlm.nih.gov/18299100/>
- [14] Cordell CL, Schubkegel T, Light TR, et al., Lipid infusion rescue for bupivacaine-induced cardiac arrest after axillary block [Internet]. *J Hand Surg Am* 2010 [cited 2021 Jun 26];35:144–146. Available from <https://pubmed.ncbi.nlm.nih.gov/20117318/>
- [15] Shih YH, Chen CH, Wang YM, et al. Successful reversal of bupivacaine and lidocaine-induced severe junctional bradycardia by lipid emulsion following infraclavicular brachial plexus block in a uremic patient. *Acta Anaesthesiol Taiwanica* [Internet]. 2011 Jun [cited 2021 Jun 26];49(2):72–74. Available from: <https://pubmed.ncbi.nlm.nih.gov/21729815/>