



Airway nerve block versus nebulization by lignocaine during diagnostic flexible bronchoscopy under moderate sedation: A randomized controlled trial

Heba F. Toulan, Maha S. El Derh and Samar M. Abdel Twab

Department of Anesthesiology, Intensive Care, and Pain Management, Faculty of Medicine, Ain Shams University, Cairo, Egypt

ABSTRACT

Background: Flexible bronchoscopy is an important procedure for the diagnosis and management of patients with respiratory diseases. This study aimed to assess safety and effectiveness of local anesthetic nebulization versus airway nerve block for upper airway anesthesia during diagnostic fiberoptic bronchoscopy under moderate sedation.

Methods: This randomized, controlled trial enrolled 120 patients scheduled for diagnostic fiberoptic procedures. The patients received 5 ml of 10% lignocaine by air-driven jet nebulizer for 20 minutes (Group A, n = 60) or bilateral superior laryngeal nerve block and trans-tracheal instillation of 4 ml of 2% lignocaine along with viscous lignocaine gargles twice (Group B, n = 60). In the postoperative period, the patient tolerance was assessed.

Results: Both groups were comparable in all baseline characteristics. The pain score was significantly lower in the nerve block group. Cough and requiring lignocaine were significantly more frequent in the nebulization group. No significant differences between the studied groups regarding intraoperative and postoperative PaO₂, PaCO₂, heart rate and mean blood pressure except heart rate; were significantly higher in the nebulized group. PaO₂ reductions at intraoperative and postoperative (compared with induction) were non-significantly higher in the nebulized group. PaCO₂, heart rate and mean blood pressure elevations in intraoperative and postoperative (compared with induction) were higher in the nebulized group, and the differences were non-significant in heart rate only.

Conclusion: Airway nerve block was associated with reduced consumption of lignocaine and less cough episodes during the procedure compared to nebulized lignocaine.

ARTICLE HISTORY

Received 31 October 2021

Revised 20 November 2021

Accepted 26 November 2021

KEYWORDS

Airway block; diagnostic fiberoptic bronchoscopy; laryngeal nerve block; nebulized lignocaine

1. Introduction

Flexible bronchoscopy is an essential procedure for diagnostic work-up and management of patients with various pulmonary diseases. This procedure is usually conducted under sedation to achieve patient tolerance to procedure. There is no clear recommendation favoring one sedation regimen over another; however, the combination of a short-acting benzodiazepine (e.g., midazolam (with propofol or an opioid has been found safe and effective [1].

It is essential to effectively anesthetize the upper airway and suppress the gag, swallow, and cough reflexes prior to diagnostic fiberoptic bronchoscopy to ensure patient tolerance. This can be achieved via either topical administration of a local anesthetic (LA) or airway nerve block [2].

Topical administrations of LA as sprays, gargles, lozenges, or nebulized forms cause less trauma to the airway compared to nerve blocks. Also, the risk of inadvertent injection into blood vessels is avoided. In contrast, nerve block techniques typically require smaller doses of LAs, possibly decreasing the risk of systemic toxicity [3].

Bronchoscopy is an endoscopic tool to examine the airway that allows both diagnostic and interventional procedures in various airway diseases. It is either rigid

or flexible bronchoscopy, depending on the patients' needs and skills of the bronchoscopist. It enables obtaining specimens from the lungs and distal airways. Broncho-alveolar lavage yields samples from the surface of the alveoli and aids differential diagnosis of different pulmonary disease [2].

Although many of the bronchoscopy procedures may be performed under moderate sedation, there has been a shift towards general anesthesia as a standard technique. Administration of general anesthesia immobilizes the patient and results in easier procedure, better outcome, and higher patient's and surgeon's satisfaction [4].

2. Methods

This study was conducted to assess safety and effectiveness of LA nebulization versus airway nerve block techniques for upper airway anesthesia during diagnostic fiberoptic bronchoscopy under moderate sedation.

Moderate Sedation/Analgesia was defined as ("Conscious Sedation") in which a drug-induced depression of consciousness during which the patient responds to verbal commands, either alone or

accompanied by light tactile stimulation. No interventions are required to maintain airway, and spontaneous ventilation is adequate. Cardiovascular function is usually maintained [5].

3. Ethical considerations

The study obtained approval from the Ethics Committee of Ain Shams Faculty of Medicine, Ain Shams University, Cairo, Egypt (FMASU R 128/2020; December 17, 2020). A written, informed consent was taken from each patient. Confidentiality of data was maintained by making code numbers for each patient. The trial was registered at ClinicalTrials.gov (NCT04806438; 19 March 2021).

We intend to share the individual de-identified participants' data through direct contact with the corresponding author, beginning 12 months and ending 36 months following article publication.

4. Study design, settings, and date

This parallel-group (1:1), randomized, clinical trial was conducted at Ain Shams University Hospitals, Cardiovascular Surgery Hospital (Thoracic Surgery Unit), Cairo, Egypt during March through June 2021.

5. Sample size calculation

Using PASS 11 program for sample size calculation, setting power at 80%, alpha error at 5%, reviewing the results of a previous study [6] showed that VAS scores for global tolerance, nausea, cough and pain were 5 ± 7.94 among the nebulization group Vs 12.08 ± 17.21 among the nerve block group. Based on these results, a sample size of at least 120 patients (60/group) will be needed.

6. Randomization and masking

Randomization was performed using a computer-generated randomization sequence and allocation concealment to be maintained all through the time of procedure using opaque, numbered, sealed envelopes.

An investigator (not involved in sequence generation and allocation concealment) assessed participants for eligibility and assigned eligible patients to receive either lignocaine nebulization (group A) or airway nerve block (group B).

7. Eligibility criteria

We enrolled adult male and female patients, aged 21–70 years, who were scheduled for diagnostic fiberoptic procedures, such as bronchoalveolar lavage, endobronchial or transbronchial biopsies, or brush cytology.

We excluded patients with (a) respiratory failure ($pH < 7.35$, arterial oxygen pressure $[PaO_2] < 55$ mmHg despite supplemental oxygen); (b) upper airway

surgery or radiation; (c) allergy to lignocaine, propofol, or midazolam; (d) bleeding disorder; (e) hemodynamic instability or decompensated heart failure; (f) epilepsy, severe neurological or psychiatric disorder; and (g) those requiring cryobiopsy or endobronchial ultrasound because these procedures are performed under deep sedation including fiberoptic intubation.

8. Intervention

All patients included in this study underwent preoperative evaluation including a complete airway evaluation (mouth opening, Mallampati grading, thyromental distance, and evaluation of dentition), smoking history, standard fasting guidelines, and anti-aspiration prophylaxis (4 mg of ondansetron by intravenous route). Complete blood count, coagulation profile, and pulmonary function tests were also performed.

The procedure was explained in the preoperative assessment visit. On patient's arrival to the induction room, an intravenous line was secured with atropine (0.01 mg/kg) administered. Standard monitoring including noninvasive blood pressure (BP), electrocardiography (ECG), and pulse oximetry (SpO_2) was applied in each patient.

An arterial line was established under local anesthesia for monitoring of arterial blood pressure and blood gases sampling for PaO_2 and $PaCO_2$ monitoring and recording. After recording the baseline heart rate (HR), BP, and SpO_2 , intravenous injection of midazolam (20 μ g/kg) was done.

The patients were randomly allocated into two groups. Group A (nebulized lignocaine group, $n = 60$) received 5 ml of 10% lignocaine by air-driven jet nebulizer for 20 min [7]. Group B (airway nerve block group, $n = 60$) received bilateral superior laryngeal nerve block and transtracheal instillation of 4 ml of 2% lignocaine along with viscous xylocaine gargles twice [5].

Adequate effect of the local anesthetic was confirmed by heaviness of tongue in group A and by hoarseness of voice in group B patients. The patients were transferred to the operation room while given supplemental oxygen through nasal prongs. Moderate level of sedation was achieved by intravenous administration of propofol (0.5 mg/kg over 3 minutes with a maximum dose of 2.5 mg/kg). Then, the fiberoptic bronchoscope was inserted by the surgeon. Vital parameters (HR, BP, Oxygen saturation) were recorded at the insertion of the bronchoscope and at 1 & 3 minutes after insertion. Supplemental LA was given as 2 ml of 2% lignocaine through the working channel of fiberoptic bronchoscope (FOB) (another dose was given after waiting for 30–60 seconds if needed) depending on gag/cough reflex and cord visibility (cord visibility recorded as relaxed, semi relaxed and adducted) and total number of lignocaine doses were recorded.

Any sign of lignocaine toxicity was noted and treated accordingly. Seizures, bradycardia (HR < 60 beats/min), and bronchoconstriction were treated by 5 mg of midazolam, 0.4 mg of atropine, and 2 puffs of B₂ agonist inhaler plus 0.2 mg/kg of hydrocortisone, respectively. Ventricular arrhythmias were managed according to the American Heart Association Clinical Practice Guidelines [5,8].

9. Outcome measures

9.1. Primary outcome

Patient tolerances were assessed in the postoperative period. Patient tolerance was assessed using the visual analogue scale (VAS) (0 = no bother, 10 = intolerable).

9.2. Secondary outcomes

- Occurrence of nausea, vomiting and cough or need for supplementary doses of lignocaine.
- Safety was assessed looking for complications or adverse effects, such as seizures, bronchoconstriction, or arrhythmias.

10. Statistical analysis

Statistical analysis was performed using Statistical Package for Social Sciences (IBM SPSS Statistics) for Windows, version 22.0 (IBM Corp., Armonk, NY, USA). Quantitative data were tested for normality using Shapiro–Wilk test, and normally distributed data were described as mean \pm standard deviation. The two groups were compared using independent *t*-test (if normally distributed) and Mann–Whitney test (if not normally distributed). For categorical data, the variables were summarized as frequencies (count and percentage). Pearson’s chi-square test for independence, Fisher’s exact test or Fisher–Freeman–Halton’s exact test were used to examine association between two categorical variables as appropriate. A *p*-value < 0.05 was adopted for interpreting significance of statistical tests. The effect size was calculated for the relative value of each medication over other tested medications.

11. Results

One hundred sixty-seven adult patients scheduled for diagnostic fiberoptic procedures were assessed. One hundred twenty met eligibility criteria and were randomly allocated to receive either lignocaine nebulization (group A, *n* = 60) or airway nerve block (group B, *n* = 60). There was no loss to follow up or exclusions after randomization (Figure 1).

We found no significant differences between the studied groups regarding age, sex, ASA, smoking, smoking index, and FEV1 > 80.0% (Table 1) as well as the types of the procedures (Table 2) (*P* > 0.05).

Table 3 shows that the pain score was significantly higher (*P* < 0.001), and cough (*P* = 0.011) and need for supplementary doses of lignocaine (*P* = 0.027) were significantly more frequent among patients in the nebulization group. We found no significant differences between the studied groups regarding the operation duration (*P* = 0.3). Cord relaxation and nausea were non-significantly less frequent in the nebulization group (*P* = 0.366 and 0.35, respectively). Vomiting or bronchoconstriction were not recorded in either group.

Table 4 shows no significant differences between the studied groups regarding induction (baseline), intraoperative, and postoperative PaO₂, PaCO₂, heart rate, and mean blood pressure (*P* > 0.05) except heart rate; it was significantly higher in nebulized group in intraoperative period at time of introduction of bronchoscopy. PaO₂ reductions at intraoperative and postoperative (compared with induction) were non-significantly higher in the nebulization group (*P* > 0.05). PaCO₂, heart rate, and mean blood pressure elevations at intraoperative and postoperative (compared with induction) were higher in the nebulization group; however, the differences were non-significant in the heart rate only.

As regards the mentioned complication of local anesthetics (seizures and arrhythmia) we did not record any case of either complication as we considered the safety margin of local anesthesia doses.

12. Discussion

Nebulization of local anesthetics and nerve block regional anesthesia are among several anesthesia techniques used to facilitate diagnostic flexible bronchoscopy. In this study, we assessed the safety and effectiveness of LA nebulization versus airway nerve block for upper airway anesthesia during diagnostic fiberoptic bronchoscopy under moderate sedation.

The results showed that the patient comfort and tolerance were better in the nerve block group compared with the nebulization group. The nerve block technique was associated with reduced consumption of lignocaine and less cough episodes during the procedure compared to nebulized lignocaine. Lignocaine nebulization patients showed non-significantly lower incidence of cord relaxation and nausea. Intraoperative and postoperative PaO₂ reductions were non-significantly higher in the nebulization group. PaCO₂, heart rate, and mean arterial blood pressure elevations were higher in the nebulization group, but the differences were only significant in heart rate values. Neither groups had signs of lignocaine toxicity.

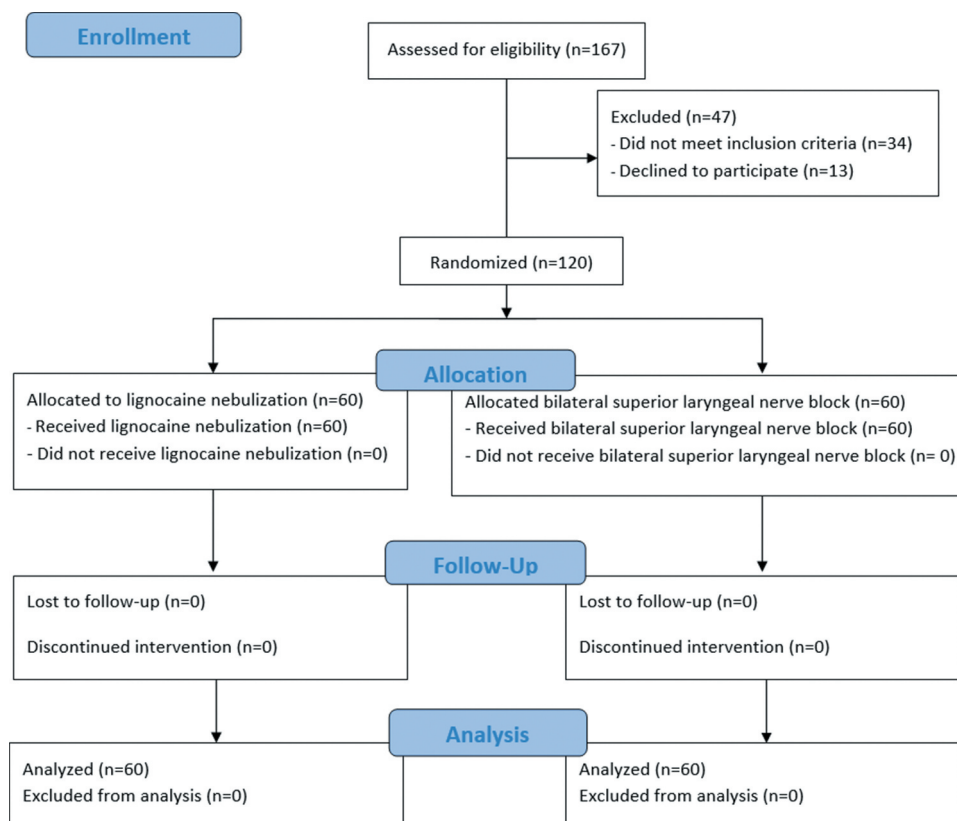


Figure 1. The trial flow diagram.

Table 1. Demographic characteristics.

Variables	Group A (n = 60)	Group B (n = 60)	P value
Age (years), mean \pm SD	47.4 \pm 5.4	46.2 \pm 5.1	\wedge 0.226
Sex (n, %)			
Male	40 (66.7%)	37 (61.7%)	#0.568
Female	20 (33.3%)	23 (38.3%)	
ASA (n, %)			
I	14 (23.3%)	12 (20.0%)	#0.801
II	31 (51.7%)	30 (50.0%)	
III	15 (25.0%)	18 (30.0%)	
Smoking (n, %)	48 (80.0%)	46 (76.7%)	#0.658
Smoking index (packs/year), median (IQR)	8.5 (3.0 – 13.8)	8.0 (1.0 – 13.8)	\boxplus 0.450
FEV1 > 80.0%, (n, %)	15 (25.0%)	19 (31.7%)	#0.418

SD: standard deviation; IQR: Interquartile range; \wedge Independent t-test; #Chi square test; \boxplus Mann Whitney test
The results are presented as mean \pm SD, number (%), or number (IQR).

Table 2. Procedures included in the study.

Diagnostic interventions	Group A (n = 60)	Group B (n = 60)
Diagnostic only	11	13
Endobronchial biopsy	31	29
Broncho-alveolar lavage	9	10
Transbronchial biopsy	6	5
Brush cytology	3	3

The results are presented as numbers.

Flexible bronchoscopy is usually conducted under sedation to facilitate the procedure and improve patient comfort and cooperation. Sedation with two or even three different drugs is safe and superior to sedation with a single drug [9]. The procedures in our study were performed under moderate sedation using propofol boluses as needed.

Lignocaine nebulization for anesthesia of upper airway and larynx has also been studied. Cullen et al [3]. found that lignocaine nebulization decreased the discomfort of nasogastric tube insertion. Similarly, lignocaine nebulization added to topical nasal cocaine produced adequate upper airway anesthesia with for fiberoptic nasotracheal techniques [10].

Nebulization of lignocaine results in good distribution of the drug on the surface of the upper airway and tracheobronchial tree leading to airway analgesia and suppression of the cough reflex [6]. This technique of drug administration also avoids the risk of inadvertent injection into the blood vessels [2].

Gupta and colleagues [2] compared airway nerve block versus nebulization of a LA by ultrasonic nebulizer for awake FOB guided intubation. They reported

Table 3. Operative findings.

Variables		Group A (n = 60)	Group B (n = 60)	P value	Effect size	
					mean \pm SD	95% CI
Operation duration (minutes), mean \pm SD		39.0 \pm 4.6	38.2 \pm 3.8	\wedge 0.300	0.8 \pm 0.8	-0.7-2.3
Pain score (VAS-10), mean \pm SD		3.5 \pm 0.6	2.8 \pm 0.7	\wedge <0.001*	0.7 \pm 0.1	0.5-0.9
Cord condition (n, %)	Relaxed	37 (61.7%)	45 (75.0%)	§0.366	RR (95% CI)	
	Semi relaxed	21 (35.0%)	14 (23.3%)		Reference	
	Adducted	2 (3.3%)	1 (1.7%)		1.53 (0.86-2.70)	
Nausea (n, %)		34 (56.7%)	39 (65.0%)	#0.350	2.36 (0.22-25.04)	
Vomiting (n, %)		0 (0%)	0 (0%)		0.87 (0.65-1.16)	
Cough (n, %)		26 (43.3%)	13 (21.7%)	#0.011*	\wedge 1.0	
Requiring lignocaine (n, %)		48 (80.0%)	37 (61.7%)	#0.027*	2.00 (1.14-3.51)	
Bronchoconstriction (n, %)		0 (0%)	0 (0%)		1.30 (1.02-1.64)	
Lignocaine doses (n, %)	Zero	12 (20.0%)a	23 (38.3%)b	#<0.001*	Reference	
	One	13 (21.7%)a	26 (43.3%)b		0.98 (0.62-1.55)	
	Two	15 (25.0%)a	9 (15.0%)a		1.98 (1.03-3.78)	
	Three	13 (21.7%)a	1 (1.7%)b		12.48 (1.77-88.19)	
	Four	7 (11.7%)a	1 (1.7%)b		8.84 (1.19-65.79)	

SD: standard deviation; \wedge Independent t-test; #Chi square test; §Fisher's Exact test; *significant; homogenous groups had the same symbol (a, b) based on post hoc Bonferroni test; RR: relative rate; CI: confidence interval
The results are presented as mean \pm SD or number (%).

a denser block in the nerve block group compared to the nebulized group as assessed by patient tolerance, coughing or gagging with FOB insertion, and visibility of vocal cords.

Likewise, Kundra et al. [11] compared two different techniques of anesthetizing the airway for awake fiberoptic nasotracheal intubation. The study participants were prepared through either nebulization (4 ml of 4% lignocaine) or airway block (trans laryngeal, bilateral superior laryngeal, and lignocaine-soaked cotton swabs in the nose). The time of intubation was similar in both groups but with higher stress during tube insertion through the glottis in the nebulization group. The grimace scores as well as the mean heart rate and blood pressure values were significantly higher during tube insertion in the nebulization group.

Our results were different from those reported by Reasoner et al. [12] who used nebulized lignocaine and airway blocks to support FOB guided intubation in patients with cervical spine instability. The topical anesthesia group received 4% lignocaine (20 ml via nebulization then 3 ml via transtracheal injection). The nerve block group received bilateral glossopharyngeal and superior laryngeal nerve blocks along with the transtracheal lignocaine injection. They found no significant differences between the two groups regarding the time taken to intubate. This was mostly due to the supplemented trans-tracheal lignocaine injection, which improved the depth of anesthesia.

Gal [13] found that lignocaine nebulization caused airway irritation as evidenced by coughing. Later, the drug produced bronchodilatation due to its membrane stabilizing action.

Table 4. Blood gases and vital data.

Time	Nebulized (n = 60)	Injected (n = 60)	\wedge P value	Effect size	
				mean \pm SE	95% CI
PaO ₂ (mmHg)					
Induction	79.5 \pm 3.5	78.9 \pm 3.1	0.350	0.6 \pm 0.6	-0.6-1.8
Intraoperative	73.6 \pm 3.5	73.3 \pm 3.1	0.568	0.3 \pm 0.6	-0.9-1.5
Postoperative	77.8 \pm 3.4	77.4 \pm 3.1	0.537	0.4 \pm 0.6	-0.8-1.6
Change at intraoperative	-5.8 \pm 0.8	-5.6 \pm 0.8	0.124	-0.2 \pm 0.1	-0.5-0.1
Change at postoperative	-1.7 \pm 0.6	-1.5 \pm 0.6	0.071	-0.2 \pm 0.1	-0.4-0.0
PaCO ₂ (mmHg)					
Induction	35.2 \pm 2.0	35.6 \pm 1.8	0.255	-0.4 \pm 0.3	-1.1-0.3
Intraoperative	46.7 \pm 2.1	46.9 \pm 1.9	0.599	-0.2 \pm 0.4	-0.9-0.5
Postoperative	38.2 \pm 2.0	38.4 \pm 1.9	0.528	-0.2 \pm 0.4	-0.9-0.5
Change at intraoperative	11.4 \pm 0.8	11.2 \pm 0.7	0.136	0.2 \pm 0.1	-0.1-0.5
Change at postoperative	3.0 \pm 0.5	2.8 \pm 0.5	0.058	0.2 \pm 0.1	0.0-0.4
Heart rate (beats/minute)					
Induction	86.4 \pm 3.7	87.6 \pm 4.8	0.127	-1.2 \pm 0.8	-2.7-0.3
Intraoperative	96.4 \pm 4.3	94.4 \pm 4.9	0.019*	2.0 \pm 0.8	0.3-3.7
Postoperative	93.3 \pm 3.9	91.3 \pm 4.8	0.018*	1.9 \pm 0.8	0.3-3.5
Change at intraoperative	10.1 \pm 1.6	6.9 \pm 1.4	<0.001*	3.2 \pm 0.3	2.7-3.7
Change at postoperative	6.9 \pm 0.6	3.8 \pm 0.6	<0.001*	3.1 \pm 0.1	2.9-3.3
Mean blood pressure (mmHg)					
Induction	57.9 \pm 4.0	58.2 \pm 3.4	0.692	-0.3 \pm 0.7	-1.6-1.1
Intraoperative	71.1 \pm 4.2	70.8 \pm 4.3	0.686	0.3 \pm 0.8	-1.2-1.9
Postoperative	62.3 \pm 4.0	62.4 \pm 3.5	0.942	-0.1 \pm 0.7	-1.4-1.3
Change at intraoperative	13.2 \pm 1.3	12.6 \pm 2.2	0.073	0.6 \pm 0.3	-0.1-1.2
Change at postoperative	4.4 \pm 0.6	4.2 \pm 0.7	0.061	0.2 \pm 0.1	0.0-0.4

SE: standard error; change = intra or postoperative-induction; negative values indicate reduction; \wedge Independent t-test; *significant; CI: confidence interval

The maximum total dose of lignocaine used in the current research work has been safely used for FOB in earlier studies. Parkes et al. [14] used 6 mg/kg of 10% lignocaine solution through nebulization. The serum lignocaine levels measured always remained below the accepted threshold of 5 mg/l (highest levels obtained were 0.45 mg/l). Also, Langmack et al. [15] measured serum lignocaine levels in asthmatic volunteers undergoing FOB with topical lignocaine. The average total dose used was 600 mg (8.2 mg/kg), which was safe in all patients as assessed by serum lignocaine concentrations. Nonetheless, Wu et al. [16] reported seizures in a patient after administration of topical lignocaine with a total dose of 300 mg during FOB. Serum lignocaine concentrations were found to be well above the acceptable toxic limits. Hence, a constant lookout for signs and symptoms of lignocaine toxicity is mandatory while using large doses.

Earlier studies compared the use of airway nerve block and nebulized lidocaine for fiberoptic intubation. To the best of our knowledge, the current study is the first to compare the two techniques with fiberoptic surgical bronchoscopies. However, the limitation of this study was that simple bronchoscopy procedures were included but more invasive procedures were not. Also, serum lignocaine was not measured due to non-availability in our hospital.

13. Conclusions

Performing diagnostic flexible bronchoscopy under moderate sedation and airway nerve block provides better airway anesthesia, higher patient tolerance, shorter procedure, lesser cough episodes, and lesser total lignocaine consumption compared with lignocaine nebulization.

Disclosure statement

No potential conflict of interest was reported by the authors.

References

- [1] Du Rand IA, Blaikley J, Booton R, et al. British thoracic society guideline for diagnostic flexible bronchoscopy in adults: accredited by NICE. *Thorax*. 2013;68(Suppl 1):i1–i44.
- [2] Gupta B, Kohli S, Farooque K, et al. Topical airway anesthesia for awake fiberoptic intubation: comparison between airway nerve blocks and nebulized lignocaine by ultrasonic nebulizer. *Saudi J Anaesth*. 2014;8:515–19.

- [3] Cullen L, Taylor D, Taylor S, et al. Nebulized lidocaine decreases the discomfort of nasogastric tube insertion: a randomized, double-blind trial. *Ann Emerg Med*. 2004;44(2):131–137.
- [4] Panchabhai TS, Chaddha U, McCurry KR, et al. Historical perspectives of lung transplantation: connecting the dots. *J Thorac Dis*. 2018;10(7):4516–4531.
- [5] Barash PG, Cullen BF, Stoelting RK, et al. *Clinical Anesthesia*. Eighth. Philadelphia PA: Wolters Kluwer; 2017. Section 6, Chapter 30. p. 2080–2097.
- [6] Müller T, Cornelissen C, Dreher M. Nebulization versus standard application for topical anaesthesia during flexible bronchoscopy under moderate sedation - a randomized controlled trial. *Respir Res*. 2018;19(1):227.
- [7] Dreher M, Cornelissen CG, Reddemann MA, et al. Nebulized versus standard local application of lidocaine during flexible bronchoscopy: a randomized controlled trial. *Respiration*. 2016;92(4):266–273.
- [8] Al-Khatib SM, Stevenson WG, Ackerman MJ, et al. AHA/ACC/HRS guideline for management of patients with ventricular arrhythmias and the prevention of sudden cardiac death: a report of the American college of cardiology/American heart association task force on clinical practice guidelines and the heart rhythm society. *Circulation*. 2017;2018(138):e272–e391.
- [9] Müller T, Thümmel K, Cornelissen CG, et al. Analogosedation during flexible bronchoscopy using a combination of midazolam, propofol and fentanyl - A retrospective analysis. *PloS One*. 2017;12(4):e0175394.
- [10] Techanivate A, Leelanukrom R, Prapongsena P, et al. Effectiveness of mouthpiece nebulization and nasal swab stick packing for topical anesthesia in awake fiberoptic nasotracheal intubation. *J Med Assoc Thailand*. 2007;90(10):2063–2071.
- [11] Kundra P, Kutralam S, Ravishankar M. Local anaesthesia for awake fiberoptic nasotracheal intubation. *Acta Anaesthesiol Scand*. 2000;44(5):511–516.
- [12] Reasoner DK, Warner DS, Todd MM, et al. A comparison of anesthetic techniques for awake intubation in neurosurgical patients. *J Neurosurg Anesthesiol*. 1995;7(2):94–99.
- [13] Gal TJ. Airway responses in normal subjects following topical anesthesia with ultrasonic aerosols of 4% lidocaine. *Anesth Analg*. 1980;59(2):123–129.
- [14] Parkes SB, Butler CS, Muller R. Plasma lignocaine concentration following nebulization for awake intubation. *Anaesth Intensive Care*. 1997;25(4):369–371.
- [15] Langmack EL, Martin RJ, Pak J, et al. Serum lidocaine concentrations in asthmatics undergoing research bronchoscopy. *Chest*. 2000;117(4):1055–1060.
- [16] Wu FL, Razzaghi A, Souney PF. Seizure after lidocaine for bronchoscopy: case report and review of the use of lidocaine in airway anesthesia. *Pharmacotherapy*. 1993;13(1):72–78.