



# Bilateral sphenopalatine ganglion block with adrenaline additive for post-dural puncture headache in orthopedic patients: A randomized controlled trial

Amany Mohamed Abotaleb , Mohammed Said ElSharkawy and Hussen Gamal Almawardy

Anesthesiology, Surgical Intensive Care and Pain Medicine, Faculty of Medicine, Tanta University, Tanta, Egypt

## ABSTRACT

**Background:** Post dural puncture headache (PDPH) is a common condition that occurs following an accidental dural puncture. The work aimed to determine the efficacy and safety of analgesia of sphenopalatine ganglion block (SPB) (lidocaine 4% with adrenaline) for PDPH in orthopedic patients.

**Methods:** This randomized prospective open-label-controlled trial was conducted on 60 cases aged 18–60 years, both sexes American Society of Anesthesiologists (ASA) physical status I and II with severe PDPH during seven days after subarachnoid blockage for surgeries of lower limbs. Cases were randomized into two equal groups: Group MT: received medical treatment paracetamol 1 gm/6 hour daily, Group SPB: received SPB by using lidocaine 4% and adrenaline (1/2,000,000). The analgesia was effective if visual analogue scale (VAS) was < 4 in the first 48 hours. Patients with VAS ≥ 4 received diclofenac 75 mg/12 hour if pain was not controlled. Epidural blood patch was used in case of unrelieved pain after 3 days.

**Results:** There were significant quicker onset and longer duration of analgesia in group SPB compared to group MT ( $P = 0.001$  and  $0.03$ , respectively). VAS score was insignificantly different at baseline and 48 hours and was significantly lower in group SPB compared to group MT at 30 min, 1 h, 2 h, 6 h, 12 h, and 24 h. The need for EBP was significantly lower in group SPB B than group MT (16.7% versus 46.7%).

**Conclusions:** SPB is an effective method for PDPH in orthopedic patients with quicker onset and longer duration of analgesia and lower VAS score compared to medical treatment.

## ARTICLE HISTORY

Received 5 April 2022

Revised 27 April 2022

Accepted 9 May 2022

## KEYWORDS

Sphenopalatine ganglion block; epidural blood patch; Post-Dural puncture headache; adrenaline

## 1. Introduction

Post dural puncture headache (PDPH) is a common condition that occurs following an accidental dural puncture or epidural needle. PDPH is a well-known iatrogenic complication particularly by using large gauge, cutting needles or multiple attempts [1]. It is the drawback in using of spinal anesthesia or diagnostic lumbar puncture [2].

The headache may persist months or even years in some patients and, if not effectively controlled, may develop into chronic headache [3] and even lead to development of an intracranial subdural hematoma [4].

Although the epidural blood patch (EBP) is considered the gold standard for treating PDPH, with success rates reaching to 90% [5]. Motor and sensory impairments, meningitis, loss of hearing, Horner's syndrome, and subdural hematoma are all possible neurological consequences [6]. EBP may result in another unintentional dural puncture [7].

Regarding the Monro–Kellie hypothesis, the intracranial compartment's total volume of brain, cerebrospinal fluid, and blood is still constant [8].

If one constituent's volume decreases, another constituent's volume must increase to maintain the balance. Following dural puncture, a continual loss of cerebrospinal fluid occurs due to the dural tear [9]. As a result, compensatory vasodilation occurs to maintain intracranial volume, resulting in headache. SPB alleviates symptoms by inhibiting parasympathetic-induced vasodilation [4].

The sphenopalatine ganglion is a parasympathetic extracranial ganglion approximately 5 mm in diameter situated in the pterygopalatine fossa, posterior to the middle nasal turbinate and anterior to the pterygoid canal [10]. Within the ganglion, only the preganglionic parasympathetic fibers synaptize. Sympathetic neurons and somatic sensory fibers from the trigeminal nerve's maxillary division run through the ganglion [11]. SPB blocks all of these fibers [12].

Sphenopalatine ganglion block (SPB) has been widely used for treating migraines, cluster headaches, trigeminal neuralgia, and orofacial discomfort [13]. SPB is minimally invasive, with few adverse effects, and

**CONTACT** Amany Mohamed Abotaleb [amanyabotaleb111@gmail.com](mailto:amanyabotaleb111@gmail.com) Anesthesiology, Surgical Intensive Care and Pain Medicine, Faculty of Medicine, Tanta University, Tanta, Egypt

The actual work was done at faculty of Medicine, Tanta University, Egypt.

© 2022 The Author(s). Published by Informa UK Limited, trading as Taylor & Francis Group.

This is an Open Access article distributed under the terms of the Creative Commons Attribution License (<http://creativecommons.org/licenses/by/4.0/>), which permits unrestricted use, distribution, and reproduction in any medium, provided the original work is properly cited.

provides effective and quick analgesia. SPB provided effective and quick analgesia when it has been used as first-line for treating and managing of PDPH [14,15].

In the present study, we hypothesized that the use of lidocaine and adrenaline for SPB will result in rapid onset of action and prolonged duration of analgesic effect of SPB for PDPH in orthopedic patients within 48 hours of follow up, therefore we established this work to determine the efficacy and safety of analgesia of SPB (lidocaine 4% with adrenaline) for orthopedic patients.

## 2. Materials and Methods

### 2.1. Patient population and eligibility criteria

This randomized-controlled open-label trial was conducted on 60 cases aged 18–60 years, both sexes American Society of Anesthesiologists (ASA) physical status I and II with severe PDPH (VAS>7) during seven days after subarachnoid blockage for surgeries of lower limbs.

The study was done after approval from the Ethical Committee at Tanta University Hospitals, Egypt (Approval code: 34268/11/20) and registered at clinicaltrials.gov (NCT04657952) from December 2020 to January 2022. An informed written consent was obtained from the patient.

Exclusion criteria were uncooperative patients, uncontrollable hypertension, known coagulopathy, nasal septal deviation, polyp, or previous nasal bleeding, and allergic response to local anesthetics.

### 2.2. Randomization

Randomization was performed with a computer-generated random list using sealed opaque envelopes indicating the group of assignment. Cases were classified into two equal groups: Group MT: received medical treatment paracetamol 1 gm/6 hour daily and IV diclofenac 75 mg/12 hours was added in case of failure in pain relief, group SPB: received SPB by using lidocaine 4% and adrenaline (1/2,000,000) for rapid onset and longer duration of action. A preprocedural evaluation was done in form of full history taking, clinical and routine laboratory investigations. Patients were instructed on how to use the visual analogue scale (VAS); a 0–10 scale of 0 with no pain and 10 being the worst pain imaginable.

### 2.3. Sphenopalatine ganglion block technique

At operation room, 20-gauge IV cannula was inserted and portable monitoring in terms of electrocardiogram, non-invasive blood pressure, and oxygen saturation was performed.

SPB was conducted transnasally as little drops of lidocaine 4% was instilled into both anterior nares. Then, the patient in the supine position, for 5 minutes, a cotton soaked in lidocaine 4% and adrenaline (1/2,000,000) was inserted through both nares, with the applicator tip just superior to the middle turbinate and anterior to the pterygopalatine fossa and sphenopalatine ganglion.

### 2.4. Measurements

The patient was instructed to sit up and the appearance of headache was determined by VAS. Also, VAS was recorded before procedure and at 30 min, 1h, 2h, 6h, 12h, 24 h and 48h after the procedures If VAS remained >4 in both groups after 2 h, IV paracetamol 1 gm was administered once then IV diclofenac 75 mg/12 hourly was added.

Patient satisfaction score from [1–5] (1: very dissatisfied), (2: dissatisfied)

(3: Neither satisfied nor dissatisfied). (4: Satisfied). (5: Very satisfied).

Adverse events are hypertension, postoperative epistaxis, local anesthetic toxicity, hypoesthesia of the palate, nausea, tingling, and cheek hematoma. Any of the following events was recorded if occurred throughout the procedure and treated accordingly: Local anesthetic toxicity was treated according to the standard protocol epistaxis or hematoma was treated by local compression. Patients in both groups who lacked acceptable pain management for three days were evaluated for EBP and hypertension (adjustment of patients treatment or using nitroglycerine 10 mg patch in persisting hypertension) were recorded.

The primary outcome was the efficacy of analgesia (VAS < 4) in the first 48 hours. The secondary outcomes were pain score, EBP was performed if failure to relieve pain after 3 days.

### 2.5. Sample Size Calculation

G\*Power 3.1.9.2 (Universitat Kiel, Germany) was used to calculate the sample size. The sample size was calculated based on 1) the expected success of treatment (our primary outcome) was ranged between 65% and 95%, 0.05 [5]  $\alpha$  error, 3, 80% power of the study, group ratio 1:1, and three cases was additionally allocated to each group to overcome dropout.

### 2.6. Statistical analysis

SPSS v25 (IBM, Chicago, IL, USA) was used to conduct the statistical analysis The normality of data distribution was evaluated using the Shapiro-Wilks test and histograms. Quantitative parametric data were presented as mean and standard deviation (SD) and

were analyzed using the unpaired student t-test. Non-parametric quantitative data were presented as median and interquartile range (IQR), Mann-Whitney test was used. Qualitative data were presented in frequencies and percentages and were analyzed by chi-square (X<sup>2</sup>) and Fisher's Exact tests. Two tails P value  $\leq 0.05$  was considered statistically significant.

### 3. Results

In this trial, 87 cases were assessed for eligibility. Sixty patients were allocated into two equal groups. All allocated patients were eligible for analysis during follow-up (Figure 1).

Patient's demographic data, duration of surgery, time from spinal anesthesia till headache were insignificantly different between both groups. Table 1

Onset of action in group SPB was significantly quicker with a median value [IQR] 20.5[11.5–28] minutes compared to group MT with a median value [IQR] 155[92.5–287.5] minutes (P value = 0.001). Table 2

Duration of analgesia was significantly longer in group SPB with a median value [IQR] 48[48–48] (hours) compared to group MT with a median value 33 [0–48] (P value = 0.03). Table 2

Block efficacy was significantly higher in group SPB (86.7%) than group MT (60.0%) (P = 0.039). Table 2

VAS score was significantly lower in group SPB compared to group MT at 30 min, 1 h, 2 h, 6 h, 12 h, 24 h and was insignificantly different at baseline and 48 h. Table 3

As regard adverse effects as nausea occurred in 7 (23.3%) patients in group MT and 5 (16.67%) patients in group SPB, vomiting in six patients in group MT and 2 (6.67%) in group SPB.

Nausea and vomiting were insignificantly different between both groups.

Other adverse effect as, cheek hematoma, local anesthetic toxicity, postoperative epistaxis, tingling, hypertension, and hypoesthesia of the palate did not occur. Table 4

### 4. Discussion

For a long period of time, the SPB block was used for treating headaches of various etiologies. Anesthesiologists have traditionally had a difficult time managing PDPH. Not only PDPH has increased the patient's misery, but it also has increased the hospital stay. Recently, the SPB has been successfully performed in patients with PDPHs [16].

SPB can be conducted trans nasally, transorally, subzygomatically, or laterally infratemporally. Trans nasal is the simplest, least invasive technique that can be performed at the bedside [12].

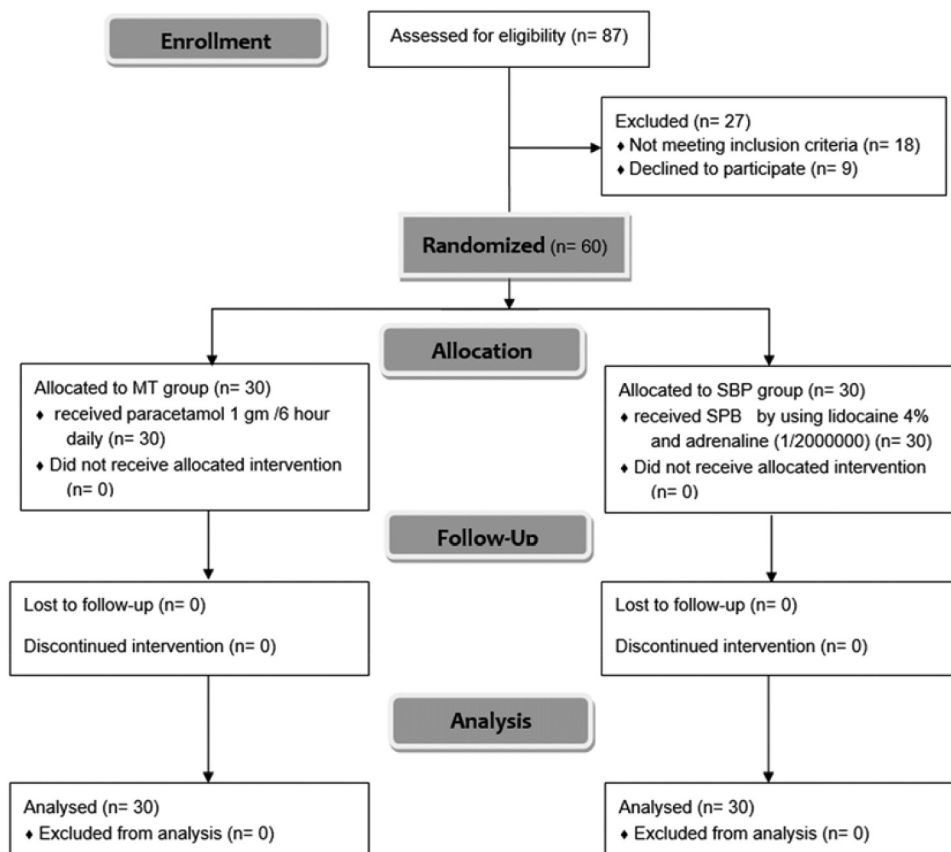


Figure 1. Consort flow diagram of the participants through each stage of the trial.

**Table 1.** Patient characteristics of the studied groups.

	Group MT (n = 30)	Group SPB (n = 30)	P value
Age (years)	41.67 ± 12.53	38.53 ± 13.55	0.356
BMI (kg/m <sup>2</sup> )	26.99 ± 5.76	29.24 ± 5.89	0.139
Sex			0.792
	Male 17 (56.7%)	19 (63.3%)	
	Female 13 (43.3%)	11 (36.7%)	
ASA physical status			0.784
	I 19 (63.3%)	21(70.0%)	
	II 11 (36.7%)	9 (30.0%)	
Duration of surgery (min)	88.6 ± 19.27	96.0 ± 16.06	0.110
Time from spinal anesthesia till PDPH (hours)	28.5 ± 10.63	31.6 ± 10.03	0.245

Data are presented as mean ± SD or frequency (%), MT: medical treatment, SPB: Sphenopalatine ganglion block BMI: Body mass index, ASA: American Society of Anesthesiologists, PDPH: post dural puncture headache.

**Table 2.** Analgesia, need for EBP, and patient satisfaction of the studied groups.

	Group MT (n = 30)	Group SPB (n = 30)	P value
Onset of analgesia (min)	155 (92.5–287.5)	20.5 (11.5–28)	0.001*
Treatment efficacy	18 (60.0%)	26 (86.7%)	0.039*
The need for EBP	14 (46.7%)	5 (16.7%)	0.025*
Succeeded EBP	6 (42.9%)	3 (60.0%)	0.628
Patient satisfaction	4 [1–4]	4 [4,5]	0.009*
	Group MT (n = 18)	Group SPB (n = 26)	
Duration of analgesia (hours)	33 (0–48)	48 (48–48)	0.03*

Data are presented as median [IQR], frequency (%), MT: medical treatment, SPB: Sphenopalatine ganglion block, EBP: Epidural blood patch, \*: significant as P value <0.05.

**Table 3.** VAS score of the studied groups.

	Group MT (n = 30)	Group SPB (n = 30)	P value
Baseline	8.5 [8,9]	9 [8–10]	0.232
30 min	7 [6–8]	2 [2,3]	0.001
1 h	5.5 [4–7]	2.5 [1–3]	0.001
2 h	5 [4–6]	2 [2,3]	0.001
6 h	3 (1.25–5)	1 (0–2)	0.006
12 h	3 [1–4]	1 (1–2.75)	0.017
24 h	3.5 [1–5]	2 (0–3)	0.014
48 h	3.5 [1–6]	3 [2,3]	0.662

Data were presented as median [IQR], MT: medical treatment, SPB: Sphenopalatine ganglion block, VAS: Visual Analogue Scale.

**Table 4.** Adverse effect of the studied groups.

	Group MT (n = 30)	Group SPB (n = 30)	P value
Nausea	7(23.33%)	5(16.67%)	0.759
Vomiting	6(20.00%)	2(6.67%)	0.734
LA toxicity	0 (0%)	0 (0%)	--
Technique complications	0 (0%)	0 (0%)	--

Data were presented as median [IQR], MT: medical treatment, SPB: Sphenopalatine ganglion block, LA: local anesthesia

The SPB produces analgesia in quicker onset and longer duration of analgesia compared to traditional measures. It can prevent the need for an EBP, an invasive procedure combined with complications [12]. The SPB was effective to relieve pain resulting from PDPH and it is regarded as a safe operation because the only contraindications are local nasal infections and fractures of the base of the skull [17].

Lidocaine 4% solution (local anesthetic) acts at sodium ion channels on the interior surface of nerve cell membranes. Because lidocaine is a weak base with a dissociation constant (pKa) of 7.7, implying that lidocaine has a faster onset of action than other local anesthetic with higher pKa values [18]. Addition of adrenaline to lidocaine substantially doubled the time required to resolve the blockage.

Adrenaline was more effective in prolonging the duration of action of drugs with a shorter duration of action, such as lidocaine [19].

In our study, analgesia showed significant earlier onset of action and longer duration in group SPB than in group MT. This agreed with Puthenveetil et al. [20] who allocated patients to either group MT who had paracetamol 1 g 8 hourly IV for a day or group SPB who received with 2% lignocaine and stated that onset of analgesia was significantly quicker in group SPB compared to group MT.

The present study reported that VAS score was significantly lower in group SPB than group MT. Also, SPB demonstrated superior outcomes in terms of pain relief as mentioned by Patel et al. [21] who presented 72 patients and they classified PDPH patients into two categories. The first group (33 patients) had bilateral SPB in Obstetric patients and found that after one hour, patients in the SPB group experienced significant pain reduction than other group.

Further, Puthenveetil et al. [20] according to the study, when mean pain scores were compared between the two groups, the mean pain score in group MT gradually decreased until it reached a value of 4 after 4 hours and remained there thereafter, whereas in group SPB after the block was performed, the median pain score remained at 4 throughout the period of trial (P value<0.001).

In our study, efficacy of block was significantly higher in group SPB (86.7%) than group MT(60.0%). In Cohen et al. [22] who stated that with 13 patients with moderate-to-severe PDPH, submitted to bilateral SPB for resolution of the symptomatology. Among the allocated patients, 11 (84.6%) presented effective pain relief after this technique, while the remaining two patients has been required EBP for treating of PDPH.

Kent and Mehaffey [23] presented a case report of three parturient with PDPH, who were offered a bilateral transnasal SPB. All three cases had effective pain relief and none of them needed a salvage EBP.

Our study presented that the efficacy of block was significantly higher in group SPB than group MT due to usage of lidocaine 4% and adrenaline, Thus, SPB could be utilized well as an initial model in the management of PDPH to provide quick pain relief.

Limitations: The study was in a single center. The sample size was relatively small to prove the secondary outcomes (as the need for EBP was insignificantly



different between both groups). Further trials are needed to show the role of repeating the block in failed block cases.

## 5. Conclusions

SPB is an effective method with shorter onset and longer duration of analgesia and lower VAS score compared to medical treatment for PDPH in orthopedic patients.

## Disclosure statement

No potential conflict of interest was reported by the author(s).

## ORCID

Amany Mohamed Abotaleb  <http://orcid.org/0000-0002-6538-4928>

Mohammed Said ElSharkawy  <http://orcid.org/0000-0003-0814-6728>

Hussen Gamal Almawardy  <http://orcid.org/0000-0001-6666-5927>

## References

- [1] Weji BG, Obsa MS, Melese KG, et al. Incidence and risk factors of postdural puncture headache: prospective cohort study design. *Perioper Med.* 2020;9(1):1–6.
- [2] Lavi R, Rowe JM, Avivi I. Lumbar puncture: it is time to change the needle. *Eur Neurol.* 2010;64(2):108–113.
- [3] Suri H, Ailani J. Cluster Headache: a review and update in treatment. *Curr Neurol Neurosci Rep.* 2021;21(7):1–9.
- [4] Puthenveetil N, Rajan S, Mohan A, et al. Sphenopalatine ganglion block for treatment of post-dural puncture headache in obstetric patients: an observational study. *IJA.* 2018;62(12):972–977.
- [5] Oedit R, van Kooten F, Bakker SLM, et al. Efficacy of the epidural blood patch for the treatment of post lumbar puncture headache BLOPP: a randomised, observer-blind, controlled clinical trial [ISRCTN 71598245]. *BMC Neurol.* 2005;5(1):12.
- [6] Zhang S, Yuan D, Tan G. Neurological involvement in primary systemic vasculitis. *Front Neurol.* 2019;10:1–10.
- [7] Cardoso JM, Sá M, Graça R, et al. Sphenopalatine ganglion block for postdural puncture headache in ambulatory setting. *Rev Bras Anesthesiol.* 2017;67(3):311–313.
- [8] Nair AS, Rayani BK. Sphenopalatine ganglion block for relieving postdural puncture headache: technique and mechanism of action of block with a narrative review of efficacy. *Korean J Pain.* 2017;30:93–97.
- [9] Zhou J, Guo P, Guo Z, et al. Fluid metabolic pathways after subarachnoid hemorrhage. *J Neurochem.* 2022;160(1):13–33.
- [10] Assaf A, Hillerup S, Rostgaard J, et al. Technical and surgical aspects of the sphenopalatine ganglion (SPG) microstimulator insertion procedure. *Int J Oral Maxillofac Surg.* 2016;45(2):245–254.
- [11] Bičanić I, Hladnik A, Džaja D, et al. The anatomy of orofacial innervation. *Acta Clin Croat.* 2019;58(Suppl 1):35–41.
- [12] Nair AS, Rayani BK. Sphenopalatine ganglion block for relieving postdural puncture headache: technique and mechanism of action of block with a narrative review of efficacy. *Korean J Pain.* 2017;30(2):93–97.
- [13] Nagib M, Hood P, Matteo J. Sphenopalatine ganglion block: treatment of migraine and trigeminal neuralgia associated with multiple sclerosis. *Cureus.* 2020;12:1–6.
- [14] Youssef HA, Abdel-Ghaffar HS, Mostafa MF, et al. Sphenopalatine ganglion versus greater occipital nerve blocks in treating post-dural puncture headache after spinal anesthesia for cesarean section: a randomized clinical trial. *Pain Physician.* 2021;24:443–451.
- [15] Lybecker H, Djernes M, Schmidt JF. Postdural puncture headache (PDPH): onset, duration, severity, and associated symptoms. An analysis of 75 consecutive patients with PDPH. *Acta Anaesthesiol Scand.* 1995;39(5):605–612.
- [16] Kaye AD, Motejunas MW, Cornett EM, et al. Emerging novel pharmacological non-opioid therapies in headache management: a comprehensive review. *Curr Pain Headache Rep.* 2019;23(8):53.
- [17] Channabasappa SM, Manjunath S, Bommalingappa B, et al. Transnasal sphenopalatine ganglion block for the treatment of postdural puncture headache following spinal anesthesia. *Saudi J Anaesth.* 2017;11(3):362–363.
- [18] Bahar E, Yoon H. Lidocaine: a local anesthetic, its adverse effects and management. *Medicina (B Aires).* 2021;57(8):1–10.
- [19] Creighton CM, Lamont L. Local anesthetics. *Manual of Equine Anesth Analg.* 2022: 232–243
- [20] Puthenveetil N, Rajan S, Mohan A, et al. Sphenopalatine ganglion block for treatment of post-dural puncture headache in obstetric patients: an observational study. *Indian J Anaesth.* 2018;62(12):972–977.
- [21] Patel P, Zhao R, Cohen S, et al. Sphenopalatine ganglion block (spgb) versus epidural blood patch (ebp) for accidental postdural puncture headache (pdph) in obstetric patients: a retrospective observation: 145. *Pain Med.* 2016;17:400–401.
- [22] Cohen S, Sakr A, Katyal S, et al. Sphenopalatine ganglion block for postdural puncture headache. *Anaesthesia.* 2009;64(5):574–575.
- [23] Kent S, Mehaffey G. Transnasal sphenopalatine ganglion block for the treatment of postdural puncture headache in the ed. *Am J Emerg Med.* 2015;33(11):1–2.