



Effectiveness of Ultrasound Guided Erector Spinae Plane Block Compared to Ultrasound Guided Modified Pectoral Nerves Block in Modified Radical Mastectomy: A Randomized Single Blinded Study

Mohamed Elsaid Abdel Fattah^a, Osama Sayed Ibrahim^b, Nevine Mahmoud Gouda^a and Mohamed Mohamed Abdel-Hak^a

^aAnesthesia, Surgical ICU and Pain Management Department, Faculty of Medicine, Cairo University, Cairo, Egypt; ^bAnesthesia, Surgical ICU and Pain Management Department, National Cancer Institute, Cairo University, Cairo, Egypt

ABSTRACT

Background: Approximately, 40–60% of breast surgeries are associated with severe acute pain. The goal of this work was to compare the analgesic effectiveness and safety between erector spinae plane block (ESPB) and modified pectoral nerve block (MPECB) in patients having modified radical mastectomy (MRM).

Methods: This randomized single blinded study included 60 adult female aged 18–65, American Society of Anesthesiologists (ASA) I, II, III patients with body mass index between 20 and 35 kg/m² who underwent MRM under general anesthesia (GA). Patients were divided into two equal groups. ESPB group received ESPB 30 mL levobupivacaine 0.25%, MPECB group received MPECB 10 ml levobupivacaine 0.25%. Blocks were done before induction of GA. Mean arterial blood pressure (MAP) and heart rate (HR) and numeric rating scale (NRS) were measured at PACU, 2, 4, 8, 12, 16, 20 and 24 h postoperatively, postoperative nausea and vomiting (PONV), assessed on a four-point verbal scale.

Results: Postoperative morphine consumption was significantly lower in MPECB group than in ESPB group. Numeric pain scale scores were significantly lower in MPECB patients both at rest and during movement than ESPB groups. Ramsey score in MPECB patients had better sedation scores in the first 4 h post-operative than ESPB group. Patients who received MPECB showed less PONV, but it was statistically insignificant and intramuscular hematoma was insignificantly higher in MPECB group.

Conclusions: MPECB provides safe and more effective analgesia in MRM compared to ESPB in the form of lower postoperative morphine consumption and low NRS scores.

ARTICLE HISTORY

Received 12 February 2022
Revised 15 March 2022
Accepted 22 September 2022

KEYWORDS

Erector spinae plane block; modified pectoral nerves block; modified radical mastectomy

1. Introduction

Breast cancer is the most frequent cancer among women [1]. Approximately, 40–60% of breast surgery patients endure severe acute postoperative pain, with over 10% of patients experiencing severe pain for 6–12 months (post mastectomy pain syndrome) [2]. Severe pain may lead to create long-term disability, disrupt sleep, and interfere with everyday activities; this results in adhesive capsulitis of the shoulder (frozen shoulder) or complicated regional pain syndrome (causalgia) and altered sensibility, putting a financial strain on the health-care system [3].

Intraoperative and postoperative pain is usually managed by opioids but is usually linked with adverse effects including prolonged sedation, respiratory depression, and postoperative nausea and vomiting (PONV) [4].

In an attempt to mitigate the adverse impacts of parenteral opioids, thoracic epidural analgesia and paravertebral block became the most effective regional breast surgery procedures [5]. Both approaches,

however, can result in major problems such pneumothorax, spinal cord injury, and incompatibility with pre-existing anticoagulant or antiplatelet medication, as well as hemodynamic instability [6].

The ultrasound (US)-guided erector spinae plane block (ESPB) was primarily mentioned in 2016, and it has since been used to manage acute and chronic thoracic pain. In a para spinal facial plane block, a local anesthetic administered the erector spinae muscle deep while the thoracic transverse processes are superficial. There are few contraindications in doing the ESPB because the injection site is far from the pleura, main blood arteries, and spinal cord. The injected local anesthetic medicine blocks the ventral and dorsal rami of spinal nerves in the paravertebral area [7].

Other regional approaches for intraoperative and postoperative pain control of MRM have been developed in the previous decade. Intercostal nerve blocks, pectoral nerve blocks (PECS 1 and 2), and serratus anterior plane block are among the treatments that

seek to be more effective and have less issues than the gold standard techniques [8].

The modified pectoral nerve block (MPECB) is a peripheral method that consists of two parts: PECS I and PECS II. The intercostobrachial nerve, four intercostal nerves (nerves III to VI), and the long thoracic nerve are all blocked. Because it incorporates both motor and sensory nerve blocks without the sympathetic block associated with paravertebral and epidural blockades, it is a simple and rapid-acting block that reduces perioperative discomfort in major breast cancer surgeries [9].

We hypothesized this study according to the same mechanism of action as paravertebral block (gold standard for intra and post-operative pain management in MRM) to compare between both ESPB and MPECB; therefore, this trial was established to determine the analgesic's efficacy and safety between both ESPB and MPECB in patients who underwent modified radical mastectomy (MRM).

2. Materials and methods

This randomized single blinded study included 60 adult females aged 18–65, American Society of Anesthesiologists (ASA) I, II, III patients who underwent MRM under general anesthesia (GA). All patients had written informed consent. The trial was carried out after approval of the National Cancer Institute's Ethical Committee at Cairo University in Egypt (MS-285-2021).

Exclusion criteria was patient refusal, known sensitivity to drug used in the study, pregnancy, and chronic pain.

2.1. Randomization and blindness

A computer-generated program (permuted block technique) was used by a statistician not related to patient management to randomize and allocate the patients in a parallel manner into two equal groups (each of 30 patients); ESPB group received ESPB (30 mL levobupivacaine 0.25%) and MPECB group received MPECB (10 ml levobupivacaine 0.25%).

The random allocation number was properly concealed in opaque closed envelopes opened during the preoperative assessment visit and after signing the trial consent. All the regional anesthetic techniques were done by an experienced anesthesiologist, not related to group assignment or data collection. The medications used in the regional anesthetic techniques were prepared according to the group by a pharmacist who was not related to the data management. The assessor of the study outcomes was unaware of the group assignment and did not witness the blocks while being performed.

Blocks were done before induction of GA in operation room under complete aseptic technique with the Fujifilm Sonosite M-Turbo US system.

All patients were monitored continuously throughout the surgical operation. Non-invasive blood pressure, electrocardiography, peripheral oxygen saturation, and end tidal carbon dioxide were measured throughout the duration of the surgical procedure.

2.2. The modified pectoral nerve block

The patient was put supine. The first rib was discovered by a high-frequency linear probe put caudal to the lateral third of the clavicle to determine the location of the axillary arteries beneath the pectoralis major and subclavian muscles. After that, the probe was advanced distally towards the axilla until it reaches the third rib. The pectoralis minor is elevated above the serratus anterior in this position, and the clavipectoral fascia continues as Gerdy's ligament into the axilla. We injected 10 ml of levobupivacaine 0.25% into the interfascial plane between the two pectoralis muscles and 20 ml into the interfascial plane between the pectoralis minor and the serratus anterior muscles using an in-plane medial-to-lateral approach once the structures have been identified with US.

2.3. Erector spinae plane block

The block level was T5. The probe was placed transversely on the back to detect the T5 transverse process tip, which was shown as flat, squared-off acoustic shadows with only a faint image of the pleura visible. Epidermis, then subcutaneous, trapezius, erector spinae muscle was seen; the needle was to be introduced passing all these layers guided by the US till reaching the transverse process below erector spinae muscle. After aspiration, 30 mL levobupivacaine 0.25% was delivered to avoid intravascular injection, and separation was seen.

2.4. Anesthesia management

2.4.1. Induction

A regimen of IV 2 µg/kg fentanyl and IV 2 mg/kg propofol were used to induce GA. Rocuronium (0.5 mg/kg IV) were used to help with tracheal intubation.

Keeping the patient anesthetized by sevoflurane inhalation, rocuronium 0.1 mg/kg was given every half an hour as maintenance dosages. As a part of multimodal analgesia, IV paracetamol 1 gm and IV ketorolac 30 mg were given.

Patients were monitored in the post-anesthesia care unit (PACU). Multimodal analgesia was administered postoperatively as follows: 1 gm paracetamol IV for 6 h, Ketorolac 30 mg IV for 8 h.

The mechanical ventilation setting was adjusted to keep the end-tidal CO₂ between 30 and 35 mmHg.

Extubation was done after full recovery of consciousness.

2.5. Measurements

Mean arterial blood pressure (MAP) and heart rate (HR) were recorded throughout the surgery. Numeric rating scale (NRS), MAP, and HR were measured at PACU, 2, 4, 8, 12, 16, 20 and 24 h postoperatively.

PONV, assessed on a four-point verbal scale (none = no nausea, mild = nausea but no vomiting, moderate = vomiting one attack, severe = vomiting >one attack) as morphine side effects. 0.1 mg/kg of IV ondansetron was given to patients with moderate or severe PONV. Postoperative urine retention and pruritus, respiratory depression, and block complications as intramuscular hematoma was assessed. Overall patient satisfaction was recorded.

The primary outcome was postoperative total morphine consumption in 24 h. The secondary outcomes were NRS, side effects, and overall patient satisfaction.

2.6. Sample size

For sample size calculations, the MedCalc® version 12.3.0.0 "Ostend, Belgium" was used. The sample was calculated based on a 95% power with 5% α error. A prior study [10] showed that the mean of morphine consumption in ESPB group was 16.7 ± 7.21 compared to PECS block group of 10.7 ± 3.12 . A minimum sample size of 48 cases was sufficient to detect such a difference. Assuming a 5% drop-out rate, the sample size was 60 cases, divided into two groups.

2.7. Statistical analysis

SPSS v26 was used for the statistical analysis (IBM Inc., Chicago, IL, USA). Quantitative parametric data were presented as mean and standard deviation (SD) and were analyzed by unpaired student t-test. Quantitative non-parametric data were presented as median and interquartile range (IQR) and were analyzed by Mann Whitney-test. The Chi-square test or Fisher's exact test was used to analyze qualitative variables when they were reported as frequency and percentage. It was considered statistically significant if the two-tailed *P*-value was less than 0.05.

3. Results

In this trial, 93 cases were assessed for eligibility. Sixty patients were allocated into two equal groups. All allocated patients were eligible for analysis during follow-up [Figure 1].

Demographic data were insignificantly different between both groups [Table 1].

Postoperative morphine consumption was significantly lower in MPECB group with a median value of 6 (3–6) compared to ESPB group with a median value of 0 (0–3) (*P*-value <0.001) [Table 2].

Intraoperative and postoperative HR and MAP were not significantly different between both study groups [Figure 2].

NRS scores were significantly lower in MPECB patients in both at rest and during movement than ESPB group [Figure 3].

Ramsey score at immediate postoperative and after 2 h was insignificantly lower in MPECB group than in ESPB group [Table 3].

Patients who received MPECB showed less PONV, but it was statistically insignificant. Intramuscular hematoma occurred in 3 (10.0%) in MPECB group and block-related complications were insignificantly different between both study groups [Table 4].

Overall patient satisfaction was insignificantly higher in MPECB group in 26 (86.66%) patients compared to ESPB group in 22 (73.33%) patients (*P*-value = 0.166) [Table 4].

4. Discussion

The use of US to guide performance of these interfacial blocks proved to be safer and associated with fewer side effects when compared to the gold standard technique [11].

Pre-emptive analgesia was used for control of postoperative pain and the inhibition of central sensitization and chronic neuropathic pain by using analgesia preoperatively [12].

In this study, we are comparing a relatively new block (ESPB) which was to an older block (MPECB) which is composed of two blocks: PECs I block and PECs II.

In our study, postoperative morphine consumption was significantly lower in MPECB group than in ESPB group.

In agreement with our results, Sinha et al. [9] found that total morphine consumption in 24 h was less in PECS II group (4.40 ± 0.94 mg) compared to group ESP (6.59 ± 1.35 mg; *P* = 0.000). The mean duration of analgesia was significantly higher in PECS than in ESPB group and the mean requirement of morphine was significantly lower in PECS group than in ESPB group. However, there was a larger volume of local anesthetic in PECS II group (25 ml 0.2% ropivacaine) compared to only 20 ml 0.2% ropivacaine in ESPB group contributing to the observed better analgesic effect; another type of local anesthetic was used other than the one used in the present study.

In agreement with our results, Gad et al. [10] divided patients into two equal groups, comparing ESPB against MPECB in MRM. 0.5 μ /kg dexmedetomidine was added in the injectate used in both blocks. The

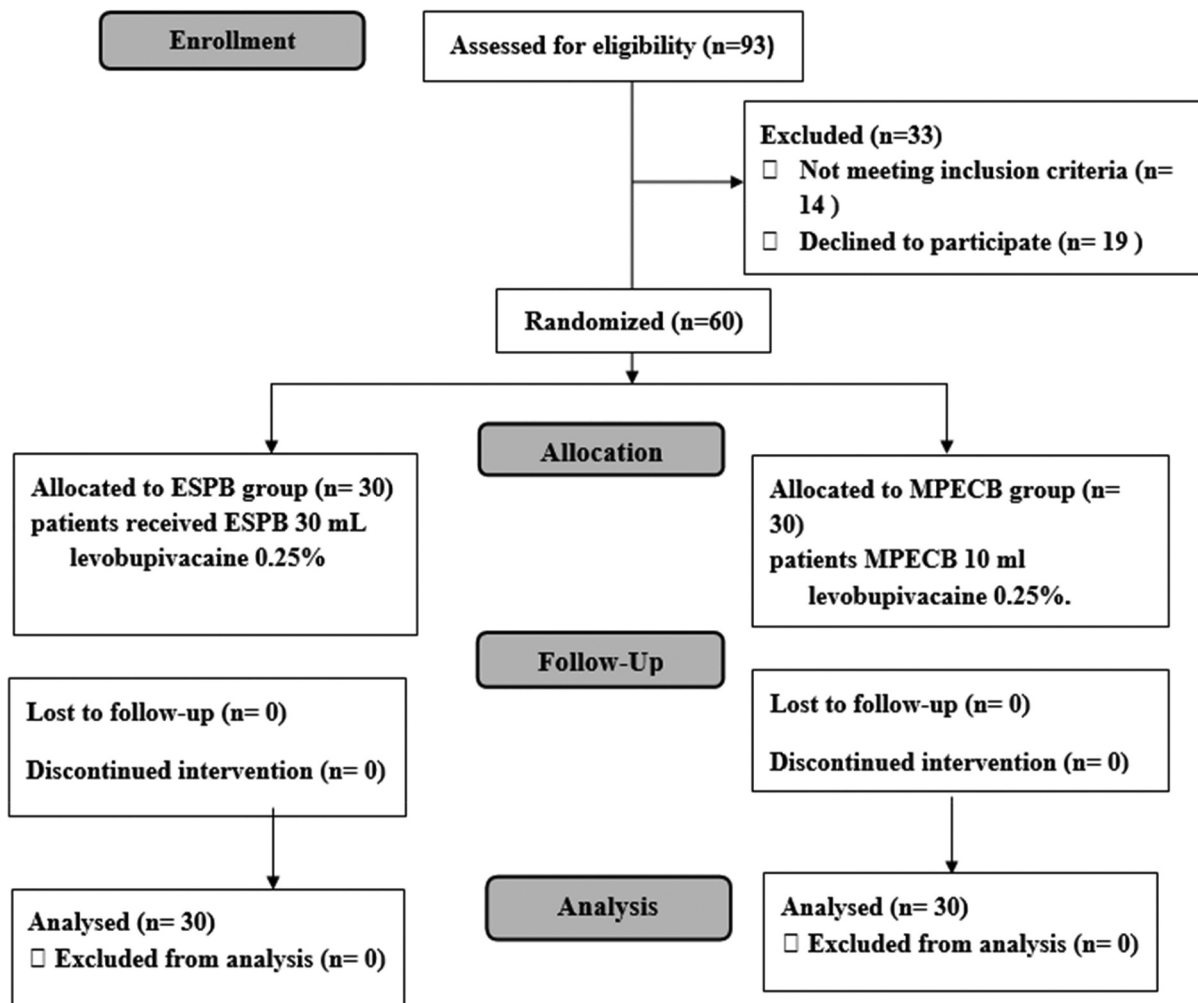


Figure 1. The randomized trial flow diagram, including enrollment, intervention allocation, and analysis.

Table 1. Demographic data of patients enrolled in this study.

| | ESPB group (n = 30) | MPECB group (n = 30) | P-value |
|--------------------------|------------------------|-------------------------|---------|
| Age (years) | 49.67 ± 9.18 | 45.57 ± 10.25 | 0.108 |
| Weight (kg) | 80.40 ± 13.85 | 79.80 ± 8.78 | 0.842 |
| Height (m) | 1.67 ± 0.06 | 1.68 ± 0.06 | 0.433 |
| BMI (kg/m ²) | 28.77 ± 5.00 | 28.17 ± 3.17 | 0.584 |
| ASA | | | 0.287 |
| I | 16 (53.3%) | 15 (50.0%) | |
| II | 10 (33.3%) | 14 (46.7%) | |
| III | 4 (13.3%) | 1 (3.3%) | |
| Side of | | | 0.299 |
| Right | 14 (46.7%) | 18 (60.0%) | |
| Left | 16 (53.3%) | 12 (40.0%) | |
| MRRM | | | |
| Left | 16 (53.3%) | 12 (40.0%) | |
| Duration of surgery | | | |

Data are represented by mean ± SD or frequency (%), ESPB: erector spinae plane block, MPECB: modified pectoral nerve block, BMI: body mass index, MRRM: modified radical mastectomy.

following was observed: postoperative morphine consumption in MPECB group was significantly lower than in ESPB group (P -value 0.001) and requested less analgesia postoperatively than ESPB patients.

Moreover, Altiparmak et al. [13] found that opioid consumption postoperatively was significantly lower in PECS group than in ESPB group.

In contrast to our results, Morioka et al. [14] found no statistically significant changes in postoperative additional analgesic administration between PECS group and ESPB group. This contradiction may be because they did the PECS block after induction of

Table 2. Postoperative morphine consumption between both groups.

| | ESPB group (n = 30) | MPECB group (n = 30) | P-value |
|---|------------------------|-------------------------|---------|
| Patient required morphine | 22 (80.00%) | 13 (43.33%) | 0.003* |
| Postoperative morphine consumption (mg) | 6 (3–6) | 0 (0–3) | <0.001* |

Data presented as Mean ± SD, Median (IQR), frequency (%), ESPB: erector spinae plane block, MPECB: modified pectoral nerve block *: significant as p -value ≤0.05.

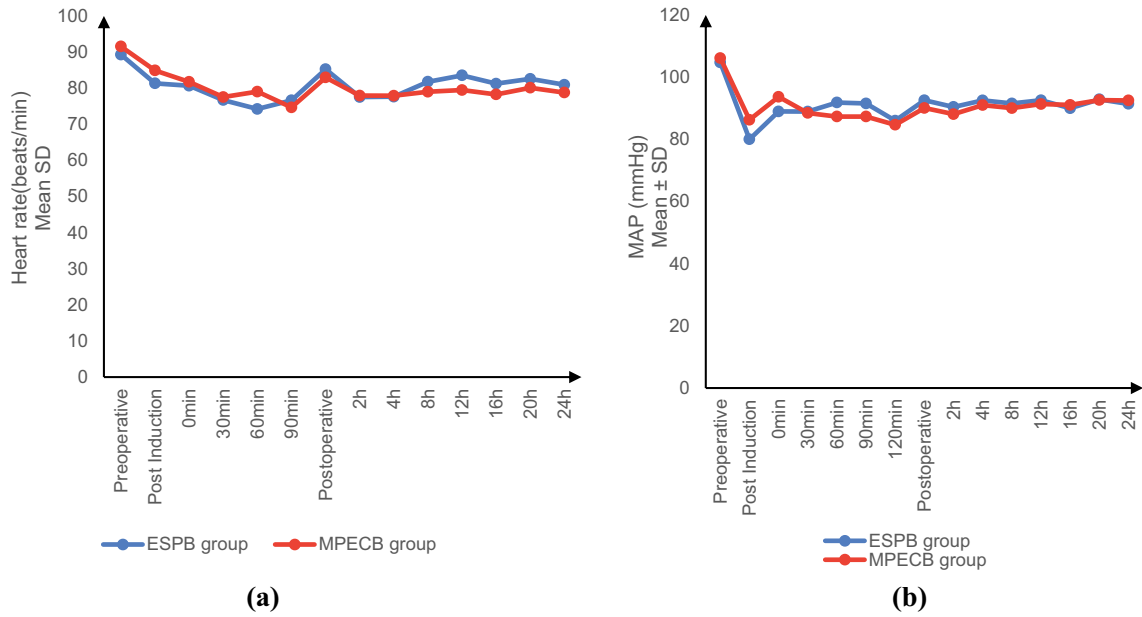


Figure 2. Preoperative, intraoperative, and postoperative changes in (a) heart rate (beats/min) and (b) Mean arterial blood pressure (mm Hg).

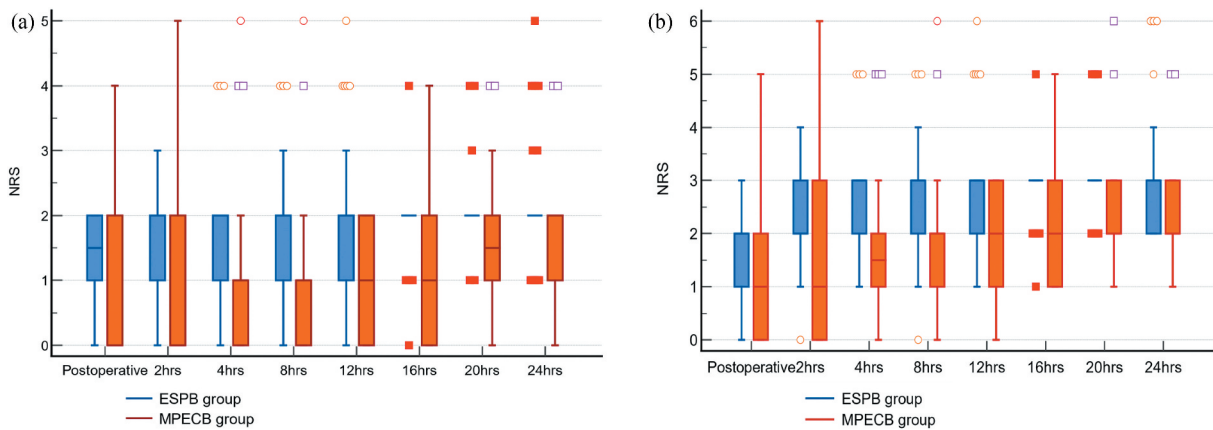


Figure 3. Numeric pain rating scale at rest (a) and at movement (b).

Table 3. Ramsey score in both study groups.

| | ESPB group (n = 30) | MPECB group (n = 30) | P-value |
|------|---------------------|----------------------|---------|
| PACU | 2.40 ± 0.62 | 2.33 ± 0.55 | 0.661 |
| 2 h | 2.03 ± 0.18 | 2.00 ± 0.00 | 0.326 |
| 4 h | 2.00 ± 0.00 | 2.00 ± 0.00 | – |
| 8 h | 2.00 ± 0.00 | 2.00 ± 0.00 | – |
| 12 h | 2.00 ± 0.00 | 2.00 ± 0.00 | – |
| 16 h | 2.00 ± 0.00 | 2.00 ± 0.00 | – |
| 20 h | 2.00 ± 0.00 | 2.00 ± 0.00 | – |
| 24 h | 2.00 ± 0.00 | 2.00 ± 0.00 | – |

Data are represented by mean ± SD, ESPB: erector spinae plane block, MPECB: modified pectoral nerve block.

GA and therefore they did not have enough time to determine the quality of the block prior to induction of anesthesia. However, in the current study, PECS block was done preoperatively and after 20 min from performing the block, the pinprick test was performed to determine the sensory block in comparison to the unblocked contralateral side. Unsuccessful

block was defined as a delayed sensory loss in the site of surgery more than 20 min after injection of local anesthetics. Second, they observed that PECS II is unable to block the anterior cutaneous branches of the intercostal nerves, which innervate the surrounding sternum; thus, PECS II may not be able to block the internal mammary region in the surgical site [14].

On the other hand, Blanco et al. [15] stated that the modified approach (PECS II + PECS I) allows for blocking of anterior intercostal nerves, which is not possible with pectoralis minor block I.

In the current study, intraoperative and postoperative HR and MAP were not significantly different between both study groups.

In agreement with our results, Sinha et al. [9] found that HR and MAP in the patients in PECS II group and ESPB group were similar intraoperatively.

In current study, patients who received MPECB showed less PONV, but it was statistically insignificant.

Table 4. Complications and satisfaction in both studied groups.

| | | ESPB group (n = 30) | MPECB group (n = 30) | P-value |
|--|---------------|------------------------|-------------------------|---------|
| PONV | Mild | 4 (13.3%) | 3 (10.0%) | 0.671 |
| | Moderate | 2 (6.7%) | 2 (6.7%) | |
| | Severe | 2 (6.7%) | 1 (3.3%) | |
| Postoperative urine retention and Pruritus | | 0 (0.0%) | 0 (0.0%) | – |
| Postoperative respiratory depression | | 0 (0.0%) | 0 (0.0%) | – |
| Postoperative Intramuscular hematoma | | 0 (0.0%) | 3 (10.0%) | 0.237 |
| block complications | | | | |
| Overall satisfaction | Satisfied | 22 (73.33%) | 26 (86.66%) | 0.166 |
| | Not satisfied | 8 (26.66%) | 4(13.33%) | |

Data presented as frequency (%), ESPB: erector spinae plane block, MPECB: modified pectoral nerve block PONV: Postoperative nausea and vomiting.

Block-related complications were insignificantly different between both study groups. Sinha et al. [9] found that there was no incidence of adverse effects in PECS II group and ESP group.

In the current study, NRS scores were significantly lower in MPECB patients in both at rest and during movement than in ESPB group.

In agreement with our results, Gad et al. [10] found that MPECB group had statistically significant less pain scores compared to ESPB group.

Moreover, Sinha et al. [9] found that NRS scores were significantly lower in PECS group at all time intervals except at 8 and 12 h.

Study limitations: The study was a single-blinded study with small sample size. Systemic anesthetic or one of the gold standard regional procedures in breast surgery were not included in our study (Thoracic Epidural Analgesia or Thoracic Paravertebral Block). Long-term effect on chronic pain was not followed up.

5. Conclusion

US-guided MPECB provides safe and effective analgesia in MRM compared to US-guided ESPB in the form of lower postoperative morphine consumption and low NRS scores.

Disclosure statement

No potential conflict of interest was reported by the authors.

References

- [1] Lei S, Zheng R, Zhang S, et al. Breast cancer incidence and mortality in women in China: temporal trends and projections to 2030. *Cancer Biol Med.* 2021;18:900–909.
- [2] De Cassai A, Bonvicini D, Correale C, et al. Erector spinae plane block: a systematic qualitative review. *Minerva Anesthesiol.* 2019;85(3):308–319.
- [3] Sharma SP, Moe-Nilssen R, Kvåle A, et al. Predicting outcome in frozen shoulder (shoulder capsulitis) in presence of comorbidity as measured with subjective

- health complaints and neuroticism. *BMC Musculoskelet Disord.* 2017;18(1):380–387.
- [4] Singh NP, Makkar JK, Kuberan A, et al. Efficacy of regional anesthesia techniques for postoperative analgesia in patients undergoing major oncologic breast surgeries: a systematic review and network meta-analysis of randomized controlled trials. *CJA.* 2022;69:1–23.
 - [5] Razek AA, AbouAllo MM, Abd El Hamid SA, et al. Ultrasound-guided pectoral nerve blocks versus serratus intercostal plane block in breast surgeries. *Res Opinion Anesthesia Intensive Care.* 2018;5(3):162–169
 - [6] Gregoretto C, Decaroli D, Miletto A, et al. Regional anesthesia in trauma patients. *Anesthesiol Clin.* 2007;25(1):99–116.
 - [7] Kot P, Rodriguez P, Granell M, et al. The erector spinae plane block: a narrative review. *Korean J Anesthesiol.* 2019;72(3):209–220.
 - [8] Blanco R. The 'PECS block': a novel technique for providing analgesia after breast surgery. *Anaesthesia.* 2011;66(9):847–848.
 - [9] Sinha C, Kumar A, Kumar A, et al. Pectoral nerve versus erector spinae block for breast surgeries: a randomised controlled trial. *Indian J Anaesth.* 2019;63(8):617–622.
 - [10] Gad M, Abdelwahab K, Abdallah A, et al. Ultrasound-guided erector spinae plane block compared to modified pectoral plane block for modified radical mastectomy operations. *Anesth Essays Res.* 2019;13(2):334–339.
 - [11] Lewis SR, Price A, Walker KJ, et al. Ultrasound guidance for upper and lower limb blocks. *Cochrane Database Syst Rev.* 2015;2015:Cd006459.
 - [12] Raja SD, Shetty AP, Subramanian B, et al. A prospective randomized study to analyze the efficacy of balanced pre-emptive analgesia in spine surgery. *Spine J.* 2019;19:569–577.
 - [13] Altıparmak B, Korkmaz Toker M, Uysal A, et al. Comparison of the effects of modified pectoral nerve block and erector spinae plane block on postoperative opioid consumption and pain scores of patients after radical mastectomy surgery: a prospective, randomized, controlled trial. *J Clin Anesth.* 2019;54:61–65.
 - [14] Morioka H, Kamiya Y, Yoshida T, et al. Pectoral nerve block combined with general anesthesia for breast cancer surgery: a retrospective comparison. *JA Clin Rep.* 2015;1(1):1–15.
 - [15] Blanco R, Fajardo M, Parras Maldonado T. Ultrasound description of PECS II (Modified Pecs I): a novel approach to breast surgery. *Rev Esp Anesthesiol Reanim.* 2012;59(9):470–475.