



Egyptian Society of Anesthesiologists
Egyptian Journal of Anaesthesia

www.elsevier.com/locate/egja
www.sciencedirect.com



Research Article

Efficacy of ultrasound-guided oblique subcostal transversus abdominis plane block after laparoscopic sleeve gastrectomy: A double blind, randomized, placebo controlled study



Mohamed Ibrahim ^{a,*,1}, Hossam El Shamaa ^{b,2}

^a Department of Anesthesiology, Zagazig University, Egypt

^b Department of Anesthesiology, Cairo University, Egypt

Received 6 December 2013; revised 13 January 2014; accepted 17 January 2014
Available online 20 February 2014

KEYWORDS

Ultrasound-guided OSTAP;
Port site infiltration;
Laparoscopic sleeve
gastrectomy;
Opioids consumption

Abstract *Introduction:* Pain control in the morbidly obese can be especially challenging because of increased sensitivity to opioid-induced respiratory depression. The subcostal transversus abdominis plane block is associated with a large area of spread (T7-L1). The aim of the study was to test the hypothesis that US-guided TAP blocks can reduce opioid consumption during the first 24 h after of laparoscopic sleeve gastrectomy in comparison with port site local anesthetic infiltration and systemic analgesia.

Method: Sixty-three ASA II/III adult patients listed for elective laparoscopic sleeve gastrectomy were randomly allocated in one of three groups: Group I (OSTAP) received bilateral OSTAP block. Group II (Local) received local anesthetic infiltration at trocar port sites. Group III (Control) placebo group received TAP block and port site infiltration by same volumes of sterile normal saline. Twenty-four hours postoperative morphine consumption, the dose of fentanyl (μg) required during surgery, equivalent morphine dose in the recovery unit (PACU) and first morphine dose were recorded. The quality of analgesia is assessed by Visual Analogue Scale for 24 h at rest and movement.

* Corresponding author. Address: Jeddah Clinic Hospital – Kandarrah, AL Kandarrah, Airport Street, P.O. Box 115, Jeddah 21411, Saudi Arabia. Tel.: +966 2 667 5000/2 669 4896; fax: +966 0126323142.
E-mail addresses: mibrahim72@windowslive.com (M. Ibrahim), hossamshamaa@yahoo.com (H.E. Shamaa).

¹ Tel.: +20 1223777755/+966 565842048.

² Tel.: +20 966500984921.

Peer review under responsibility of Egyptian Society of Anesthesiologists.



Production and hosting by Elsevier

Results: The mean opioid consumptions in PACU showed significant difference between the three groups, $P = 0.02$. The mean 24 h morphine consumption showed statistically significant difference between groups (P value < 0.001). Significant differences were found between both OSTAP and Local groups with control group ($P < 0.001$) and also between OSTAP and Local groups ($P = 0.02$). Pain score of OSTAP group was significantly lower than local infiltration group at 6 and 4 h at rest and movement respectively. OSTAP group had faster extubation time than other groups. Postoperative nausea and vomiting were not significant between groups. No signs or symptoms of local anesthetic systemic toxicity or complications were detected.

Conclusion: Oblique subcostal TAP block is a good alternative for providing analgesia during the postoperative period. The block is easily performed using ultrasound guidance. It is safe, provides effective analgesia with significant morphine-sparing effect with reduced side-effects of opioids.

© 2014 Production and hosting by Elsevier B.V. on behalf of Egyptian Society of Anesthesiologists.
Open access under [CC BY-NC-ND license](#).

1. Introduction

The transversus abdominis plane (TAP) block is a local anesthetic block used to provide analgesia to the anterior and lateral abdominal wall. Rafi [1] and McDonnell et al. [2] were the first to describe this novel abdominal field block. They described an anatomical landmark technique and provided evidence of blockade to the mid/lower thoracic and upper lumbar spinal nerves as they travelled in the fascial plane between the transversus abdominis and internal oblique muscles.

Hebbard et al. [3] have subsequently described an ultrasound-guided approach to the TAP block. This technique involves injection of local anesthetic through the lumbar triangle of Petit into the plane between the transversus abdominis and the internal oblique muscles to block the thoracolumbar intercostal nerves.

Over the last decade, TAP blockade has been shown to improve patient comfort and decrease systemic narcotics requirements postoperatively [4–6].

Despite the less invasive nature of laparoscopic sleeve gastrectomy, pain can be moderated to severe in the immediate postoperative period [7]. Pain control in the morbidly obese can be especially challenging because of increased sensitivity to opioid-induced respiratory depression [8]. The transversus abdominis plane (TAP) block has been demonstrated to improve pain related outcomes after laparoscopic cholecystectomy, open appendectomy, and cesarean section [9–13].

Three approaches for the TAP block, subcostal, mid-axillary and lumbar triangle of Petit, were compared [14]. The subcostal approach was associated with a larger area of spread (T7-L1), whereas it was only that T10-L1 was achieved with the other two approaches [15]. The transversus plane may also be used for analgesia superior to the umbilicus and as far superiorly as the xyphoid process by deposition of the local anesthetic into the transversus plane along the costal margin [16].

This oblique subcostal TAP block is performed by identifying the rectus abdominis near the costal margin and imaging the underlying transversus abdominis muscle. The transversus can usually be followed right along from near the xyphoid to the iliac crest in one line, this is called the sub-costal oblique line. For subcostal TAP block the needle is introduced several cm from the probe to come into view in plane to the probe [17].

Few studies evaluated the analgesic efficacy of ultrasound (US)-guided TAP blocks in the setting of bariatric laparoscopic sleeve gastrectomy [18,19].

For that we planned to test the hypothesis that US-guided TAP blocks can reduce opioid consumption during the first 24 h after of laparoscopic sleeve gastrectomy in comparison with the conventional analgesic techniques, specifically port insertion site local anesthetic infiltration and systemic analgesia.

2. Patient and method

After approval from our faculty ethical committee, written informed consent was gained from 70 ASA II/III adult (> 18 years old) at least 72 h before surgery by the surgical and anesthetic team. Patients were listed for elective laparoscopic sleeve gastrectomy with body mass index (BMI) more than 35 and incisions for port sites at or above thoracic T 10 dermatome. Patients allergic to amino-amide local anesthetics, the presence of coagulopathy, local skin infection at the needle puncture sites, preoperative chronic dependence upon opioid medication, patients with that need and conversion of laparoscopic to open surgery or manipulations more than expected with more tissue trauma, American Society of Anesthesiologists (ASA) Class 4 and Class 5 were excluded.

All procedures were performed by the same surgeon. All patients received general anesthesia for the surgery. Preoperative investigations have been done according to the local protocol designed to evaluate the bariatric patients. It included hemoglobin, hematocrit levels, blood sugar levels, serum urea, serum electrolytes, liver function tests, coagulation profile, respiratory functional tests, chest radiogram, ECG, abdominal and barium meal. A multidisciplinary team: nutritionist, cardiologist, radiologist, which constantly takes care of the preoperative assessment of the bariatric patients. Patients have been assessed for hypertension, coronary disease, diabetes mellitus, obstructive apnea syndrome, or other medical conditions that all have been stabilized before the surgical procedure.

All patients were oriented about the use of visual analogue score (VAS) (10 cm marked line in which 0 cm referred to no pain and 10 cm to the worst pain imaginable). Patients are asked to place a mark on the line to express the amount of pain that they are experiencing at a particular time. The distance between the end labeled “no pain” and the mark placed by the patient is measured in centimeters, to give a pain score between 0 and 10 cm.

Patients were blinded to the treatment group, as was the anesthetist involved in postoperative data collection. All patients received pre-oxygenation with O_2 100% for 5 min.

The study was randomized, double-blinded, and placebo controlled. A sealed envelope randomization system was employed to allocate patients between three groups where:

Group I (OSTAP) received bilateral OSTAP block using a standardized dose of 30 ml of bupivacaine hydrochloride 0.25% using (Marcain, Astra Zeneca, UK) in each side plus port site infiltration of 20 ml sterile normal saline.

Group II (Local) received bupivacaine hydrochloride 0.25% infiltration (total volume of 30 ml) divided equally between port sites plus bilateral OSTAP block using 30 ml of normal sterile saline per block.

Group III (Control) placebo group received TAP block and port site infiltration by same volumes of sterile normal saline.

A standardized general anesthetic regime was employed, consisting of propofol (2.5 mg/kg), fentanyl (2 mcg/kg), and cisatracurium (0.15 mg/kg), with intraoperative non-opioid analgesia of paracetamol (15–20 mg/kg) Lornoxicam (*zefo^R*, *NYCOMED Austria*) 8 mg slowly IV. Volatile agent used was sevoflurane 1.0–1.2 minimum alveolar concentration in N₂O/oxygen (fractional inspired oxygen of 0.35). Fentanyl boluses were given in response to changes in hemodynamics (more than 15% increase in MAP and HR than the baseline values taken after induction by 5 min). Fentanyl boluses were repeated every 5 min if these parameters remain 15% above their baseline values. The total dose of fentanyl required was documented.

Ventilator settings were adjusted to keep EtCO₂ between 35 and 40 mmHg and SPO₂ between 94 and 100%. Positive end expiratory pressure PEEP of 5 cm H₂O has been added to all patients. The operation was done in reverse trendelenburg position, with lower limbs abducted. Pneumoperitoneum was initiated to 14 mmHg intraabdominal pressure (IAP). At the end of the procedure the neuromuscular block has been reversed with neostigmine 0.04 mg/kg and atropine 0.01 mg/kg at 50% responsiveness to TOF stimulus. Before extubation, all patients received dexamethasone 8 mg IV, and ondansetron 4 mg IV for antiemetic prophylaxis. Extubation with patient awake and with TOF response at 90% of control.

Three subcostal and one periumbilical port sites were employed in all cases. The OSTAP block was performed by the anesthetists with expertise in ultrasound-guided trunk blocks, whereas port-site infiltration was performed by the surgeon. The block was performed under ultrasound guidance (SIEMENS ACUSON P300, Siemens Medical Solutions USA Inc.). The linear probe (7–13 MHz ultrasound transducer) was placed in the midline of the abdomen 2 cm below the xiphisternum and moved right laterally along the subcostal margin (Fig. 1A) and the rectus abdominis and transverses abdominis muscles were identified (Fig. 1B)

A 150-mm, 22-G echoplex block needle, VYGON was then inserted in plane through the rectus muscle 2–3 cm medial to the probe. Once the tip of the needle was visualized in between the rectus muscle and transversus abdominis muscle (Fig. 1C), and negative pressure aspiration was demonstrated, 30 ml/site bupivacaine 0.25% was deposited within the plane and hydrodissection was noted.

Following aspiration, port-site infiltration was performed preoperatively after induction of anesthesia in the usual manner bupivacaine hydrochloride 0.25% infiltration (total volume of 30 ml) divided equally between port sites.

The skin incision was made 15 min after bilateral OSTAP blocks or port site infiltration in the three groups.

Postoperatively, patients were transferred to the postanesthesia care unit (PACU) for 1 h. Recovery nurses were blinded to the group intervention. In the PACU, patients received intravenous analgesia of fentanyl 25–50 mcg IV or morphine 1–2 mg IV or pethidine 20–40 mg IV boluses. Administration of analgesia was decided if pain described as moderate or severe when asked about their pain intensity on a scale of mild, moderate, or severe. The criteria for discharge from the PACU were 1-absent or mild pain 2-absence of nausea and vomiting, 3-hemodynamic stability, and 4-alert or appropriately responsive to voice. On discharge, all patients had achieved a modified Aldrete score of ≥ 9 [20].

In the surgical ward, all patients received our hospital standard for postoperative analgesia regimen for such cases. It consists of paracetamol 1000 mg IV every 6 h, Lornoxicam (*zefo^R*) 8 mg slowly IV every 12 h and, in cases of moderate to severe pain, morphine 2–6 mg IV every 3 h as needed. Antiemetic medications included IV, ondansetron 4 mg IV or metoclopramide 10 mg IV if needed.

Pain severity was measured using VAS. The time points of pain assessment were performed at 0 (recovery), 2, 4, 6, 12, and 24 postoperatively. Pain scores were measured at rest and on movement (patients asked to flex their knees).

Outcome data were collected by an anesthetist who was blind to the treatment groups.

The primary outcome was 24 h postoperative morphine consumption on the ward which was calculated as the morphine dose equivalent to the opioid analgesia consumed (using opioid:morphine equivalents of 100 mcg i.v. fentanyl to 10 mg i.v. morphine; 75–100 mg IV pethidine to 10 mg i.v. morphine [21].

The dose of fentanyl (μ g) required during surgery, equivalent morphine dose in the recovery unit (PACU) and first morphine dose also recorded.

Secondary outcome include the quality of analgesia as determined by comparing visual pain analogue scores (VPAS) preoperatively and every 2 h after surgery for 24 h. Extubation time, postoperative nausea and vomiting at PACU and 24 h postoperative. OSTAP block complications (including local anesthetic systemic toxicity, vascular injury, intravascular injection of local anesthetic, local hematoma and visceral injury), surgical time (defined as the time between the incision and the completion of the dressing) were also documented.

Statistical analysis was performed using IBM-SPSS 20 software. The sample size of 21 per group was calculated assuming a 30% reduction in opioid use to provide 90% power at a significance level of 5%. Allowing for a 20% drop-out rate, we planned to recruit a total of 70 subjects. The 30% assumed reduction was a conservative estimate based upon prior studies which show 45–70% reductions in postoperative morphine requirement following TAP blockade [4,5,9,11,22,23].

Data are presented as median and interquartile range (IQR) or with mean and SD as appropriate. Morphine consumption did not follow a normal distribution and were compared with the Kruskal–Wallis test.

Categorical data were analyzed using the chi square (χ^2) test. Normally distributed data were analyzed using a repeated-measures general linear model analysis of variance (ANOVA).

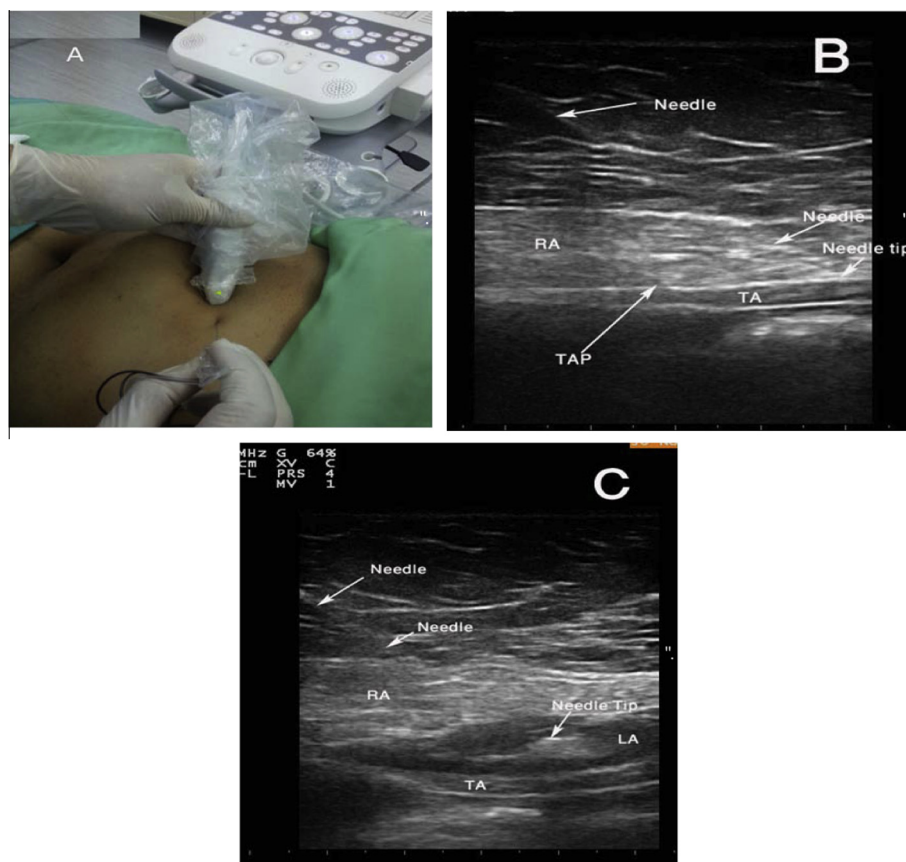


Figure 1 (A) Placement of ultrasound probe for subcostal TAP blocks, (B) ultrasound anatomy and needle placement TAP (transversus abdominis plan) at the fascia layer between TA (transversus abdominis muscle) and RA (rectus abdominis muscle), (C) ultrasound image during injection of local anesthetic.

3. Results

Seventy patients were scheduled and data from 63 were included for analysis. Two patients refused inclusion in the study, four patients excluded due to protocol violation and one canceled. Patient characteristics were similar between groups (Table 1).

3.1. Opioid consumption

The control group required more intraoperative rescue fentanyl as compared to the OSTAP block and port site

infiltration groups (Table 2). Median fentanyl consumption (intraoperatively) was 40 μ g (IQR: 20–80 μ g) in the control group compared with 20 μ g (IQR: 0–60 μ g) in both OSTAP and Local groups but statistically insignificant ($P = 0.099$).

The mean opioid consumptions in PACU (Table 2) are (OSTAP 4.38 \pm 0.45 mg [95% CI, 2.43–4.33], Local 4.33 \pm 0.52 mg [95% CI, 3.2–5.4] and control 6.19 \pm 0.44 mg [95% CI, 4.6–20.7]; $P = 0.02$).

The mean 24 h morphine consumption (Table 2) showed statistically significant difference between groups (P value < 0.001 by using one way ANOVA). Significance confirmed by Kruskal–Wallis test due to abnormal distribution of data. Comparison between groups using independent t -test revealed

Table 1 Demographic data.

	Group I (N = 21)	Group II (N = 21)	Group III (N = 21)	P value [#]
Age (year)	38.26 \pm 10.19	36.67 \pm 9.34	37.44 \pm 11.34	0.76
Sex (F/M) ^a	16/5	15/6	14/7	0.79
ASA II/III ^a	16/5	13/8	14/7	0.59
BMI (kg/m ²)	48.52 \pm 10.39	46.14 \pm 9.26	46.4 \pm 8.65	0.65
Duration of surgery (min)	119.34 \pm 10.39	113.93 \pm 18.39	120.55 \pm 13.34	0.293

Values are given as mean \pm standard deviation.

^a Analysis done by using chi square test.

[#] P value > 0.05 = insignificant.

Table 2 Comparison of analgesic efficacy of oblique subcostal transversus abdominis plane block and port site infiltration in laparoscopic sleeve gastrectomy.

	OSTAP group (<i>N</i> = 21)	Local group (<i>N</i> = 21)	Control group (<i>N</i> = 21)	<i>P</i> value
Intraoperative rescue fentanyl ^a	20 [20–60], 29.5 ± 21.9	20 [0–60], 30.4 ± 21.5	60 [20–80], 40.0 ± 21.5	0.099 ^c
PACU morphine analgesia (mg)	4.38 ± 0.45	4.33 ± 0.52	6.19 ± 0.44	0.02 ^c I vs. II = 0.179 ^b I vs. III < 0.001 ^b II vs. III = 0.01 ^b
24 h Morphine	16.76 ± 2.7	18.38 ± 4.2	24.76 ± 5.0	< 0.001 ^c I vs. II = 0.02 ^b I vs. III < 0.001 ^b II vs. III < 0.001 ^b
First morphine dose (min)	340 ± 72	266 ± 33	67 ± 23	< 0.001 ^c

P value < 0.05 is considered significant.

^a Values are given as median (IQR), mean ± SD.

^b Analysis between groups done using independent *t*-test.

^c Analysis done using one way ANOVA.

significant differences between both OSTAP and Local groups with control group ($P < 0.001$). Significant difference was found also between OSTAP and Local groups ($P = 0.02$).

Values of 24 h morphine consumption in the interquartile range between 25th and 75th percentiles and median values are illustrated in Fig. 2.

Time to extubation was significantly shorter in the OSTAP block and Local groups in comparison with control group (10.4 ± 2.1 , 9.8 ± 3.4 , and 14.5 ± 1.3 respectively $P < 0.05$). No side-effects related to OSTAP block were observed 24 h after the block.

3.2. Pain assessment

The mean VAS at rest (Fig. 3A) of Local group became significantly higher than OSTAP group after 6 h. The VAS at rest was significantly lower in the OSTAP block group than in the control group at 0, 2, 4, 6, 12, and 24 h. The VAS at movement (Fig. 3B) at 4 and 6 h was lower in the OSTAP block than local group.

No significant differences were recorded among the three study groups regarding incidence of postoperative side effects of morphine. Despite the higher incidence of postoperative nausea and vomiting in control group (22.5.4.2% and 28.3%) than in OSTAP group (12.8% and 10.4%) and Local group (15.2% and 16.5%) at PACU and 24 h respectively, it did not reach a statistical significance (P value was 0.22 and 0.18 respectively).

No signs or symptoms of local anesthetic systemic toxicity or complications were detected.

4. Discussion

Although obesity surgery is expensive, it is highly competitive to the cost of obesity concomitant diseases. The current study was designed to evaluate the analgesic efficacy of US-guided OSTAP in comparison with trocar port site infiltration by bupivacaine 0.25% and placebo control group in patients undergoing laparoscopic sleeve gastrectomy. Analgesic efficacy measured by intra- and postoperative narcotic consumption

and assessment of pain using VAS at rest and movement for 24 h.

The study suggests that pre-incisional US-guided OSTAP blocks provide analgesic benefit that is proved by reduced PACU and 24 h morphine consumption in patients undergoing laparoscopic sleeve gastrectomy when compared with trocar insertion site local anesthetic infiltration and systemic analgesia.

Most studies revealed the efficacy of TAP blocks by reducing postoperative opioid requirement, lower pain scores, and/or reduction in opioid-related side effects. A meta-analysis of 7 studies (180 cases and 184 controls) demonstrated an average reduction in 24-h morphine consumption of 22 mg in favor of TAP block patients compared with standard management. Furthermore, TAP blocks were associated with reduced early postoperative visual analog scores (VAS) both at rest and during mobilization. Postoperative sedation, as well as postoperative nausea and vomiting (PONV), was marginally reduced in patients with TAP blocks [24].

A major component of pain experienced by patients after abdominal surgery is originating from the abdominal wall incision [25].

Similarly, another meta-analysis by Charlton et al., demonstrated a significant reduction in 24-h morphine requirements of average 22 mg in TAP block patients compared to controls [26].

Several studies found that US-guided TAP blocks reduce pain scores in phase I recovery and at 24 h [10,11]. Other studies demonstrated that US-guided TAP blocks reduce morphine consumption during phase I recovery [9] and at 24 h [9,11], and reduce the incidence of postoperative nausea and vomiting at 30 min [11] when compared to systemic analgesia for patients undergoing laparotomy or laparoscopic surgery.

Albrecht et al. [27] compared OSTAP block with placebo together with local anesthesia infiltration of port sites in both groups for patients undergoing laparoscopic gastric banding. They concluded that bilateral OSTAP blocks do not provide additional analgesic benefit when added to trocar insertion site local anesthetic infiltration and systemic analgesia for laparoscopic gastric-bypass surgery.

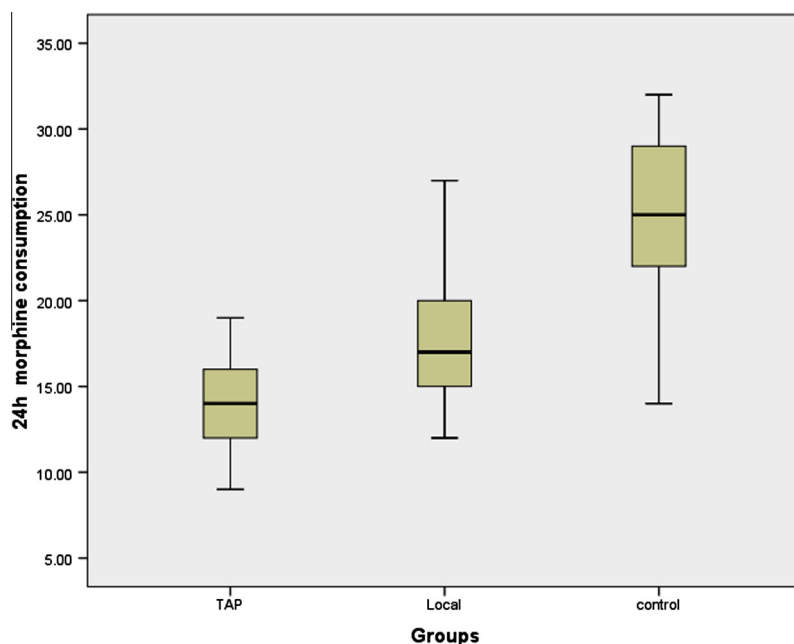


Figure 2 Values 24 h morphine consumption are shown on the left-hand axis. The upper and lower limits of the box show the limits of the interquartile range between 25th and 75th percentiles (9–19 mg for TAP, 12–27 mg for local groups and 14–32 mg for control group), and the dark middle horizontal line represents the median value (approx 14, 17 mg, and 25 mg respectively). The whiskers, extend to the extreme values of the sample.

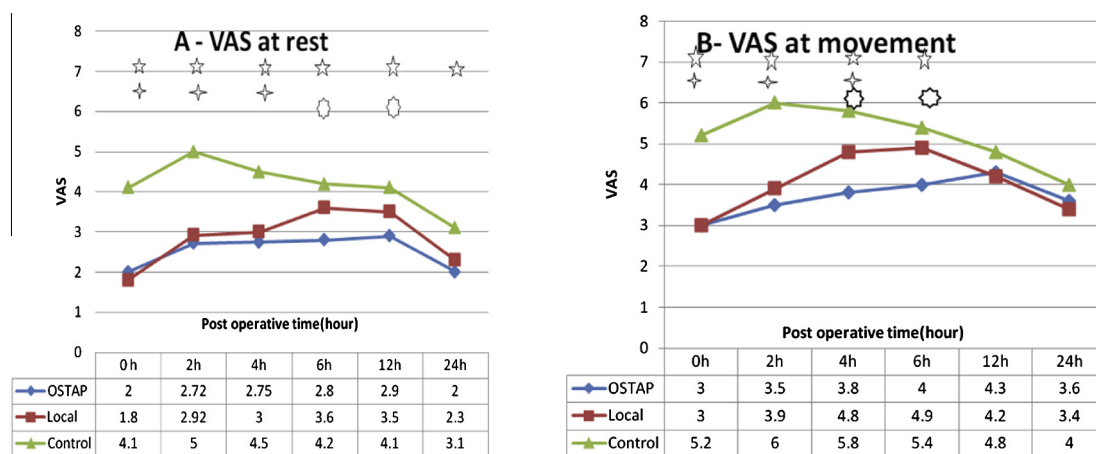


Figure 3 VAS at rest (A) and VAS at movement (B) change according to the time. OSTAP, oblique subcostal transversus abdominis plane. $\circ P < 0.05$ when comparing OSTAP with the local group. $\star P < 0.05$ when comparing OSTAP with the control group. $\dagger P < 0.05$ when comparing local with the control group.

Two other studies evaluated the feasibility and efficacy of TAP in bariatric laparoscopic procedures and concluded that USG-TAP as part of multimodal analgesic technique in morbidly obese patients undergoing laparoscopic gastric bypass reduces opioid requirement, improves pain score, decreases sedation, promotes early ambulation, and has greater patient satisfaction [18,19].

They attributed the reasons of the differences seen in their trial and studies supporting the analgesic efficacy of TAP blocks for laparoscopic surgery to that studies did not include trocar insertion site local anesthetic infiltration [9,10] and when

trocar site infiltration was added, TAP blocks might not offer any significant supplementary analgesic benefit.

We compared a OSTAP block to a placebo block and local anesthetic infiltration into the abdominal port hole wounds. Local anesthetic infiltration has an expected duration of 0–6 h [28], three other studies concluded that local anesthetics have a significant benefit after laparoscopic cholecystectomy, but the effect is small and of doubtful clinical relevance [28–30].

Niraj et al. [17] also documented that single shot injection can provide dynamic analgesia for 6–8 h.

These results came in agreement of our findings of reduced pain score with the OSTAP block, especially during the first 8 postoperative hours.

The VAS at rest was significantly lower in the OSTAP block group than in the control group at 0, 2, 4, 6, 12, and 24 h while VAS at rest of Local group became significantly higher than OSTAP group after 6 h. The VAS at movement at 4 and 6 h was lower in the OSTAP block than local infiltration group.

However, a major disadvantage of OSTAP block is the inability to block visceral pain, which can be substantial, both intra- and postoperatively [17].

Our results suggested that laparoscopic gastric sleeve may differ from other laparoscopic procedures due to associated moderate severe visceral pain, resulting from surgical manipulation of the stomach. Both TAP blocks and trocar insertion site infiltration are effective only for somatic pain of the abdominal wall and not this deep visceral pain.

Pharmacokinetic data during these techniques have never been measured, but recent data indicate that administration of local anesthetic between fascia layers is associated with fast absorption kinetics and high plasma levels of local anesthetics. Thus, an important prerequisite for a routine use of TAP block is the knowledge of these data and volume reduction studies where the 'optimal' volume for this regional anesthetic technique should be evaluated [31].

The total dose of local anesthetic (150 mg of bupivacaine) administered between both sides was lower than that previously suggested to be hazardous [32].

The systemic absorption and peak plasma levels of local anesthetic following TAP blocks in bariatric patients have never been examined. However, it seems plausible that morbid obesity may confer an additional margin of safety against local anesthetic systemic toxicity given the large potential volume of distribution.

The dose and volume of local anesthetic infusion needed to produce efficient analgesia in TAP block is not yet agreed. Being not highly vascular, the volume of local anesthetic used in this study was probably safe to infuse in the transversus abdominis plane [33,34].

We had encountered some technical difficulties including that are mostly due to obesity related large subcutaneous fat and wasting of the abdominal musculature making identification of the anatomy more difficult and limitations in needle movement.

To overcome these problems taller needle was used and a test of 5 ml normal saline injection was done before local anesthetic injection to confirm accurate position of needle tip in TAP plane with visualized hydrodissection. We did not measure sedation score.

Shin et al. [35] did not find a difference in morphine consumption between patients receiving single-shot TAP block and control patients undergoing abdominal hysterectomy. They used only 20 ml of ropivacaine 0.375% as a single shot. This dose might have been insufficient to produce long-lasting analgesia which was produced in the current study by the continuous infusion of levobupivacaine.

In conclusion oblique sub costal TAP block is a good alternative for providing analgesia during the postoperative period. The block is easily performed using ultrasound guidance. It is safe, provides effective analgesia with significant morphine-sparing effect with reduced side-effects of opioids.

Conflict of Interest

None declared.

References

- [1] Rafi AN. Abdominal field block: a new approach via the lumbar triangle. *Anaesthesia* 2001;56:1024–6.
- [2] McDonnell JG, O'Donnell BD, Tuite D, Farrell T, Power C. The regional abdominal field infiltration technique computerised tomographic and anatomical identification of a novel approach to the transversus abdominis neuro-vascular fascial plane. *Anesthesiology* 2004;101:A899.
- [3] Hebbard P, Fujiwara Y, Shibata Y, Royse C. Ultrasound guided transversus abdominis plane block. *Anaesth Intens Care* 2007;35(4):616–7.
- [4] McDonnell JG, O'Donnell BD, Curley GCJ, et al. The analgesic efficacy of transversus abdominis block after abdominal surgery: a prospective randomised controlled trial. *Anaesth Analg* 2007;104:193–7.
- [5] McDonnell JG, Curley G, O'Donnell B, Heffernan A, Power C, Laffey JG. The analgesic efficacy of transversus abdominis plane block after caesarean section: a prospective randomized controlled trial. *Anesth Analg* 2008;106:186–91.
- [6] Carney J, McDonnell JG, Ochana A, et al. The transversus abdominis plane block provides effective postoperative analgesia in patients undergoing total abdominal hysterectomy. *Anaesth Analg* 2008;107:2056–60.
- [7] Tufanogullari B, White PF, Peixoto MP, et al. Dexmedetomidine infusion during laparoscopic bariatric surgery: the effect on recovery outcome variables. *Anesth Analg* 2008;106:1741–8.
- [8] Benumof JL. Obesity, sleep apnea, the airway and anesthesia. *Curr Opin Anaesthesiol* 2004;17:21–30.
- [9] El-Dawlatly AA, Turkistani A, Kettner SC, et al. Ultrasound-guided transversus abdominis plane block: description of a new technique and comparison with conventional systemic analgesia during laparoscopic cholecystectomy. *Br J Anaesth* 2009;102:763–7.
- [10] Ra YS, Kim CH, Lee GY, et al. The analgesic effect of the ultrasound-guided transverse abdominis plane block after laparoscopic cholecystectomy. *Korean J Anesthesiol* 2010;58:362–8.
- [11] Niraj G, Searle A, Mathews M, et al. Analgesic efficacy of ultrasound-guided transversus abdominis plane block in patients undergoing open appendectomy. *Br J Anaesth* 2009;103:601–5.
- [12] Belavy D, Cowlshaw PJ, Howes M, Phillips F. Ultrasound-guided transversus abdominis plane block for analgesia after Caesarean delivery. *Br J Anaesth* 2009;103:726–30.
- [13] Abdallah FW, Chan VW, Brull R. Transversus abdominis plane block: a systematic review. *Reg Anesth Pain Med* 2012;37:193–209.
- [14] Milan Z, Tabor D, McConnell P, Pickering J, Kocarev M, du Feu F, et al. Three different approaches to transversus abdominis plane block: a cadaveric study. *Medicinski Glasnik* 2011;8:181–4.
- [15] Sivapurapu V, Vasudevan A, Gupta S, Badhe A. Comparison of analgesic efficacy of transversus abdominis plane block with direct infiltration of local anesthetic into surgical incision in lower abdominal gynecological surgeries. *J Anaesthesiol Clin Pharmacol* 2013;29(1):71–5.
- [16] Hebbard PD, Barrington MJ, Vasey C. Ultrasound-guided continuous oblique subcostal transversus abdominis plane blockade: description of anatomy and clinical technique. *Reg Anesth Pain Med* 2010;35(5):436–41.

- [17] Niraj G, Kelkar A, Powell R. Ultrasound-guided subcostal transversus abdominis plane block. *Int J Ultrasound Appl Technol Perioperative Care* 2010;1(1):9–12.
- [18] Sinha A, Jayaraman L, Punhani D. Efficacy of ultrasound-guided transversus abdominis plane block after laparoscopic bariatric surgery: a double blind, randomized, controlled study. *Obes Surg* 2013;23(4):548–53.
- [19] Wassef M, Lee YD, Levine JL, Ross RE, Guend H, Vandepitte C, Hadzic A, Teixeira J. Feasibility and analgesic efficacy of the transversus abdominis plane block after single-port laparoscopy in patients having bariatric surgery. *J Pain Res* 2013;6:837–41.
- [20] Aldrete JA. Modification to post anaesthesia score for use in ambulatory surgery. *J Perianaesth Nurs* 1998;13:148–55.
- [21] Sasada M, Smith S. *Drugs in anaesthesia and intensive care*. 3rd ed. Oxford: Oxford University Press; 2003.
- [22] Kadam RV, Field JB. Ultrasound-guided continuous transverse abdominis plane block for abdominal surgery. *J Anaesthesiol Clin Pharmacol* 2011;27:333–6.
- [23] Shibata Y, Sato Y, Fujiwara Y, Komatsu T. Transversus abdominis plane block. *Anesth Analg* 2007;105:883.
- [24] Petersen PL, Mathiesen O, Torup H, Dahl JB. The transversus abdominis plane block: a valuable option for postoperative analgesia? A topical review. *Acta Anaesthesiol Scand* 2010;54(5):529–35.
- [25] Tran TMN, Rozen W, Ashton M, Barrington M, Ivanusic J, Taylor G. Redefining the course of the intercostal nerves: a new understanding of the innervation of the anterior abdominal wall. *Clin Anat* 2008;21:325–33.
- [26] Charlton S, Cyna AM, Middleton P, Griffiths JD. Perioperative transversus abdominis plane (TAP) blocks for analgesia after abdominal surgery. *Cochrane Database of Systematic Reviews*, vol. 8.
- [27] Albrecht E, Kirkham KR, Endersby RVW, Chan VWS, Jackson T, Okrainec A, Penner T, Jin R, Brull R. Ultrasound-guided transversus abdominis plane (TAP) block for laparoscopic gastric-bypass surgery: a prospective randomized controlled double-blinded trial. *Obes Surg* 2013;23:1309–14.
- [28] Bisgaard T. Analgesic treatment after laparoscopic cholecystectomy: a critical assessment of the evidence. *Anesthesiology* 2006;104:835–46.
- [29] Boddy AP, Mehta S, Rhodes M. The effect of intraperitoneal local anesthesia in laparoscopic cholecystectomy: a systematic review and meta-analysis. *Anesth Analg* 2006;103:682–8.
- [30] Moiniche S, Jorgensen H, Wetterslev J, Dahl JB. Local anesthetic infiltration for postoperative pain relief after laparoscopy: a qualitative and quantitative systematic review of intraperitoneal, port-site infiltration and mesosalpinx block. *Anesth Analg* 2000;90:899–912.
- [31] Weintraud M, Lundblad M, Kettner S, et al. Ultrasound versus landmark-based technique for ilioinguinal–iliohypogastric nerve blockade in children: implication on plasma levels of ropivacaine. *Anesth Analg* 2009;108.
- [32] Griffiths JD, Barron FA, Grant S, et al. Plasma ropivacaine concentrations after ultrasound-guided transversus abdominis plane block. *Br J Anaesth* 2010;105:853–6.
- [33] Kotze A, Scale A, Howell S. Efficacy and safety of different techniques of paravertebral block for analgesia after thoracotomy: a systematic review and metaregression. *Br J Anaesth* 2009;103:626–36.
- [34] Joshi GP, Bonnet F, Shah R, Wilkinson RC, Camu F, Fischer B, et al. A systematic review of randomized trials evaluating regional techniques for postthoracotomy analgesia. *Anesth Analg* 2008;107:1026–40.
- [35] Shin HJ, Kim ST, Yim KH, Lee HS, Sim JH, Shin YD. Preemptive analgesic efficacy of ultrasound-guided transversus abdominis plane block in patients undergoing gynecologic surgery via a transverse lower abdominal skin incision. *Korean J Anesthesiol* 2011;61:413–8.