



Egyptian Society of Anesthesiologists  
Egyptian Journal of Anaesthesia

www.elsevier.com/locate/egja  
www.sciencedirect.com



Case report

# Retrieval of surgical blade by open thoracotomy – A case report of an iatrogenic complication



Anil Thakur, Kiranpreet Kaur \*, Garima Jain, Suresh K. Singhal, Jagdish Dureja, Susheela Taxak

Department of Anaesthesiology and Critical Care, Pt. B.D. Sharma PGIMS, Rohtak 124001, India

Received 8 March 2013; accepted 25 March 2014  
Available online 29 April 2014

## KEYWORDS

Foreign body thorax;  
Thoracotomy;  
Thoracoscopy

**Abstract** Presence of foreign body in thoracic cavity is very uncommon. Most common etiologies for the presence of such foreign bodies are accidental, traumatic or iatrogenic. We report the management of a case with a rare foreign body in the thorax i.e. surgical blade. While inserting ICD the surgical blade slipped from the scalpel and was sucked into the pleural cavity. FB migrated in the mediastinum and Contrast Tomographic scan showed elongated radio-opaque object of metallic density in the mediastinum, just abutting the superior vena cava. An immediate open thoracotomy was planned to retrieve the blade.

© 2014 Production and hosting by Elsevier B.V. on behalf of Egyptian Society of Anesthesiologists.  
Open access under [CC BY-NC-ND license](#).

## 1. Introduction

Presence of foreign body (FB) in thoracic cavity is very uncommon. Most common etiologies for the presence of such foreign bodies are accidental, traumatic-intentional or iatrogenic [1]. So far the literature has reported the presence of various blunt and sharp objects in the thorax. Sewing needles, hypodermic needles, acupuncture needles, and glass pieces are various sharp objects and wooden pieces, retained sponges are few of the blunt objects reported so far. Sharp objects can cause injury to pleura, lungs, heart, great vessels, and diaphragm and can also migrate into the abdominal cavity resulting in injury to vis-

ceral organs [1,2]. Several forms of acupuncture iatrogenia have been reported, including pneumothorax, hemorrhage, hematoma formation, hepatitis, abdominal aortic disruption, HIV transmission, cardiac tamponade, endocarditis, and death [3]. However, leaving the Blunt FB in the chest (either in the pleural cavity or extrapleurally) predispose the patient to the risk of potential infection in future and can even result in full-blown empyema in some of these patients [1]. We herein, report the management of a case with a rare foreign body in the thorax i.e. surgical blade having an unusual mode of penetration.

## 2. Case report

A 45 years old adult male with H/O chest trauma reported in another hospital with multiple rib fractures involving 8th, 9th and 10th ribs on right side. B/L Subcutaneous emphysema was present on face, neck and chest wall with an associated pneumothorax of the ipsilateral side. Immediate insertion of inter-

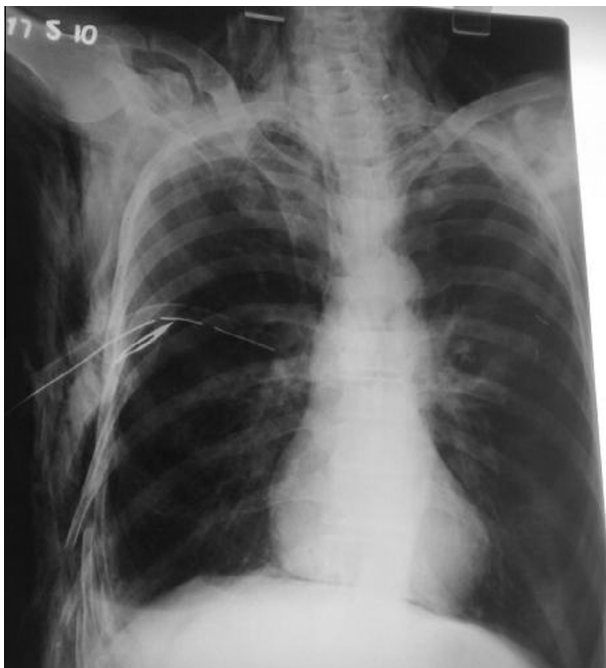\* Corresponding author. Address: 52/9J, Medical Enclave, Rohtak 124001, Haryana, India. Tel.: +91 1262 213171.

E-mail address: [kiranpreet72@rediffmail.com](mailto:kiranpreet72@rediffmail.com) (K. Kaur).

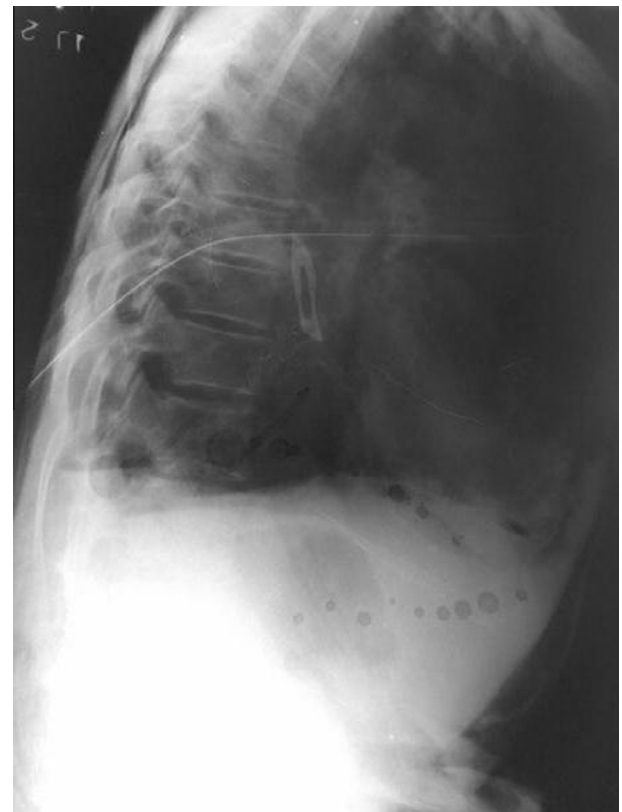Peer review under responsibility of Egyptian Society of Anesthesiologists.

costal drain (ICD) was planned. Small nick with surgical blade was given and ICD was inserted but the surgical blade slipped from the scalpel and was sucked into the pleural cavity. Chest roentgenogram was immediately taken, which showed blade in thorax near the chest wall along the ICD (fig. 1). Patient was subjected to local exploration under general anesthesia but the foreign body could not be retrieved possibly due to suspected migration of FB in the thoracic cavity. Follow-up chest radiograph showed scalpel blade near the vertebral column (fig. 2). Patient was then referred to the cardiothoracic department of our institution for further management. Patient underwent Contrast Tomographic scan (CT) which showed extensive bilateral subcutaneous emphysema with right sided hydropneumothorax and pneumomediastinum despite the presence of ICD. An elongated radio-opaque object of metallic density was seen in the mediastinum, just abutting the superior vena cava. An immediate open thoracotomy was planned to retrieve the blade lest it should penetrate major organs and vessels of thorax.

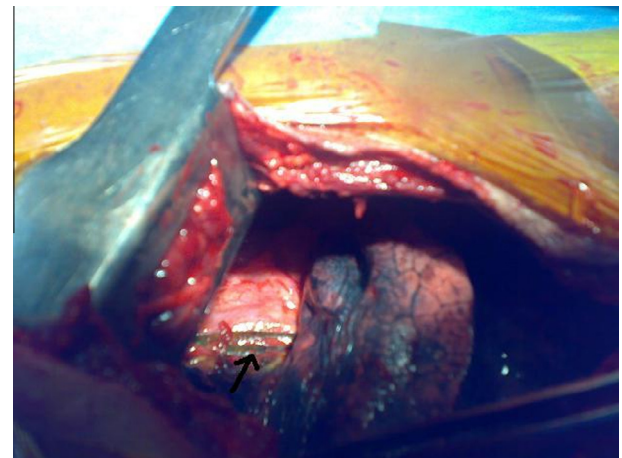
General Physical examination of the patient was remarkable for massive subcutaneous emphysema of face, neck, chest and abdominal wall and respiratory rate of 40 per minute. On arrival in the operating room intravenous line was secured with 16 gauge cannula. All monitoring devices were placed which included continuous electrocardiogram, O<sub>2</sub> saturation of arterial blood and arterial blood pressure. Patient was subjected to general anesthesia and left sided PVC double lumen tube of size 39 French gauge was inserted successfully. Patient was placed in left lateral position and right thoracotomy was commenced. After the thorax was opened right lung was collapsed by clamping the tracheal lumen. As the lung collapsed surgeon was able to locate the surgical blade which was lying in the mediastinum near the superior vena cava (fig. 3). No major injury involving lung, heart and great vessels was found except for mild contusions of right lung. Chest drain was



**Figure 1** Showing blade along the ICD.



**Figure 2** Migration of scalpel blade near the vertebral column.



**Figure 3** Surgical blade lying in the mediastinum marked with arrow.

inserted and thorax was closed. Patient was extubated and shifted to ICU with uneventful outcome.

### 3. Discussion

Retained foreign bodies (FBs) in the tracheobronchial tree, gastrointestinal tract, peritoneal cavity, and in various other locations have been the subject of many reports and reviews. In contrast, pleural cavity and chest wall have been rarely mentioned in this association. FBs located in the immediate proximity of major vessels, heart, or esophagus, and all sharp

FBs should be extracted, lest they penetrate and cause bleeding or damage to organs. However, the small and clean objects located in the periphery are well tolerated and can be left behind [1]. The foreign body, lying in proximity to the right coronary artery bears the potential risk of bleeding, embolization, endocarditis or pericarditis, surgical therapy is indicated in such patients in spite of the fact that patient is asymptomatic [4]. We planned to explore our patient, because of presence of sharp object and its proximity to superior vena cava.

The best way of extraction of FBs from the pleural cavity would be either thoracotomy or videothoracoscopy (VATS) [1]. Thoracoscopy has enjoyed a resurgence in popularity due to improvements in technology and instrumentation. The indications for thoracoscopy in the trauma patient include the use of thoracoscopy to evaluate possible diaphragmatic or vascular injury in the hemodynamically stable patient [5]. Compared to thoracotomy, VATS is reported to have fewer postoperative complications, better postoperative pain control, fewer wound and pulmonary complications, shorter time to resumption of normal activity and shorter chest tube duration time. Hemodynamic stability is a prerequisite for doing VATS [6]. Rapid improvements in endoscopic surgical technique and instrumentation have expanded the indications of videothoracoscopy in the diagnosis and treatment of diseases of the chest, but its use remains controversial in the trauma setting. Thoracotomy is indicated in patients who require the treatment for associated injuries along with suspected involvement of great vessel and heart where the use of thoracoscope is not recommended [7]. Open thoracotomy wide incision gives the surgeon excellent exposure and allows removal of the object under direct vision [8]. We planned open thoracotomy in our patient because of lacking facility of thoracoscope in emergency set up and to prevent iatrogenic injuries associated with removal of very sharp objects.

This case serves to remind readers that surgical blade is another sharp object that can iatrogenically enter thoracic cav-

ity while inserting the chest tube. Open thoracotomy and Video-assisted thoracoscopy are recommended treatment modalities used to remove the migratory surgical blade from the thorax. The patient recovered without complication but such sharp object could have resulted in devastating injury involving heart and great vessels.

#### 4. Conflict of interest

There is no conflict of interest.

#### References

- [1] Weissberg D, Weissberg-Kasav D. Foreign bodies in pleura and chest wall. *Ann Thorac Surg* 2008;86(3):958–61.
- [2] Kim TJ, Goo JM, Moon MH, Im JG, Kim MY. Foreign bodies in the chest: how come they are seen in adults? *Korean J Radiol* 2001;2(2):87–96.
- [3] Wesley B, Baker VRMK, Brewer RJ. Video-assisted thorascopic removal of migratory acupuncture needle causing pneumothorax. *Chest* 2007;131:899–901.
- [4] Harrer J, Holubec T, Brtko M. A foreign body in the heart due to an unusual injury. *Ann Thorac Surg* 2009;88(3):985–7.
- [5] Bartek JP, Grasc A, Hazelrigg SR. Thorascopic retrieval of foreign bodies after penetrating chest trauma. *Ann Thorac Surg* 1997;63:1783–5.
- [6] Milanchi S, Makey I, McKenna R, Margulies DR. Video-assisted thorascopic surgery in the management of penetrating and blunt thoracic trauma. *J Min Access Surg* 2009;5(3):63–6.
- [7] Lazdunski LL, Mouroux J, Pons F, Grosdidier G, Martinod E, Elkaïm D, et al. Role of videothoracoscopy in chest trauma. *Ann Thorac Surg* 1997;63:327.
- [8] Burack JH, Amuraj EA, O'Neill P, Brevetti G, Lowery RC. Thorascopic removal of a knife impaled in the chest. *J Thorac Cardiovasc Surg* 2005;130:1213–4.