



## Case report

# Intraoperative change in P-wave polarity, an accidental finding: Anaesthesiologist's dilemma



Swati Chhabra \*, S.K. Singhal

Department of Anaesthesiology, Pt. B D Sharma Post Graduate Institute of Medical Sciences, Rohtak, India

Received 7 February 2014; accepted 13 November 2014

Available online 19 December 2014

### KEYWORDS

Changing p wave polarity;  
Intraoperative;  
Anaesthesia

**Abstract** Arrhythmias are commonly observed in the intraoperative period. These could arise due to varied reasons and are treated accordingly. However certain situations are encountered where arrhythmias are transient and do not cause any haemodynamic instability. We report a case of 61 year old female posted for an orthopaedic procedure where intraoperative changing p wave polarity was noticed on monitor. Since, the patient was asymptomatic and haemodynamically stable, we decided to proceed with a spinal anaesthetic after much dilemma. The intraoperative period went uneventful with continued changes in p wave polarity.

© 2014 Production and hosting by Elsevier B.V. on behalf of Egyptian Society of Anesthesiologists.

## 1. Introduction

In a normal electrocardiogram, P-wave has a positive axis in all leads but aVR. Deviation of P-wave axis from its normal polarity is seen in varied conditions. Spontaneous changes in P-wave axis have been described in the literature but most of the studies/case reports include the patients who are either symptomatic or have co-existing cardiac conditions [1].

Here, we report a patient with spontaneous changes in P-wave polarity detected accidentally intraoperatively.

## 2. Case report

A 61 year old female presented to Emergency Room with pain, swelling and deformity over right thigh after accidental fall the

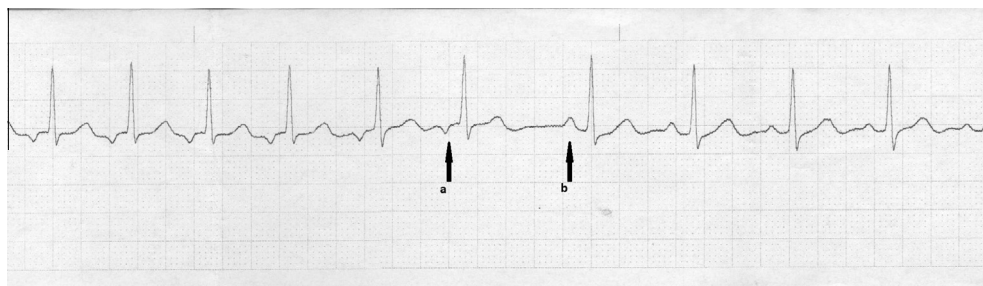
same day. She gave history of right sided total hip replacement one year back. X-ray showed periprosthetic fracture of shaft of right femur. She was planned for an open reduction internal fixation with plating of femur and sent for pre-anaesthetic evaluation. No positive history or findings were elicited and baseline investigations (including serum electrolytes) were within normal limits. She had undergone total right hip replacement under spinal anaesthetic one year back which was uneventful.

Pre-operative medication (Tab. Alprazolam 0.25 mg and Tab. Ranitidine 150 mg) were advised for the night before and morning of surgery. Spinal anaesthetic was planned. On receiving the patient in Operating Room, multipara monitor (Philips Intellivue MP50) was attached and an 18 G i.v.canula was secured. At this time, an inverted P-wave was noticed on the ECG (Lead II & V<sub>5</sub>) on the monitor. While this was being evaluated, P-wave changed its polarity to upright and then to inverted again. Patient's heart rate was 84 beats per minute and blood pressure was 140/82 mm of Hg. No pattern was observed in the transient changes in polarity of P-wave and the heart rate was not variable after the transitions (except

\* Corresponding author at: 95, Green Park, Hisar 125001, Haryana, India. Tel.: +91 9468090819.

E-mail address: [swati\\_virgo83@yahoo.co.in](mailto:swati_virgo83@yahoo.co.in) (S. Chhabra).

Peer review under responsibility of Egyptian Society of Anesthesiologists.



**Figure 1** (a) Inverted p wave and (b) upright p wave.

for the prolonged R–R interval during the transition) (Fig. 1). Since the patient was asymptomatic and hemodynamically stable, it was decided to proceed with the surgical procedure. Spinal anaesthesia was given at L<sub>3-4</sub> level with 2.8 ml of 0.5% Inj. Bupivacaine (Heavy). Sensory blockade up to T<sub>10</sub> was achieved. Spontaneous and transient changes in P-wave polarity continued throughout the intraoperative period. No changes in blood pressure were observed. After the completion of the surgical procedure, the patient was shifted to Post Anaesthesia Care Unit (PACU). ECG, NIBP and SPO<sub>2</sub> were monitored continuously in PACU as well. Changes in P-wave polarity were noted here as well. The patient was discharged from PACU after discharge criteria was met and shifted to postoperative ward. Serial 12 lead ECGs were done during her hospital stay, some had positive P-waves, some negative and some both. Cardiologist consultation was obtained. Echocardiographic study was within normal limits. Since the patient was asymptomatic, it was decided not to refer the patient for electrophysiologic studies. Patient was discharged on 18th postoperative day. Patient was followed up telephonically at monthly intervals for next three months and was found to have no complaints pertaining to cardiovascular system.

### 3. Discussion

Negative P-wave axis in leads other than aVR can have numerous mechanisms such as exit of impulse from SA node via abnormal pathways, conduction block in the internodal pathways or increased degree of automaticity of an atrial site which then functions as an ectopic atrial pacemaker.

Another differential could be wandering atrial pacemaker which can be defined as an irregularly irregular rhythm with a ventricular rate less than 100 beats/min, characterized by at least 3 different P-wave morphologies on the same strip, each associated with their own PR interval [2]. It is thus an slower version of multifocal atrial tachycardia (MAT: 3 or more

different P wave morphologies, differing P–P, PR and R–R intervals with narrow QRS complex). But this is not the case as in our patient. There is no difference in P-wave morphology but P-wave polarity (Fig. 1a and b); so wandering pacemaker is not a cause of changing P-wave polarity in this patient.

Changing P-wave polarity is a known entity [3] and may occur as a normal (physiologic) variant, especially with high vagal tone or in a variety of pathologic settings such as digitalis overdose, sick sinus syndrome and different types of organic heart disease. Most of reported patients with changing P-wave polarity were symptomatic with structural or functional cardiac problems [1].

Such a change in P-wave polarity in perioperative period has not been reported before. This situation creates dilemma in the mind of anaesthesiologist whether to proceed with the procedure without further investigations or not. Whether patient is symptomatic or not and haemodynamic status could be useful guiding factors (as in this case) but this remains open to further debate.

### Conflict of interest

None.

### References

- [1] Abedin Z, Geraci AR. Changing P wave polarity. Intermittent posterior internodal conduction. *Chest* 1976;70:792–5.
- [2] Garcia Tomas B, Miller Geoffrey T. Wandering atrial pacemaker. In: Arrhythmia recognition: the art of interpretation. Sudbury, Massachusetts: Jones & Bartlett Publishers; 2009. p. 207–14.
- [3] Goldberger Ary L, Goldberger Zachary D, Shvilkin Alexei. Cardiac rhythm disturbances. In: Goldberger's clinical electrocardiography: a simplified approach. Philadelphia, Pennsylvania: Saunders; 2013. p. 116.