



Use of Ambu[®] aScope[™] 3 in difficult airway management in giant lipoma neck



Reena MD*

Heritage Institute of Medical Sciences, Varanasi, Uttar Pradesh, India

ARTICLE INFO

Article history:

Received 5 October 2016

Accepted 13 October 2016

Available online 9 November 2016

Keywords:

Lipoma neck
Fibreoptic intubation
Ambu aScope
Awake intubation
Difficult airway

ABSTRACT

Background and objectives: Lipoma represents very common soft tissue tumour, which may appear anywhere in the body. Appearance of a giant lipoma at the nape of neck, can severely compromise neck extension especially in elderly patients where age related degenerative changes in airways present significant challenges to anesthesiologists in airway management whenever needed. This paper evaluates the role of Ambu[®] aScope[™] 3 in such a patient.

Case report: An expected case of difficult airway where an old man presents with a huge lipoma of 15.5 × 12.4 cm at the nape of neck where we achieved awake intubation using a non-fiberoptic flexible bronchoscope Ambu[®] aScope[™] 3. In the absence of fiberoptic bronchoscope, this device helped us secure airway in this very challenging case.

Conclusion: Ambu[®] aScope[™] 3 can be used for elective awake intubations in patients with difficult airways.

© 2016 Publishing services by Elsevier B.V. on behalf of Egyptian Society of Anesthesiologists. This is an open access article under the CC BY-NC-ND license (<http://creativecommons.org/licenses/by-nc-nd/4.0/>).

1. Introduction

Geriatric population presents unique problems in terms of airway difficulty. Degenerative changes like dental loss and cervical rigidity further compound the problem. Many edentulous elderly patients present greater difficulty during mask ventilation.

The difficulty further gets stepped up when the patient has a large mass like lipoma at the back of neck. Several newer devices are available which help to achieve successful intubation in difficult airway scenarios. Of these a newer device is Ambu aScope[™] (Ambu A/S, Ballerup, Denmark) is a fully disposable, sterile, battery-operated, non-fibreoptic flexible bronchoscope with a small (0.8-mm) working channel capable of drug instillation but not suctioning (Fig. 1). It has a CMOS (complementary metal-oxide semiconductor) chip, a steering button to flex the tip, and a distal LED [1]. Images are transmitted along a cable within the insertion tube and transferred to a small portable monitor by way of a video connection cable at the handle. Earlier version had a timing mechanism allowing it to function for a maximum of 30 min during an 8-h period starting from the initial power startup. They also had lesser range of tip movements (120° up

and down). A more recent version of this device comes without these time limitations. The monitor can be used for 150 intubations and is connected to an external monitoring system, and also tip movements in Ambu[®] aScope[™] 3 are 150° up and 130° down which is comparable to flexible fibreoptic bronchoscope where it is 180° up and 130° down.

2. Case report

A 75 year old patient, weighing 40 kg was posted for the excision of a non-pedunculated, ulcerated, giant lipoma at the nape of neck (Fig. 2). The tumour, which was initially small for many years, had reached the size of 15.5 cm in length and 12.4 cm in width over a period of 5 years. The pre anaesthetic check-up revealed that patient had no significant past medical or surgical history, but he had the habit of tobacco chewing for more than four decades. Systemic examination was within normal limits for his age while findings on airway examination revealed the presence of mouth opening restricted to two fingers breadth, buck teeth and multiple loose and missing teeth, Mallampati classification grade 3, considerably restricted neck extension and lateral rotation as was expected from the large size mass. Routine investigations were within normal limits.

As per ASA guidelines patient was put nil per orally for 8 h in the night before surgery. Since the patient was a difficult airway, as per our institutional protocol we planned to go with awake intu-

Peer review under responsibility of Egyptian Society of Anesthesiologists.

* Address: Department of Anaesthesiology, Heritage Institute of Medical Sciences, Mohansarai-Ramnagar Bypass, Bhadwar, Varanasi, U.P. 221311, India.

E-mail address: reena216@gmail.com

<http://dx.doi.org/10.1016/j.egja.2016.10.006>

1110-1849/© 2016 Publishing services by Elsevier B.V. on behalf of Egyptian Society of Anesthesiologists.

This is an open access article under the CC BY-NC-ND license (<http://creativecommons.org/licenses/by-nc-nd/4.0/>).




Figure 1. Ambu® aScope™ 3.

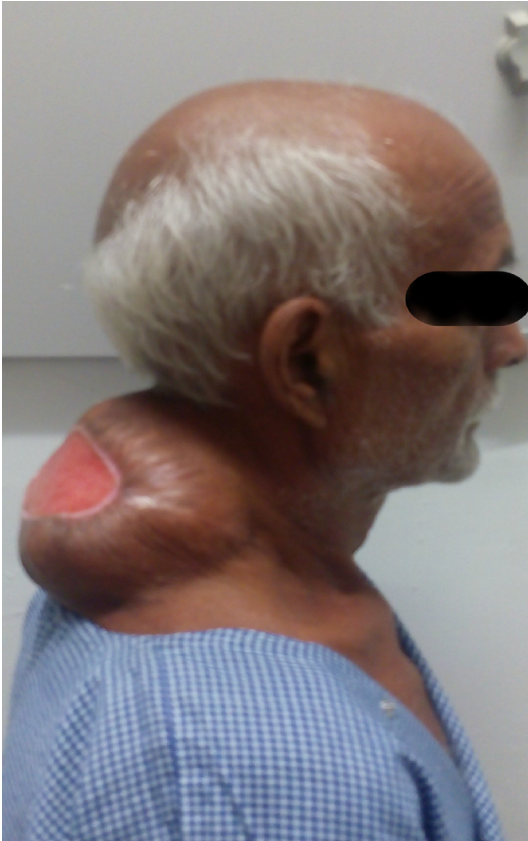

Figure 2. Giant Lipoma at the back of neck.

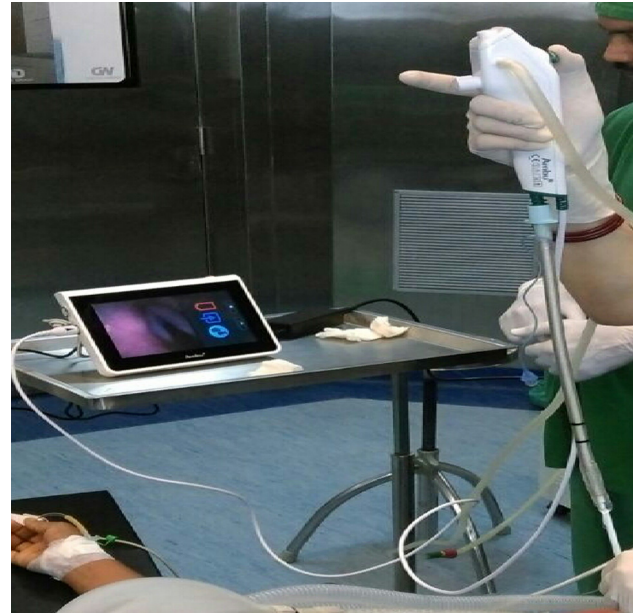

Figure 3. Intubation using Ambu® aScope™ 3.

vocal cords movements became sluggish. At this point ETT was introduced in trachea under vision followed by removal of insertion cord and after cuff inflation ETT was connected to closed circuit. ETT position was confirmed with bilateral chest auscultation and EtCO₂ monitoring. Propofol 80 mg and vecuronium 4 mg iv were given. Oxygen and nitrous oxide were started in 40:60 ratios with isoflurane 1% and patient was made prone taking care of ETT position and adequate abdominal movements assured on controlled ventilation. Adequate padding was given to protect eyes and also on pressure points. Intraoperative period was uneventful. After surgery patient was made supine and upon return of spontaneous efforts patient was extubated after reversing the neuromuscular blockade with intravenous glycopyrrolate 0.4 mg and neostigmine 2 mg.

3. Discussion

Airway management in elderly patients presents multiple problems. Loss of elastic tissues in this population results in restricted mouth opening which gets further accentuated in a habitual tobacco chewer due to mucosal fibrosis. Dental loss, loose teeth and loss of oropharyngeal tone make mask ventilation more difficult; also restricted cervical spine movements [restriction of atlantooccipital joint extension (less than 35 degrees)] [2] make tracheal intubation more difficult. Limitations of neck mobility get worsened in the presence of large size posterior neck tumours like lipoma.

Obtaining a “sniffing position” is required for optimum alignment of oral, pharyngeal and laryngeal axes during direct laryngoscopy [3], which would have not been possible in our patient because of the large sized lipoma severely restricting the neck extension.

In our institute fiberoptic bronchoscope is not available, but we have a similar device Ambu® aScope™ 3 which is a flexible video-endoscope and when connected to the portable monitor, Ambu® aView™ gives high resolution images, enabling easy navigation and fast identification of anatomical landmarks. In a randomised controlled trial, Kristensen compared the Ambu aScope™ against a multiple-use fiberoptic endoscope in 60 patients with expected normal and difficult airways [4]. All patients were successfully

bation using Ambu® aScope™ 3 which is a flexible non-fiberoptic bronchoscope. In the pre operative area we prepared patient's upper airway for awake intubation using lignocaine 4% nebulization for 15 min, lignocaine 10% spray in oropharynx and the patient was also made to gargle with lignocaine 2% viscous. In the operation theatre standard monitors like SPO₂, ECG, and NIBP were applied and baseline values recorded. An 18 gauge intravenous cannula was put in left hand and a Ringer's lactate drip started. A shoulder roll was put behind patient's back to prevent compression of ulcerated lipoma. Patient was premedicated with intravenous glycopyrrolate 0.2 mg, midazolam 1 mg, fentanyl 100 Å µg and pre oxygenated for 3 min. The intubation was attempted by a senior qualified anaesthesiologist, who was well versed with the use of flexible endoscopes and also had been using Ambu Ascope in various difficult airway scenarios. A flexometallic endotracheal tube (ETT) size 7.5 was advanced over the insertion cord of Ambu® aScope™ 3 (Fig. 3) and with the help of control lever of the device vocal cords were visualised followed by instillation of lignocaine 2% in 1 ml aliquots through the working channel of the device until

intubated and median intubation time was recorded. The difference was statistically significant in favour of fiberoptic endoscope, but the authors concluded that it was clinically not important. In another RCT, Krugel et al. compared Ambu® aScope 2 against a multiple-use fibreoptic endoscope in 100 patients with difficult airways (simulated by a semi-rigid cervical collar) [5]. The use of the Ambu aScope 2 was associated with a longer time to intubation along with somewhat poorer quality images compared with the fibreoptic endoscope. However they also mentioned that lesser patients required two attempts in Ambu aScope 2 group in comparison with fibreoptic group. Pujol et al. described a case series of 10 patients with expected difficult airways in whom successful intubation was done in 9 patients using Ambu aScope. The intubation was easy in eight patients while one patient needed some manoeuvres to achieve successful intubation; one patient could not be intubated with it [6].

We didn't find any study where difficult airway due to lipoma at the nape of neck was managed by Ambu® aScope™ 3. However, Ali et al. have reported similar case of lipoma neck where they used Airtraq® laryngoscope to achieve tracheal intubation [7], but they performed intubation under general anaesthesia in contrast to our case where we chose awake intubation. Awake intubation offers several advantages, allows airway assessment, maintains airway patency, and allows time to modify the approach and technique, high success rate and if intubation is unsuccessful, we have a conscious patient in whom we can postpone the surgery or do tracheostomy after taking consent [8].

Flexible non-fiberoptic endoscopes like Ambu® aScope™ 3, are a valuable tool in smaller centres like ours, where fibreoptic bronchoscopes are not available. Krugel et al. also have suggested that despite their limitations, and aScopes are an attractive alternative to fibreoptic devices [5]. They are light weight, easy to transport and ready to use devices. Since they are disposable devices they can be used in patients with infectious and transmissible diseases. Cost analysis between fibreoptic bronchoscope and Ambu aScope has shown that standard fibroscopes, although are reusable but are expensive to purchase, in addition to the cost of maintenance [9,10]. Also reusable devices increase the chances of transmitting infections among patients [11]. While some studies have favoured disposable bronchoscopes over multi use devices [12–14], some other studies discourage its use whenever fibreoptic bronchoscopes are available due to some of the limitations of aScopes like the absence of suction port and low performance lenses in the earlier versions [5]. Ambu® aScope™ 3 has a suction port to overcome these limitations, but it is not as effective as the one seen in fibre-optic bronchoscopes.

4. Conclusion

In conclusion, Ambu aScope is an attractive alternative to fibre-optic bronchoscope in patients with difficult airway especially in

small centres where purchase and maintenance of fiberoptic devices are likely to be more expensive. In our knowledge this is the first reported case of lipoma neck which was successfully intubated using Ambu® aScope™ 3; however, more case reports and randomised controlled trials are needed to establish its utility in the difficult airway scenarios.

Conflicts of interest

None declared.

Acknowledgement

The author acknowledges Matson Surgicals Pvt. Limited for providing Ambu® aScope™ 3.

References

- [1] Benumof JL. Fiberoptic and flexible endoscopic aided techniques. In: Hagberg CA, editor. Benumof's and Hagberg's Airway Management. Philadelphia, PA: Elsevier Saunders; 2013. p. 365–411.
- [2] Bellhouse CP, Dore C. Criteria for estimating likelihood of difficulty of endotracheal intubation with the Macintosh laryngoscope. *Anaesth Intensive Care* 1988;16:329–37.
- [3] Magill IW. Endotracheal anesthesia. *Am J Surg* 1936;34:450–5.
- [4] Kristensen MS, Fredensborg BB. The disposable Ambu aScope vs. a conventional flexible videoscope for awake intubation- a randomised study. *Acta Anaesthesiol Scand* 2013;57(7):888–95.
- [5] Krugel V, Bathory I, Frascarolo P, Schoettker P. Comparison of the single-use Ambu® aScope™ 2 vs the conventional fibroscope for tracheal intubation in patients with cervical spine immobilisation by a semirigid collar. *Anaesthesia* 2013;68:21–6.
- [6] Pujol E, Lopez AM, Valero R. Use of the Ambu® aScope in 10 patients with predicted difficult intubation. *Anaesthesia* 2010;65:1037–40.
- [7] Ali QE, Siddiqui OA, Amir SH, Azhar AZ, Ali K. Airtraq® optical laryngoscope for tracheal intubation in a patient with giant lipoma at the nape: a case report. *Rev Bras Anesthesiol* 2012;62(5):736–40.
- [8] Ramesh S. Fiberoptic airway management in adults and children. *Indian J Anaesth* 2005;49(4):293–9.
- [9] Tvede MF, Kristensen MS, Nyhus-Andreasen M. A cost analysis of re-usable and disposable flexible optical scopes for intubation. *Acta Anaesthesiol Scand* 2012;56:577–84.
- [10] Gupta D, Wang H. Cost-effectiveness analysis of flexible optical scopes for tracheal intubation: a descriptive comparative study of re-usable and single-use scopes. *J Clin Anesth* 2011;23:632–5.
- [11] AAGBI (Association of Anaesthetists of Great Britain and Ireland) safety guidelines. Infection control in anaesthesia. *Anaesthesia* 2008;63:1027–32.
- [12] Piepho T, Werner C, Noppens RR. Evaluation of the novel, single use, flexible aScope for tracheal intubation in the simulated difficult airway and first clinical experiences. *Anaesthesia* 2010;65:820–5.
- [13] Scutt S, Clark N, Cook TM, et al. Evaluation of a single-use intubating videoscope (Ambu aScope) in three airway training manikins for oral intubation, nasal intubation and intubation via three supraglottic airway devices. *Anaesthesia* 2011;66:293–9.
- [14] Vijayakumar M, Clarke A, Wilkes AR, Goodwin N, Hodzovic I. Comparison of the manoeuvrability and ease of use of the Ambu aScope and Olympus reusable fibroscope in a manikin. *Anaesthesia* 2011;66:689–93.