

Dexmedetomidine Versus Ketamine as an Adjuvant in Erector Spinae Block for Perioperative Thoracotomy Pain Control

Original Article

Ahmed M.Elhaddad and Passaint F. Hassan

Department of Anesthesia, Kasr Alainy, Cairo University, Abo Elreesh Children's Hospital, Cairo, Egypt.

ABSTRACT

Background: Erector Spinae Plane Block (ESPB) is a simple and safe analgesic technique to relieve thoracotomy pain, but we need to increase the duration of analgesia with a single shot. so, we compared the analgesic efficacy of Dexmedetomidine (DEX) versus ketamine as an adjuvant to bupivacaine ESPB in children scheduled for thoracotomy cardiothoracic surgeries.

Methods: 90 children aged 3 to 36 months, scheduled for thoracotomy cardiothoracic surgeries, were divided into group Bupivacaine (B) ($n=30$) and received ESPB using 0.5 ml/kg bupivacaine 0.25% in 15 ml saline. Group Bupivacaine-ketamine (BK) ($n=30$) received the same as group B plus ketamine 2 mg/kg. Group Bupivacaine-Dexmedetomidine (BD) received the same as group B plus dex 1 μ g/kg. The time to first rescue analgesia, perioperative hemodynamics, postoperative pain intensity, total consumption of opioids, and frequency of complications were measured.

Results: The addition of dexmedetomidine and ketamine to bupivacaine resulted in a significant prolongation of postoperative analgesia duration (16.4 ± 3.79 hr, 95%CI: 14.951:17.783, $P<0.001$) and (10.1 ± 2.36 hr, 95%CI: 9.184:10.949, $P<0.001$), respectively compared with 0.5% bupivacaine alone (5.2 ± 1.26 hr. 95%CI: 4.714:5.625). postoperative analgesia duration was more prolonged in the BD group than in the Bk group ($P<0.001$). with lower perioperative opioid consumption, better hemodynamic profile, and better predictive indexes (extubation time and hospital stay) in the BD and BK groups than in the B group.

Conclusion: Dexmedetomidine as an adjuvant to bupivacaine provides a longer duration of analgesia as compared to ketamine without any significant side effects.

Key Words: Adjuvant, analgesia, dexmedetomidine, erector spinae plane block, Ketamine

Received: 16 April 2024, **Accepted:** 19 May 2024

Corresponding Author: Ahmed M.Elhaddad, Department of Anesthesia, Kasr Alainy School of Medicine, Cairo , Egypt. **Tel.:** +2001224042847 , **E-mail:** drblacksmith5@kasralainy.edu.eg

ISSN: 2090-925X, The Egyptian Journal of Cardiothoracic Anesthesia 2024, 18: 8-15

INTRODUCTION

Thoracotomy is one of the most painful surgical procedures. Inadequate pain relief impedes deep breathing, coughing, and early mobilization resulting in atelectasis and pneumonia^[1]. Erector spinae plane block (ESPB) is an interfascial plane block that deposits a local anesthetic (LA) deep to the erector spinae muscle (ESM) adjacent to transverse processes. Recent research showed that ESPB is a simple and safe alternative analgesic technique to address acute post-surgical, post-traumatic, and chronic neuropathic thoracic pain in adults^[2] and children^[3,4]. Fortunately, its efficacy in alleviating incisional pain has already been confirmed in clinical studies^[5,6].

Since it is difficult to admit patients to a ward with indwelling peripheral nerve catheters, it is more practical to develop methods to increase the duration of analgesia with single-shot peripheral nerve blocks. The most commonly used drugs as adjuvants are clonidine,

ketamine, and opioids. In our practice, ketamine and dexmedetomidine (DEX) are administered as an additive to improve the duration and quality of analgesia. Both have sedating actions but somewhat opposite effects on the cardiovascular system^[7].

Dexmedetomidine is a potent α_2 -agonist used as an adjuvant to regional anesthesia and analgesia. It can prolong the duration of nerve block anesthesia when used with a LA and only has a few side effects^[7,8]. N-methyl D-Aspartate (NMDA) receptors play an important role in neuronal plasticity leading to central sensitization and increasing postoperative pain intensity. Ketamine is an NMDA antagonist with analgesic properties that modulate central sensitization of nociceptive stimulation^[9,10].

This study compared the efficacy of DEX versus ketamine as an adjuvant to bupivacaine in ultrasound-guided ESPB in patients scheduled for cardiothoracic surgeries with thoracotomy incision.

METHODOLOGY:

This double-blinded, randomized, controlled study was conducted in the Department of Cardiothoracic Surgery, Abo El-Reesh Children Hospital, Cairo University. The study included 90 children aged 3 to 36 months scheduled for cardiothoracic surgeries with thoracotomy incisions. The study was approved by the Research Ethics Committee and registered at ClinicalTrials.gov (NCT05552391). Informed consent was obtained from the patient's parents before enrollment. Exclusion criteria were skin erosions, hematomas, or infection at or near the injection site, coagulopathy, and a history of hypersensitivity to study drugs.

An online randomization program (<http://www.randomizer.org>) was used to generate a random list to allocate patients into three groups. Random allocation numbers were concealed in opaque closed envelopes opened 10 minutes after induction of anesthesia. Group B ($n=30$) received ESPB using 0.5 ml/kg bupivacaine 0.25% with isotonic saline in a total volume of 15 ml. Group BK ($n=30$) received ESPB using 0.5 ml/kg bupivacaine 0.25% plus ketamine 2 mg/kg diluted in volume 15 ml isotonic saline. Group BD received ESPB using 0.5 ml/kg bupivacaine 0.25% plus dexmedetomidine 1 µg/kg diluted in 15 ml isotonic saline. A nurse not involved in the study prepared syringes of local anesthetics, and the investigator was blinded to the type of drug injected. The patient and doctor assessing study outcomes were blinded to group allocation.

The patients were subjected to thorough clinical examination and routine investigations, which included a complete blood count (CBC), coagulation profile, liver function tests, renal function tests, blood grouping, chest X-ray, ECG, and echocardiography if needed.

Anesthetic Technique:

Children were premedicated with midazolam 0.2 mg/kg IM and atropine 0.02 mg/kg IM 10 minutes before induction of anesthesia. In the operating room, on a warming mattress, non-invasive monitors were applied (ECG, pulse oximetry, and non-invasive blood pressure). The baseline heart rate (HR) and mean arterial pressure (MAP) were recorded. Anesthesia was induced using 3% sevoflurane and fentanyl 3 µg/kg. Atracurium 0.5 mg/kg was administered to facilitate endotracheal intubation and was infused intraoperatively at 0.5 mg/kg/hr to maintain muscle relaxation. Anesthesia was maintained using sevoflurane 0.3-1.5% in an oxygen-air mixture.

Ultrasound-guided ESPB was applied after induction of anesthesia with the patient in the lateral position. The ultrasound 5-6 Hz machine has a 35 mm linear probe (SonoSite M-turbo system, Fujifilm SonoSite Inc., USA). The trapezius, rhomboid major, and ESMs were visualized approximately 3 cm lateral to the T5 spinous process (Figure 1). A 22G bevel needle was advanced in a cephalad to caudad direction till the needle reached a plane deep

between the ESM lateral to the transverse thoracic process. Aspiration was done to ensure the absence of air or blood, and then LA was injected to anesthetize the dorsal and ventral rami to anesthetize the T3-T10 dermatomes.

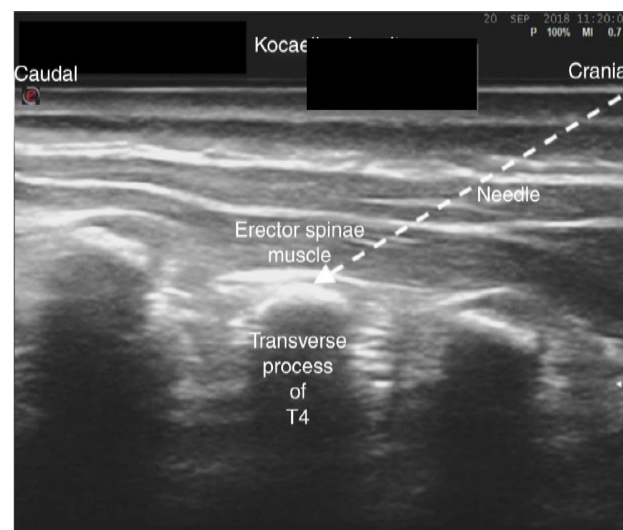


Fig. 1: Ultrasound anatomy and injection site for Erector Spinae block

The HR, MAP, and O₂ saturation were monitored. Fentanyl 1 µg/kg IV was administered if the surgical incision increased systolic blood pressure or HR by more than 15%. Significant bradycardia (< 20% from baseline) was treated with atropine 0.02 mg/kg. Hypotension (20% systolic blood pressure fall) was treated with an IV fluid bolus of 10 ml/kg 0.9% normal saline. At the end of surgery, inhalational anesthetics and muscle relaxants were stopped, and the patient was transferred to the ICU.

Postoperative Assessment and Analgesic Regimen:

An observer blinded to group allocation assessed postoperative pain intensity using an objective pain score (OPS). The OPS incorporates four pain behaviors (crying, movement, agitation, and verbalization) and BP change. Each category is scored from 0 to 2^[11]. Paracetamol 15 gm/kg/6 hours was administered as a component of a multimodal analgesia regimen for postoperative pain control. If the OPS score ≥ 4 , the patient received a rescue analgesic of IM morphine 0.1 mg/kg.

HR and MAP were recorded at baseline (T0), with skin incision (T1), every 30 minutes intraoperatively, then every 6 hours in the ICU. Duration of surgery and total intraoperative fentanyl consumption were recorded. Time to extubation, ICU stay duration, and complications (nausea and vomiting, pruritus, LA toxicity, and intravascular injection) were recorded.

The primary outcome measure was the duration of analgesia, defined as the time from the block to the first need for rescue analgesia, with an OPS score ≥ 4 . The secondary outcome measures were postoperative pain intensity, total consumption of opioids, perioperative hemodynamics, and frequency of perioperative complications.

Sample size calculation:

We performed a pilot study (5 cases in each group), and we found that the mean difference of time to first rescue analgesia was 1.4 between dexmedetomidine and ketamine groups with an SD of 1.64. The sample size was based on the following considerations: 0.8 effect size, 0.05 alpha error, 80% power of the study, group ratio 1:1, and four cases were added to each group to overcome dropout. Therefore, we recruited 30 patients in each group. The sample size calculation was done by G*Power 3.1.9.2 (Universität Kiel, Germany).

Statistical analysis:

Statistical analysis was done by SPSS v27 (IBM©, Chicago, IL, USA). Shapiro-Wilks test was used to test data distribution. Quantitative parametric data were presented as mean and standard deviation (SD) and were analyzed by ANOVA test with post hoc test (Tukey). Quantitative

non-parametric data were presented as the median and interquartile range (IQR) and were analyzed by the Kruskal-Wallis test with the appropriate post hoc test. Qualitative variables were presented as frequency and percentage and analyzed using the Chi-square test. Kaplan-Meier method was used to estimate the cumulative number of patients needing rescue postoperative analgesia. A two-tailed *p*-value < 0.05 was considered statistically significant.

RESULTS

Study population:

As shown in Figure 2, 113 patients were assessed for eligibility, 17 did not meet the criteria, and six refused to participate. The remaining 90 patients were included in the analysis. Table 1 shows no significant difference between the three groups regarding demographic data, type, and duration of surgery.

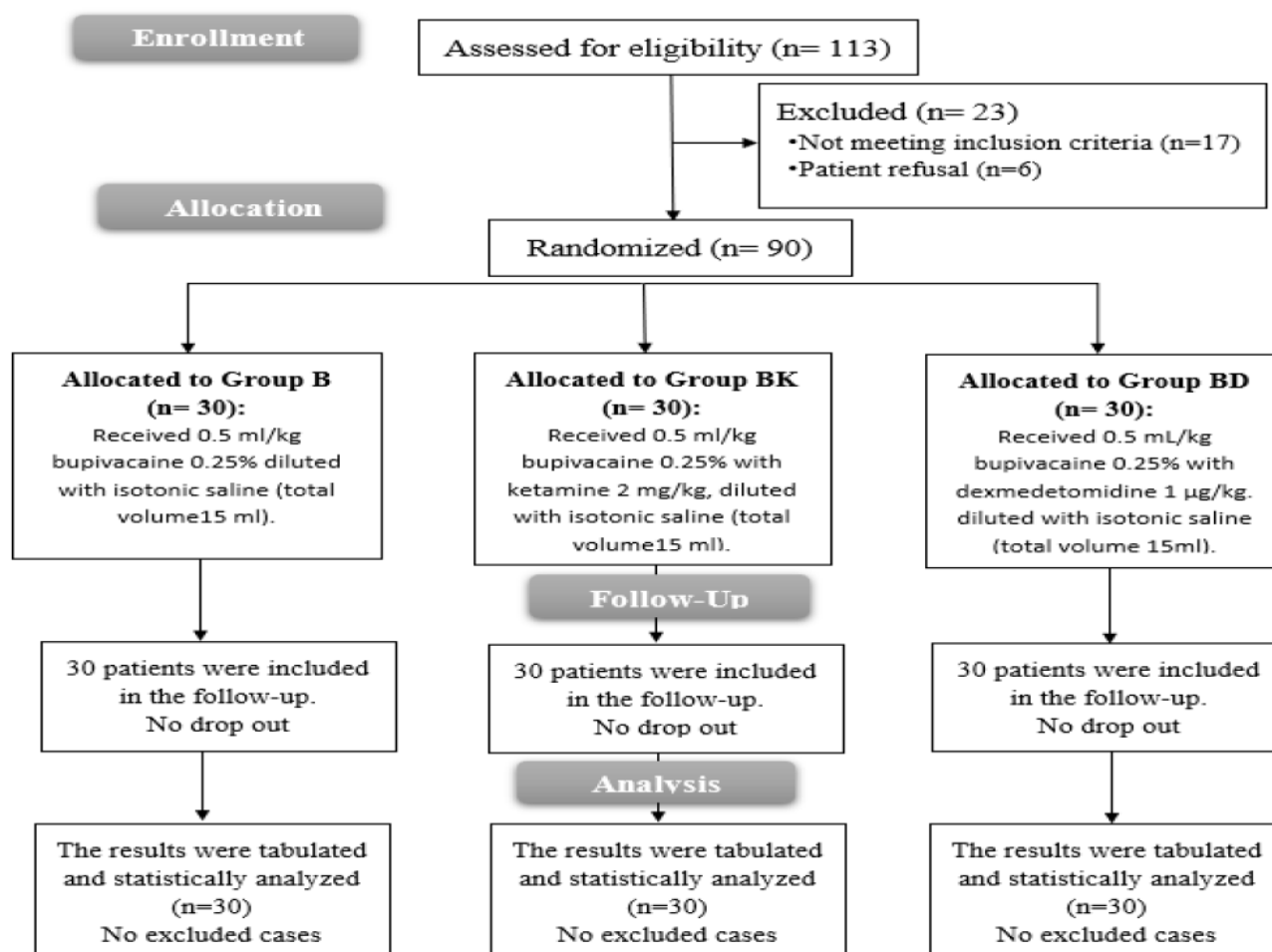


Fig. 2: CONSORT flowchart of the enrolled patients

Table 1: Baseline characteristics and intraoperative data.

	Group B (n=30)	Group BK (n=30)	Group BD (n=30)	p-value
Age (months)	7.0 (2.0-24.0)	6.0 (1.5-18.0)	5.0 (1.0-24.0)	0.090
Sex (male/female)	17/13	17/13	16/14	0.956
Weight (kg)	7.5±4.3	6.0±2.8	7.2±3.3	0.207
Surgery type				
AO.CO	7 (23.3%)	10 (33.3%)	10 (33.3%)	0.431
PDA	15 (50.0%)	14 (46.7%)	9 (30.0%)	
Decortication	8 (26.7%)	6 (20.0%)	11 (36.7%)	
Surg. Duration (hrs)	1.6±0.6	1.8±0.6	1.9±0.7	0.375
fentanyl consump. (µg)	12.0 (4-60)	10 (5-26)	7.5 (4-15)	<0.001*

Data are presented as median (range), mean±SD or frequency (%).

Primary outcome:

The addition of dexmedetomidine and ketamine to bupivacaine resulted in a significant prolongation of postoperative analgesia duration (16.4 ± 3.79 hr, 95%CI: 14.951:17.783, $P < 0.001$) and (10.1 ± 2.36 hr, 95%CI: 9.184:10.949, $P < 0.001$), respectively compared with 0.25% bupivacaine alone (5.2 ± 1.26 hr. 95%CI: 4.714:5.625). postoperative analgesia duration was more prolonged in the BD group than in the Bk group ($P < 0.001$) (figure 3).

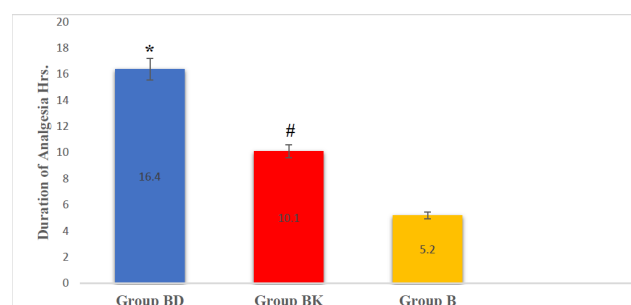


Fig. 3: Time to first rescue analgesia.

The total intraoperative fentanyl consumption and The total postoperative morphine consumption were significantly lower in the BD and BK groups than in the B group and were comparable between the BK and BD groups (Table 2).

Table 2: Postoperative analgesia and postoperative variables.

	Group B (n=30)	Group BK (n=30)	Group BD (n=30)	p-value
OPS Pain score				
Immediate post-operative	2(1 - 2)	1(1 - 2)	1(1 - 2)	0.007*
After 6h	5(4 - 5)	3(3 - 4)	2(2 - 2)	<0.001*
After 12h	3(2 - 3)	3(2.25 - 5)	3(2.25 - 3)	<0.001*
After 18h	4.5(3.25 - 5)	2(1 - 2)	2(2 - 2.75)	<0.001*
After 24 h	2(2 - 2)	2(1 - 2)	2(1 - 2)	0.355
Mean 24 h	3.55±0.34 (3.427:3.680)	2.37±0.28 (2.263:2.471)	2.38±0.22 (2.296:2.246)	0.021*
Morphine consump. (mg)	1.5±0.9	0.6±0.3	0.7±0.3	<0.001*
Extubation time (h)	3.5 ± 2.15 (2.73:4.33)	1.9 ± 0.94 (1.52:2.22)	2.1 ± 0.99 (1.73:2.47)	<0.001
ICU (days)	5.5 ± 2.69 (4.46:6.47)	4 ± 1.4 (3.44:4.49)	4.2 ± 1.74 (2.16:2.84)	0.011*

Data are presented as median (range) or mean±SD (95% confidence interval)

Secondary outcomes:

Hemodynamic parameters (Mean blood pressure and heart rate) were comparable between the three groups at T0 and showed statistically significant higher HR and lower MBP through other intraoperative and postoperative time intervals in Group B compared to Group BD and Group BK, However, all measurements were within the clinically accepted ranges (Figure 4).

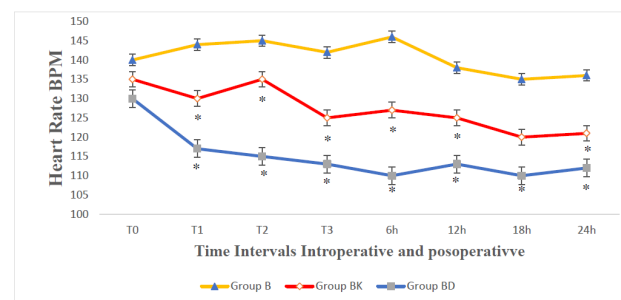


Fig. 4: Intraoperative and postoperative heart rate HR (bpm).

Postoperative pain scores were significantly lower in BD and BK groups than in group B immediately postoperative and after 6,12,18 hours and were insignificantly different among the three groups after 24 hours. The mean 24-hour pain score was significantly lower in group BD and BK than in group B ($p=0.021$) (Table 2).

For postoperative indices, Extubation time, and ICU stay were significantly shorter in group BK and BD than in group B and were insignificantly different between group BD and group BK. No complications were recorded in any patient in the three groups.

DISCUSSION

This study demonstrated that adding DEX or ketamine to LA in ESPB can significantly prolong postoperative analgesia duration. The two drugs were associated with reduced postoperative pain scores, intraoperative fentanyl consumption, and postoperative morphine consumption compared to the control group. DEX was superior to ketamine in prolonging the postoperative analgesic duration. No significant side effects requiring intervention were observed in any group.

Single-shot ESPB provided a relatively short duration of analgesia. Continuous ESPB with catheter insertion was suggested to overcome this drawback^[12]. Some catheter-related complications have been reported, including occlusion, displacement, infection, and accidental removal^[13]. Adding adjuvants was another alternative to prolong the analgesic duration of ESPB.

DEX is supposed to induce hyperpolarization-activated cation current that affects peripheral nerve activity. Moreover, it may cause vasoconstriction at the injection site, limiting LA absorption and lengthening the impact. Furthermore, it has analgesic advantages through the reduction of norepinephrine release and α -2 receptor-independent suppression of nerve fiber action potentials^[14].

Ketamine probably induced its local effect by blocking the voltage-operated sodium channels. It is an N-methyl-d-aspartate (NMDA) receptor antagonist, and these receptors are important contributors to central sensitization^[15]. The effect of ketamine on NMDA abolishes peripheral afferent noxious stimulation^[16].

After an extensive literature search, we could not find a similar study conducted to compare ketamine and dexmedetomidine as adjuvants to local anesthetic in ESPB for analgesia during pediatric cardiac surgery. The efficacy of DEX as an adjuvant to ESPB was investigated in other types of surgery in adults. An Egyptian randomized trial reported similar results to the present study. They found that the DEX-bupivacaine combination of ESPB provided better and longer analgesia and less perioperative opioid consumption in patients undergoing open thoracotomies^[17]. Another study compared nalbuphine and DEX as adjuvants to ropivacaine in ESPB in video-assisted thoracoscopic

lobectomy surgeries. Their findings concurred with ours in that VAS and postoperative analgesic intake were markedly reduced in the DEX group compared to the control group nalbuphine resulted in a comparable analgesic profile to DEX^[18]. Similarly, DEX in a dose of 1 $\mu\text{g}/\text{kg}$ as an adjuvant to ESPB provided better analgesia in patients subjected to modified radical mastectomy^[19,20].

Our findings concur with Ram *et al.*, who randomized 90 children undergoing routine infra-umbilical surgical procedures under general anesthesia to receive caudal block with levobupivacaine 0.25%, with the addition of ketamine or DEX. DEX and ketamine prolonged postoperative analgesia compared to levobupivacaine alone with no harmful side effects^[21]. Adding caudal DEX to the LA in pediatric patients undergoing lower extremity and infra-umbilical surgical procedures is recommended by a systematic review of 21 studies involving 1590 children. A dose of 1 $\mu\text{g}/\text{kg}$ significantly prolonged the duration of analgesia regardless of the LA employed^[22]. Also, in pediatric patients undergoing infra-umbilical surgery, 1 $\mu\text{g}/\text{kg}$ of DEX reduced the required concentration of levobupivacaine used in the caudal block from 0.25% to 0.125%. It prolonged the duration of analgesia with a lower frequency of emergence delirium^[23]. In 60 adult patients with esophageal cancer, adding 0.5 $\mu\text{g}/\text{kg}$ DEX to ropivacaine in ESPB during open thoracotomy prolonged the duration of analgesia and decreased opioid consumption without increasing adverse effects^[24].

A recent meta-analysis evaluated the efficacy and safety of DEX as an effective adjuvant to LA in ESPB^[25]. It involved eight studies with a total of 570 patients. DEX significantly increased the duration of analgesia and reduced opioid consumption and the risk of PONV. DEX was not associated with an increased incidence of hypotension or arrhythmia. Patients receiving DEX did not report neurotoxicity symptoms or neurologic adverse effects. They found that prolonging analgesic duration with DEX was dose-dependent, where 1 $\mu\text{g}/\text{kg}$ was superior to 0.5 $\mu\text{g}/\text{kg}$ ^[25].

DEX addition to LA was tested in other types of regional blocks. It was effective as an adjuvant to LA in a single-shot paravertebral block (PVB) for patients undergoing major breast cancer surgery. It prolonged analgesic duration and reduced pain intensity^[26,27]. DEX with ropivacaine in thoracic PVB combined with ESPB prolonged the duration of analgesia and reduced pain intensity and perioperative analgesic drug consumption^[28]. A meta-analysis of 12 RCTs evaluated adding DEX to the LA in the brachial plexus block. DEX addition was associated with shorter onset and longer duration of analgesia^[29]. Compared with clonidine, DEX added to LA in the supraclavicular brachial plexus block prolonged the duration of analgesia and enhanced the block quality. DEX extended sensory and motor block duration with no side effects^[30].

Another study compared ketamine to MgSO₄ as adjuvants to levobupivacaine in ESPB following MRM. Both drugs provided satisfactory pain alleviation without adverse side effects. The duration of analgesia was longer, and opioid consumption was lower with ketamine and magnesium sulfate than in the control group^[31]. Similar findings were found by adding ketamine 50 mg to bupivacaine 0.5% in TPVB for MRM^[32]. These results confirmed the findings of a systematic review, which concluded that caudal ketamine combined with bupivacaine or ropivacaine provided a faster onset and longer duration of caudal analgesia than LA alone^[33].

In contrast to our trial, Packiasabapathy et al. showed that adding 1 µg/kg of DEX to the femoral nerve block did not lower morphine consumption in total knee arthroplasty cases^[34].

In the present study, DEX and ketamine were hemodynamically stable and not associated with significant adverse events. DEX was associated with the lowest intraoperative MAP than groups B and BK. However, all readings were within the clinically accepted ranges without any reported complications. The HR readings were also within the clinically accepted ranges despite the statistically significant differences between the three groups. The safety of DEX and ketamine was confirmed in previous studies. Adding DEX or ketamine to levobupivacaine in the caudal block under general anesthesia was not associated with significant hemodynamic adverse effects^[21]. In PVB, the addition of DEX to LA was not associated with an increased frequency of hypotension and bradycardia^[27]. Arrhythmia and hypotension were not increased with the addition of DEX to LA in ESPB^[35]. Ketamine was also reported to be a hemodynamically safe adjuvant to ESPB^[31] or Supraclavicular brachial plexus block^[36].

This study has several limitations. It was carried out at a single facility with a small sample size of patients, which related to the primary outcome. Besides, we did not evaluate the sedation scoring individually. The patient profile of our study makes it challenging to differentiate between sedation and analgesia because a pain-free youngster is cozy and sleepy.

CONCLUSION

Dexmedetomidine 1 µg/kg as an adjuvant with bupivacaine 0.25% 0.5 mL/kg provided a longer duration of postoperative analgesia compared to ketamine 0.5 mg/kg when administered in unilateral ultrasound-guided Erector Spinae Plane Block for pediatric cardiothoracic surgeries with thoracotomy incision.

CONFLICTS OF INTEREST

There are no conflicts of interest.

REFERENCES

- Mesbah A, Yeung J, Gao F. Pain after thoracotomy. *BJA Education*. 2016;16:1–7.
- Forero M, Adhikary SD, Lopez H, Tsui C, Chin KJ. The Erector Spinae Plane Block: A Novel Analgesic Technique in Thoracic Neuropathic Pain. *Reg Anesth Pain Med*. 2016;41:621–7.
- De la Cuadra-Fontaine JC, Concha M, Vuletin F, Arancibia H. Continuous Erector Spinae Plane block for thoracic surgery in a pediatric patient. *Paediatr Anaesth*. 2018;28:74–5.
- Paladini G, Musella G, Farris G, Mogiatti M, Agosti M, Fusco P, et al. Erector spinae plane block to enhance recovery after thoracoscopic lung lobectomy in infants. *Minerva Anestesiol*. 2019;85:1247–9.
- Chin KJ, Malhas L, Perlas A. The Erector Spinae Plane Block Provides Visceral Abdominal Analgesia in Bariatric Surgery: A Report of 3 Cases. *Reg Anesth Pain Med*. 2017;42:372–6.
- Restrepo-Garces CE, Chin KJ, Suarez P, Diaz A. Bilateral Continuous Erector Spinae Plane Block Contributes to Effective Postoperative Analgesia After Major Open Abdominal Surgery: A Case Report. *A A Case Rep*. 2017;9:319–21.
- Andersen JH, Grevstad U, Siegel H, Dahl JB, Mathiesen O, Jæger P. Does Dexmedetomidine Have a Perineural Mechanism of Action When Used as an Adjuvant to Ropivacaine?: A Paired, Blinded, Randomized Trial in Healthy Volunteers. *Anesthesiology*. 2017;126:66–73.
- Rancourt M-PM, Albert NT, Côté M, Létourneau D-R, Bernard P-M. Posterior tibial nerve sensory blockade duration prolonged by adding dexmedetomidine to ropivacaine. *Anesth Analg*. 2012;115:958–62.
- Sunder RA, Toshniwal G, Dureja G. Ketamine as an adjuvant in sympathetic blocks for management of central sensitization following peripheral nerve injury. *J Brachial Plex Peripher Nerve Inj*. 2008;3:22.
- Kulkarni KR, Kadam AI, Namazi IJ. Efficacy of stellate ganglion block with an adjuvant ketamine for peripheral vascular disease of the upper limbs. *Indian J Anaesth*. 2010;54:546–51.
- Shamim F, Ullah H, Khan FA. Postoperative pain assessment using four behavioral scales in Pakistani children undergoing elective surgery. *Saudi J Anaesth*. 2015;9:174–8.
- Nagaraja P, Ragavendran S, Singh NG, Asai O, Bhavya G, Manjunath N, et al. Comparison of Continuous Thoracic Epidural Analgesia with Bilateral Erector Spinae Plane Block for Perioperative Pain Management in Cardiac Surgery. *Ann Card Anaesth*. 2018;21:323–7.
- Hong B, Bang S, Chung W, Yoo S, Chung J, Kim S. Multimodal analgesia with multiple intermittent doses of erector spinae plane block through a catheter after total mastectomy: a retrospective observational study. *Korean J Pain*. 2019;32:206–14.

14. Abdallah FW, Brull R. Facilitatory effects of perineural dexmedetomidine on neuraxial and peripheral nerve block: a systematic review and meta-analysis. *Br J Anaesth.* 2013;110:915–25.
15. Sawynok J. Topical and Peripheral Ketamine as an Analgesic. *Anesthesia & Analgesia.* 2014;119:170.
16. Trehan V, Srivastava U, Kumar A, Saxena S, Singh CS, Darolia A. Comparison of two approaches of infraclavicular brachial plexus block for orthopaedic surgery below mid-humerus. *Indian J Anaesth.* 2010;54:210–4.
17. Elshal MM, Gamal RM, Ahmed AM, Gouda NM, Abdelhaq MM. Efficacy of adding dexmedetomidine as adjuvant with bupivacaine in ultrasound-guided erector spinae plane block for post thoracotomy pain: Randomized controlled study. *Egyptian Journal of Anaesthesia.* 2021;37:425–31.
18. Rao J, Gao Z, Qiu G, Gao P, Wang Q, Zhong W, et al. Nalbuphine and dexmedetomidine as adjuvants to ropivacaine in ultrasound-guided erector spinae plane block for video-assisted thoracoscopic lobectomy surgery. *Medicine (Baltimore).* 2021;100:e26962.
19. Gad M, Elmetwally M. Efficacy of adding dexmedetomidine as adjuvant with levobupivacaine in ultrasound-guided serratus plane block for modified radical mastectomy surgery. *Research and Opinion in Anesthesia and Intensive Care.* 2019;6:234.
20. Wang X, Ran G, Chen X, Xie C, Wang J, Liu X, et al. The Effect of Ultrasound-Guided Erector Spinae Plane Block Combined with Dexmedetomidine on Postoperative Analgesia in Patients Undergoing Modified Radical Mastectomy: A Randomized Controlled Trial. *Pain Ther.* 2021;10:475–84.
21. Ram GK, Dubey PK, Akhileshwar P, Ranjan A. Dexmedetomidine and Ketamine as an Adjuvant to Levobupivacaine for Pediatric Caudal Analgesia: A Randomized, Controlled Study. *Anesth Essays Res.* 2020;14:253–8.
22. Trifa M, Tumin D, Tobias JD. Dexmedetomidine as an adjunct for caudal anesthesia and analgesia in children. *Minerva Anesthesiol.* 2018;84:836–47.
23. Nasreen F, Khalid A, Rashid H. Comparison of 0.125% Levobupivacaine with Dexmedetomidine and 0.25% Levobupivacaine in Ultrasonography-guided Pediatric Caudal Block: A Prospective, Randomized, Double-blinded Study. *Indian Journal of Pain.* 2019;33:86.
24. Wang Q, Li H, Wei S, Zhang G, Ni C, Sun L, et al. Dexmedetomidine Added to Ropivacaine for Ultrasound-guided Erector Spinae Plane Block Prolongs Analgesia Duration and Reduces Perioperative Opioid Consumption After Thoracotomy. *Clin J Pain.* 2021;38:8–14.
25. Yu L, Shen X, Liu H. The effect and safety of dexmedetomidine as an adjuvant to local anesthetics in erector spinae plane block: a systematic review and meta-analysis of randomized controlled trials. *BMC Anesthesiol.* 2023;23:61.
26. Mohamed SA, Fares KM, Mohamed AA, Alieldin NH. Dexmedetomidine as an adjunctive analgesic with bupivacaine in paravertebral analgesia for breast cancer surgery. *Pain Physician.* 2014;17:E589-598.
27. Mohta M, Kalra B, Sethi AK, Kaur N. Efficacy of dexmedetomidine as an adjuvant in paravertebral block in breast cancer surgery. *J Anesth.* 2016;30:252–60.
28. Yang J, Zhao M, Zhang X-R, Wang X-R, Wang Z-H, Feng X-Y, et al. Ropivacaine with Dexmedetomidine or Dexamethasone in a Thoracic Paravertebral Nerve Block Combined with an Erector Spinae Plane Block for Thoracoscopic Lobectomy Analgesia: A Randomized Controlled Trial. *Drug Des Devel Ther.* 2022;16:1561–71.
29. Dai W, Tang M, He K. The effect and safety of dexmedetomidine added to ropivacaine in brachial plexus block. *Medicine (Baltimore).* 2018;97:e12573.
30. Swami SS, Keniya VM, Ladi SD, Rao R. Comparison of dexmedetomidine and clonidine (α_2 agonist drugs) as an adjuvant to local anaesthesia in supraclavicular brachial plexus block: A randomised double-blind prospective study. *Indian J Anaesth.* 2012;56:243–9.
31. El Sherif FA, Youssef HA, Fares KM, Mohamed SA-B, Ali AR, Thabet AM. Efficacy of Ketamine versus Magnesium Sulphate as Adjuvants to Levobupivacaine in Ultrasound Bilevel Erector Spinae Block in Breast Cancer Surgery (a Double-Blinded Randomized Controlled Study). *Local Reg Anesth.* 2022;15:87–96.
32. El Mourad MB, Amer AF. Effects of adding dexamethasone or ketamine to bupivacaine for ultrasound-guided thoracic paravertebral block in patients undergoing modified radical mastectomy: A prospective randomized controlled study. *Indian J Anaesth.* 2018;62:285–91.
33. Ansermino M, Basu R, Vandebek C, Montgomery C. Nonopioid additives to local anaesthetics for caudal blockade in children: a systematic review. *Paediatr Anaesth.* 2003;13:561–73.
34. Packiasabapathy SK, Kashyap L, Arora MK, Batra RK, Mohan VK, Prasad G, et al. Effect of dexmedetomidine as an adjuvant to bupivacaine in femoral nerve block for perioperative analgesia in patients undergoing total knee replacement arthroplasty: A dose-response study. *Saudi J Anaesth.* 2017;11:293–8.
35. Yu L, Shen X, Liu H. The effect and safety of dexmedetomidine as an adjuvant to local anesthetics in erector spinae plane block: a systematic review and

- meta-analysis of randomized controlled trials. *BMC Anesthesiol.* 2023;23:61.
36. Lashgarinia M, Naghibi K, Honarmand A, Safavi M, Khazaei M. Effect of ketamine as an adjuvant in ultrasound-guided supraclavicular brachial plexus block: A double-blind randomized clinical trial study. *Adv Biomed Res.* 2014;3:232.