

# Foreign Body in the Pericardium: a Cause of Cardiac Dysfunction.

## Case Report

*Kiran K. Pisekar, Ramkiran Kandala, Sunil Ninama, Ritesh Shah*

*Department of Cardiac Anesthesia, U.N. Mehta Institute of Cardiology and Research Center, Ahmadabad, Gujarat, India.*

## ABSTRACT

A sewing needle was found in the pericardium of a young male who was taken for emergency surgery with severe biventricular dysfunction due pericarditis, was successfully managed using TEE, meticulous anaesthesia technique and postoperative management leading to smooth and early recovery of the patient.

**Key Words:** Cardiac, foreign body, heart surgery, pericardium.

**Received:** 24 November 2023, **Accepted:** 13 December 2023

**Corresponding Author:** Kiran Kishor Pisekar, DNB, Department of Cardiac Anesthesia, U.N. Mehta Institute of Cardiology and Research Center, Ahmadabad, Gujarat, India, **Postal Code:** 380016, **Tel.:** +91 902 940 1337 **E-mail:** kiranpisekar@gmail.com

**ISSN:** 2090-925X, The Egyptian Journal of Cardiothoracic Anesthesia 2024, 18: 25-27

## INTRODUCTION

The foreign body in the pericardium is a rare entity and is known to be associated with dreaded complications such as hemopericardium, biventricular dysfunction due to pericardial thickening, and free-wall rupture.

## CASE REPORT

A 27-year-old male with no known comorbidity presented with sudden chest pain even at rest since 10 days associated with breathlessness on exertion NYHA grade 2, fever, and generalized weakness. Patient did not have any history of surgery or trauma in the past.

The patient was found to have gross pericardial effusion on two-dimensional echocardiography for which pericardial tapping was performed which showed exudative fluid with no growth on culture. The chest radiograph was suggestive of cardiomegaly with a foreign body in the mediastinum that was confirmed on cardiac computed tomography, a foreign body was found piercing the diaphragm in the pericardial cavity and C-reactive protein were raised and rest all laboratories were under normal limits. On physical examination during preanesthesia assessment we found a small scar below xiphoid process.

The patient was taken for emergency surgical exploration. Preoperatively the patient had tachycardia (130 bpm), hypotension (70/50 mmHg) with low pulse pressure. We secured one large bore intravenous cannula, an arterial line (20 G vygon) in the right radial artery and a central venous catheter (7.5 Fr triple lumen) in the right

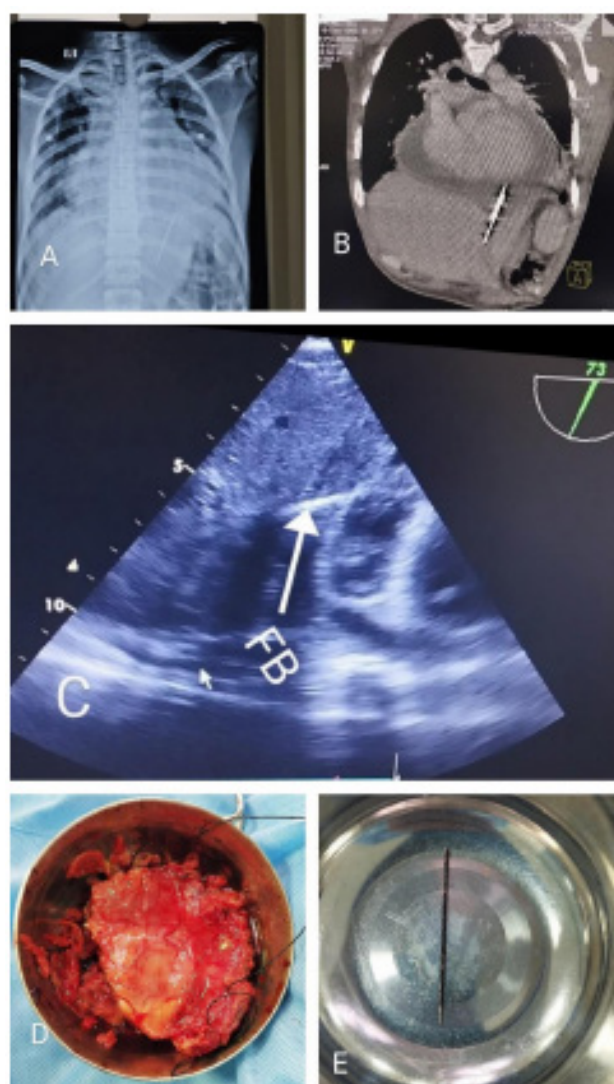
internal jugular vein under local anesthesia, central venous pressure was raised (15 mmHg) with respiratory variations.

Anesthetic induction was performed with titrated dose of Fentanyl (2 µg/kg) and the Vecuronium (0.1 mg/kg) and the airway was secured with an appropriate size ET tube. Anesthesia was maintained with sevoflurane as inhalational agent with targeted minimum alveolar concentration of 0.7.

Transesophageal echocardiography (TEE) was done to confirm preoperative findings which showed a foreign body piercing the diaphragm in the pericardium, biventricular dysfunction and dilated inferior vena cava of 23 mm, medial mitral annular e' velocity 11 cm/s and E/A of 1 which was suggestive of constrictive pericarditis. Dobutamine infusion was started at 5 µg/kg/min.

The cardiopulmonary bypass machine was kept on standby. A midline sternotomy was performed. After pericardiotomy, thick pus was drained. A needle was found piercing the diaphragm in the pericardium, which was removed without requiring diaphragm repair. The thick pericardium was adhered to the heart and partial pericardiectomy was performed without using cardiopulmonary bypass.

After pericardiectomy, cardiac contractility was found to be improved along with stabilization of hemodynamics. The patient was transferred to the cardiac ICU, was extubated 8 h later and transferred from ICU on third postoperative day and was discharged without complications (Figure 1).



**Fig. 1:** (a) Chest radiograph showing foreign body piercing through diaphragm; (b) computed tomographic image of foreign body; (c) TEE image of the foreign body from the liver through the diaphragm to the right ventricle; (d) removed pericardium; and (e) foreign body, which was a sewing needle. TEE, transesophageal echocardiography.

## DISCUSSION

There is a paucity of literature on foreign body pericardium, of which most were in pediatric age group due to ingestion of foreign body and migration from the esophagus into the mediastinum.

In our case, the patient was a young adult without a history of foreign body ingestion or trauma, presented with signs of pericarditis and it was incidentally found that foreign body was the cause. Foreign body piercing the pericardium could have caused irritation leading to pericarditis. The patient was immediately scheduled for surgical removal of the foreign body. Although patient did

not give any history of trauma, he might have accidental injury.

Perrotta *et al.*<sup>[1]</sup> reviewed relevant articles of pericardial foreign body in which they found that almost all the cases required surgical exploration and removal of foreign body.

Claudet *et al.*<sup>[2]</sup> quotes that immediately after injury, children (or adults) may have minimal clinical signs or be symptom-free when a foreign body is embedded in the myocardium or pericardial space and the presence of symptoms is a primary indication for surgery, especially in cases of cardiac tamponade, and median sternotomy is recommended if pericardiectomy is necessary.

Grocott *et al.*<sup>[3]</sup> in their review article suggested that anesthetic plan requires careful consideration of preoperative assessment and intraoperative management with hemodynamic goals targeted at maintaining preload, afterload, contractility, and heart rate along with postoperative management in the form of good analgesia, also TEE evaluation of the heart and surrounding structures adds critical information regarding the volume and composition of the pericardial fluid as well as the intracardiac blood flow velocities.

Patient had hemodynamic compromise with severe tachycardia, hypotension, cold peripheries and feeble pulse which was suggestive of low cardiac output. We used opioid induction to avoid further hemodynamic compromise. For maintenance we used inhalational anesthesia to achieve minimum anesthesia concentration 0.5–0.8 after sternotomy. Dobutamine infusion was started as patient had biventricular dysfunction. We used pulse pressure variation as a surrogate marker to titrate intravenous fluids with target of less than 13.

TEE helped in confirmation of foreign body and evaluation of cardiac function during the intraoperative period. TEE along with invasive arterial line monitoring helped in titration of inotropic support during the intraoperative period thereby avoiding hemodynamic instability. Midline sternotomy with meticulous pericardiectomy lead to immediate improvement in cardiac function and uneventful postoperative course. Slow, titrated induction and maintenance of preload, afterload and contractility for stable hemodynamics is crucial in such patients.

## CONCLUSION

Although a rare entity, foreign body in pericardium can be encountered in our clinical practice. History can be vague in such cases, thorough clinical examination and workup can help in diagnosis. Early surgical removal with meticulous anesthetic technique can reduce disease progression and help in patients' recovery.

## CONFLICTS OF INTEREST

There are no conflicts of interest.

**REFERENCES**

---

1. Perrotta S, Perrotta A, Lentini S. In patients with cardiac injuries caused by sewing needles is the surgical approach the recommended treatment?. *Interact Cardiovasc Thorac Surg* 2010; 10:783–792.
2. Claudet I, Bréhin C, Roux D, Hascoët S. Lessons learned from a thorny case. *J Thorac Cardiovasc Surg* 2015; 149:e97–99.
3. Grocott HP, Gulati H, Srinathan S, Mackensen GB. Anesthesia and the patient with pericardial disease. *Can J Anesth* 2011; 58:952.