

# A Review on Androgenic Alopecia: Etiology, Pathogenesis, Pharmacological and Non-Pharmacological Treatment Approaches

Review  
Article

*Alshimaa A. Elgobashy, Nagwa Ebrahim El-Nefiawy, Sayed M El-Sayed, Shaimaa Magdy and Walaa Adel Abdelmoez.*

*Department of Anatomy and Embryology, Faculty of Medicine-Ain Shams University.*

## ABSTRACT

**Background:** Androgenic alopecia (AGA) is one of the commonest reasons for dermatological consultation. It is characterized by progressive thinning; miniaturization of the hair follicle leading to alteration in hair cycle dynamics and a bald appearance.

**Aim of the Work:** The present review aimed to collect, present and analyze all previous data concerning etiology, pathogenesis and treatment modalities of AGA. A search was conducted in PubMed and Google Scholar using key words: etiology, pathogenesis, psychological problems or self-esteem, treatment modalities.

**Observations:** AGA has global prevalence rate ranging from 0.2% to 2%. It affects both genders as well as different races. Numerous mechanisms have been hypothesized to understand the underlying mechanism of hair follicle miniaturization occurring in AGA but it remains incompletely understood. AGA is characterized by elevated dehydrotestosterone levels and abundance of androgen receptors within the scalp. A complex genetic predisposition can also contribute to the progressive reduction and ultimate loss of hair follicles observed in AGA. The assessment of severity of AGA relies on the modified Norwood-Hamilton classification systems which can divide the hair loss into seven different stages (I-VII). Multiple treatment modalities for AGA are approved by FDA; such as topical minoxidil, oral finasteride and low-level light therapy. Other treatment options are available such as hormonal therapies, platelet-rich plasma, exosome treatments and hair transplantation. Searching for other recent modalities is still a point of recent research work.

**Conclusion:** The data examined from these studies shed light on the cutting-edge information regarding prevalence, pathogenesis, etiology and therapeutic approaches of AGA.

**Key Words:** Androgenic alopecia, causes, pathology, treatment options.

**Received:** 25 June 2024, **Accepted:** 25 July 2024.

**Corresponding Author:** Nagwa Ebrahim El-Nefiawy, Department of Anatomy, Faculty of Medicine, Ain Shams University, 12613, Egypt. **Tel.:** +00201156290585, **E-mail:** nagwaebrahim@med.asu.edu.eg

**ISSN:** 2735-3540, vol. 75, No. 3, September 2024.

## INTRODUCTION

Human physical appearance plays a significant role in shaping self-identity and social interactions. First impressions are heavily influenced by facial features and hair quality. This perception of physical attractiveness can be linked to an individual's self-image, which is associated with increased self-esteem and potentially improved mental well-being<sup>[1]</sup>.

Androgenic alopecia (AGA) is a prevalent form of hair loss that significantly upsets one's physical appearance. It is widely recognized as the most common type of alopecia. AGA manifests in approximately half of the male and female population, typically commencing after puberty.

Its hallmark features include the gradual thinning and shedding of scalp hair, exhibiting a recognizable pattern in both genders<sup>[2]</sup>. The primary causative factor in AGA is attributed to the influence of dihydrotestosterone (DHT), a metabolite of testosterone, on hair follicles susceptible to androgenic stimulation<sup>[3,4]</sup>.

In males, the initial presentation typically involves a bilateral recession of the frontal hairline at the temples [bi-temporal recession] (Figure 1)<sup>[5]</sup>. This is followed by a gradual thinning of hair on the crown of the scalp. Conversely, females experience diffuse hair loss, characterized by general weakening and reduction in hair density primarily between the forehead [frontal scalp] and the crown, with the frontal hairline often remaining relatively unaffected<sup>[6-8]</sup>.

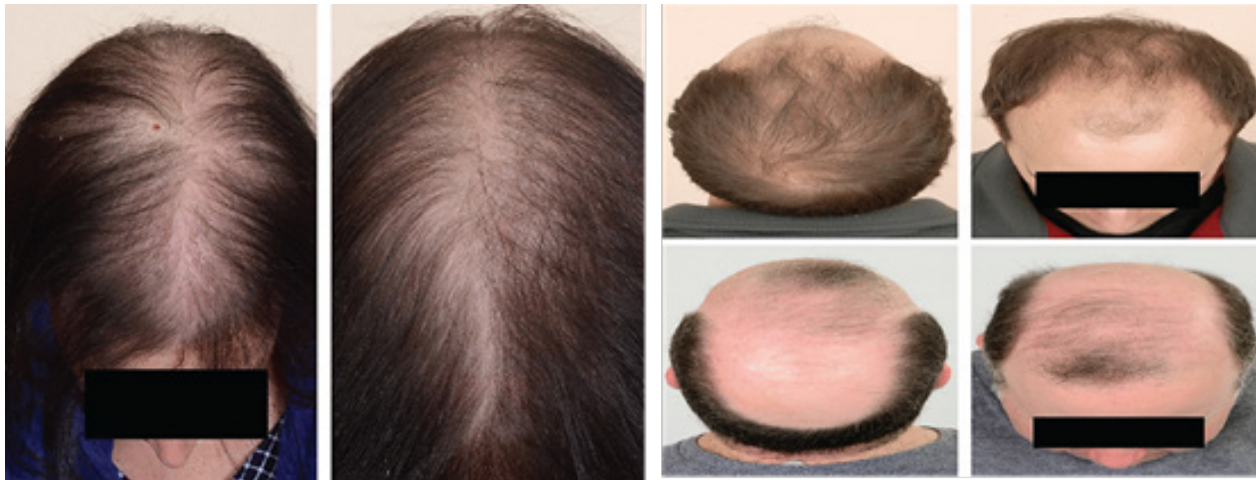

Fig. 1: Androgenic alopecia male and female pattern<sup>[5]</sup>.

### Epidemiology of AGA

Epidemiology of AGA involves; the study and analysis of the distribution, patterns and determinants of the condition. AGA reveals a global prevalence ranging from 0.2% to 2% across various populations. Intriguingly, the prevalence and severity of AGA demonstrate a well-established trend of increase with age, affecting both genders as well as races<sup>[9]</sup>. Studies showed that the prevalence of severe AGA varies significantly by geographical region with a prevalence of 15.33% overall<sup>[10,11]</sup>.

AGA exhibits a marked racial predilection, with the highest prevalence observed in Caucasian populations. East Asians and African Americans demonstrate a lower incidence, while native American and Inuit individuals are affected to the least extent. Furthermore, the disorder displays a strong association with age in 'Caucasian males', where approximately half of them are affected by the age of 50 years old and this proportion rises to 80% by the age of 70. It is noteworthy that this condition also affects females, with a significant increase in prevalence following menopause<sup>[12]</sup>. A large, multicenter investigation encompassing patients from Europe, America, Africa, and Australia revealed AGA as the predominant form of hair loss. Among 2,835 patients diagnosed with various alopecia subtypes, AGA constituted a significant (37.7%) of all cases. Furthermore, the study demonstrated a trend of increased occurrence and severity of AGA in Caucasian men compared to their Asian and African American counterparts<sup>[13]</sup>.

The investigators examined the prevalence and risk factors for AGA in a population of college freshmen in China. The study involved 9227 freshmen from two comprehensive universities across two Chinese cities. Their findings revealed a prevalence of AGA of 5.3 per 1000 individuals. Gender emerged as a significant

factor, with males exhibiting a higher prevalence of AGA compared to females<sup>[14]</sup>.

The incidence of AGA varies between genders and age groups. In men, the prevalence ranges from 47.5% to 73.2% in different age groups, with the maximum prevalence in the 41-45 years' age group<sup>[10,15]</sup>. In men, the risk of severe AGA is much higher for Jewish men compared to non-Jewish men. The most common type of AGA varies by age group, with different patterns observed in males and females. Studies have also explored the association between AGA and other factors such as BMI, gender and comorbidities like acne vulgaris and rosacea<sup>[16]</sup>.

### Etiology and pathogenesis of AGA

AGA is a complex disorder influenced by "genetic", "environmental", and "hormonal factors". While genetic predisposition and hormonal dysregulation are recognized as primary drivers, environmental influences likely contribute as well. The primary driver for AGA is an exaggerated response to androgens. This condition presents as a polygenic trait, influenced by contributions from both maternal and paternal alleles. Notably, a strong familial association exists, with male offspring exhibiting a 5- to 6-fold increased relative risk for developing AGA if their fathers experienced hair loss<sup>[17]</sup>.

Moreover, hormonal factors, specifically androgens like DHT, regulate hair growth cycles and can stimulate hair follicles excessively, resulting in shorter growth periods and thinner hair strands. Increased DHT levels contribute to the diminishment of hair follicles in AGA. Additionally, age, race, stress, certain health conditions, medications, menopause, and lifestyle factors can also influence the progression of this condition<sup>[18]</sup>.

The pattern of alopecia appears upon activation of androgen receptors, with its onset typically occurring post-puberty. This is further evidenced by the absence of this condition in pre-pubertal castrated individuals and those with androgen insensitivity syndrome. These observations collectively suggest a serious role for both androgen receptor function and hormone metabolism in the pathogenesis of the pattern of alopecia<sup>[17]</sup>.

AGA pathogenesis is characterized by a confluence of two key events: a progressive miniaturization of the hair follicle and alterations in the hair growth cycle. The hallmark pathological feature of AGA is the continual miniaturization of terminal hair follicles, ultimately leading to their conversion into vellus hairs. While numerous mechanisms have been hypothesized, the precise underlying cause of hair follicle miniaturization in AGA remains incompletely understood<sup>[19]</sup>.

Hair follicles are composite structures composed of both mesenchymal and ectodermal elements. The ectodermal contribution originates from the epidermis, invaginating downwards to penetrate the dermis and potentially reach the subcutaneous adipose tissue. Within the base of the follicle resides the hair bulb, which harbors the hair matrix. This matrix is responsible for the continuous production of the hair shaft. The mesenchymal component, on the other hand, is represented by the dermal papilla. This papilla is a localized cluster of specialized fibroblasts completely encapsulated by the hair bulb<sup>[20]</sup>.

The dermal papilla, situated within the hair bulb at the base of the follicle, plays a pivotal role in regulating diverse processes within the overlying epithelial compartment of the hair follicle. This specialized mesenchymal structure dictates the type of hair ultimately produced. While the initiating factors remain elusive, researchers propose that a decline in the cellular population of the dermal papilla represents the initial event leading to hair miniaturization<sup>[6]</sup>.

Recent research<sup>[21]</sup> have proposed an alternative pathway, suggesting that an expedited mitotic process within the hair matrix results in a diminished timeframe for differentiation. This, in turn, could lead to a subsequent increase in telogen shedding, followed by a prolonged lag phase.

The pathogenesis of androgenic alopecia involves a multipart interaction of genetic, hormonal, and environmental factors.

### **Genetic factors**

AGA is a genetically influenced, androgen-dependent dermatologic condition characterized by progressive hair loss. While more prevalent in males, AGA can also manifest in females. The development of AGA is modulated by the interplay between dihydrotestosterone (DHT), a metabolite of testosterone, and androgen receptor (AR) activity within hair follicles. Additionally, genetic polymorphisms have been recognized as contributing factors in the etiology of AGA<sup>[6]</sup>. While initial investigations posited an autosomal dominant mode of inheritance for AGA, subsequent research has refined this understanding. Current evidence suggests a polygenic model, highlighting the complex interplay of multiple genes in conferring susceptibility to AGA<sup>[18]</sup>.

Genome-wide association studies have recently identified strong association signals for AGA in the X chromosome. AR gene and the ectodysplasin A2 receptor (AR/EDA2R locus in Xq11-q12) have been strongly implicated. Various AR polymorphism and AR restriction sites have been investigated<sup>[22]</sup>. Specific AR gene polymorphism termed StuI polymorphism has been found to be linearly related to AR activity, and associated with AGA risk. The AR-E211 A allele has been found to be associated with a lower risk of alopecia, while the EDA2R gene variation causes susceptibility to AGA<sup>[18]</sup>.

Previous research<sup>[22]</sup>, suggested a polygenic component to AGA, identified 4 risk loci located in 2q35, 3q25.1, 5q33.3, and 12p12.1. The strongest association signal was seen in the locus 2q35, which contains the WNT10A gene. The WNT10A gene is expressed in the bulge region of the hair follicle during the anagen phase of the hair growth cycle and has been shown to have a genotypic effect on hair follicle expression. Other genetic loci linked to AGA have been also identified, including 1p36.22, 2q37, 7p21.1, 7q11.22, 17q21.31, 18q21.1, 20p11, and 3q26 and also a polymorphism in the APCDD1 gene, a WNT signaling inhibitor located in 18p11.2.

The identification of autosomal loci for AGA susceptibility suggests that androgen-independent pathways are also involved in AGA pathogenesis<sup>[18]</sup>. Studies also have demonstrated no participation of the well-established locus on chromosome 20p11 in female pattern hair loss (FPHL), but suggested that the locus on X-chromosome containing the AR gene and the EDA2R gene might be specifically involved in the pathogenesis of early-onset FPHL. Another genome-wide association study has suggested that the aromatase gene (CYP19A1) may contribute to FPHL<sup>[23]</sup>.

### **Hormonal factors**

AGA is hypothesized to be influenced by hormonal factors, particularly androgens like dihydrotestosterone (DHT)<sup>[24]</sup>. In individuals genetically predisposed to AGA, androgens act as key drivers of follicular miniaturization and a shortened hair growth cycle. This pathogenesis is mediated by the conversion of testosterone, the principal circulating androgen, into dihydrotestosterone (DHT) by the enzyme “5 $\alpha$ -reductase”. Notably, the expression of 5 $\alpha$ -reductase is significantly elevated within scalp hair follicles susceptible to AGA<sup>[25]</sup>. AGA exhibits a dynamic relationship with hormonal fluctuations throughout the lifespan. Puberty, pregnancy and menopause, characterized by significant shifts in androgen levels, are known to influence the onset and progression of this condition<sup>[19]</sup>.

Beyond the primary role of androgens in androgenic alopecia (AGA), estrogenic hormones and antiandrogens exert modulatory effects on androgen action within hair follicles. This underpins the potential efficacy of hormonal therapies in AGA, particularly for females. These therapies may include oral contraceptives containing antiandrogenic progestins or estrogen replacement therapy<sup>[26]</sup>. Furthermore, strong evidence suggests that insulin-like growth factor (IGF) signaling cascades may play a contributory role in the pathogenesis of AGA. These pathways exhibit crosstalk with androgen signaling, thereby exerting an influence on the hair growth cycle<sup>[27]</sup>.

### **Environmental factors**

Various environmental factors had been found to be associated with the pathogenesis of AGA<sup>[18]</sup>. Certain lifestyle habits have been correlated with AGA progression, for instance, smoking and alcohol consumption.

To fully understand the pathogenesis of AGA; the following items must be fully explained:

- A. Histology of hair.
- B. Hair cycle.

#### **A. Histology of hair**

Within the integumentary system, hair follicles and their keratinized product, hair, are ubiquitous appendages found throughout most body regions. Exceptions include the palms, soles, lips, and urogenital openings. Sex hormones exert a significant influence on the distribution, texture, and pigmentation of hair. Hair follicles not only produce hair, but also contribute epithelial stem cells essential for wound healing<sup>[28]</sup>.

During human development, skin appendages originate from the downward extension of the epidermis. Each hair follicle signifies an invagination of the epidermis that occurs during hair formation. A distinct glassy basement membrane, known as the dermal sheath or hair-specific basal lamina, demarcates the hair follicle from the surrounding dermal connective tissue<sup>[29]</sup>.

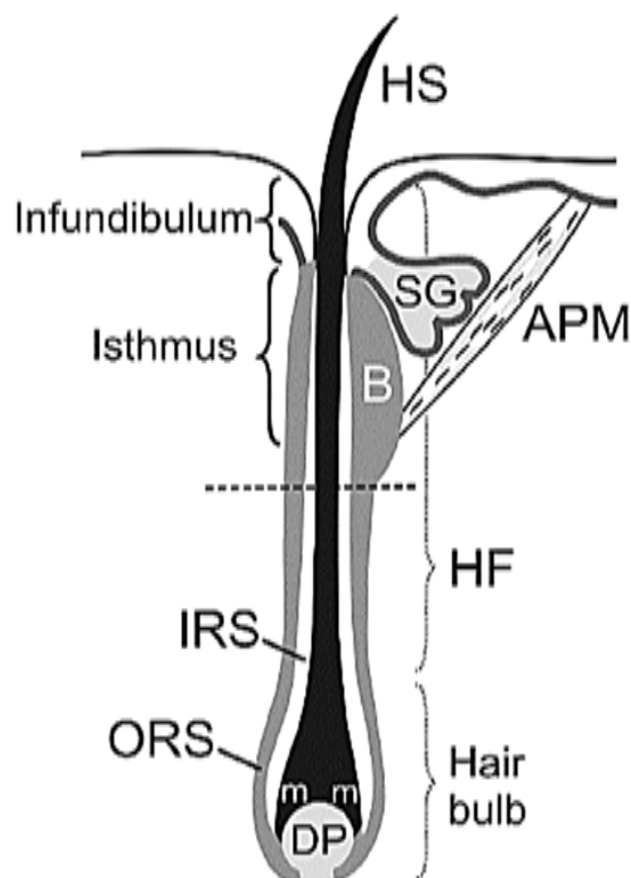
**There are 3 sections of the hair follicles (Figure 2)<sup>[11]</sup>:**

- “Infundibulum”
- “Isthmus”
- “Inferior segment”

The infundibulum, the uppermost portion, extends from the epidermal invagination to the sebaceous gland's opening. This region is part of the pilo-sebaceous unit, facilitating sebum expression. Below the infundibulum lies the isthmus, reaching the level of the arrector pili muscle insertion. This muscle connects to the hair follicle and surrounding dermis, and its contraction in response to very low temperatures causes the hair to stand upright. Finally, the deepest segment, the inferior region, expands into the hair bulb. At the bulb's base resides the dermal papilla, a vital structure providing blood supply necessary for hair follicle growth. Within the hair follicle, the dermal papilla, a mesenchymal invagination of the dermis, interacts with the surrounding dermal sheath. This sheath harbors progenitor cells that function in both the renewal of the dermal papilla and the promotion of wound healing processes<sup>[30]</sup>.

Epithelial stem cells within the hair bulb, known as matrix cells, are responsible for hair follicle and subsequent hair growth through their continuous proliferation. This process is cyclical and can be categorized into three distinct phases: “anagen”, “catagen”, and “telogen”, collectively referred to as the hair cycle. Hair pigmentation is caused by melanocytes residing within the matrix cell layer. These melanocytes produce melanosomes that influence hair color. The epithelial cells that make up the hair germ (germ layer) are in close proximity to the mesenchymal dermal papilla cells. These two components interact to promote signal transduction from the hair germ, which in turn causes the activation of stem cells in the hair bulge and the start of the anagen phase. As these matrix cells in the germ layer undergo division, they differentiate into two distinct lineages: the internal root sheath and the keratinocytes responsible for hair shaft formation (specifically, the cuticle and cortex layers)<sup>[31]</sup>.





**Fig. 2:** Hair anatomy. The hair root comprises a hair follicle (HF), a hair bulb, and a dermal papilla (DP). The outer root sheath (ORS) is a direct continuation of the Malpighian layer of the epidermis. The bulge (B) is located at the insertion site of the arrector pili muscle (APM) into the ORS. The insertion of the sebaceous gland (SG) duct forms the anatomical interface between the infundibulum and isthmus. A dotted line separates an upper transient portion of the hair from a lower permanent portion. IRS, inner root sheath; m, matrix; HS, hair shaft<sup>[11]</sup>.

Residing within the hair follicle, the internal root sheath encases the lower portion of the hair shaft. Notably, the internal root sheath is composed of three distinct layers, differentiated from the surrounding layers of the hair follicle itself. The layers of the internal root sheath are as follows:

- “Cuticle”
- “Huxley’s layer”
- “Henle’s layer”

The cuticle consists of flattened, overlapping corneocytes (keratinized cells) that have lost their nuclei. The Huxley layer occupies the middle position and is composed of approximately two cell strata. The outermost layer, the Henle layer, directly abuts the external root

sheath. All three layers of the internal root sheath (IRS) contribute to the developing hair shaft by synthesizing and depositing keratin and trichohyalin granules<sup>[31]</sup>.

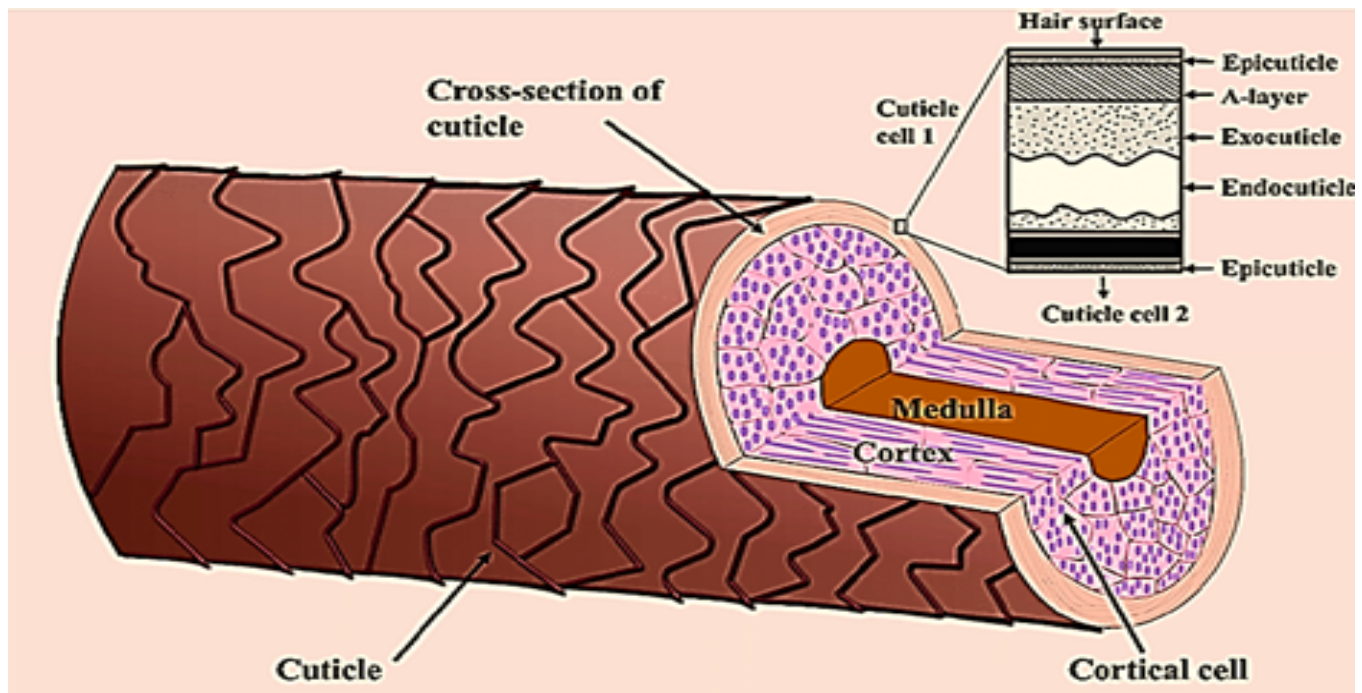
Within the hair follicle's histological structure, the external root sheath serves a dual function. Firstly, it provides the attachment site for the arrector pili muscle, influencing hair erection. Secondly, it facilitates the pilosebaceous unit, a functional complex encompassing the hair follicle and the sebaceous gland. Notably, the region adjacent to the arrector pili attachment and the sebaceous duct origin, termed the follicular bulge, harbors a population of undifferentiated epithelial stem cells. These resident stem cells play a crucial role in hair follicle growth by contributing to its ongoing renewal. Furthermore, their remarkable plasticity extends beyond the follicle, as they possess the capacity to migrate towards sites of epidermal injury and actively participate in the wound healing process<sup>[32]</sup>.

Hair is keratinized cells originating from the hair follicles, where pigment-producing cells in the dermal papilla contribute to hair pigmentation by extending melanin into the hair cortex. These hair shafts exhibit a stratified structure upon microscopic examination<sup>[28]</sup>.

**Histologically, hairs contain two or three layers (Figure 3)<sup>[33]</sup>:**

- Medulla
- Cortex
- Cuticle

The hair shaft exhibits a layered structure, with the innermost region being the medulla. However, the presence of the medulla is restricted to hairs with a larger diameter. The middle layer, termed the cortex, comprises cuboidal cells that undergo differentiation to become specialized keratinocytes. These keratinocytes are responsible for the hair shaft's structural integrity. The outermost layer, the cuticle, interfaces directly with the internal root sheath's cuticle. Analogous to the cortex, the cuticle is composed of flattened, keratinized cells derived from the hair follicle's matrix progenitor cells during the growth phase. These differentiating cells lose their nuclei and become filled with keratin, ultimately forming a cohesive external layer that anchors the growing hair shaft within the follicle while providing mechanical reinforcement and protection<sup>[34]</sup>.



**Fig. 3:** Schematic presentation showing the three main layers of a hair strand; the cuticle, cortex, and medulla. The inner hair structure (i.e., the cortex and medulla) is surrounded by several layers of cuticle cells<sup>[33]</sup>.

## B. Overview of Hair Cycle

Hair growth follows a cyclical pattern consisting of four distinct phases (Figure 4)<sup>[19]</sup>: anagen [growth], catagen [regression], telogen [rest], and exogen [shedding]. Each hair follicle operates independently, undergoing this cycle 10-30 times throughout an individual's lifespan. While a typical scalp houses roughly 100,000 hairs at any given moment, a healthy shedding rate involves losing 100-150 hairs in the telogen phase daily. Due to the asynchronous nature of hair follicles, hair density and count remain relatively stable under healthy conditions.

The anagen phase, the longest, persists for 2-8 years in scalp hair. Conversely, eyebrow hair follicles have a considerably shorter anagen phase, typically ranging from two to three months<sup>[35]</sup>.

At the catagen phase, hair growth undergoes a critical transition from active anagen phase to resting telogen phase. This brief period, lasting approximately two weeks, is characterized by follicular regression. The hair follicle detaches from the dermal papilla, this detachment triggers apoptosis, within the epithelial cells of the follicular bulb. Following catagen, a successful transition relies upon the upward migration of the dermal papilla towards the bulge region of the hair follicle. However, if the dermal papilla

fails to reach the bulge during this critical window, hair follicle cycling ceases altogether leading to permanent hair loss<sup>[35]</sup>.

The telogen phase typically lasts for two to three months. During this period, approximately 9% of scalp hair follicles reside in a resting state, compared to a significantly higher proportion (40-50%) observed in hair follicles on the body trunk. While telogen hairs remain dormant, new hair growth commences at the base of the follicle, ultimately displacing the resting hairs. However, a disruption in the hair cycle can occur when the anagen phase prematurely transitions into the telogen phase. This phenomenon, characterized by excessive hair shedding and subsequent thinning, is known as telogen effluvium (TE)<sup>[36]</sup>.

Conversely, hair loss can be managed by minimizing the proportion of hair follicles within the telogen (resting) phase. Finally, the exogen phase signifies the conclusion of telogen and the commencement of anagen (growth). During this transitional period, the development of new hair shafts progresses upwards, physically displacing the club hair (resting hair) and culminating in its eventual shedding<sup>[35]</sup>.

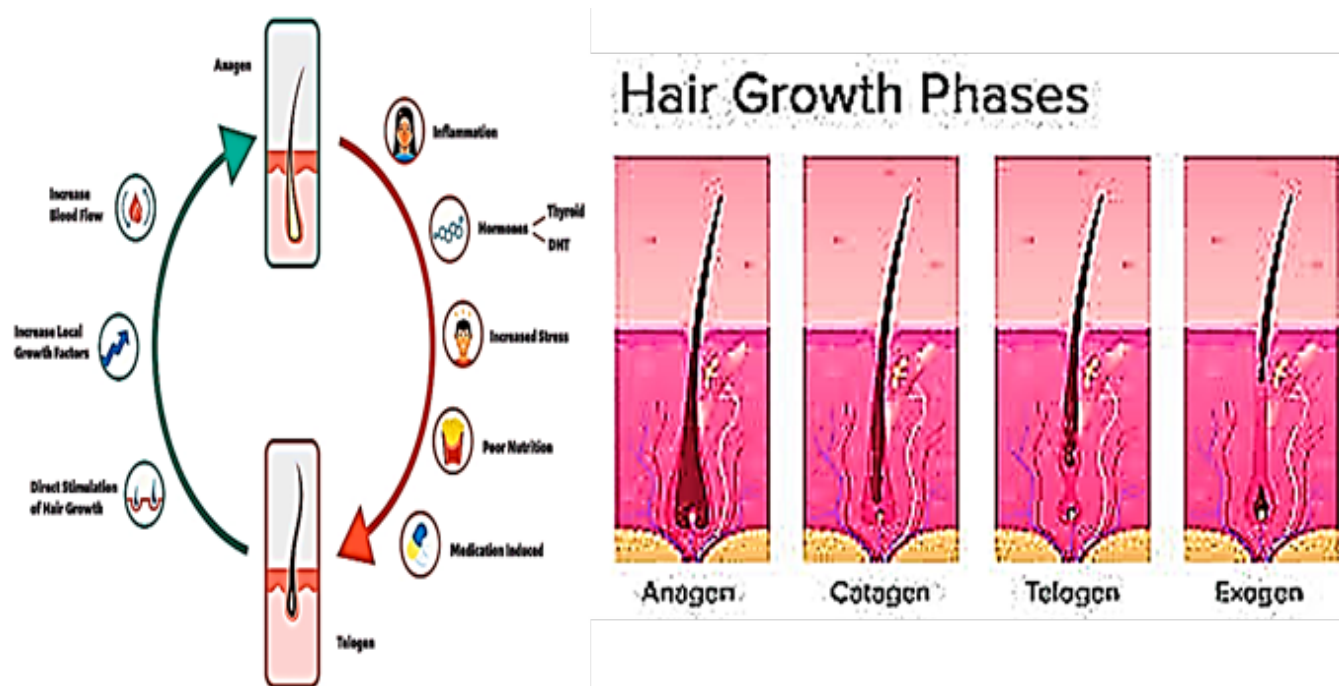


Fig. 4: Hair growth cycle and the factors influence a transition from anagen to telogen vs. telogen to anagen phase<sup>[19]</sup>.

### Diagnosis of Androgenic alopecia

AGA is characterized by a progressive decline in scalp hair density and caliber. This manifests clinically as a receding frontal hairline, vertex balding, or a combination of these presentations<sup>[6]</sup>. Manifestations may be associated with endocrine disorders such as polycystic ovary syndrome (PCOS)<sup>[37]</sup>. The diagnosis of AGA relies on: clinical evaluation and disease grading<sup>[18]</sup>.

The assessment of AGA severity is managed through modified Norwood-Hamilton classification. It divides hair loss into seven stages (I-VII), with stage I representing no hair loss and stage VII representing complete baldness on the top and front of the scalp. Each stage is further divided into a letter (a, b, c) to describe the degree of hair loss at the temples. For example, stage IIIa represents moderate hair loss at the temples with a receding hairline, while stage IIIc represents more extensive hair loss at the temples and vertex (crown) of the scalp<sup>[38]</sup>.

Trichoscopy, a non-invasive diagnostic tool, has emerged as a valuable complement to traditional methods. By enabling high-resolution examination of hair follicles, trichoscopy offers a unique advantage in the diagnosis of AGA and subsequent monitoring of treatment efficacy in patients<sup>[39]</sup>. Furthermore, growing evidence suggests an association between AGA and metabolic syndrome. Notably, the occurrence of metabolic syndrome and its constituent components demonstrated a statistically significant increase with escalating severity grades of

AGA<sup>[40]</sup>. A study investigating AGA as a marker of metabolic syndrome revealed a 10.1% prevalence of metabolic syndrome among the patient population. This prevalence exhibited a significant association with subjects exceeding four decades of age, wedded participants, individuals of low socioeconomic status and participants with no formal education<sup>[41]</sup>.

Investigations into diagnostic criteria for AGA in pediatric populations emphasize the rarity of prepubertal presentation. However, the occurrence of prepubertal AGA warrants suspicion of underlying conditions. Notably, secondary etiologies of AGA, including conditions such as premature adrenarche and polycystic ovary syndrome (PCOS)<sup>[42]</sup>.

Diagnosis of AGA can involve the use of monoclonal antibodies to target specific antigens associated with the condition<sup>[43]</sup>. Diagnosis of AGA can utilize vascular endothelial growth factor (VEGF) monoclonal antibodies for assessment. Research indicates that VEGF plays a crucial role in angiogenesis and vascular maintenance around hair follicles, with lower levels observed in alopecic areas compared to healthy scalp tissue. Furthermore, studies suggest that upregulating VEGF through topical immunotherapy can lead to increased VEGF expression in hair follicles, promoting angiogenesis and potentially aiding in AGA treatment<sup>[44]</sup>.

### **Treatment modalities of AGA**

Androgenic alopecia can be treated through various methods. Treatment options may include medications such as “minoxidil” and “finasteride”, “low-level laser therapy”, “platelet-rich plasma (PRP) therapy”, “hair transplant surgery”, “stem cell therapy”, and “rosemary oil”<sup>[37]</sup>. These treatments aim to slow down or reverse the progression of AGA by targeting the androgen receptor, disrupting the hair follicle cycle, or promoting hair growth. Additionally, combination therapies have been explored to assess their synergistic effects<sup>[45]</sup>.

### **Minoxidil**

Minoxidil, a piperidinopyrimidine derivative, possesses the following chemical structure: 2,6-diamino-4-piperidinopyrimidine-1-oxide (C<sub>9</sub>H<sub>15</sub>N<sub>5</sub>O). Minoxidil solution (MS) is formulated with a vehicle system comprised primarily of water. Additional inactive ingredients, such as ethanol and propylene glycol (PG), are incorporated to enhance the drug's solubility. While PG facilitates efficient delivery of minoxidil to the hair follicles, its propensity to induce localized irritation has led to the development of a propylene glycol-free minoxidil foam (MF)<sup>[46]</sup>. In comparison to MS, MF appears to demonstrate enhanced delivery of the active ingredient to the target site. This potentially translates to improved drug penetration with a reduced risk of irritation. This finding is further supported by the approval granted by the Food and Drug Administration (FDA) for the use of 5% MF in the treatment of AGA. Additionally, MF offers increased convenience due to its rapid drying properties and minimal spread to surrounding areas<sup>[47]</sup>.

The well-documented hair growth promoting effects of minoxidil are primarily attributed to its active metabolite, minoxidil sulfate. This conversion is mediated by sulfotransferase enzymes localized within hair follicles, with individual variability observed in enzyme production levels<sup>[48]</sup>. In addition, human scalp tissue expresses two phenol sulfotransferases responsible for the sulfation of minoxidil. Studies have demonstrated a positive correlation between the activity of these enzymes and the efficacy of topical minoxidil treatment for hair growth. Interestingly, serum or tissue concentrations of minoxidil itself do not exhibit a similar association with hair growth outcomes. Notably, salicylate and aspirin possess inhibitory effects on sulfotransferase activity. A recent investigation revealed a decrease in follicular enzymatic activity following a fourteen-day regimen of low-dose aspirin. These findings suggest that prior or concurrent use of aspirin may diminish the clinical response to topical minoxidil treatment<sup>[47]</sup>.

Following topical application, only a minimal amount (approximately 1.4%) of minoxidil penetrates a healthy scalp. This percutaneous absorption can be influenced

by several factors. Higher drug concentrations, increased application frequency, and compromised stratum corneum integrity (the outermost layer of the skin) all contribute to enhanced systemic uptake. Notably, less than 1% of the topically applied minoxidil reaches the systemic circulation. Furthermore, minoxidil exhibits minimal plasma protein binding and does not traverse the blood-brain barrier. The majority (approximately 95%) of the absorbed drug and its metabolites undergo renal elimination within a four-day timeframe<sup>[49]</sup>.

Topical minoxidil exhibits a multifaceted mechanism of action in promoting hair growth. Beyond its established vasodilatory and anti-inflammatory properties, minoxidil has been shown to induce the Wnt/ $\beta$ -catenin signaling pathway and possess anti-androgenic effects. These diverse actions suggest the potential for minoxidil to influence hair follicle cycling through multiple potentially interconnected pathways. Notably, minoxidil stimulates the release of vascular endothelial growth factor (VEGF) within dermal papilla cells, leading to the activation of the VEGF-associated  $\beta$ -catenin signaling cascade.  $\beta$ -catenin, a cytoplasmic transcriptional regulator whose accumulation is mediated by the Wnt pathway, plays a crucial role in hair follicle regeneration<sup>[49]</sup>.

Minoxidil exerts its hair growth promoting effects through a multifaceted mechanism. One aspect involves its anti-androgenic properties, leading to a downregulation of  $5\alpha$ -reductase type 2 gene expressions. This enzyme plays a crucial role in the conversion of testosterone to dihydrotestosterone (DHT), a potent androgen implicated in androgenic alopecia (AGA). By inhibiting  $5\alpha$ -reductase type 2, minoxidil indirectly reduces the levels of DHT within the hair follicle microenvironment. Additionally, minoxidil stimulates DNA synthesis within the anagen bulb, the actively growing hair follicle compartment. This enhanced cellular proliferation is hypothesized to trigger the premature activation of secondary germ cells residing in telogen (resting) follicles, thereby promoting an earlier transition into the anagen phase [50]. Furthermore, minoxidil may influence the hair growth cycle by extending the duration of the anagen phase, shortening the telogen phase, or potentially exerting both effects. Research has also explored the potential application of topical minoxidil in alopecia areata, an autoimmune form of hair loss. The underlying mechanism is thought to involve the inhibition of immunological processes at the site of application, potentially contributing to hair regrowth in AGA patients<sup>[50]</sup>.

Although minoxidil is generally well tolerated, topical minoxidil is associated with the following adverse effects<sup>[43]</sup>. Telogen effluvium; Minoxidil can shorten the telogen (resting) phase of the hair cycle, leading to a transient increase in hair shedding. Scalp irritation;



Minoxidil application may cause erythema (redness), discomfort, and a burning sensation on the scalp. Scalp desquamation; Minoxidil use can induce scalp scaling, potentially worsening existing seborrheic dermatitis. Localized pruritus; Itching may occur at the application site and allergic contact dermatitis. Both oral and topical minoxidil can cause unwanted hair growth (hypertrichosis). This is more frequent with the oral form and higher concentration of topical solutions (5% vs. 2%). The extended anagen (growth) phase induced by minoxidil is believed to contribute to hypertrichosis. Notably, cases of infant hypertrichosis have been reported due to inadvertent topical exposure<sup>[51]</sup>.

### **Finasteride**

Studies have explored the use of topical finasteride formulations for the treatment of hair loss. These formulations demonstrate promise, with some exhibiting a significant ability to reduce both plasma and scalp levels of DHT<sup>[52]</sup>. Previous pioneering study<sup>[53]</sup> investigated the potential of topical finasteride for hair regrowth in AGA. Their single-blind, placebo-controlled trial with 52 participants yielded promising results, demonstrating both hair regrowth and a reduction in balding areas. Notably, the authors reported no adverse effects associated with the treatment.

While one study suggests topical finasteride gel may be equally effective as its oral counterpart, the comparative research has been limited to durations of only six months. Furthermore, the lack of standardization among compounded topical formulations hinders assessment of their true efficacy<sup>[52]</sup>. Topical finasteride is typically prescribed for chronic use with a once-daily application regimen. However, data regarding patient adherence to this treatment schedule is currently unavailable<sup>[52]</sup>. Oral finasteride has been approved for the treatment of male pattern baldness since 1997. It functions via inhibiting type (II) 5-alpha-reductase enzyme, thereby blocking the conversion of testosterone to DHT. It is available in 1 mg and 5 mg tablets, of which the lower dose is indicated for male pattern baldness. This drug can be purchased over the counter which has made it much more cost-effective for patients. It is not approved for use in women and is assigned to pregnancy category X due to risk of causing ambiguous genitalia in a male fetus<sup>[54]</sup>.

Potential adverse effects associated with topical finasteride use have been documented, including localized skin reactions like erythema (redness) and contact dermatitis. Additionally, some studies have reported elevated liver enzymes, nocturnal enuresis, testicular pain, headaches, and oropharyngeal pain<sup>[52]</sup>. Also, finasteride administration exhibits a range of adverse effects in a significant portion of patients. These include orthostatic

hypotension (approximately 9%), dizziness (7%), and sexual dysfunction encompassing erectile dysfunction (5-19%), ejaculatory dysfunction (1-7%), and decreased libido (2-10%). Due to this potential for sexual dysfunction, clinicians are advised to approach finasteride treatment for AGA with caution. Furthermore, a recognized syndrome termed Post-Finasteride Syndrome (PFS) encompasses a cluster of sexual side effects alongside neuropsychiatric effects, including depression<sup>[55]</sup>.

### **Low-level laser therapy**

The discovery of low-level laser therapy (LLLT) for AGA treatment arose from an unexpected observation in the 1960s. During an experiment, mice exposed to low-dose red laser irradiation exhibited increased hair growth. This chance finding sparked further investigation over several decades, culminating in the emergence of LLLT as a more commercially accessible therapeutic approach for AGA. LLLT is typically administered through home-use devices that are available in the forms of combs, helmets, and caps. The Capillus® laser cap and Hairmax® Lasercomb/Laserband are two such devices that are FDA-cleared for the management of AGA<sup>[56]</sup>. The mechanism of action is not completely elucidated; however, it is believed that red light absorption by cytochrome c oxidase (CCO) in mitochondria leads to photodissociation of inhibitory nitric oxide (NO), which causes increased ATP production, reactive oxygen species modulation, and transcription factor induction. These transcription factors induce protein synthesis and lead to downstream effects of NO-related vasodilation. Other proposed theories include a mechanism of action similar to that of minoxidil with blood flow promotion in the scalp via NO production and reduced follicular inflammation<sup>[37]</sup>. A low incidence of adverse events was associated with LLLT administration. These events, reported by a limited subset of participants, included acneiform eruptions, mild paresthesias (burning sensation), xeroderma (dry skin), cephalalgia (headache), and pruritus (itching)<sup>[57]</sup>.

### **Platelet-rich plasma**

Platelet-rich plasma (PRP) therapy emerges as a minimally-invasive treatment option for AGA, particularly advantageous due to its lack of post-procedural patient requirements. PRP is best suited for individuals in the early stages of AGA. This strategic targeting capitalizes on the presence of intact hair follicles, thereby optimizing the potential for hair restoration<sup>[41]</sup>.

During the procedure, approximately 10–30 mL of blood are drawn from the patient's vein and centrifuged for 10 min in order to separate the plasma from red blood cells. The platelet-rich plasma, containing numerous growth factors, is then injected into the deep dermis or subcutaneous tissue at a volume of 4–8 mL per session.

Mild side effects include scalp pain, headache, and burning sensation, but these effects usually subside in 10–15 min post-injection and do not warrant use of topical anesthesia or pain medications<sup>[58]</sup>. Vibration or cool air is typically sufficient to alleviate any significant pain that a patient may feel from the treatment. Patients can resume regular activities immediately after treatment but should avoid strenuous physical activity 24h post-treatment to allow for optimal absorption of PRP into tissue<sup>[58]</sup>.

While PRP injections generally exhibit a favorable safety profile when administered by qualified healthcare professionals, their application is not universally appropriate. Contraindications for PRP therapy may include bleeding disorders, autoimmune conditions, or active infections. Additionally, patients currently taking anticoagulant medications are not typically considered ideal candidates. Although the majority of patients appear to tolerate the discomfort associated with scalp injections, some may seek alternative approaches due to pain sensitivity<sup>[3]</sup>.

### ***Exosomes derived stem cell therapy***

Mesenchymal stem cell-derived exosomes (MSC-Exosomes) emerge as a novel and promising avenue in regenerative medicine. These exosomes, characterized by their nanoscale size and membrane-bound structure, are released by mesenchymal stem cells and function as facilitators of intercellular communication<sup>[59]</sup>. The cellular nature of exosomes translates to a new therapeutic approach with minimal risk of immunogenic response and tumorigenesis. Their therapeutic potential extends beyond a single organ system<sup>[60]</sup>. Current research explores the use of exosomes for treating various medical conditions in the pulmonary, cardiac, neurological systems, and beyond. Notably, mesenchymal stem cell (MSC) exosomes demonstrate promising applications in hair restoration. This effect is attributed to their cargo of potent cytokines and growth factors known to stimulate hair growth<sup>[60]</sup>.

Previous investigation<sup>[61]</sup> demonstrated that injecting exosomes derived from dermal papilla cells into mice accelerated the initiation of the hair follicle's anagen phase while delaying the catagen phase. This effect was accompanied by increased expression of beta-catenin and sonic hedgehog, both well-established hair growth promoting factors, further supporting the therapeutic potential of exosomes for hair restoration. It was reported<sup>[62]</sup> that a significant increase in both mean hair density and thickness in 20 patients following a 12-week exosome treatment regimen. Their study suggested that exosomes promote hair growth through multiple mechanisms: stimulating proliferation of hair follicle cells, accelerating transition from telogen to anagen phase, and protecting

these cells from oxidative damage. These findings highlight the promise of exosome-based therapies, such as ExoFlo<sup>®</sup> and ExoCel<sup>®</sup>, as novel and potentially effective approaches for hair restoration. Paralleling the administration of PRP, MSC-exosome therapy involves scalp injections with potential variations in treatment frequency based on the severity of AGA. Despite these initial explorations, further research is necessary to optimize treatment protocols for routine clinical application of MSC-exosomal therapies in managing AGA. This optimization process may involve refining injection techniques, dosage regimens, and treatment schedules to maximize efficacy<sup>[3]</sup>. Exosomal hair restoration can be performed as an in-clinic procedure, minimizing patient burden and recovery time. To achieve optimal hair regrowth, this treatment typically requires monthly injection sessions. Mild, transient pain at the injection site on the scalp is the most frequently reported side effect, typically resolving within 24-48 hours<sup>[3]</sup>.

### ***Micro-needling***

Micro-needling mechanism of action is thought to involve a multifaceted approach. It potentially stimulates the release of growth factors and activates stem cells associated with the dermal papilla. Additionally, the physical micro-wounds created by the needles trigger wound healing mechanisms, leading to collagen formation. Finally, micro-needling may enhance the penetration of topically applied medications by creating temporary channels in the skin. Research suggests that micro-needling is a safe and effective complementary therapy, potentially improving the efficacy of topical treatments due to increased penetration<sup>[63]</sup>. It was first noted in 100 male patients with mild-to-moderate AGA who were randomized into 5% minoxidil lotion twice daily group or 5% minoxidil lotion twice daily plus micro-needling once weekly group. Significant improvements were noted in the combined treatments group per investigator's and subjects' ratings, as well as hair counts<sup>[64]</sup>.

Also, other authors<sup>[65]</sup> reported superior clinical outcomes seen in the PRP, micro-needling, and topical minoxidil patients vs. monotherapy patients. There is evidence that micro-needling preceding PRP enhances the efficacy of PRP as the pinpoint bleeding provoked by micro-needling allows more uniform absorption of PRP ; there is lack of standardization in this method of treatment. In a study investigating optimal needle depth for hair restoration, the authors<sup>[66]</sup> proposed 0.6 mm to be a more favorable option compared to 1.2 mm. Micro-needling is performed within a clinical setting. The procedure is associated with several potential drawbacks, including patient discomfort, bruising, and folliculitis development. Treatment adherence is a critical factor for successful outcomes, particularly considering high cost and potential discomfort associated with micro-needling<sup>[3]</sup>.

## ***Hair transplantation***

Patients that are optimal for hair transplantation have either failed medical therapy or have lost a significantly large and non-recoverable surface area of scalp hair that can only be treated by implanting new hairs into the area. The procedure, if done successfully, induces a natural-appearing look in both men and women and essentially lasts permanently with graft survival among AGA patients being greater than 90%<sup>[67]</sup>. Hair transplantation can be performed in an outpatient setting using topical anesthesia, allowing for same-day completion within a few hours. Lidocaine solution (0.5–1.0%) with epinephrine is commonly employed for regional anesthesia (field block) or local infiltration to achieve adequate pain control. Due to the potentially extended duration of the procedure, additional anesthetic injections may be necessary at regular intervals<sup>[3]</sup>. Patient evaluation for hair transplantation necessitates consideration of several critical factors. One such factor is the caliber, or thickness, of the donor hair follicles. This characteristic impacts the perceived density of the transplanted hair more significantly than the sheer number of follicles transplanted. Additionally, the Norwood/Ludwig classification system plays a crucial role in assessing a patient's suitability for hair transplantation. This system categorizes the pattern and severity of hair loss, providing valuable information for treatment planning<sup>[68]</sup>. Potential adverse events associated with the procedure include: reactions to anesthesia, bleeding, pain, edema, intra-operative or post-operative discomfort, and patient dissatisfaction with the cosmetic outcome. Additionally, Follicular Unit Extraction (FUE) may pose a specific risk of developing keloid or hypertrophic scars during wound healing. These are raised, thickened scars that can be aesthetically displeasing<sup>[3]</sup>.

## **CONCLUSION**

---

Androgenic alopecia occurs in men and women and is characterized by loss of hair from the scalp in a defined pattern. Determining factors appear to be genetic predisposition coupled with the presence of sufficient circulating androgens. The prevalence of this condition is high (up to 50% of white males are affected by 50 years of age) and although there are no serious direct health consequences; the loss of scalp hair can be distressing. The pathogenesis of AGA involves; pre-programmed follicles on the scalp undergo a transformation from anagen and short rest telogen cycles, to long rest and short growth cycles. This process is coupled with progressive miniaturization of the follicle. These changes are androgen dependent, and require the inheritance of several genes. To date, only one of these genes, which encodes the androgen receptor (AR), has been identified. Of the many treatments available for androgenic alopecia, only two medications (finasteride and minoxidil) have FDA approval and demonstrated successful results. However, these therapies are variable in

their effectiveness and carry many undesired side effects. Discovery of the involvement of the AR gene, and the identification of other genes contributing to the condition, might lead to the development of new and more effective therapies that target the condition at a more fundamental level.

## **FUNDING**

---

There was no funding grant.

## **CONFLICT OF INTEREST**

---

The authors declare no conflict of interest.

## **LIST OF ABBREVIATIONS**

---

AGA: androgenetic alopecia.

FDA: Food and drug administration.

DHT: dihydrotestosterone

BMI: Body mass index

AR: androgen receptor.

FPHL: female pattern of hair loss

IGF: insulin like growth factor.

IRS: inner root sheath.

TE: telogen effluvium.

PCOS: polycystic ovary syndrome.

MSC: mesenchymal stem cells.

PRP: platelet rich plasma.

FUE: Follicular Unit Extraction.

LLLT: Low level laser therapy.

CCO: cytochrome c oxidase.

NO: nitric oxide.

PFS: Post-Finasteride Syndrome.

VGEF: vascular endothelial growth factor.

---

## REFERENCES

1. Adamowicz, R., Załęcki, P., Dukiel, A., and Nowicka, D. (2022). Association between androgenetic alopecia and psychosocial disease burden: A cross-sectional survey among Polish men. *Dermatology research and practice*, 2022.
2. Ntshingila, S., Oputu, O., Arowolo, A. T., and Khumalo, N. P. (2023). Androgenetic alopecia: An update. *JAAD international*, 13, 150-158.
3. Nestor, M. S., Ablon, G., Gade, A., Han, H., and Fischer, D. L. (2021). Treatment options for androgenetic alopecia: Efficacy, side effects, compliance, financial considerations, and ethics. *Journal of cosmetic dermatology*, 20(12), 3759–3781. <https://doi.org/10.1111/jocd.14537>
4. Philipsen, M. H., Haxen, E. R., Manaprasertsak, A., Malmberg, P., and Hammarlund, E. U. (2021). Mapping the chemistry of hair strands by mass spectrometry imaging—a review. *Molecules*, 26(24), 7522.
5. Tamashunas, N. L., and Bergfeld, W. F. (2021). Male and female pattern hair loss: Treatable and worth treating. *Cleveland Clinic Journal of Medicine*, 88(3), 173-182.
6. Asfour, L., Cranwell, W., and Sinclair, R. (2023). Male androgenetic alopecia. *Endotext* [Internet].
7. Fabbrocini, G., Cantelli, M., Masarà, A., Annunziata, M. C., Marasca, C., and Cacciapuoti, S. (2018). Female pattern hair loss: A clinical, pathophysiologic, and therapeutic review. *International journal of women's dermatology*, 4(4), 203-211.
8. Ceruti, J. M., Leirós, G. J., and Balañá, M. E. (2018). Androgens and androgen receptor action in skin and hair follicles. *Molecular and cellular endocrinology*, 465, 122–133. <https://doi.org/10.1016/j.mce.2017.09.009>
9. He H, Xie B, and Xie L. (2018). Male pattern baldness and incidence of prostate cancer: A systematic review and meta-analysis. *Medicine (Baltimore)*. 2018 Jul;97(28): e11379.
10. Salman, K. E., Altunay, I. K., Kucukunal, N. A., and Cerman, A. A. (2017). Frequency, severity and related factors of androgenetic alopecia in dermatology outpatient clinic: hospital-based cross-sectional study in Turkey. *Anais brasileiros de dermatologia*, 92(1), 35–40. <https://doi.org/10.1590/abd1806-4841.20175241>
11. Rishikaysh, P., Dev, K., Diaz, D., Qureshi, W. M. S., Filip, S., and Mokry, J. (2014). Signaling involved in hair follicle morphogenesis and development. *International journal of molecular sciences*, 15(1), 1647-1670.
12. Mahmoudi, H., Salehi, M., Megados, S., Ghandi, N., Teimourpour, A., and Daneshpazhooh, M. (2018). Dermoscopic findings in 126 patients with alopecia areata: A cross-sectional study. *International journal of trichology*, 10(3), 118-123.
13. Vañó-Galván S, Saceda-Corrado D, Blume-Peytavi U, *et al.*, (2019): Frequency of the Types of Alopecia at Twenty-Two Specialist Hair Clinics: A Multicenter Study. *Skin Appendage Disorder*. 2019 Aug;5(5):309-315. doi: 10.1159/000496708. Epub 2019 Apr 2.
14. He, F., Shen, M., Zhao, Z., Liu, Y., Zhang, S., Tang, Y., and Li, J. (2022). Epidemiology and disease burden of androgenetic alopecia in college freshmen in China: A population-based study. *PLoS One*, 17(2), e0263912.
15. Tamashunas, N. L., and Bergfeld, W. F. (2021). Male and female pattern hair loss: Treatable and worth treating. *Cleveland Clinic Journal of Medicine*, 88(3), 173-182.
16. Adamowicz, R., Załęcki, P., Dukiel, A., and Nowicka, D. (2022). Association between androgenetic alopecia and psychosocial disease burden: A cross-sectional survey among Polish men. *Dermatology research and practice*, 2022.
17. Ho CH, Sood T and Zito PM. (2024): Androgenetic Alopecia. 2024 Jan 7. In: *StatPearls* [Internet]. Treasure Island (FL): StatPearls Publishing; 2024 Jan-. PMID: 28613674.
18. Kidangazhiathmana, A., and Santhosh, P. (2022). Pathogenesis of androgenetic alopecia. *Clinical Dermatology Review*, 6(2), 69-74.
19. Grymowicz, M., Rudnicka, E., Podfigurna, A., Napierala, P., Smolarczyk, R., Smolarczyk, K., and Meczekalski, B. (2020). Hormonal Effects on Hair Follicles. *International journal of molecular sciences*, 21(15), 5342. <https://doi.org/10.3390/ijms21155342>
20. Abreu, C. M., and Marques, A. P. (2021). Recreation of a hair follicle regenerative microenvironment: Successes and pitfalls. *Bioengineering & translational medicine*, 7(1), e10235. <https://doi.org/10.1002/btm2.10235>



21. **Guarrera, M., and Rebor, A. (2019).** The higher number and longer duration of kenogen hairs are the main cause of the hair rarefaction in androgenetic alopecia. *Skin Appendage Disorders*, 5(3), 152-154.
22. **Heilmann, S., Kiefer, A. K., Fricker, N., Richer, D., Hillmer, A. M., Herold, C., and Nöthen, M. M. (2013).** Androgenetic alopecia: identification of four genetic risk loci and evidence for the contribution of WNT signaling to its etiology. *Journal of Investigative Dermatology*, 133(6), 1489-1496.
23. **Martinez-Jacobo, L., Villarreal-Villarreal, C. D., Ortiz-López, R., Ocampo-Candiani, J., and Rojas-Martínez, A. (2018):** Genetic and molecular aspects of androgenetic alopecia. *Indian journal of dermatology, venereology and leprology*, 84, 263.
24. **Castellanos, A., Kazimir, K., Sampath, S., and Trotter, S. C. (2023).** 63-Year-Old Female with Diffuse Thinning of the Hair. In *Clinical Cases in Alopecia* (pp. 1-9). Cham: Springer International Publishing.
25. **Chen, S., Sun, Y., Liu, J., Yan, W., Liu, J., & Hu, W. (2023).** The Progress of Common Treatments and Research for Androgenetic Alopecia. *Current Research in Medical Sciences*, 2(2), 46-51.
26. **Lai, J. J., Chang, P., Lai, K. P., Chen, L., and Chang, C. (2012).** The role of androgen and androgen receptor in skin-related disorders. *Archives of dermatological research*, 304(7), 499–510. <https://doi.org/10.1007/s00403-012-1265-x>
27. **Panchaprateep, R., and Asawanonda, P. (2014).** Insulin-like growth factor-1: roles in androgenetic alopecia. *Experimental dermatology*, 23(3), 216–218. <https://doi.org/10.1111/exd.12339>
28. **Brown TM and Krishnamurthy K. (2024).** Histology, Hair and Follicle. 2023 May 1. In: StatPearls [Internet]. Treasure Island (FL): StatPearls Publishing; 2024 Jan-. PMID: 30422524.
29. **Yousef, H., Miao, J. H., Alhajj, M., and Badri, T. (2023).** Histology, skin appendages. In StatPearls [Internet]. StatPearls Publishing.
30. **Martel JL, Miao JH and Badri T. (2024):** Anatomy, Hair Follicle. 2022 Oct 10. In: StatPearls [Internet]. Treasure Island (FL): StatPearls Publishing; 2024 Jan-. PMID: 29261946.
31. **Hoover E, Alhajj M and Flores JL. (2024)** Physiology, Hair. [Updated 2023 Jul 30]. In: StatPearls [Internet]. Treasure Island (FL): StatPearls Publishing; 2024 Jan-. Available from: <https://www.ncbi.nlm.nih.gov/books/NBK499948/>
32. **Murphrey MB, Miao JH and Zito PM. (2024).** Histology, Stratum Corneum. 2022 Nov 14. In: StatPearls [Internet]. Treasure Island (FL): StatPearls Publishing; 2024 Jan-. PMID: 30020671.
33. **Philipsen, M. H., Haxen, E. R., Manprasertsak, A., Malmberg, P., and Hammarlund, E. U. (2021).** Mapping the chemistry of hair strands by mass spectrometry imaging—a review. *Molecules*, 26(24), 7522.
34. **Erdoğan, B. (2017).** Anatomy and physiology of hair. *Hair and scalp disorders*, 13, 1-7.
35. **Natarelli, N., Gahoonia, N., and Sivamani, R. K. (2023).** Integrative and Mechanistic Approach to the Hair Growth Cycle and Hair Loss. *Journal of clinical medicine*, 12(3), 893. <https://doi.org/10.3390/jcm12030893>
36. **Burg, D., Yamamoto, M., Namekata, M., Haklani, J., Koike, K., and Halasz, M. (2017).** Promotion of anagen, increased hair density and reduction of hair fall in a clinical setting following identification of FGF5-inhibiting compounds via a novel 2-stage process. *Clinical, cosmetic and investigational dermatology*, 71-85.
37. **Nestor, M. S., Ablon, G., Gade, A., Han, H., and Fischer, D. L. (2021).** Treatment options for androgenetic alopecia: Efficacy, side effects, compliance, financial considerations, and ethics. *Journal of cosmetic dermatology*, 20(12), 3759–3781. <https://doi.org/10.1111/jocd.14537>
38. **Wirya, C. T., Wu, W., and Wu, K. (2017).** Classification of Male-pattern Hair Loss. *International journal of trichology*, 9(3), 95–100. [https://doi.org/10.4103/ijt.ijt\\_46\\_17](https://doi.org/10.4103/ijt.ijt_46_17)
39. **Ummiti, A., Priya, P. S., Chandravathi, P. L., and Kumar, C. S. (2019).** Correlation of Trichoscopy Findings in Androgenetic Alopecia and the Disease Severity. *International journal of trichology*, 11(3), 118–122. [https://doi.org/10.4103/ijt.ijt\\_103\\_17](https://doi.org/10.4103/ijt.ijt_103_17)
40. **Dharam Kumar, K. C., Krishna Kumar, Y. H., and Neladimmanahally, V. (2018).** Association of Androgenetic Alopecia with Metabolic Syndrome: A Case-control Study on 100 Patients in a Tertiary Care Hospital in South India. *Indian journal of endocrinology and metabolism*, 22(2), 196–199. [https://doi.org/10.4103/ijem.IJEM\\_650\\_17](https://doi.org/10.4103/ijem.IJEM_650_17)
41. **Memon, F. H., Rahimoon, A. G., Kumar, P., Memon, S. H., Siddiqui, E., Devrajani, T., and Shah, S. Z. A. (2021).** Androgenetic alopecia as a marker of metabolic syndrome. *Journal of Pharmaceutical Research International*, 33(30A), 146-153.

42. Rossi, A., D'Arino, A., Pigliacelli, F., Caro, G., Muscianese, M., Fortuna, M. C., and Carlesimo, M. (2019). The diagnosis of androgenetic alopecia in children: Considerations of pathophysiological plausibility. *The Australasian journal of dermatology*, 60(4), e279–e283. <https://doi.org/10.1111/ajd.13079>
43. Prugsakij, W., Numsawat, S., Netchareonsirisuk, P., Tengamnuay, P., and De-Eknankul, W. (2023). Mechanistic synergy of hair growth promotion by the *Avicennia marina* extract and its active constituent (avicequinone C) in dermal papilla cells isolated from androgenic alopecia patients. *Plots one*, 18(4), e0284853. <https://doi.org/10.1371/journal.pone.0284853>
44. Bălăsoiu, A. T., Ciurea, R. N., Mănescu, M. R., Mocanu, C. L., Stepan, A. E., Bălăsoiu, M. A. R. I. A., and Niculescu, M. (2016). Assessment of VEGF and EGFR in the study of angiogenesis of eyelid carcinomas. *Rom. J. Morphologic. Embryol*, 57, 1229-1234.
45. Abdin, R., Zhang, Y., and Jimenez, J. J. (2022). Treatment of Androgenetic Alopecia Using PRP to Target Dysregulated Mechanisms and Pathways. *Frontiers in medicine*, 9, 843127. <https://doi.org/10.3389/fmed.2022.843127>
46. Patel, P., Nessel, T. A., and Kumar, D. (2024). Minoxidil. In *StatPearls* [Internet]. StatPearls Publishing.
47. Suchonwanit, P., Thammarucha, S., and Leerunyakul, K. (2019). Minoxidil and its use in hair disorders: a review. *Drug design, development and therapy*, 13, 2777–2786. <https://doi.org/10.2147/DDDT.S214907>
48. Pietrauszk, K., and Bergler-Czop, B. (2022). Sulfotransferase SULT1A1 activity in hair follicle, a prognostic marker of response to the minoxidil treatment in patients with androgenetic alopecia: a review. *Postepy dermatologii i alergologii*, 39(3), 472–478. <https://doi.org/10.5114/ada.2020.99947>
49. Udare, S., Baruah, A., Mathur, A., Dayananda, T. R., Jain, K., Puhan, M. R., Bajaj, P., Sharma, R., Gamit, S. R., Ramesh, V., Venugopal, V., Karthik, V., Neena Gala, M. Y., McHale, S., and Mane, A. (2023). Positioning of Low Alcohol or Alcohol-Free Minoxidil Formulation for the Management of Androgenetic Alopecia: Indian Perspective. *International journal of trichology*, 15(1), 13–17. [https://doi.org/10.4103/ijt.ijt\\_54\\_22](https://doi.org/10.4103/ijt.ijt_54_22)
50. Gupta, A. K., Talukder, M., Venkataraman, M., and Bamimore, M. A. (2022). Minoxidil: a comprehensive review. *Journal of Dermatological Treatment*, 33(4), 1896-1906.
51. Rica Echevarría, I., García del Monte, J., Delgado Rubio, A., Arcangeli, F., and Lotti, T. (2020). Severe hypertrichosis in infants due to transdermic exposure to 5% and 7% topical minoxidil. *Dermatologic Therapy*, 33(6), e14230.
52. Lee, S. W., Juhasz, M., Mobasher, P., Ekelem, C., and Mesinkovska, N. A. (2018). A Systematic Review of Topical Finasteride in the Treatment of Androgenetic Alopecia in Men and Women. *Journal of drugs in dermatology: JDD*, 17(4), 457–463.
53. Mazzarella, G. F., Loconsole, G. F., Camias', G. A., Mastrolonardo, G. M., and Vena, G. A. (1997). Topical finasteride in the treatment of androgenic alopecia. Preliminary evaluations after a 16-month therapy course. *Journal of dermatological treatment*, 8(3), 189-192.
54. van Zuuren, E. J., Fedorowicz, Z., and Schoones, J. (2016). Interventions for female pattern hair loss. *Cochrane Database of Systematic Reviews*, (5).
55. Pereira, A. F. J. R., and Coelho, T. O. D. A. (2020). Post-finasteride syndrome. *Anais Brasileiros de Dermatologia*, 95, 271-277.
56. Adil, A., and Godwin, M. (2017). The effectiveness of treatments for androgenetic alopecia: a systematic review and meta-analysis. *Journal of the American Academy of Dermatology*, 77(1), 136-141.
57. Darwin, E., Heyes, A., Hirt, P. A., Wikramanayake, T. C., and Jimenez, J. J. (2018). Low-level laser therapy for the treatment of androgenic alopecia: a review. *Lasers in medical science*, 33, 425-434.
58. Girijala, R. L., Riahi, R. R., and Cohen, P. R. (2018). Platelet-rich plasma for androgenic alopecia treatment: a comprehensive review. *Dermatology Online Journal*, 24(7).
59. Ha, D. H., Kim, H. K., Lee, J., Kwon, H. H., Park, G. H., Yang, S. H., and Cho, B. S. (2020). Mesenchymal stem/stromal cell-derived exosomes for immunomodulatory therapeutics and skin regeneration. *Cells*, 9(5), 1157.
60. Yin, K., Wang, S., and Zhao, R. C. (2019). Exosomes from mesenchymal stem/stromal cells: a new therapeutic paradigm. *Biomarker research*, 7, 1-8.

61. Zhou, L., Wang, H., Jing, J., Yu, L., Wu, X., and Lu, Z. (2018). Regulation of hair follicle development by exosomes derived from dermal papilla cells. *Biochemical and biophysical research communications*, 500(2), 325-332
62. Kwack, M. H., Seo, C. H., Gangadaran, P., Ahn, B. C., Kim, M. K., Kim, J. C., and Sung, Y. K. (2019). Exosomes derived from human dermal papilla cells promote hair growth in cultured human hair follicles and augment the hair-inductive capacity of cultured dermal papilla spheres. *Experimental dermatology*, 28(7), 854-857.
63. Zhang, F., Yang, Y. N., Feng, J. D., Zhao, J. H., Wan, L., Che, J., Yan, Y., Guo, N. N., and Zhang, J. Y. (2022). Observation on the Efficacy of a Combined Treatment for Moderate and Severe Androgenetic Alopecia Incorporating Electric Microneedles. *Clinical, cosmetic and investigational dermatology*, 15, 2573–2581. <https://doi.org/10.2147/CCID.S383289>
64. Dhurat, R., Sakes', M. S., Aphid, G., Dandale, A., Pal, A., and Pund, P. (2013). A randomized evaluator blinded study of effect of micro-needling in androgenetic alopecia: a pilot study. *International journal of trichology*, 5(1), 6-11.
65. Jha, A. K., Vinay, K., Zeeshan, M., Roy, P. K., Chaudhary, R. K. P., and Priya, A. (2019). Platelet-rich plasma and micro-needling improves hair growth in patients of androgenetic alopecia when used as an adjuvant to minoxidil. *Journal of Cosmetic Dermatology*, 18(5), 1330-1335.
66. Faghihi, G., Nabavinejad, S., Mokhtari, F., Fatemi Manini, F., and Iraj, F. (2021). Micro-needling in androgenetic alopecia; comparing two different depths of microneedles. *Journal of Cosmetic Dermatology*, 20(4), 1241-1247.
67. Razmi, T. M., and Subburaj, K. (2022). Hair transplantation: A brief review. *Clinical Dermatology Review*, 6(2), 80-87.
68. Zito PM and Raggio BS. (2024): Hair Transplantation. 2024 Feb 12. In: StatPearls [Internet]. Treasure Island (FL): StatPearls Publishing; Jan-. PMID: 31613520.

## مراجعة عن الصلع الاندروجيني: المسببات، نشأته وتطوره، وطرق العلاج الدوائية وغير الدوائية

الشيما ع. الغباشي، نجوى إبراهيم النفاوي، سيد مصطفى السيد، شيما مجدي و ولاء عادل عبد المعز

قسم التشريح والأجنة، كلية الطب، جامعة عين شمس

**الخلفية:** الصلع الاندروجيني (AGA) يعد واحداً من أكثر الأسباب شيوعاً لاستشارة أطباء الجلدية، وهو اضطراب وراثي يتميز بترقق وانكماش بصيلات الشعر تدريجياً؛ مما يؤدي إلى تغيير في ديناميكيات دورة الشعر وظهور الصلع.

**الهدف من العمل:** تهدف المراجعة الحالية إلى جمع وتقديم وتحليل جميع البيانات السابقة المتعلقة بالمسببات، ونشوء وتطور، وطرق علاج الصلع الاندروجيني.

تم إجراء بحث في PubMed و Google Scholar باستخدام استراتيجية البحث التالية: الصلع الاندروجيني والمسببات المرضية، الصلع الاندروجيني والمشاكل النفسية أو احترام الذات، طرق العلاج الحديثة للصلع الاندروجيني. تم استبعاد الدراسات إذا ركزت على أنواع مرضية أخرى من الصلع.

**الملاحظات:** يعتبر الصلع الاندروجيني مشكلة عالمية يتراوح معدل انتشارها ما بين ٠,٢٪ إلى ٢٪ بين مختلف المجموعات السكانية، ويؤثر على كلا الجنسين، وكذلك على الأعراق المختلفة.

تم افتراض العديد من الآليات لفهم الآلية الأساسية لانكماش بصيلات الشعر التي تحدث في الصلع الاندروجيني ولكنها لا تزال غير مفهومة بشكل كامل. علاوة على ذلك، يتميز الصلع الاندروجيني بوجود بيئة أندروجينية موضعية داخل فروة الرأس، وارتفاع مستويات ديهيدروتستوستيرون ووفرة مستقبلات الأندروجين. يمكن أيضاً أن يساهم الاستعداد الوراثي المعقد في الانخفاض التدريجي والخسارة النهائية لبصيلات الشعر التي لوحظت في هذه الحالة. يعتمد تقييم شدة الصلع الاندروجيني على أنظمة تصنيف Norwood-Hamilton المعدلة والتي يمكنها تقسيم تساقط الشعر فيها إلى سبع مراحل مختلفة (١-٧).

تم الموافقة على طرق متعددة لعلاج الصلع الاندروجيني من قبل إدارة الغذاء والدواء الأمريكية؛ مثل المينوكسيديل الموضعي، والفيناسترايد عن طريق الفم، والعلاج بالضوء منخفض المستوى. تتوفر خيارات علاجية حديثة أخرى مثل العلاجات الهرمونية والبلازما الغنية بالصفائح الدموية وعلاجات الإكسوسوم وزراعة الشعر، ولا يزال البحث عن طرائق حديثة أخرى يمثل نقطة ساخنة في العمل البحثي الحديث.

**الخلاصة:** البيانات التي تم فحصها من هذه الدراسات تلقي الضوء على أحدث المعلومات المتعلقة بانتشار الصلع الاندروجيني ومسبباته ونشأته وتطوره وطرق علاجه.