

## Assessment of Osseointegration Properties of Hyaluronic Acid coated Titanium Implant Versus Sandblasted Large Thread Acid Etched Implants in Posterior Maxilla: A Randomized Clinical Trial

Mohamed Hamdy Mahmoud Ismail <sup>1,\*</sup>, Shaimaa Saieed Nasr <sup>2</sup>, Nouran Abdullah Mater <sup>3</sup>, Omnia Ibrahim Sultan <sup>4</sup>

### ARTICLE INFO.

#### Keywords:

Hyaluronic Acid; Dental Implants; Posterior Maxilla; Implant stability; Osseointegration.

### Abstract

**Background:** This study was performed to compare the implant stability of Hyaluronic Acid coated dental implants with Sandblasted Large Thread Acid Etched surface (SLA) dental implants placed in the maxillary posterior area.

**Methods:** Thirty adult patients with at least one missing maxillary posterior tooth were randomly assigned into two equal parallel groups with a 1:1 allocation ratio to receive either HA coated Titanium Implant (test group) or SLA Implants (control group).

**Results:** The primary outcome was implant stability as measured by the Resonance Frequency Analysis (RFA) via the Ostell ISQ system <sup>®</sup> at baseline (T0) and 6 (T1) and 12 (T2) weeks post-operatively. The secondary outcome was concerned with surgical wound healing based on Landry index evaluated at 7<sup>th</sup> and 14<sup>th</sup> day post-operatively. Regarding implant stability, results of the primary implant stability at (T0) revealed no statistically significant differences between the two study groups (P= 0.129). Contrarily, the secondary implant stability at (T1) and (T2) weeks showed statistically significant greater ISQ values in the HA coated implant group than SLA implants group (P≤0.001 at T1 and T2). On the 14th postoperative day, there was statistically significant difference regarding soft tissue healing index between the two groups (P=0.005).

**Conclusion:** HA-coated implants with hydrophilic surfaces achieve faster osseointegration than those without modification within a shorter period, making them suitable candidates for early loading protocols.

© 2024 MSA. All rights reserved.

#### \* Corresponding author.

E-mail address: dr.hamdy88@gmail.com

- 1 Lecturer of Oral & Maxillofacial Surgery, Faculty of Dentistry, October University for Modern Sciences and Arts, Egypt.
- 2 Associate Professor of Periodontology, Faculty of Dentistry, Fayoum University, October University for Modern Sciences and Arts, Egypt.
- 3 Lecturer of Periodontology, Faculty of Dentistry, October University for Modern Sciences and Arts, Egypt.
- 4 Associate Professor of Oral & Maxillofacial Surgery, Faculty of Dentistry, October University for Modern Sciences and Arts, Egypt.

## 1 Introduction

The goal of modern dentistry is to restore an individual's normal state in terms of function, comfort, appearance, speech, and overall health. This is achieved by eliminating tooth decay or replacing multiple missing teeth. Implant dentistry is exceptional in its capacity to accomplish this objective regardless of the presence of atrophy, sickness, or injury in the stomatognathic system. Bone is a dynamic organ that can undergo changes as a result of many factors such as hormonal, nutritional, and mechanical influences. Thus, implant stability is crucial for uninterrupted healing and bone formation after placement, as well as for the appropriate distribution of stress from chewing and occlusal functional loads through the interface between the implant and the surrounding tissue <sup>1,2</sup>.

Implant stability is attained through two distinct stages: primary and secondary. Primary stability is derived

from the mechanical connection with the outer layer of bone, known as cortical bone. While secondary stability is achieved through the process of bone and tissue regeneration and remodeling that occurs around the implant during osteotomy healing. Accordingly, the literature established Resonance frequency (RF) analysis as a precise and objective technique that measures the primary and secondary stability of implants without causing any harm or invasion.<sup>3-5</sup>

Recent literature has focused on the dental implant surface's role in achieving a higher osseointegration rate and bone-implant bonding and stability. The success of a dental implant is determined by its capacity to fulfill particular clinical parameters about symptoms and the functioning of prosthetic rehabilitation, such as the gradual increase in stability over time.<sup>6</sup>

Aiming for better stability, different commercial titanium implants underwent various treatments to modify their surfaces for better osteoconductivity and osseointegration. Implant surface treatment is a well-known procedure done to improve the osseointegration and thus the stability of the implant fixture through altering and preserving the favorable characteristics of the basic materials. It can be categorized into additive or subtractive techniques based on their approach to modify the implant's surface characteristics. This included both blasting and ion implantation, to enhance the durability of implants and promote the process of osseointegration. Different materials had been used for implant additive coating; ceramic coatings such as calcium phosphate (CAP), hydroxyapatite (HAP), and titanium oxide (TiO<sub>2</sub>) which continue to be widely used in surface treatments as bioceramic materials to further enhance osseointegration.<sup>7-9</sup>

On the other hand, Subtractive techniques including Sandblasting, acid etching or combination of sandblasting and acid etching (SLA), Oxidation in a galvanic bath, sandblasting with aluminum oxide or titanium microparticles, high-pressure plasma spray procedures with calcium and phosphate granules, were used to treat the implant surface that result in faster osseointegration compared to machined surfaces.<sup>6,10-14</sup>

The biochemical strategies used for implant surface modification aimed to apply our present understanding of cell activity and differentiation in biology and biochemistry. Surface modification is conducted with the aim of influencing the reactions of tissues. The objective of tissue modification is to anchor proteins, enzymes, or peptides onto implant surfaces to provoke specific tissue reactions.<sup>6,15</sup>

One promising material being studied is hyaluronic acid (HA), which offers osteo-conductivity properties necessary for secondary stability through its positive interaction with progenitor cells responsible for

bone formation. The covalent bonding of HA to the surfaces of titanium implants has a major impact on bone formation, leading to enhanced bone maturity at the implant interface. HA plays a crucial role in bone mineralization, bone healing, and the production of extracellular matrix.<sup>16</sup>

The latest approach to enhance the connection between bone and implants involves the immobilizing of the cellular matrix components, which in turn promotes osseointegration by upholding the attachment of osteoblasts to the implant surfaces, hence, the utilization of HA as it is one of the crucial glycosaminoglycans in the cellular matrix produced by fibroblasts, synoviocytes, and chondrocytes.

It has been observed that HA significantly reduces inflammation during the process of wound healing, which promotes cell growth, re-epithelialization, and minimizes scarring. Moreover, studies have shown that topical application of HA gel reduces inflammation levels around implants affected by peri-implantitis. It is highly suitable for tissue engineering grafts due to its excellent blood compatibility and strong ability to adhere to osteoblasts. This also enhances the surface's wettability, which in turn promotes better organization of the blood clot and facilitates the subsequent cascade of healing processes that are directly influenced by the presence of the molecule.<sup>16</sup>

In the context of increased wettability and hydrophilicity, the HA chemical modification which improved the wettability of the implant surface, also allowed better organization of the blood clot and cascade healing. Furthermore, this modification has an influence on surface charge, which may affect protein adsorption, cell adhesion, specific cell responses, and eventually osseointegration.<sup>6,17</sup>

Therefore, the aim of this randomized clinical trial was to compare the results of the implant stability quotient (ISQ) obtained from HA-coated implants with the same design, length, and diameter as sandblasted acid etch (SAE) surface implants placed in the posterior area of the maxilla within the first 12 weeks of follow-up. The study also aimed to assess the ability of these implants to achieve rapid osseointegration and soft tissue healing, which enables early loading.

## 2 Materials and Methods

### 2.1 Study design, setting and population:

This randomized controlled clinical trial was approved by Ethics Committee of Scientific research, MSA University (No.1654), conducted in accordance with the revised Helsinki Declaration of 2013 and reported according to CONSORT guidelines, 2012.<sup>18</sup> (Fig. 1). This study included 30 patients recruited from outpatients' clinics of the Faculty of Dentistry, MSA University over a period of four months, between January and April 2024 meeting the following criteria:

**Inclusion Criteria:**

- Patients with at least one missing maxillary posterior tooth
- Adults aged 18 years old and above
- Patients with no systemic contraindication to implant placement were included. (ASA I)<sup>17</sup>
- The alveolar bone should be with sub-antral bone height not less than 8 mm, and bone densities of D3 or D4 as classified by Lekholm and Zarb<sup>19</sup>.
- Patients presenting with at least three months post-extraction healing

**Exclusion Criteria:**

- Patients who are allergic to titanium
- Heavy smoker patients
- Patients receiving chemotherapy or radiotherapy within the past two years
- Previous bone grafting and/or Sinus lifting.
- Untreated periodontitis
- Severe clenching or bruxing habits
- Alcohol or drug addiction.

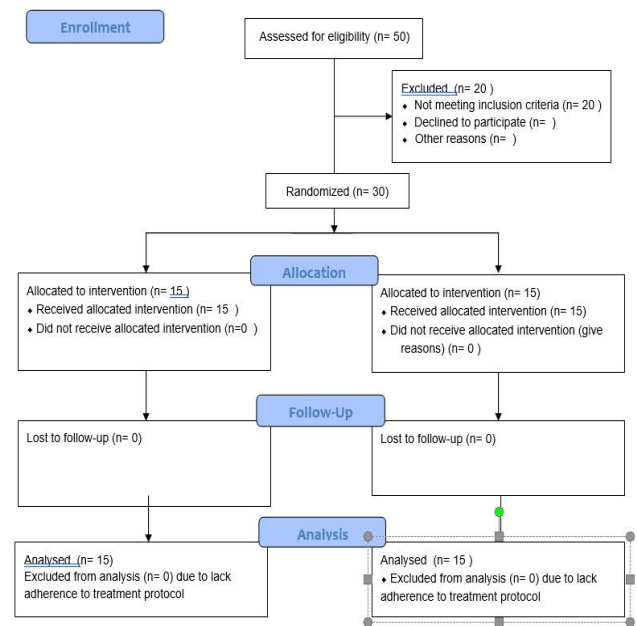
**2.2 Measured outcomes:**

The primary outcome: implant stability measured by RFA via the Osstell ISQ system® at baseline (T0) and 6 (T1) and 12 (T2) weeks post-operatively.

The secondary outcome: the surgical wound healing based on Landry index<sup>20</sup> evaluated at 7<sup>th</sup> and 14<sup>th</sup> day post-operatively.

**2.3 Sample size analysis:**

Based on a previous study by El-Hadidi et al.<sup>21</sup>, where the effect size (d) was 1.2508999, sample size was estimated for the probability of type I error ( $\alpha$ ) = 0.05 and power (1- $\beta$ ) of 80% for the primary outcome (implant stability measured with RFA via the Osstell ISQ system® after topical application of Hyaluronic Acid to immediately loaded dental implant in posterior Maxilla versus conventional method after three months of treatment) and using two tailed t-tests of difference between two independent means, it was found to be 24 participants (12 in each group). The sample size was increased to a total of 30 participants (15 in each group) to allow for dropout loss. Sample size calculation was performed by G\*Power 3.1.9.7.



**Figure 1.** CONSORT 2010 Flow Diagram

**2.4 Clinical and surgical procedures****Pre-operative assessment:**

- Comprehensive clinical assessment with full diagnostic charts was performed to examine the condition of the implant site and to ensure eligibility.
- All patients were scanned pre-operatively using an intraoral scanner (IOS) (TRIOS, 3Shape A/S, Copenhagen K, Denmark).
- Cone beam computed tomography CBCT (Newtom Giono Imola, Italy) was done with a high contrast resolution detector (high bit depth) and a field of vision 6x8, to evaluate the residual bony quality and quantity and exclude the presence of any bony lesion. Imaging protocol was standardized by radiographing the patients with a wax interocclusal record to separate maxillary and mandibular teeth at a kVp between five and ten. These specifications decreased the beam hardening effect.

**Surgical procedure:**

- Buccal and palatal infiltration (ARTINIBSA 4% 1:200,000, Inibsa, Spain) was injected intraoral at the implant site.
- Patients used antiseptic mouthwash rinse for 30 seconds (Oraldene; Chlorhexidine hydrochloride 125mg in each 100 ml solution. EDCO, Egypt) before the surgery.
- Full thickness mucoperiosteal flap was elevated to expose the implant site.
- Drilling protocol for implants (IS II active fixture SLA tapered body implant by Neobiotech) was done according to manufacturer's instructions.

- Implants of the same diameter and length were placed for the two groups in a one stage procedure. For control group, implants were placed directly into the osteotomy site. For intervention group implants were dipped into the sterile container of HA (HYALGAN – Sodium Hyaluronate -Fidia USA) for its full length then placed into the osteotomy site
- The primary implant stability was measured by using the RFA via the Osstell ISQ system ® (Integration Diagnostics, Göteborg, Sweden) at baseline (immediately after insertion) (T0). For this measurement, a transducer with 8.5 mm length was placed on the fixtures. The RF transducer consisted of two piezoceramic elements attached to an offset cantilever beam. Stimulation of the elements causes vibration of the beam. The stimulating signal is a sinusoid wave with frequency of 5 to 15 Hz and amplitude peak of 1 V. RF values are recorded as implant stability quotient (ISQ) on a scale from 1 to 100. Buccal and mesial measurements were performed and the arithmetic mean obtained by the two ISQ values were registered for respective time as shown in (Fig. 2).
- The flap was closed by absorbable sutures (Ethicon, coated vicryl (polyglactin 910), Johnson & Johnson, USA)

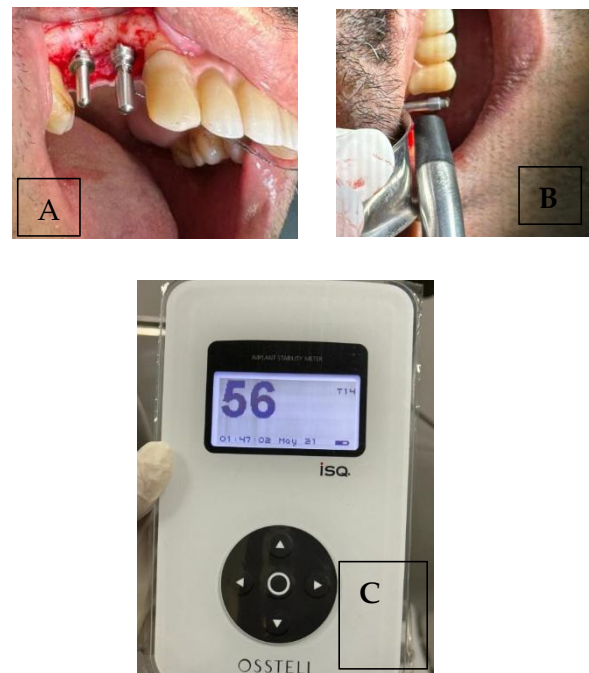
#### Post-operative assessment:

- Systemic antibiotics (Augmentin 1gm. tablets, Smithkline Beecham Pharmaceuticals Co., Brentford, England) was prescribed twice daily for 5 days and non-steroidal anti-inflammatory drugs (Cataflam 50mg. tablets, Novartis Pharma AG, Basle, Switzerland) every 8 hours for 3 days
- Using RFA, the secondary implant stability was measured at 6 (T1), and 12 weeks (T2) post-operative.
- Implants received final restoration when secondary implant stability reached ISQ value of 70 which is considered satisfactory as it is higher than the minimum implant stability suggested by manufacturer for loading implant
- At the 7th and 14th day post-operative, the soft tissue healing was evaluated by soft tissue index as described by Landry<sup>20</sup>. The Landry index rates the surgical wound healing process as “very poor”, “poor”; “good”; “very good”; or “excellent” according to tissue colour, bleeding on palpation, presence of granulation tissue, incision margins and suppuration.

#### 2.5 Statistical Analysis

In the current study, most of the variables were

continuous (Age, ISQ value, and PPD) which were expressed in mean ( $\pm$  SD). These variables were tested for normality using Shapiro-Wilk and Homogeneity of Variances was examined with Levene's test. Most of the continuous data were parametric, therefore, student's t- test was used to compare values for the two independent groups at baseline and at the 6<sup>th</sup> and 12<sup>th</sup> week postoperatively. The One-Way ANOVA (Welch's) was used to compare ISQ values at different points of time followed by Tukey's post hoc analysis. Statistical significance was considered at  $P \leq 0.05$ , while  $P \leq 0.001$  was considered Highly significant. For categorical data (Landry's index), Fischer's exact test was used. Statistics were done using the *jamovi*. (Version 2.3) [Computer Software].



**Figure (2a, b, c).** The measurement of implant stability with the use of RFA via the Osstell ISQ system ®

### 3 Results

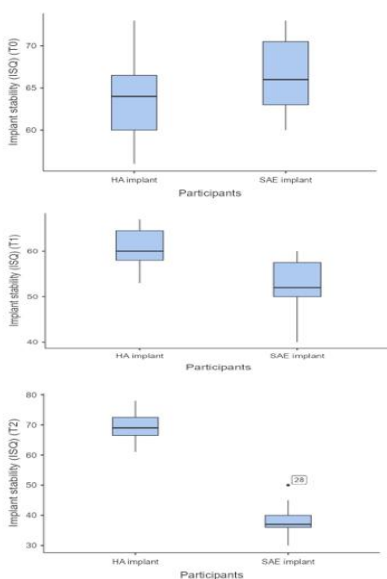
In the current study, the implant surgical procedures were performed on 30 patients involving 23 females and 7 males. Those patients who received HA coated Implant had mean age of  $38.1 \pm 17.61$  years, while those who received SAE implants had mean ages of  $35.7 \pm 7.14$  years, with no statistically significant differences in the mean ages between the two groups ( $P=0.43$ ).

Based on the Landry index (Soft tissue index) on the 7<sup>th</sup> postoperative day, the surgical wound healing in the HA coated Implant group was either very good or excellent, with most participants presenting with very good (13.3%) or excellent (86.7%) healing. Similarly, participants in SAE implants group showed very good (20%) or excellent (80%) soft tissue healing with no statistically significant difference between the two groups ( $P=1.00$ ). On the 14<sup>th</sup> postoperative

day, the surgical wound healing in the HA coated Implant group was either very good or excellent, with most participants presenting with very good (66.7%) or excellent (33.3%) healing. In contrast, SAE implants group varied from good to excellent soft tissue healing, in which participants presented good (53.3%), very good (26.7%) or excellent (20%) healing. The differences in soft tissue index were statistically significant between the two groups (P=0.005).

Regarding implant stability, as measured by RFA and presented in ISQ value, results of the primary implant stability (at insertion) (T0) revealed no statistically significant differences between the two study groups (P= 0.129). Contrarily, the secondary implant stability at 6<sup>th</sup> (T1) and 12<sup>th</sup> (T2) weeks showed statistically significant greater ISQ values in the HA coated implant group than SAE implants group (P<0.001 at T1 and T2) as depicted in **Table 1. (Fig. 3)**

The current statistical analysis showed that implant stability, as measured by RFA and presented in ISQ value, has been reduced from the time of insertion till the 12<sup>th</sup> week in SAE implant group with statistically significant differences (P<0.001) between each point of time (T0-T1-T2). On the contrary, the HA coated implant group provided statistically significant improvement (P= 0.011) from the time of insertion till the 12<sup>th</sup> week postoperative (T0- T2). Although there was minimal reduction in implant stability in the HA coated implant group from the time of insertion to the 6<sup>th</sup> week postoperative (T0- T2) that was not statistically significant (P= 0.244), but there was highly significant elevation (P<0.001) in implant stability between the 6<sup>th</sup> and 12<sup>th</sup> week postoperative (T1-T2) as shown in **Table 2.**



**Figure 3.** Shows the difference in mean ISQ between the two study groups at T0, T1 and T2

**Table 1.** Comparison between HA implant group and SLA implant group regarding implant stability at baseline (T0), 6 weeks (T1) and 12 weeks (T2)

Parameter	HA implant group	SLA implant group	Statistics	Mean difference	95% CI		Effect size	P-value
					Lower	Upper		
	Mean± SD							Student's t- test
Implant stability (ISQ) (T0)	63.4 ±4.79	66.3± 4.39	75.5	-3.00	-7.00	1.00	0.329	0.091
Implant stability (ISQ) (T1)	60.4± 4.44	52.5± 5.67	25	8.00	4.00	12.00	0.778	≤0.001
Implant stability (ISQ) (T2)	69.4± 5.05	38.1± 5.42	0.0	31.00	27.00	36.00	1.00	≤0.001

**Table 2.** Change in implant stability (ISQ) between baseline (T0), 6 weeks (T1) and 12 weeks (T2)

	HA implant group		SLA implant group	
	W <sup>a</sup>	P-value	W <sup>a</sup>	P-value
<b>T0-T1</b>	-2.27	0.209	-6.55	≤0.001**
<b>T0-T2</b>	4.08	0.004*	-6.61	≤0.001**
<b>T1-T2</b>	5.62	≤0.001**	-6.17	≤0.001**
<b>One-Way ANOVA (T0-T1-T2)</b>		≤0.001**		≤0.001**

<sup>a</sup> Tukey's post hoc test

\*Statistically significant \*\* Highly significant

#### 4 Discussion

Surface alteration of implants is a potential factor that can cause variation and potentially impact the process of bone integration and bone-implant contact.

In this study, 30 implants of the same diameter and length were placed in patients of the two groups. This was to prevent any added variable that may affect ISQ measurements, despite the statement of *Han et al.*<sup>22</sup> who did not observe a correlation between implant diameter and ISQ value.

*Sim & Lang*<sup>23</sup> stated that the area of the jaw (namely the quality of the bone) had a significant effect on the analysis using RFA. Accordingly, the region of the implant placement in our study was always the same (posterior maxilla), though patients may have had differences in bone quality, to allow for the separate evaluation of the clinical significance of HA surface treatment for dental implants compared to SLA treated implant surfaces.<sup>17</sup>

In this research, RFA results yielded a significantly higher mean ISQ of the HA implant group than the SLA implant group at 6<sup>th</sup> and 12<sup>th</sup> weeks post-operatively. These results were consistent with those of *Novellino et al*<sup>17</sup> which declared the faster gain in stability in implants with hydrophilic HA than with SLA implants. Hence HA coatings showed faster and greater stability than SLA implants, it can be speculated that the faster gain in stability after a proper healing period could be regarded as an indicator of a more successful osseointegration as described in the literature. Moreover, one possible explanation is that the hydrophilic nature of implant surfaces coated with HA has increased allowing for faster and better

osseointegration.<sup>24</sup>

The current study demonstrated a statistically significant difference between primary and secondary implant stability (ISQ) between both groups. The results obtained revealed a reduction in implant stability from the time of insertion until the 12<sup>th</sup> week post-operatively in the SAE implant group. Contrarily, implant stability has been increased since the time of implant placement till the 12<sup>th</sup> week of follow-up in the HA-coated implant group. This was in accordance with *Cervino et al.*<sup>6</sup> who concluded that the addition of HA to the implant surface favors the maturation of osteoid tissue which has an impact on the implant stability. Moreover, studies reported that when machined treated implants were placed in the maxilla, higher rates of failure than any other site was observed.<sup>25</sup>

Noteworthy, a decrease in mean ISQ was observed in both groups by the 6<sup>th</sup> week of implant placement. This initial reduction in mean ISQ in both groups agrees with other studies and suggests the existence of a drop that occurs between primary and secondary implant stability. This drop in stability is due to the fact that osseointegration only occurs after initial but temporary bone resorption, followed by the gain of biologics (secondary).

Similar results were obtained by *Elhadidi et al.*<sup>21</sup> when they compared implant stability (ISQ) in HA implants versus conventional implants at different times. Moreover, other studies showed that with the use of hydrophilic surfaces, the osseointegration period was shortened. Given all this, it is evident that the use of hydrophilic SLA implants, particularly if they have been coated with HA, could validate early implant loading protocols.

Regarding the soft tissue healing, on the 7<sup>th</sup> day postoperatively, there was no statistically significant difference between the HA implants and SLA implant groups in the soft tissue healing index values. However, the differences in soft tissue healing index were statistically significant between the two groups on the 14<sup>th</sup> postoperative day, where the in the HA-coated implant group revealed better results. These results were in accordance with a study conducted by de Arajo Nobre et al. (2007) who used gels containing HA versus chlorhexidine to enhance peri-implant soft tissue healing, in which they found significantly better soft tissue healing in the HA group, as revealed by the modified bleeding index values.<sup>26</sup>

Moreover, our study came in agreement with other studies that demonstrated the benefits of HA in combination with other medications in soft tissue healing enhancement with the HA-coated implants. In this sense, our results aligned with a study conducted by *Genovesi et al. (2017)*,<sup>27</sup> where soft tissue healing index was used in the assessment of patients treated with 0.12% chlorhexidine

plus HA mouthwash compared to chlorhexidine alone. The chlorhexidine plus HA group provided better results than chlorhexidine rinse alone.

The results of the present study were also consistent with *Fernandez et al. (2021)*<sup>28</sup> who found that the topical application of HA gel significantly reduces the inflammatory response associated with peri-implant mucositis during early healing phase. Additionally, emerging evidence from various clinical trials (*Shukla and Kranthi Kiran, 2023*)<sup>29</sup> suggested that HA promotes the soft tissue healing process and aids in the management of postoperative symptoms.

Therefore, the overall findings suggest that HA-coated implants with hydrophilic surfaces achieve faster osseointegration and greater gain in implant stability making them suitable candidates for early loading protocols. Moreover, the HA-treated surfaces could be an excellent way to enhance the success rate in areas of poor bone density. Further research is recommended using a larger sample size to evaluate the long-term outcomes of these surface modifications.

## 5 Conclusion

Within the limitation of this study, it is possible to conclude that HA-coated implants with hydrophilic surfaces achieve faster osseointegration than those without modification within a shorter period, making them suitable candidates for early loading protocols.

### Authors' Contributions

Mohamed Hamdy and Shaimaa Nasr managed the methodology, review & editing, supervision. Nouran Mater managed the supervision of the surgical part and managed the resources and manuscript writing. Omnia Sultan managed the methodology, Manuscript Writing roles and responsibilities. All authors have read and approved the manuscript.

### Conflict of interest

The authors declared that they hold no competing interests.

### Funding

The research study was self- funded by the authors.

### Acknowledgement

We acknowledge Dr. Rania Shalaby for accomplishing the statistical analysis .

## References

- [1] Misch, C. E. (2008). *Contemporary Implant Dentistry* (3Nd Edition). [http://books.google.ie/books?id=3\\_RUPgAACAAJ&dq=Misch,+C.E.\(2008\),Contemporary+Implant+Dentistry.Mosby+Elsevier](http://books.google.ie/books?id=3_RUPgAACAAJ&dq=Misch,+C.E.(2008),Contemporary+Implant+Dentistry.Mosby+Elsevier).
- [2] Roberts, W. E., Turley, P. K., Brezniak, N., & Fielder, P. J. (1987). *Implants: Bone physiology and metabolism*. PubMed, 15(10), 54–61.
- [3] Meredith N, Alleyne D, Cawley P. Quantitative determination of the stability of the implant-tissue interface using resonance frequency analysis. *Clin Oral Implants Res*. 1996 Sep;7(3):261-7.
- [4] Zix J, Hug S, Kessler-Liechti G, Mericske-Stern R. Measurement of dental implant stability by resonance frequency analysis and damping capacity assessment: comparison of both techniques in a clinical trial. *Int J Oral Maxillofac Implants*. 2008 May-Jun;23(3):525-30.
- [5] Lee DH, Ku Y, Rhyu IC, Hong JU, Lee CW, Heo MS, Huh KH. A clinical study of alveolar bone quality using the fractal dimension and the implant stability quotient. *J Periodontal Implant Sci*. 2010 Feb;40(1):19-24.
- [6] Cervino G, Fiorillo L, Iannello G, Santonocito D, Risitano G, Cicciù M. Sandblasted and Acid Etched Titanium Dental Implant Surfaces Systematic Review and Confocal Microscopy Evaluation. *Materials* (Basel). 2019 May 30;12(11):1763.
- [7] Jemat A, Ghazali MJ, Razali M, Otsuka Y. Surface Modifications and Their Effects on Titanium Dental Implants. *Biomed Res Int*. 2015; 2015:791725.
- [8] He FM, Yang GL, Li YN, Wang XX, Zhao SF. Early bone response to sandblasted, dual acid-etched and H<sub>2</sub>O<sub>2</sub>/HCl treated titanium implants: an experimental study in the rabbit. *Int J Oral Maxillofac Surg*. 2009 Jun;38(6):677-81.
- [9] Bryington MS, Hayashi M, Kozai Y, Vandeweghe S, Andersson M, Wennerberg A, Jimbo R. The influence of nano hydroxyapatite coating on osseointegration after extended healing periods. *Dent Mater*. 2013 May;29(5):514-20.
- [10] Chrcanovic BR, Kisch J, Albrektsson T, Wennerberg A. A retrospective study on clinical and radiological outcomes of oral implants in patients followed up for a minimum of 20 years. *Clin Implant Dent Relat Res*. 2018 Apr;20(2):199-207.
- [11] Wang Q, Hong YB, Huang MD, Wang QM, Teng W. Constructing self-adhesive and robust functional films on titanium resistant to mechanical damage during dental implanting. *Mater Sci Eng C Mater Biol Appl*. 2020 May;110:110688.
- [12] Rauso R, Federico F, Zerbinati N, De Cicco D, Nicoletti GF, Tartaro G. Hyaluronic Acid Injections to Correct Lips Deformity Following Surgical Removal of Permanent Implant. *J Craniofac Surg*. 2020 Sep;31(6):e604-e606.
- [13] Bianchi S, Fantozzi G, Bernardi S, Antonouli S, Continenza MA, Macchiarelli G. Commercial oral hygiene products and implant collar surfaces: Scanning electron microscopy observations. *Can J Dent Hyg*. 2020 Feb 1;54(1):26-31.
- [14] Areevijit K, Dhaneuan N, Luckanagul JA, Rungsyanont S. Biocompatibility study of modified injectable hyaluronic acid hydrogel with mannitol/BSA to alveolar bone cells. *J Biomater Appl*. 2021 May;35(10):1294-1303.
- [15] Cervino G, Meto A, Fiorillo L, Odorici A, Meto A, D'Amico C, Oteri G, Cicciù M. Surface Treatment of the Dental Implant with Hyaluronic Acid: An Overview of Recent Data. *Int J Environ Res Public Health*. 2021 Apr 27;18(9):4670.
- [16] Traini T, Degidi M, Strocchi R, Caputi S, Piattelli A. Collagen fiber orientation near dental implants in human bone: do their organization reflect differences in loading? *J Biomed Mater Res B Appl Biomater*. 2005 Jul;74(1):538-46.
- [17] Novellino MM, Sesma N, Zanardi PR, Laganá DC. Resonance frequency analysis of dental implants placed at the posterior maxilla varying the surface treatment only: A randomized clinical trial. *Clin Implant Dent Relat Res*. 2017 Oct;19(5):770-775.
- [18] Moher D, Hopewell S, Schulz KF, Montori V, Gøtzsche PC, Devereaux PJ, Elbourne D, Egger M, Altman DG. CONSORT 2010 explanation and elaboration: updated guidelines for reporting parallel group randomised trials. *BMJ*. 2010 Mar 23;340:c869.
- [19] Brånemark, P. I., Zarb, G. A., & Albrektsson, T. (1985). *Tissue-integrated Protheses*. Quintessence Publishing (IL). [http://books.google.ie/books?id=sRJqAAAAMAAJ&q=Patient selection and preparation.TissueIntegr.Prothes. Patient selection and preparation. TissueIntegr.Prothes](http://books.google.ie/books?id=sRJqAAAAMAAJ&q=Patient+selection+and+preparation.TissueIntegr.Prothes.+Patient+selection+and+preparation.+TissueIntegr.Prothes)
- [20] Landry, R. G. (1985). *Effectiveness of Benzylamine HCl in the Treatment of Periodontal Post-surgical Patients*. [http://books.google.ie/books?id=MhB\\_NAAACAAJ&dq=Effectiveness of benzylamine HCl in the treatment of periodontal post-surgical patients](http://books.google.ie/books?id=MhB_NAAACAAJ&dq=Effectiveness+of+benzylamine+HCl+in+the+treatment+of+periodontal+post-surgical+patients)
- [21] Elhadidi MH, Yousef EAS, Elhindawy MM, Ahmed WMS. The Effect of Topical Application of Hyaluronic Acid on the Stability of Immediate Loaded Dental Implants in the Posterior Maxilla: Clinical and Animal Study. *Int J Oral Maxillofac Implants*. 2023 Jul-Aug;38(4):775-783.
- [22] Han J, Lulic M, Lang NP. Factors influencing resonance frequency analysis assessed by Osstell mentor during implant tissue integration: II. Implant surface modifications and implant diameter. *Clin Oral Implants Res*. 2010 Jun;21(6):605-11.
- [23] Sim CP, Lang NP. Factors influencing resonance frequency analysis assessed by Osstell mentor during implant tissue integration: I. Instrument positioning, bone structure, implant length. *Clin Oral Implants Res*. 2010 Jun;21(6):598-604.
- [24] Dreifke MB, Ebraheim NA, Jayasuriya AC. Investigation of potential injectable polymeric biomaterials for bone regeneration. *J Biomed Mater Res A*. 2013 Aug;101(8):2436-47.
- [25] Balshe AA, Eckert SE, Koka S, Assad DA, Weaver AL. The effects of smoking on the survival of smooth- and rough-surface dental implants. *Int J Oral Maxillofac Implants*. 2008 Nov-Dec;23(6):1117-22.
- [26] de Araújo Nobre M, Cintra N, Maló P. Peri-implant maintenance of immediate function implants: a pilot study comparing hyaluronic acid and chlorhexidine. *Int J Dent Hyg*. 2007 May;5(2):87-94.
- [27] Genovesi A, Barone A, Toti P, Covani U. The efficacy of 0.12% chlorhexidine versus 0.12% chlorhexidine plus hyaluronic acid mouthwash on healing of submerged single implant insertion areas: a short-term randomized controlled clinical trial. *Int J Dent Hyg*. 2017 Feb;15(1):65-72.
- [28] Sánchez-Fernández E, Magán-Fernández A, O'Valle F, Bravo M, Mesa F. Hyaluronic acid reduces inflammation and crevicular fluid IL-1 $\beta$  concentrations in peri-implantitis: a randomized controlled clinical trial. *J Periodontal Implant Sci*. 2021 Feb;51(1):63-74.
- [29] Kirti Shukula and Kranthi Pebilli. The Emerging role of hyaluronic acid in dental implant procedures. *Annals of International Medical and Dental Research (AIMDR)*, 9(6), 93 – 102. (2023).