



## Adaptation of TIMP-1/P21 signaling pathways in hepatic fibrosis induced in albino rats using Telmisartan with Vitamin D

Fatma Amer<sup>1\*</sup>, Mahmoud El-Rehany<sup>2</sup>, Hamdy A. Zahran<sup>3</sup>, Othman Ali<sup>1</sup>

<sup>1</sup>Biochemistry Division, Chemistry Dept., Faculty of Science, Minia University, Minia, 61511, Egypt

<sup>2</sup>Biochemistry Dept, Faculty of Medicine, Minia University, Minia, 61511, Egypt

<sup>3</sup>Fats and Oils Dept., National Research Centre, Dokki 12622, Cairo, Egypt



CrossMark

### Abstract

Liver fibrosis is regarded as one of the most severe manifestations of liver diseases, which is marked by excessive cell proliferation and abnormal extracellular matrix deposition, leading to significant pathological distortions in liver tissue architecture and function. The current study aimed to assess the antioxidant and hepatoprotective effectiveness of Vitamin D (VD3) and Telmisartan (TEL) against liver fibrosis induced by thioacetamide (TAA) (200 mg/kg, i.p) in an in vivo rat model. Four groups were randomly divided, each with ten rats (n = 10): 1) healthy, 2) TAA-induced for 8 weeks, 3) prophylactic group, and 4) TAA-induced for 8 weeks, followed by VD3+TEL therapy for 8 weeks. Tissue samples were evaluated using histological techniques (H&E, Masson's trichrome stain), biochemical procedures, and gene expression analysis for Mmp9, TNF- $\alpha$ , p21, Coll1 $\alpha$ 1, TIMP-1, Acta2, and IL-6. TAA led to liver damage and increased blood levels of ALT, AST, ALP, MDA, TNF- $\alpha$ , IL-6, and IL-1 $\beta$  in the fibrotic group. Fortunately, combined treatment of VD3 with TEL significantly reduced the severity of TAA-induced biochemical, molecular, and histopathological changes. Significant improvement in the histological morphology and structure of the liver parenchyma. VD3 with TEL reduced oxidative stress and inflammation and inhibited the TIMP-1/p21 signaling pathway and consequent cell senescence.

**Keywords:** Hepatic Fibrosis; TAA ; P21, Oxidative Stress ;TIMP-1.

### 1. Introduction

Hepatic fibrosis is a pathological condition due to ongoing liver damage induced via various agents, such as viral infections, drugs, high alcohol intake, autoimmune illnesses, abnormalities in metabolism, and other damaging agents. Its essential nature is the aberrant and abnormal extracellular matrix formation, which destroys normal liver tissue and causes fibrotic scarring [1, 2]. Hepatic fibrosis is a crucial factor in the development of chronic hepatic damage to cirrhosis and HCC [3]. Thus, early detection and treatment of hepatic fibrosis are critical in predicting the prognosis for anyone with liver disorders. The pathophysiology of liver fibrosis has advanced significantly throughout the years. While removing and treating the underlying cause may assist in treating hepatic fibrosis, there is a lack of specialized treatments [4]. As a result, developing efficient treatments to reverse liver fibrosis continues to be a significant issue.

Treatment approaches for hepatic fibrosis involve removing the cause, inflammation-targeted

therapy, hepatocyte apoptosis suppression, lowering cell activation and proliferation, signalling pathway modulation, suppression of fibrosis-related cytokines and mediators, and gene therapy [5]. Additionally, numerous efforts are looking for hepatoprotective drugs that block the stimulation of HSC and similar pathways as possible therapy possibilities [6, 7]. Thioacetamide ( $C_2H_5NS$ ) is an organosulfur compound that mainly occurs by inhalation and skin contact [8]. TAA is a widely used hepatotoxic chemical that induces hepatic fibrosis when administered repeatedly. TAA metabolites chemically bind to hepatic macromolecules, reducing their antioxidant activity and improving lipid peroxidation via increasing the amount of reactive oxygen species (ROS) generation [9].

Vitamin D<sub>3</sub>(VD<sub>3</sub>) is synthesized under UV radiation from the sun in the skin or taken from a diet, particularly fatty fish. Its active form is 1,25-dihydroxy cholecalciferol (1,25[OH]<sub>2</sub>D<sub>3</sub>); it promotes bone strength in humans and additionally controls several genes that regulate cell proliferation,

\*Corresponding author e-mail: [fatma.amer@mu.edu.eg](mailto:fatma.amer@mu.edu.eg); (Fatma Amer).

Received date 18 October 2024; revised date 02 November; accepted date 11 November 2024

DOI: 10.21608/ejchem.2024.329319.10652

©2024 National Information and Documentation Center (NIDOC)

angiogenesis, and cell death [10]. Several challenging recent investigations indicate a relationship between VD3 insufficiency and heart disease, diabetes, cancer, and depression [11]. Oxidative stress is a major cause of cellular damage, whereby the formation of reactive oxygen species (ROS) hampers the cells' antioxidant defence mechanism, resulting in cellular loss. Under normal conditions, antioxidant defence mechanisms regulate the oxidant-antioxidant equilibrium by adapting to the changing amounts of oxidants. Enzymes like glutathione peroxidase, catalase, superoxide dismutase, and other substances make up the antioxidant defence system. Furthermore, several nutrients, such as vitamins and minerals, might have an impact on the antioxidant homeostasis [12]. As a result, vitamin D has been considered to possess antioxidant effects. Over twenty years ago, Wiseman discovered that vitamin D decreased iron-dependent liposomal lipid peroxidation in rats. Vitamin D and cholesterol have similar structures, and ergosterol has been studied for its membrane antioxidant effects [9]. In addition, it is well-recognised that vitamin D interacts with its nuclear receptor (VDR) within the cell and modulates the target expression of genes [10]. Thus, vitamin D can lower OS via increasing cellular GSH and antioxidant systems, including glutathione peroxidase and superoxide dismutase [13, 14].

Telmisartan is a particular angiotensin receptor blocker (ARB) that regulates Peroxisome Proliferator-Activated Receptor Gamma (PPAR- $\gamma$ ) activity, enhancing insulin sensitivity and reducing hepatic fat building up. Telmisartan's therapeutic impact on hepatocytes can be linked to its anti-oxidative properties [15]. Likewise, telmisartan decreased liver fibrosis that was triggered in rats by a diet with methionine-deficient and choline-deficient [16]. Bataller et al, [17] Found that elevated systemic Angiotensin (Ang) II levels cause fibrogenesis and promote inflammation. Telmisartan has the most robust attachment for the AT1-R and has an extremely long half-life duration among the ARBs. Furthermore, Telmisartan's lipophilicity and preference for the liver make it ideal for liver signs [18]. So, the aim of these studies depends on the therapy of telmisartan with Vitamin D to prevent or treat hepatic fibrosis induced in rats.

## 2. Material and Methods

### Ethical Approval

All animal research investigations have been performed according to the rules and guidelines of using animals in labs by the National Institutes of Health and under a protocol granted by the ethics committee, Faculty of Pharmacy, Mania University, with approval code (**MPEC 230203**). The best efforts

have been taken to reduce the discomfort of the animals.

### Animals

The present research involved forty healthy adult male albino Wistar rats with weights ranging from 170 gm to 250 gm from the National Research Centre (Giza, Egypt). The National Research Center approved the rats of liver-free injuries (Dokki, Giza, Egypt). Animals were kept in the Deraya University animal house unit (Mania, Egypt). The rats were kept in polypropylene boxes with an unlimited supply of regular laboratory food and drink and maintained in a normal habitat with 12 hours of light/dark cycles,  $25 \pm 2$  °C, and 44-56% relative humidity.

### Experimental design

Forty male Wistar rats were categorized into four groups, with ten in each group.

**Group (I): Healthy control:** Ten animals received no treatment and were used as a control group.

**Group (II): liver fibrotic group:** This group contained only ten animals injected with TAA and served as a positive fibrotic group. Animals of this group were injected intraperitoneally with Thioacetamide (Sigma-Aldrich, USA) at a dosage of 20 mg/100g body weight dissolved in distilled water [19], Twice weekly for up to 8 weeks.

**Group (III): prophylactic with VD3+TEL:** consisted of 10 animals and was treated with Concomitant administration of Vitamin D (0.5 $\mu$ g/100g. body weight, i.p) dissolved in distilled sesame oil [20, 21], and telmisartan (8 mg/kg body weight, orally) [22], Starting with TAA injection twice weekly for up to 8 weeks.

**Group (IV): Treatment with VD3+TEL:** consisted of 10 animals who were given Vitamin D (0.5 $\mu$ g/100g. body weight) dissolved in sesame oil and telmisartan (8 mg/kg body weight) twice weekly for up to 8 weeks after TAA injection period.

### Samples preparation and tissue isolation

Rats received general anesthesia with an intraperitoneal injection of urethane (25% at 1.6 g/kg). For biochemical evaluation, blood samples were centrifuged at 4000  $\times$ g for 15 minutes, and the serum was removed and kept at -20°C. The liver was immediately removed and cut into three portions for analysis. The first portion was kept at -20 °C for additional biochemical evaluation. The second part was stored at -80 °C for QRT-PCR. The final part was fixed in 10% formaldehyde for additional histological investigation.

### Evaluation of liver function tests

Serum Alanine transaminase (ALT), aspartate transaminase (AST), albumin (ALB), and alkaline phosphatase (ALP) were performed via commercial kits (biosystems, Barcelona, Spain), depending on the manufacturer's directions using clinical chemistry analyzer machine (URIT, Chine)[23-25].

### Investigation of Antioxidant Markers

The liver homogenate was utilized to determine oxidative stress and antioxidant markers such as malondialdehyde (MDA), superoxide dismutase (SOD), and hepatic reduced glutathione (GSH) using easily accessible already assembled kits (Biodiagnostic, Cairo, Egypt) that were evaluated following the company's protocols [26].

### Evaluation of serum inflammatory cytokines

Serum levels of Interleukin-6 (IL-6), interleukin-1beta (IL-1 $\beta$ ), and Tumor necrosis factor (TNF- $\alpha$ ) were evaluated using commercial rat ELISA kits (Elabscience, Houston, Texas, USA) depending on the manufacturer's instructions using Elisa reader (Infitek, China)[27].

**Table (1).** The sequences of the primers.

| Gene                            | Forward primer                    | Reverse primer                  |
|---------------------------------|-----------------------------------|---------------------------------|
| <i>GAPDH</i>                    | GAA CAT CAT CCC TGC ATC CA        | CCA GTG AGC TTC CCG TTC A       |
| <i>TNF-<math>\alpha</math></i>  | ACC ACG CTC TTC TGT CTA CTG       | CTT GGT GGT TTG CTA CGA C       |
| <i>Mmp9</i>                     | AAA CCT CCA ACC TCA CGG AC        | TGG CCT TTA GTG TCT CGC TG      |
| <i>p21</i>                      | AGC GCC GAT TGG TCT TCT G         | GTA TAT CGA ATT GCA CGA GGG GAG |
| <i>Coll<math>\alpha</math>1</i> | GAG ACA GGC GAA CAA GGT GA        | GGG AGA CCG TTG AGT CCA TC      |
| <i>Acta2</i>                    | ACC ATC GGG AAT GAA CGC TT        | CTG TCA GCA ATG CCT GGG TA      |
| <i>IL-6</i>                     | GAA ATA CAA AGA AAT GAT GGA TGC T | TTC AAG ATG AGT TGG ATG GTC T   |
| <i>TIMP-1</i>                   | TTC GTG GGG ACA CCA GAA GTC       | TAT CTG GGA CCG CAG GGA CTG     |

### Histopathological study

Liver tissues were fixed in a neutral buffered formalin solution (10%) and stained with standard Hematoxylin and Eosin (H&E). Sections were assessed with a high-quality digital camera attached to the microscope (Olympus, Tokyo, Japan), and digital images were taken. The monitoring and evaluation were carried out blindly. The assessment phase included looking for centrilobular hepatocyte necrosis, ballooning or degeneration, and cellular inflammation. Fibrotic regions were quantitatively assessed (% of stained area relative to the total area) with Masson's trichrome stain to determine the amount of collagen fiber accumulation. The microscopic images were captured utilizing a digital imaging system.

### Quantitative real-time polymerase chain reaction

Using an ultrasonic homogenizer (SFX 550 Branson Digital Sonifier<sup>®</sup> ultrasonic cell disruptor/homogenizer, Danbury, CT, USA), 100 mg tissue was homogenized with 1 mL of TRIzol reagent. The entire quantity of RNA was measured at A260 nm, and the A260/A280 ratio was used for estimating RNA purity. RNA samples having a purity of at least 1.7 were utilized for QRT-PCR analysis. Using the Revert Aid First Strand cDNA Synthesis Kit (Life Technologies Ltd., Paisley, UK), equivalent quantities of total RNA were transformed into cDNA, and then Real-time PCR was carried out. **Table (1)** shows the primer sequences provided by the National Center for Biotechnology Information (NCBI). Thermo Scientific Maxima SYBR Green qPCR Master Mix (2x) (Life Technologies Ltd, Paisley, UK) was utilized. The PCR reactions were performed using real-time PCR detection equipment (Applied Biosystems, Life Technologies Ltd., Paisley, UK). The comparative CT (threshold cycle) technique measured gene expression levels, with GAPDH as a housekeeping gene.

### Statistical analysis

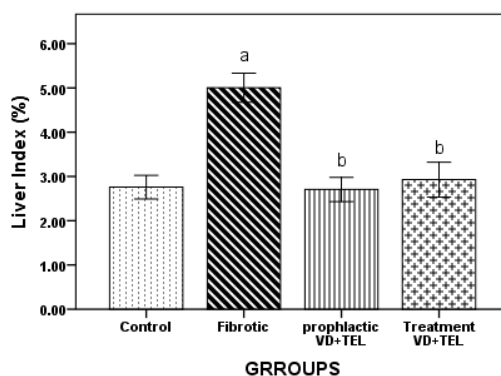
Data are provided as means  $\pm$  standard deviation ( $x \pm s$ ) and processed with SPSS 22.0. Comparisons between experimental groups were examined using analysis of variance (ANOVA), followed by post-hoc testing. P-values less than  $<0.001$  were considered highly significant, while P-values less than  $<0.05$  were considered statistically significant.

## 3. Results and Discussion

### Effect Of Vitamin D & Telmisartan on Liver Index

First, we weighed the liver and body of rats in all groups, as shown in **Table (2)** and **Figure (1)**. The formula for determining the liver index was as follows:

$$liver\ index = \frac{liver\ weight}{body\ weight} \times 100$$



Bars represent mean  $\pm$  SD. A significant difference was analyzed by one-way ANOVA ( $n = 10$ ), where a;  $p < 0.001$  compared to the Control group, b;  $p < 0.001$  compared to the Fibrotic group.

**Figure (1).** The effect of VD3+TEL treatment on the liver index of rats in each group.

The fibrotic group had a greater liver index and weight than the control group ( $P < 0.05$ ). However, fibrotic rats receiving Vitamin D and Telmisartan had

significantly lower liver index and weight, particularly in the prophylactic group.

**Table (2).** The effect of Vitamin D and Telmisartan treatment on the body weight, liver weight, and liver index of rats in each group.

| Groups               | Weight (g)                     | Weight of liver (g)          | Liver index (%)              |
|----------------------|--------------------------------|------------------------------|------------------------------|
| Control              | 203.00 $\pm$ 2.73              | 5.60 $\pm$ 0.54              | 2.75 $\pm$ 0.26              |
| Fibrotic             | 169.83 $\pm$ 0.75 <sup>a</sup> | 8.50 $\pm$ 0.54 <sup>a</sup> | 5.00 $\pm$ 0.32 <sup>a</sup> |
| Prophylactic VD3+TEL | 200.71 $\pm$ 2.69 <sup>b</sup> | 5.42 $\pm$ 0.53 <sup>b</sup> | 2.70 $\pm$ 0.27 <sup>b</sup> |
| Treatment VD3+TEL    | 205.40 $\pm$ 6.34 <sup>b</sup> | 6.00 $\pm$ 0.70 <sup>b</sup> | 2.92 $\pm$ 0.39 <sup>b</sup> |

Data represents mean  $\pm$  SD. The significant difference was analyzed by one-way ANOVA ( $n = 10$ ), where a;  $p < 0.001$ , compared to the control group, b;  $p < 0.001$ , compared to the fibrotic group.

### Effect of TAA and co-treatment of VD3 + TEL on Biochemical Parameters

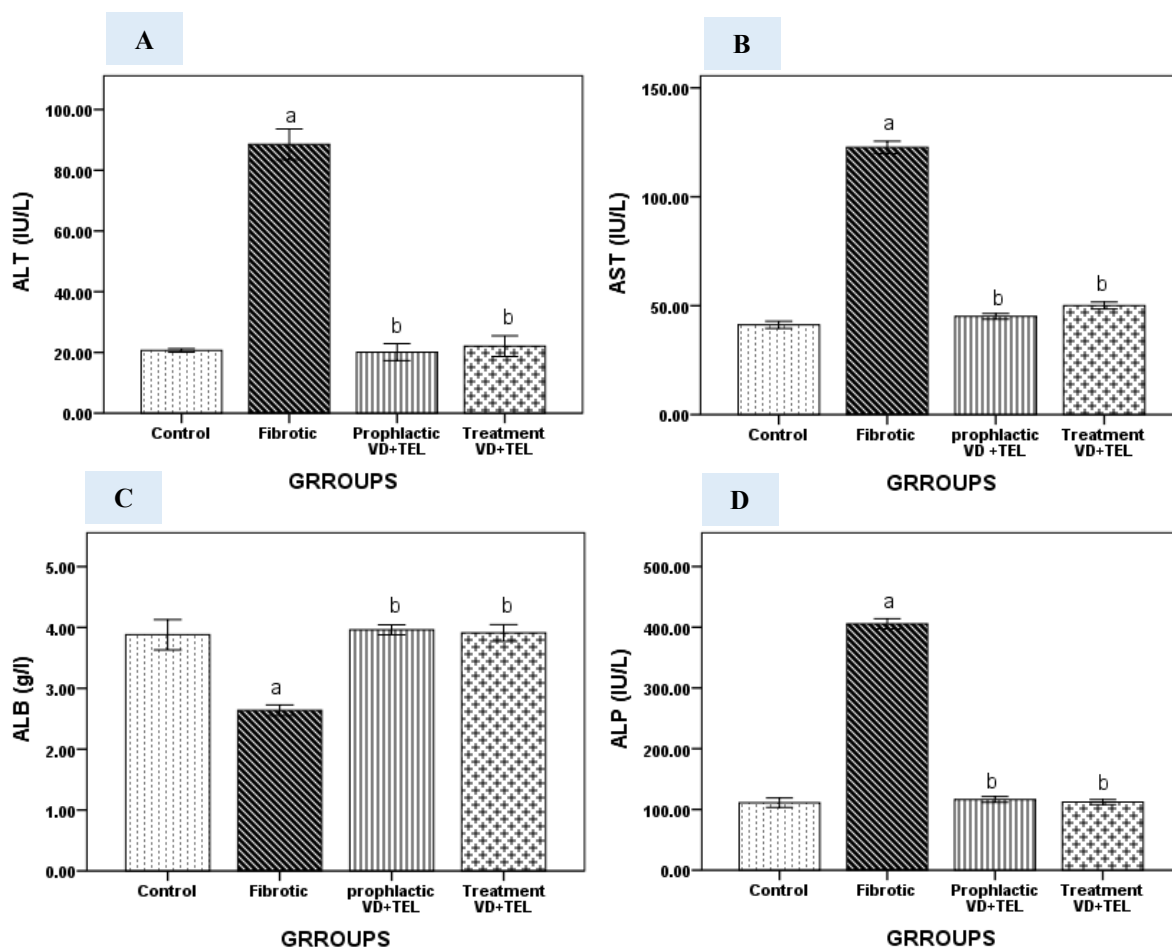
TAA induces hepatic damage with a significant elevation ( $p < 0.01$ ) in the ALT, AST, and ALP values and a significant drop in albumin levels compared to the healthy group. Therapy with VD3 and TEL significantly recovered normal ALT levels in the

TAA+VD3+TEL group compared to the TAA-treated group. Furthermore, AST and ALP levels were considerably downregulated. On the other hand, the prophylactic group of VD3+TEL (G3) maintains the level of ALT, AST, ALP, and albumin during TAA injection, as indicated in **Table (3)** and **Figure (2)**.

**Table (3).** The effect of Vitamin D and Telmisartan treatment on biochemical evaluation in each group.

| Groups               | ALT(IU/L)                     | AST(IU/L)                      | ALP(IU/L)                      | ALB(g/dl)                    |
|----------------------|-------------------------------|--------------------------------|--------------------------------|------------------------------|
| Control              | 20.68 $\pm$ 0.58              | 41.20 $\pm$ 1.64               | 111.00 $\pm$ 7.81              | 3.88 $\pm$ 0.24              |
| Fibrotic             | 88.53 $\pm$ 5.08 <sup>a</sup> | 122.66 $\pm$ 2.87 <sup>a</sup> | 405.66 $\pm$ 8.33 <sup>a</sup> | 2.63 $\pm$ 0.08 <sup>a</sup> |
| Prophylactic VD3+TEL | 20.10 $\pm$ 2.77 <sup>b</sup> | 45.07 $\pm$ 1.30 <sup>b</sup>  | 116.35 $\pm$ 4.80 <sup>b</sup> | 3.96 $\pm$ 0.08 <sup>b</sup> |
| Treatment VD3+TEL    | 22.08 $\pm$ 3.41 <sup>b</sup> | 50.08 $\pm$ 1.64 <sup>b</sup>  | 112.00 $\pm$ 4.12 <sup>b</sup> | 3.91 $\pm$ 0.13 <sup>b</sup> |

Data represents mean  $\pm$  SD. The significant difference was analyzed by one-way ANOVA ( $n = 10$ ), where a;  $p < 0.001$ , compared to the control group, b;  $p < 0.001$ , compared to the fibrotic group.



Bars represent mean  $\pm$  SD. The significant difference was analyzed by one-way ANOVA ( $n = 10$ ), where a;  $p < 0.001$ , compared to the Control group, b;  $p < 0.001$  compared to the Fibrotic group. ALT: alanine transaminase, AST: Aspartate Transaminase, ALB: Albumin, ALP: Alkaline Phosphatase

**Figure (2).** Serum levels of ALT (A), AST (B), ALB (C) and ALP (D).

#### Effect of TAA and co-treatment of VD3 + TEL on oxidative stress parameters

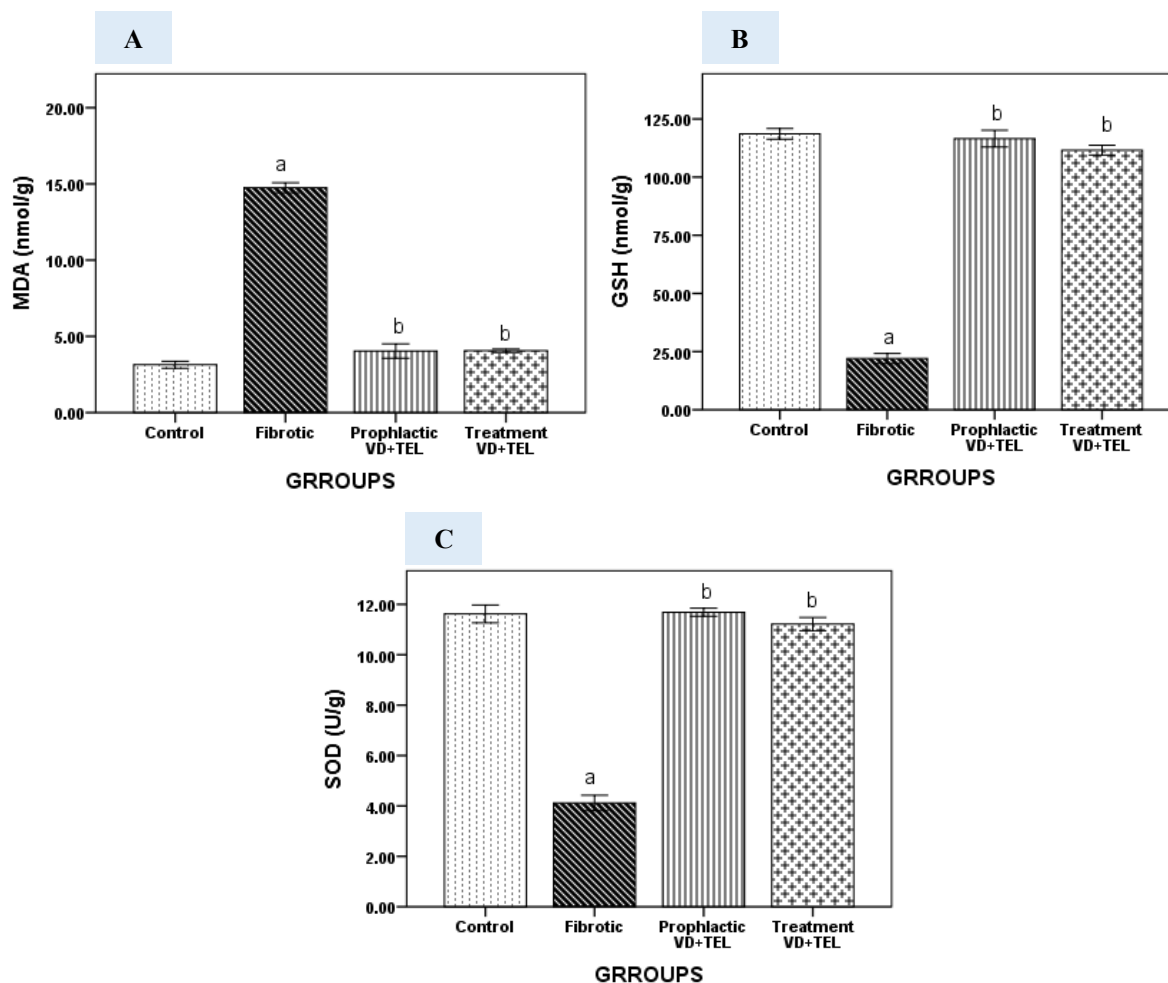
**Table (4) and Figure (3)** indicate the levels of MDA, SOD, and GSH in each group. The TAA group had significantly higher levels of malondialdehyde ( $p < 0.001$ ) in comparison with the healthy group, while the prophylactic group (G3) (VD3+TEL) and treatment group (G4) had significantly lower levels of MDA ( $p < 0.001$ ) compared to the TAA group (**Figure 3A**).

**Fig. 3B-C** shows that the TAA group had considerably lower hepatic SOD and GSH levels ( $p < 0.001$ ) than the control group. Treatment with VD3 and TEL considerably improved these changes ( $p < 0.001$ ) compared to the TAA group. Vitamin D and telmisartan significantly increased GSH levels ( $p < 0.01$ ).

**Table (4).** The effect of Vitamin D and Telmisartan treatment on oxidative stress markers in each group.

| Groups               | MDA (mmol/g)                  | GSH (mmol/g)                   | SOD(u/g)                      |
|----------------------|-------------------------------|--------------------------------|-------------------------------|
| Control              | 3.14 $\pm$ 0.23               | 118.60 $\pm$ 2.30              | 11.62 $\pm$ 0.35              |
| Fibrotic             | 14.75 $\pm$ 0.32 <sup>a</sup> | 22.00 $\pm$ 2.19 <sup>a</sup>  | 4.11 $\pm$ 0.30 <sup>a</sup>  |
| Prophylactic VD3+TEL | 4.04 $\pm$ 0.47 <sup>b</sup>  | 116.57 $\pm$ 3.5 <sup>b</sup>  | 11.68 $\pm$ 0.15 <sup>b</sup> |
| Treatment VD3+TEL    | 4.05 $\pm$ 0.11 <sup>b</sup>  | 111.60 $\pm$ 2.07 <sup>b</sup> | 11.21 $\pm$ 0.26 <sup>b</sup> |

Data represents mean  $\pm$  SD. The significant difference was analyzed by one-way ANOVA ( $n = 10$ ), where a;  $p < 0.001$ , compared to the control group, b;  $p < 0.001$ , compared to fibrotic group.



Bars represent mean  $\pm$  SD. The significant difference was analyzed by one-way ANOVA ( $n = 10$ ), where a;  $p < 0.001$ , compared to the Control group, b;  $p < 0.001$ , compared to the Fibrotic group. GSH: reduced glutathione, MDA: malondialdehyde, SOD: superoxide dismutase.

**Figure (3).** Hepatic tissue levels of MDA (A), GSH (B), and SOD (C).

#### Effect of TAA and co-treatment of VD3 + TEL on proinflammatory cytokines

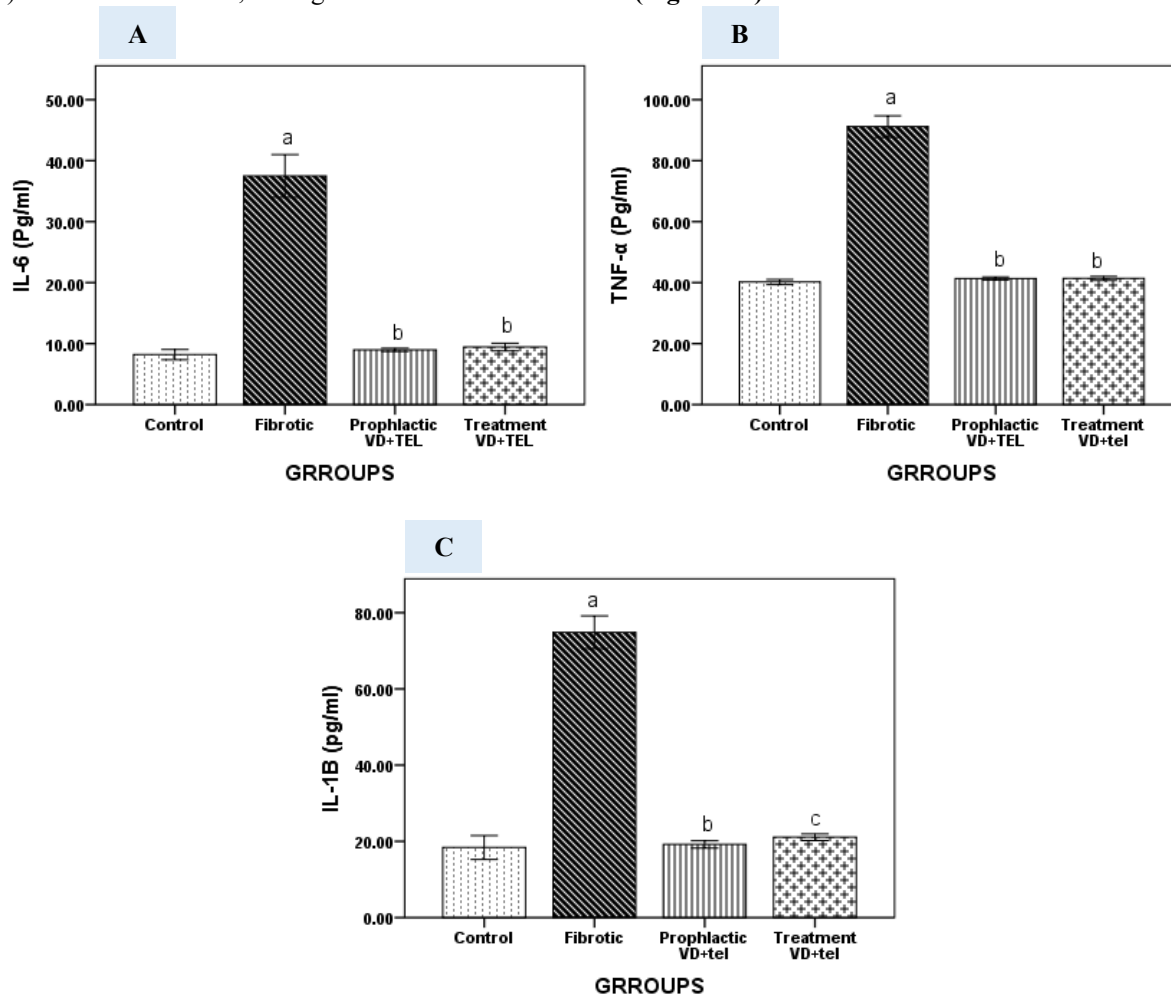
**Table (5)** and **(Figure 4A-C)** indicate a highly significant elevation in serum levels of proinflammatory cytokines IL-6, IL-1 $\beta$ , and TNF- $\alpha$  in the TAA group compared to the control group ( $p < 0.001$ ). On the other hand, their serum levels were significantly reduced ( $p < 0.001$ ) in groups treated with VD3 + TEL and highly maintained ( $p < 0.001$ ) in the prophylactic group compared to the TAA group. On the other hand, we indicate the effect of VD3 with TEL on the expression of the proinflammatory genes. We found an elevation in IL-6 and TNF- $\alpha$  5-10-fold, respectively, in the fibrotic group, but the prophylactic group revealed suppressed expression as the control group, as indicated in **Figure (5A-B)**

#### Antifibrogenic role of Vitamin D with Telmisartan on the expression of the significant fibrotic marker.

To understand the mechanisms by which the combination produces an antifibrogenic impact, first, we investigate how it affected the expression of key fibrotic markers such as collagen I $\alpha$ 1, tissue inhibitor metalloproteinase1 (TIMP-1), and actin alpha 2 (ACTA2). Collagen I $\alpha$ 1 mRNA expression was significantly higher ( $p < 0.001$ ) in the fibrotic group, whereas the prophylactic group indicates lower expression of COL1 $\alpha$ 1 compared to the TAA-induction group (**Figure 5C**). Furthermore, induction of TAA demonstrates a highly significant level of TIMP-1 mRNA expression. (**Figure.5D**), whereas treatment of VD3 with TEL reduced mRNA expression of  $\alpha$ -SMA (**Figure 5E**). The results showed that TAA induction caused a rise in mRNA levels, but therapy with 1,25(OH)2D3 and telmisartan decreased the mRNA levels. MMP-9 activity was also evaluated,

and TAA increased matrix metalloproteinase 9 (MMP-9). On the other hand, no significant alteration was

observed in MMP-9 activity in the preventive group (Figure 5F).



Bars represent mean  $\pm$  SD. A significant difference was analyzed by one-way ANOVA ( $n = 10$ ), where a;  $p < 0.001$ , compared to the Control group, b;  $p < 0.01$ , compared to the Fibrotic group, c;  $p < 0.001$ , compared to the fibrotic group, IL-6: interleukin 6, IL-1 $\beta$ : interleukin one beta, TNF- $\alpha$ : tumour necrosis alpha.

Figure (4). Serum levels of IL-6 (A), TNF $\alpha$  (B) and IL-1 $\beta$  (C).

Table (5). The effect of Vitamin D and Telmisartan treatment on pro-inflammatory cytokines in each group.

| Groups               | IL-6 (pg/ml)                  | TNF- $\alpha$ (pg/ml)         | IL-1B (pg/ml)                 |
|----------------------|-------------------------------|-------------------------------|-------------------------------|
| Control              | 8.20 $\pm$ 0.83               | 40.20 $\pm$ 0.83              | 18.40 $\pm$ 3.13              |
| Fibrotic             | 37.50 $\pm$ 3.50 <sup>a</sup> | 91.16 $\pm$ 3.54 <sup>a</sup> | 74.83 $\pm$ 4.30 <sup>a</sup> |
| Prophylactic VD3+TEL | 8.97 $\pm$ 0.27 <sup>b</sup>  | 41.34 $\pm$ 0.50 <sup>b</sup> | 19.20 $\pm$ 0.97 <sup>b</sup> |
| Treatment VD3+TEL    | 9.43 $\pm$ 0.62 <sup>b</sup>  | 41.38 $\pm$ 0.68 <sup>b</sup> | 21.08 $\pm$ 0.85 <sup>b</sup> |

Data represents  $m \pm$  SD. The significant difference was analysed by one-way ANOVA ( $n = 10$ ), where a;  $p < 0.001$ , compared to the control group, b;  $p < 0.001$ , compared to the fibrotic group.

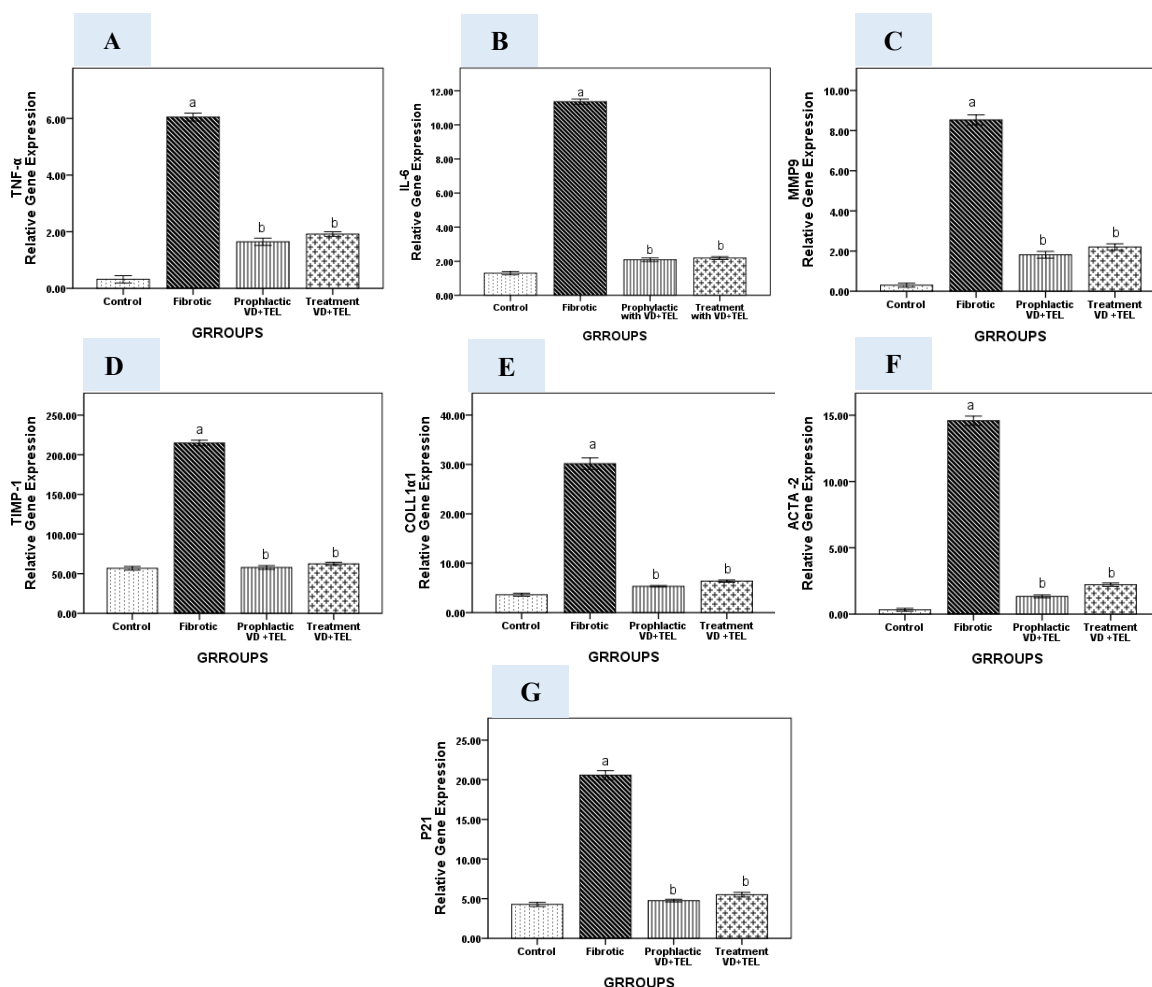
#### Active VD3 with Telmisartan inhibits the p21 signaling pathway and cell senescence.

Hepatocyte apoptosis, senescence, and proliferation drive liver aging, as revealed by the activation of cyclin -dependent kinase inhibitor (p21) signaling pathways. p21 is a crucial signal molecule that induces cell death. It attaches to CDK and then forms

a complex with proliferating cell nuclear antigen (PCNA), preventing PCNA-dependent DNA synthesis and terminating the cell cycle. The investigation found that the expression of p21 was substantially higher in the fibrotic group than in the control group ( $P < 0.05$ ). Figure (5G) indicates that when 1,25(OH)2D3 was treated with telmisartan, the



expression of p21 was reduced. Our findings showed that active VD3 with TEL might reduce the process of fibrosis by increasing cell death by altering the p21 signaling pathway.



Quantitative RT-PCR was used to analyze the gene expression of different groups. Expression was normalized to the corresponding GAPDH gene expression and expressed relative to the control group. Bars represent mean  $\pm$  SD. The significant difference was analyzed by one-way ANOVA ( $n = 10$ ), where a;  $p < 0.001$ , compared to the control group, b;  $p < 0.001$ , compared to fibrotic group.

**Figure (5).** Effect of Telmisartan and Vitamin D on the expression of TNF- $\alpha$  (A), IL-6 (B), MMP9 (C), TIMP-1 (D), COLL1 $\alpha$ 1 (E), ACTA2 (F) and P21 (G) genes in hepatic tissues.

### Histopathological Examination of Liver Sections Using H&E Staining

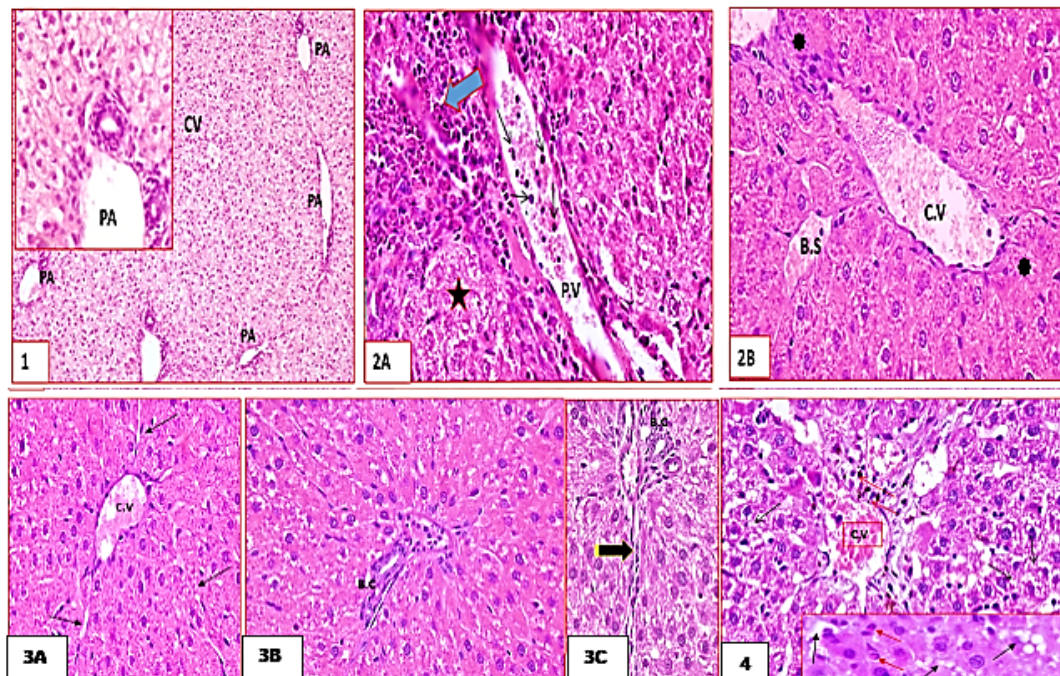
**Figure (6)** indicates the histopathological examination into four groups. **Group I**, the Control group, showed normal liver tissue architecture in (**Fig 1**), But in **Group II**, the Fibrotic group, the liver tissue showed predominant histopathological changes in the form of extensive disorganization of hepatocytes and hepatic cord dissolution. Varying degrees of cytoplasmic vacuolation and nuclear changes were occasionally observed, e.g., nuclear pyknosis (eccentric, dark stained, and small-sized nucleus), fragmentation, or lysis "karyolysis." Previous changes were

accompanied by marked congestion and dilatation of portal veins, central veins and blood sinusoids (**fig. 2A**). Widely distributed patchy necrosis and inflammatory cellular infiltration, mainly neutrophils concentrated around the central veins and extending towards the portal area were observed in the severely affected sections (**fig. 2B**). Group III, Prophylactic group, shows Marked improvement in the liver tissue was seen as they appeared nearly similar to that of the normal picture. Classic hepatic lobules were roughly hexagonal, with central veins forming their central axis from which hepatocyte cords radiated like sun rays. There were delicate interlobular septa and thin



sheaths of connective tissue surrounding the liver cells and the blood sinuses. Some tissue sections showed portal areas having branching bile canaliculi (**figs 3A, B, C**). In Group IV, the Treatment group Tissue sections showed slight improvement. Tissue sections

showed marked connective tissue deposition in the portal areas plus mononuclear cellular infiltration, mainly eosinophils, and many hepatocytes appeared vacuolated. Significant fibrosis was also seen around the central veins (**fig .4**).

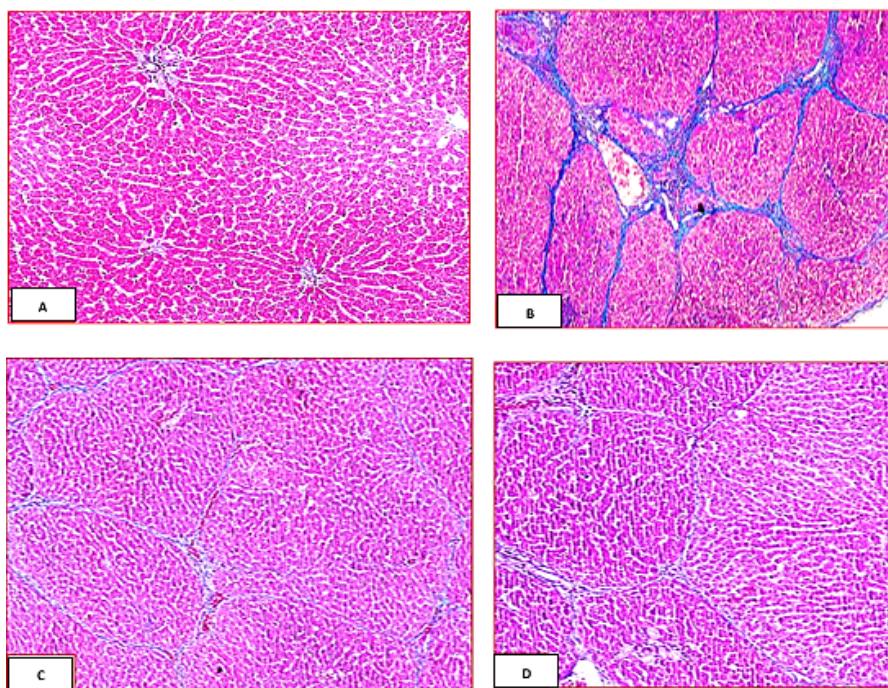


**Figure (6).** Photomicrographs of rat liver tissue by using H&E method; g1:1, g2:2A-2B,g3:3A-3B-3C,g4:4 showing: Normal liver architecture showing hexagonal classic hepatic lobules with central v (CV) surrounded by portal areas (PA) at each corner. Liver cells are arranged in cords and blood sinusoids in between rows of hepatocytes (arrows). 2A- Extensive disorganization of hepatocytes, patchy necrosis (star), and inflammation mainly around the portal areas (arrow). Notice dilated portal vein filled with inflammatory mononuclear cells, primarily neutrophils (arrows).2B- Showing congestion of central vein (CV) and blood sinusoids (BS) and dissolution of hepatic cords (asterisks). 3A, B, C- 3A, showing hepatocytes arranged in radiating and branching cords, and the parenchyma appears supported by a very delicate connective tissue (arrows).3B, C showing delicate interlobular septa (striped arrows) and a portal area having branching bile canaliculi (B.C). 4- Showing marked connective tissue deposition in the portal areas and around central veins, plus mononuclear cellular infiltration, mainly eosinophils (red arrows) and hepatocytes appear vacuolated (arrows). (H&E X200, 400).

#### Histopathological Examination of Liver Sections Using Masson's Trichrome

**Figure (7)** illustrates the histopathological examination using Masson's Trichrome method. **Group 1** revealed delicate collagen fibers in the interlobular septa and surrounding the liver cells and the blood sinusoids (**fig. A**). However, **group II** showed extensive collagen deposition in the portal

and inter-lobar connective tissue. Significant fibrosis was also seen around the central veins (**fig. B**). **Group III** revealed delicate collagen fibers in the interlobular septa and surrounding the liver cells and the blood sinusoids (**fig. C**). **Group IV** revealed a few collagen fibers in the interlobular septa and surrounding the liver cells and the blood sinuses (**fig. D**).



**Figure (7).** Masson trichrome stained liver tissue. g1: A, g2: B, g3:C, g4:D showing:

- A. control group shows normal collagen distribution.
- B. shows extensive collagen deposition in the portal and inter-lobar connective tissue. Significant fibrosis was also seen around the central veins.
- C. shows delicate collagen fibers in the interlobular septa and surrounding the liver cells and the blood sinusoids
- D. revealed few collagen fibers in the interlobular septa surrounding the liver cells and the blood sinusoids.

### Discussion

The liver is a crucial organ that manages many processes, such as metabolic balance, eliminating waste, and responding to immunological signals [28]. Hepatic fibrosis is a complicated disease that leads to long-term damage and involves several signaling pathways [29]. Damaged hepatocytes cause apoptosis, generating damage-associated molecular patterns (DAMPs) and ROS. These chemicals stimulate HSCs and attract immune cells, activating pro-inflammatory signaling pathways [29]. These pro-inflammatory mediators include TNF, IL-6, IL-1 $\beta$ , and others that assist in converting HSCs into myofibroblasts, promoting proliferation and protein production, including  $\alpha$ -SMA and collagen. This mechanism eventually causes the development of fibrosis [29]. When the natural factors of liver injury are eliminated, post-phagocytic macrophages play a significant role in fibrosis resolution. They reduce pro-inflammatory mediator production, induce apoptosis in active HSCs, restore the dormancy of HSCs, and encourage hepatocyte regeneration [29-31].

TAA is a common toxic term known to cause chronic liver injury [32]. Cytochrome P450 2E1 enzymes metabolically activate it in the liver, requiring two oxidative processes. TAA is first oxidized to TAA-S-oxide (TASO) and then to TAA-

S, S-dioxide (TASO<sub>2</sub>). These byproducts covalently bond to amine-lipids and proteins to create hepatotoxic chemicals [33]. The pathological alterations in TAA-induced liver fibrosis are comparable to human fibrosis [34]. Mice and rats are often used models for researching TAA-induced liver fibrosis [35, 36]. TAA injection in rats causes oxidative stress and inflammation, which results in chronic liver damage. TAA-induced liver fibrosis mimics human hemodynamic, morphological, and biochemical effects [36]. Consequently, TAA is an appropriate hepatotoxin for studying the processes of liver fibrosis, which is why we used TAA to make a rat model with hepatic fibrosis in this work. Elevated ALT, ALP, and AST levels are linked to hepatic inflammation and injury [28]. The current research found that their levels were significantly higher in the fibrotic group but markedly lower in the TAA-treated groups with Vitamin D and Telmisartan, indicating that they improved liver function and reduced hepatic injury.

The current study found that during TAA induction, GSH and SOD were reduced; however, they were dramatically increased following therapy with Vitamin D and Telmisartan, indicating antioxidant activity in fibrotic rats' liver tissues. Furthermore, MDA, produced from fatty acid peroxidation induced by ROS, has been shown to

promote apoptosis [37, 38]. Our results showed that the TAA-induced group considerably raised hepatic MDA levels. At the same time, therapy with VD3 and TEL demonstrated a significant reduction in these MDA levels, indicating the hepatoprotective of Vitamin D with telmisartan in mitigating hepatic oxidative stress during TAA-induced fibrosis. Our study found a considerable rise in pro-inflammatory cytokines involving IL-6, TNF- $\alpha$ , and IL-1 $\beta$  in the fibrotic group. VD3 and TEL reduced their levels in other groups. This might be attributed to Kupffer cell activation and increased activity. We investigated how VD and TEL inhibited the expression of various profibrotic and antifibrotic indicators, including coll Ia1,  $\alpha$ -SMA, MMP-9, and TIMP-1. The antifibrotic effect of VD3 with TEL was also demonstrated by the upregulation of MMP-9 activity. Our investigation identified pathogenic variations related to collagen deposition, including increased MMP-9, TIMP-1, and  $\alpha$ -SMA gene expression.

#### 4. Conclusions

In our investigation, we revealed the hepatoprotective effect of Vitamin D with Telmisartan. It substantially inhibited the progression of TAA-induced liver destruction, mitigating the hepatotoxic compound's effects. Our results indicate their crucial antioxidant, anti-inflammatory, and antifibrotic activities against TAA. Additionally, they suppressed the hepatic expression of the fibrogenic factor and the pro-inflammatory cytokine. We found a remarkable reducing oxidative stress and TIMP-1/P21 signaling pathways. The study found that combining Vitamin D with telmisartan reduced TAA-induced hepatic oxidative stress by boosting GSH and SOD levels while decreasing MDA, IL-6, IL-1 $\beta$ , and TNF $\alpha$ .

#### Funding

This research didn't receive any funds.

#### Conflicts of interest

There are no conflicts of interest.

#### Acknowledgements

We appreciate Prof. Dr Entesar Ali, Histology Department, Faculty of Medicine, Minia University, helping us with the histology part.

#### References

1. Friedman, S.L., Liver fibrosis – from bench to bedside. *Journal of Hepatology*, 2003. 38: p. 38-53.
2. Parola, M. and M. Pinzani, Liver fibrosis: Pathophysiology, pathogenetic targets and clinical

- issues. *Molecular Aspects of Medicine*, 2019. 65: p. 37-55.
3. Acharya, P., et al., Cellular mechanisms of liver fibrosis. *Frontiers in Pharmacology*, 2021. 12: p. 671640.
4. Mao, S., et al., The role and mechanism of hydrogen sulfide in liver fibrosis. *Nitric Oxide*, 2024. 145: p. 41-48.
5. Pu, T.-Y., et al., Lactoferrin as a therapeutic agent for attenuating hepatic stellate cell activation in thioacetamide-induced liver fibrosis. *Biomedicine & Pharmacotherapy*, 2024. 174: p. 116490.
6. Tan, Z., et al., Liver Fibrosis: Therapeutic Targets and Advances in Drug Therapy. *Front Cell Dev Biol*, 2021. 9: p. 730176.
7. Cohen-Naftaly, M. and S.L. Friedman, Current status of novel antifibrotic therapies in patients with chronic liver disease. *Therap Adv Gastroenterol*, 2011. 4(6): p. 391-417.
8. Veerakumar, D. and M. Muthulingam, A REVIEW ON HEPATOTOXICANT OF THIOACETAMIDE (C<sub>2</sub>H<sub>5</sub>NS). *Journal of Experimental Zoology India*, 2021. 24(2).
9. Elnfarawy, A.A., et al., Vinpocetine attenuates thioacetamide-induced liver fibrosis in rats. *Human & Experimental Toxicology*, 2020. 40(2): p. 355-368.
10. Bikle, D.D., Vitamin D metabolism, mechanism of action, and clinical applications. *Chem Biol*, 2014. 21(3): p. 319-29.
11. Jorge, A.J.L., et al., Vitamin D deficiency and cardiovascular diseases. *International Journal of Cardiovascular Sciences*, 2018. 31: p. 422-432.
12. Wacker, M. and M.F. Holick, Sunlight and Vitamin D: A global perspective for health. *Dermatoendocrinol*, 2013. 5(1): p. 51-108.
13. Lin, A.M., K.B. Chen, and P.L. Chao, Antioxidative effect of vitamin D3 on zinc-induced oxidative stress in CNS. *Ann N Y Acad Sci*, 2005. 1053: p. 319-29.
14. Bhat, M. and A. Ismail, Vitamin D treatment protects against and reverses oxidative stress induced muscle proteolysis. *The Journal of Steroid Biochemistry and Molecular Biology*, 2015. 152: p. 171-179.
15. Ayza, M.A., et al., Anti-Diabetic Effect of Telmisartan Through its Partial PPAR $\gamma$ -Agonistic Activity. *Diabetes Metab Syndr Obes*, 2020. 13: p. 3627-3635.
16. Tamaki, Y., et al., Angiotensin II type 1 receptor antagonist prevents hepatic carcinoma in rats with nonalcoholic steatohepatitis. *Journal of gastroenterology*, 2013. 48: p. 491-503.
17. Bataller, R., et al., Systemic infusion of angiotensin II exacerbates liver fibrosis in bile duct-ligated rats. *Hepatology*, 2005. 41(5): p. 1046-1055.



18. Schuppan, D., et al., The challenge of developing novel pharmacological therapies for non-alcoholic steatohepatitis. *Liver International*, 2010. 30(6): p. 795-808.
19. Li, C.-J., et al., Effects of aspirin and enoxaparin in a rat model of liver fibrosis. *World journal of gastroenterology*, 2017. 23(35): p. 6412.
20. Derakhshanian, H., et al., The Effect of Vitamin D on Cellular Pathways of Diabetic Nephropathy. *Rep Biochem Mol Biol*, 2019. 7(2): p. 217-222.
21. Abramovitch, S., et al., Vitamin D inhibits development of liver fibrosis in an animal model but cannot ameliorate established cirrhosis. *American Journal of Physiology-Gastrointestinal and Liver Physiology*, 2015. 308(2): p. G112-G120.
22. Noma, K., et al., Telmisartan suppresses food intake in mice via the melanocortin pathway. *Obesity research & clinical practice*, 2011. 5(2): p. e93-e100.
23. Gella, F.J., et al., A simple procedure for the routine determination of aspartate aminotransferase and alanine aminotransferase with pyridoxal phosphate. *Clinica chimica acta*, 1985. 153(3): p. 241-247.
24. Belfield, A. and D.M. Goldberg, Normal ranges and diagnostic value of serum 5' nucleotidase and alkaline phosphatase activities in infancy. *Archives of disease in childhood*, 1971. 46(250): p. 842-846.
25. Doumas, B.T., W.A. Watson, and H.G. Biggs, Albumin standards and the measurement of serum albumin with bromocresol green. *Clinica chimica acta*, 1971. 31(1): p. 87-96.
26. Ohkawa, H., N. Ohishi, and K. Yagi, Assay for lipid peroxides in animal tissues by thiobarbituric acid reaction. *Analytical Biochemistry*, 1979. 95(2): p. 351-358.
27. Ballou, S.P. and G. Lozanski, Induction of inflammatory cytokine release from cultured human monocytes by C-reactive protein. *Cytokine*, 1992. 4(5): p. 361-368.
28. Duarte, S., et al., Matrix metalloproteinases in liver injury, repair and fibrosis. *Matrix Biology*, 2015. 44-46: p. 147-156.
29. Pellicoro, A., et al., Liver fibrosis and repair: immune regulation of wound healing in a solid organ. *Nature Reviews Immunology*, 2014. 14(3): p. 181-194.
30. Henderson, N.C. and J.P. Iredale, Liver fibrosis: cellular mechanisms of progression and resolution. *Clinical Science*, 2007. 112(5): p. 265-280.
31. Bataller, R. and D.A. Brenner, Liver fibrosis. *The Journal of clinical investigation*, 2005. 115(2): p. 209-218.
32. Delire, B., P. Stärkel, and I. Leclercq, Animal models for fibrotic liver diseases: what we have, what we need, and what is under development. *Journal of clinical and translational hepatology*, 2015. 3(1): p. 53.
33. Ezhilarasan, D., Molecular mechanisms in thioacetamide-induced acute and chronic liver injury models. *Environmental Toxicology and Pharmacology*, 2023. 99: p. 104093.
34. Li, X., I.S. Benjamin, and B. Alexander, Reproducible production of thioacetamide-induced macronodular cirrhosis in the rat with no mortality. *Journal of Hepatology*, 2002. 36(4): p. 488-493.
35. Liedtke, C., et al., Experimental liver fibrosis research: update on animal models, legal issues and translational aspects. *Fibrogenesis & tissue repair*, 2013. 6: p. 1-25.
36. Wu, S., et al., An update on animal models of liver fibrosis. *Frontiers in Medicine*, 2023. 10: p. 1160053.
37. Requena, J.R., et al., Lipoxidation products as biomarkers of oxidative damage to proteins during lipid peroxidation reactions. *Nephrology Dialysis Transplantation*, 1996. 11(supp5): p. 48-53.
38. Zahran, H., Gad, M. A., Fawzy, M., & Hassan, H. (2021). The role of different edible vegetable oils as hypolipidemic agents on experimental hyperlipidemic rat model. *Egyptian Journal of Chemistry*, 64(11), 6231-6242.