

Potential protective effect of Panax ginseng extract on corticosteroid induced myopathy

Maha Abd-El Baki Ahmed ^a, Nahla Shahat Ismail^a, Yahia A. Amin^{b*}, Hoda Ahmed M. Abdel-ziz ^{c,d}, Ahmed Talat Galal ^{c,d}, Tarek Hamdy Abd-Elhamid ^{e,f}

^aDepartment of Human Anatomy & Embryology, Faculty of Medicine, South Valley University, Qena, Egypt.

^bDepartment of Theriogenology, Faculty of Veterinary Medicine, Aswan University, Aswan 81528, Egypt

^cDepartment of Human Anatomy & Embryology, Faculty of Medicine, Assiut University, Assiut, Egypt

^dDepartment of Basic Medical Sciences, Badr University, Assiut, Egypt

^eDepartment of Histology and Cell Biology, Faculty of Medicine, Assiut University, Assiut 71515 Egypt

^fDepartment of Basic Medical Sciences, Faculty of Medicine, Aqaba Medical Sciences University, Ports Hwy, Aqaba 77110 Jordan

Abstract

Background: Myopathy is a side effect long term use of glucocorticoid. Ginseng extract has an antioxidant, and anti-inflammatory activities that have been reported in the muscular tissue.

Objectives: This study aimed to investigate whether the administration of ginseng ameliorates glucocorticoid-induced skeletal muscles damage in male albino rats.

Materials and methods: Forty male rats were randomly divided into four groups (10/group). Group I (Control group): Rats received normal diet and saline, Group II: (Dexa group). Rats given dexamethasone, 0.5mg/kg for one month, Group III (Ginseng group): Ginseng extract was administered daily for one month, 300 mg/kg, Group IV (Treated group): Ginseng was administered for 14 days after giving dexamethasone for another 16 days. Body weight at different time points was measured and skeletal muscles specimens were processed for light and electron microscopic (EM) examination and immunohistochemistry (IHC) assessment by apoptotic marker, Caspase 3 and CD105 as homing stem cell markers.

Results: Dexa group showed decrease in body weight, histologically myofibrillar degeneration, increased connective tissue infiltration, decreased cross-sectional area, strong positive reaction with Caspase 3 and mild positive reaction with CD105. Treated group showed regeneration of muscle fibers, increased cross-sectional area ($p < 0.001$), and decreased reaction with Caspase 3 and increased with CD105. Assessment of area percentage of their immunostaining of caspase 3 was significantly increased in dexa group and decreased in treated group ($p < 0.001$) while CD105 was significantly increased in treated group compared to dexa group.

Conclusion: Ginseng extract improved myopathic manifestations caused by dexamethasone.

Keywords: Myopathy; Dexamethasone; Panax ginseng; Skeletal muscle.

DOI: 10.21608/SVUIJM.2024.324368.1985

*Correspondence: yahiaamin2030@gmail.com

Received: 1 October, 2024.

Revised: 4 November, 2024.

Accepted: 5 November, 2024.

Published: 8 November, 2024

Cite this article as: Maha Abd-El Baki Ahmed, Nahla Shahat Ismail, Yahia A. Amin, Hoda Ahmed M. Abdel-ziz, Ahmed Talat Galal, Tarek Hamdy Abd-Elhamid. (2024). Potential protective effect of Panax ginseng extract on corticosteroid induced myopathy. *SVU-International Journal of Medical Sciences*. Vol.7, Issue 2, pp: 812-831.

Copyright: © Ahmed et al (2024) Immediate open access to its content on the principle that making research freely available to the public supports a greater global exchange of knowledge. Users have the right to Read, download, copy, distribute, print or share link to the full texts under a [Creative Commons BY-NC-SA 4.0 International License](https://creativecommons.org/licenses/by-nc-sa/4.0/)

Introduction

Exogenous glucocorticoids are now the most frequent cause of drug-induced myopathy due to the increasing usage of glucocorticoids to treat a variety of medical diseases such as autoimmune and inflammatory diseases (Pereira and de Carvalho, 2011). Myopathy can occur with many widely used glucocorticoid, however it is more frequently associated with fluorinated glucocorticoid preparations, such as betamethasone, triamcinolone, and dexamethasone (Gupta and Gupta, 2013; Shi et al., 2019; Wu et al., 2022).

Dexamethasone, a synthetic glucocorticoid, causes muscle atrophy as a side effect because it down regulates myogenin, this prevents myogenesis, and increases the synthesis of myostatin. Myostatin is mainly responsible for downregulating the differentiation and the proliferation of muscle satellite (stem) cells and thus inhibits the development of muscle mass (Gupta and Gupta, 2013; Lee et al., 2021). It is believed that a fundamental function of the ubiquitin-protease system (UPS) in muscle protein degradation contributes to the catabolic impact of glucocorticoids (Attaix et al., 2005). The muscle RING-finger protein-1 (MuRF-1) and atrogin-1; the two ubiquitin ligases involved in targeting of proteolysis by proteasome machinery, are two examples of the atrogenes or "genes involved in atrophy" that are highly expressed in response to glucocorticoids, which stimulate the UPS (Komamura et al., 2003). Glucocorticoids prevent amino acids from entering the muscle, which may reduce the amount of protein synthesis (Shah et al., 2000; Xu et al., 2022).

Research indicates that the administration of glucocorticoids activates the apoptotic signals mediated by the mitochondria. It has been demonstrated that ceramide accumulation, proteasome, and IGF-

1 signaling inhibition may all be significant factors in glucocorticoid-induced apoptosis and myopathy (Dirks-Naylor and Griffiths, 2009).

The root of the Araliaceous plant, *Panax ginseng*, has long been utilized in Chinese medicine for its immune-boosting, anti-tumor, antioxidant, anti-aging, and organ-protective properties (Attele et al., 1999; Shi et al., 2019). Ginseng plays a major function in enhancing immunity against autoimmune disorders, bacterial and viral infections, and cancer (Riaz et al., 2019). Moreover, the FDA typically considers ginseng to be safe (Vaughn, 2012). Regarding the ginseng constituents, to date, over 100 ginsenosides are found; additionally, multiple pharmacological validations are provided. The pharmacological and clinical characteristics of ginsenosides have been the focus of numerous research among them (Siti et al., 2015). Additionally, it was reported that ginseng has protective effects on muscle atrophy in rats (Jiang et al., 2019).

Myosin heavy chain (MyHC) levels in differentiated myoblast are likewise enhanced by mountain ginseng therapy (Seok et al., 2021), while MyHC levels are decreased by dexamethasone (Clarke et al., 2007). Ginseng therapy prevents myostatin from being highly expressed (Ahmad et al., 2024). Mountain ginseng significantly reduces the expressions of atrogin1 and MuRF1 (Seok et al., 2021), which both are transcriptionally upregulated under atrophic conditions (Bodine and Baehr, 2014). MuRF1 has been shown to play a direct role in myosin heavy chain ubiquitination and degradation during synthetic glucocorticoid treatment (Clarke et al., 2007). It has been shown that ginsenosides Rg1 and Rb2 cause myoblast differentiation by activating p38 and Akt signaling (Go et al., 2020).

Muscle stem cells (MuSCs); often referred to as satellite cells, have the capacity

for both differentiation and proliferation. Normally quiescent MuSCs are activated and undergo additional differentiation following skeletal muscle injury to support muscular tissue regeneration and preserve skeletal muscle homeostasis. Since oxidative stress causes inflammation and damage, skeletal muscle's ability to regenerate itself depends mostly on its ability to self-renew via activating and differentiating MuSCs (Yanay et al., 2020). Many of researches have revealed that MuSC dysfunction has been linked to several myopathies, including disused muscular atrophy and Duchenne muscular dystrophy (Liu et al., 2021; Yamakawa et al., 2020).

The MuSC population or function was compromised, which increased its susceptibility to free-radical stress and slowed its rate of damage recovery. Senescent MuSCs mechanically experienced greater oxidative stress and were more readily eliminated through apoptosis or went into an irreversible quiescent state (Picca et al., 2018). A bioactive ingredient taken from ginseng called ginsenoside Rb1 has an anti-aging, anti-inflammatory, and antioxidant properties (Zhou et al., 2019). Ginsenoside Rb1 may improve MuSC function and prevent apoptosis by lowering oxidative stress levels, thereby mitigating oxidative damage to MuSCs or revitalizing MuSCs in senescent skeletal muscle (Dong et al., 2022). Therefore, the current study aimed to declare to what extent panax ginseng can alleviate myopathic features induced by dexamethasone.

Materials and methods

Experimental animals

The study protocol was approved by the Institutional Research Committee at the Faculty of Medicine, South Valley University, Qena, Egypt. Number ANA00122211492. Forty male Wistar rats (8-12 weeks old), weighing 135-185 gm were used in the study. The animals were purchased from the official

animal supplier of the Faculty of Science, South Valley University. The study was carried out at the animal house of the Faculty of Medicine, South Valley University. Throughout the study, rats were housed in wire mesh cages under strict hygienic measures and was allowed for acclimatization two weeks before the start of the experiment. Rats were kept in room temperature, 55-60% humidity and normal light/dark cycle with free access to food pellets and tap water. They were randomly assigned to four groups of ten rats for each one.

Experimental design

The animals were equally divided into four groups (ten rats for each) as the following (Fig.1): Group I (Control group): Control healthy group, rats received normal diet and saline.

Group II (Dexamethasone group): Rats were given dexamethasone at a dose of 0.5mg/kg for one month by intraperitoneal injection (Huang et al., 2018), Dexamethasone phosphate (Dexa): Ampoules (8mg/2ml), is a product of AMRIYA Pharmaceutical Industries-Egypt.

Group III (Ginseng group): Rats were given panax ginseng extract only in a dose of 300 mg/kg daily for one month via oral gavage (Estaki and Noble, 2015). Panax ginseng radix powder was obtained from El Gomhoria Company, Assuit, Egypt.

Group IV (Treated): Ginseng was administered for 14 days after giving dexamethasone for another 16 days.

Assessment method

For assessment of body weight, each rat's body weight in all groups was measured weekly by a digital scale and recorded. For sampling, after the experiment (over 30 days), the animals got unconscious with diethyl ether and had intracardiac perfusions of 10% neutral buffered formalin and saline. Gastrocnemius muscle was dissected and sectioned longitudinally and transversely then

fixed in 10% formalin for histopathological examination and IHC staining.

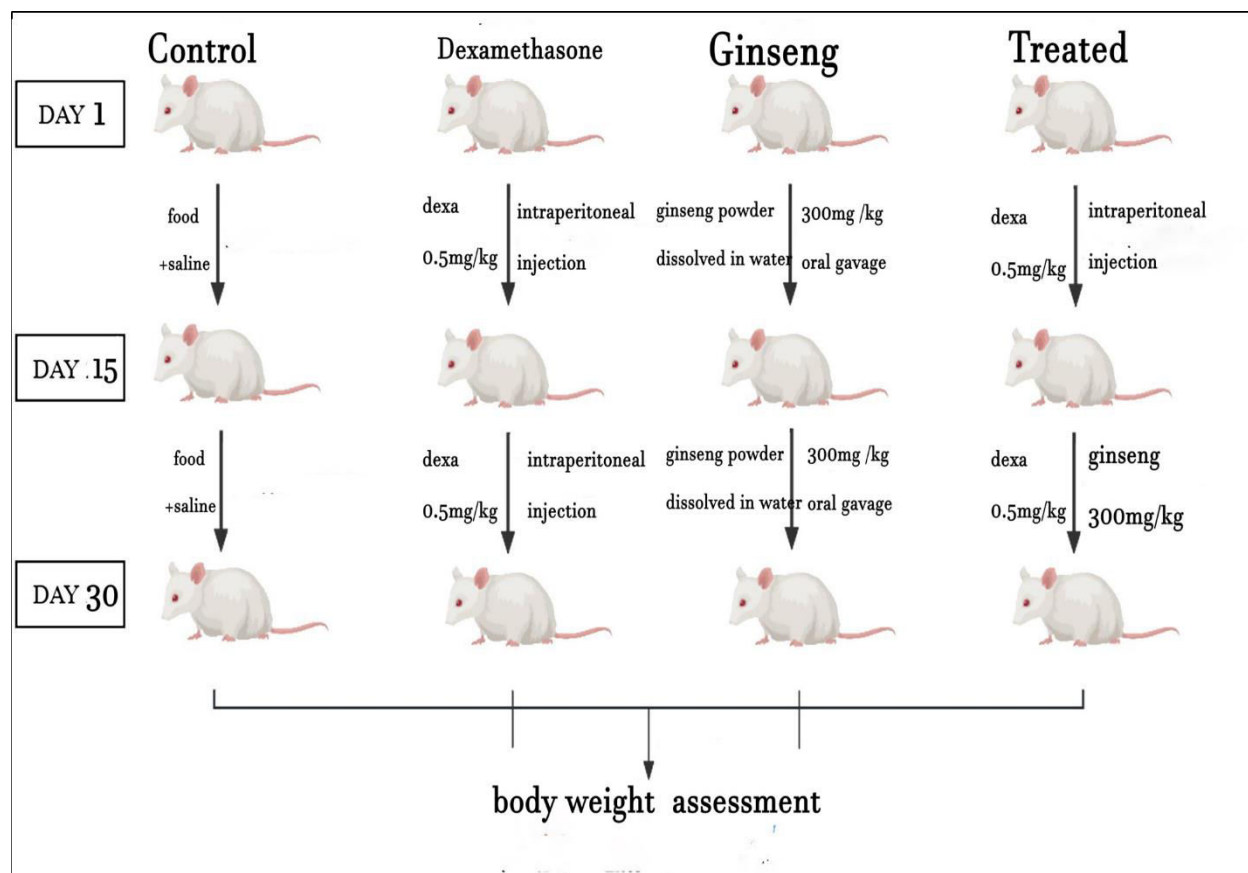


Fig.1. Summarized study design shape

Histopathological and immunohistochemical assessment

General histological examination

Preparation of tissues for histology was done (Slaoui et al., 2017). Briefly, the specimens were taken from the gastrocnemius muscle of the three groups and were fixed in 10% buffered formalin for at least 24 hours (h), and passed in ascending grades of alcohol. The specimens were cleared in Cedar-wood oil and impregnated in Paraffin wax, sectioned (5 microns thickness) and stained with hematoxylin and eosin (H&E) for general histological structure study and with Masson Trichrome for collagen fibers of muscle in different groups and evaluated

using a Leica microscope (CH9435 Hee56rbrugg, Leica Microsystems, Switzerland), Faculty of Medicine, South Valley University.

Electron Microscopic Examination

Muscle samples for EM examination were fixed in 2.5–3% glutaraldehyde in cacodylate buffer for 24 h. Samples were postfixated in osmium tetroxide in phosphate buffer for 2 h, dehydrated in graded alcohols, and embedded in epoxy resin blocks. Semithin sections (0.5 μ m) were cut, stained with toluidine blue, and examined using a light microscope. Ultrathin sections (70–80 nm) were prepared from selected areas in semithin sections, mounted on copper grids, and

contrasted with uranyl acetate and lead citrate according to previously published (Tizro et al., 2019). Sections were examined and photographed using a JEOL1010 CX Japan transmission EM in South Valley University.

Immunohistochemistry Staining Protocol:

The sections were deparaffinized and pre-treated with citrate buffer retrieval solution (pH6) for antigen retrieving (Shi et al., 1993). Briefly, a staining dish containing 10 mM citrate buffer was heated in a water bath at 95-100°C. The slides were immersed in the staining dish, loosely covered, incubated for 20 minutes (min) and then left to cool for 20 min at room temperature. Tissue sections were then immunostained using avidin-biotin complex (ABC) methods. IHC caspase 3 staining was performed using a rabbit anti-cleaved caspase 3 antibody (1:500, NO. 9661, Cell Signaling Technology, Frankfurt, Germany), and IHC caspase 3 staining was performed using FITC mouse anti-human CD105 antibody (1:100 from Serotec, Bavaria, GER). Image J software for morphometric assessment was used.

Statistical analysis

Data was collected, coded, revised, and entered into the Statistical Package for Social Science (IBM SPSS) version 27. The data was presented as means \pm standard deviation (SD) for the numerical variables with parametric distribution.

One-way ANOVA (Analysis of variance) compares tested groups with

quantitative data and parametric distribution, followed by a post hoc test using Bonferroni correction for pairwise comparison. A repeated measure ANOVA (analysis of variance) was used to evaluate the intra-group difference along different time intervals. The allowable margin of error was set at 5%, while the confidence interval was set at 95%. Consequently, the p-value was deemed significant (S) when $p < 0.05$: and highly significant when $p < 0.01$.

Results

Control and ginseng groups of rats gained weight during the experimental periods. In contrast, the dexamethasone group (dexa group) showed loss of body weight during experimental time. Therefore, it is obvious improvement in weight loss in treated group during the 4th week (Table.1 and Fig.2). In light microscopic examination (Figure 3), the muscle fibers of control and ginseng groups (group I & III) (Fig.3 a & c) showed normally arranged myofibers. There was no obvious variation in muscle fiber size or shape. Cytoplasmic staining was uniform, and small peripherally located nuclei were marked. Variation in fiber size and shape was seen in the dexa group (group II) (Fig.3b). Necrotic fibers invaded by numerous macrophages were seen. These all-destroyed changes were improved after ginseng administration in treated group (group IV) (Fig.3d).

Table 1. Weight of rats (gm) at different time points among the four experimental groups (n=10).

Recall Times	Rats' groups					Pairwise comparison (p-value***)					
	Group I (n=10)	Group II (n=10)	Group III (n=10)	Group IV (n=10)	P value	I vs. II	II vs. III	III vs. IV	I vs. IV	I vs. III	II vs. IV
Day 0	149.4 \pm 11.52	163.8 \pm 22.23	162 \pm 7.8	167.7 \pm 14.54	0.055						

Week 1	160± 13.44	175.2 ± 23.47	178.3 ± 16.73	171.5 ± 11.1	0.099						
Week 2	173.9± 12.63	147.8 ± 16.34	189 ± 15.39	148.6 ± 5.23	< 0.001*	<0.001	<0.001	<0.001	<0.001	0.06 6	0.999
Week 3	200.3 ± 20.7	136.9 ± 8.47	216.2 ± 18.67	157.9 ± 12.42	< 0.001*	<0.001	<0.001	<0.001	<0.001	0.13 1	0.026
Week 4	256.7 ± 32.08	131 ± 12.36	269.1± 36.65	236.1 ± 18.59	<0.001*	<0.001	<0.001	0.043	0.329	0.73 0	<0.001
P value	<0.001* *	<0.001* *	<0.001* *	<0.001* *							

* One-way ANOVA, **Repeated measure ANOVA, ***Post hoc test with Tukey correction. Group I (control), Group II (dexamethasone), Group III (ginseng), Group IV (Treated). Values are expressed as mean ± SD. Day 0: time before the start of the experiment

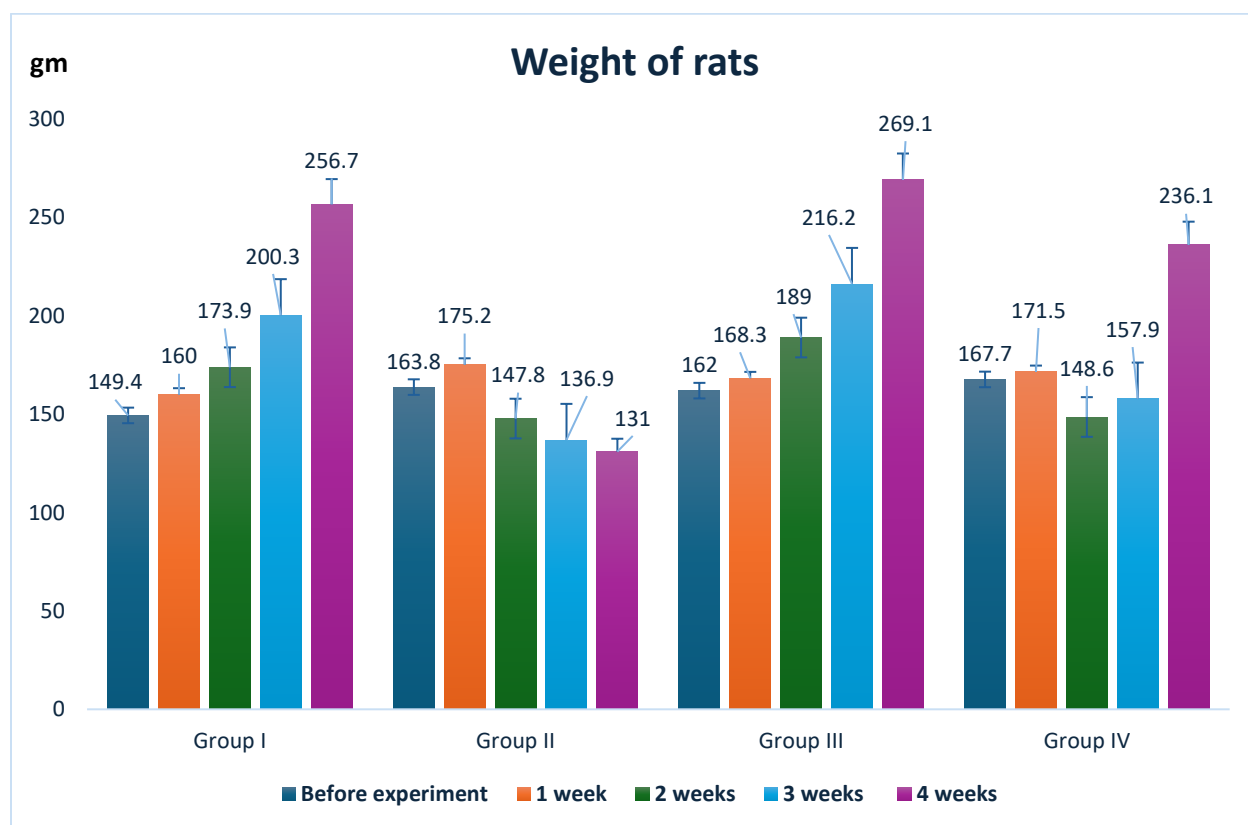


Fig. 2. Rats’ weight among the four studied groups during the experiment.

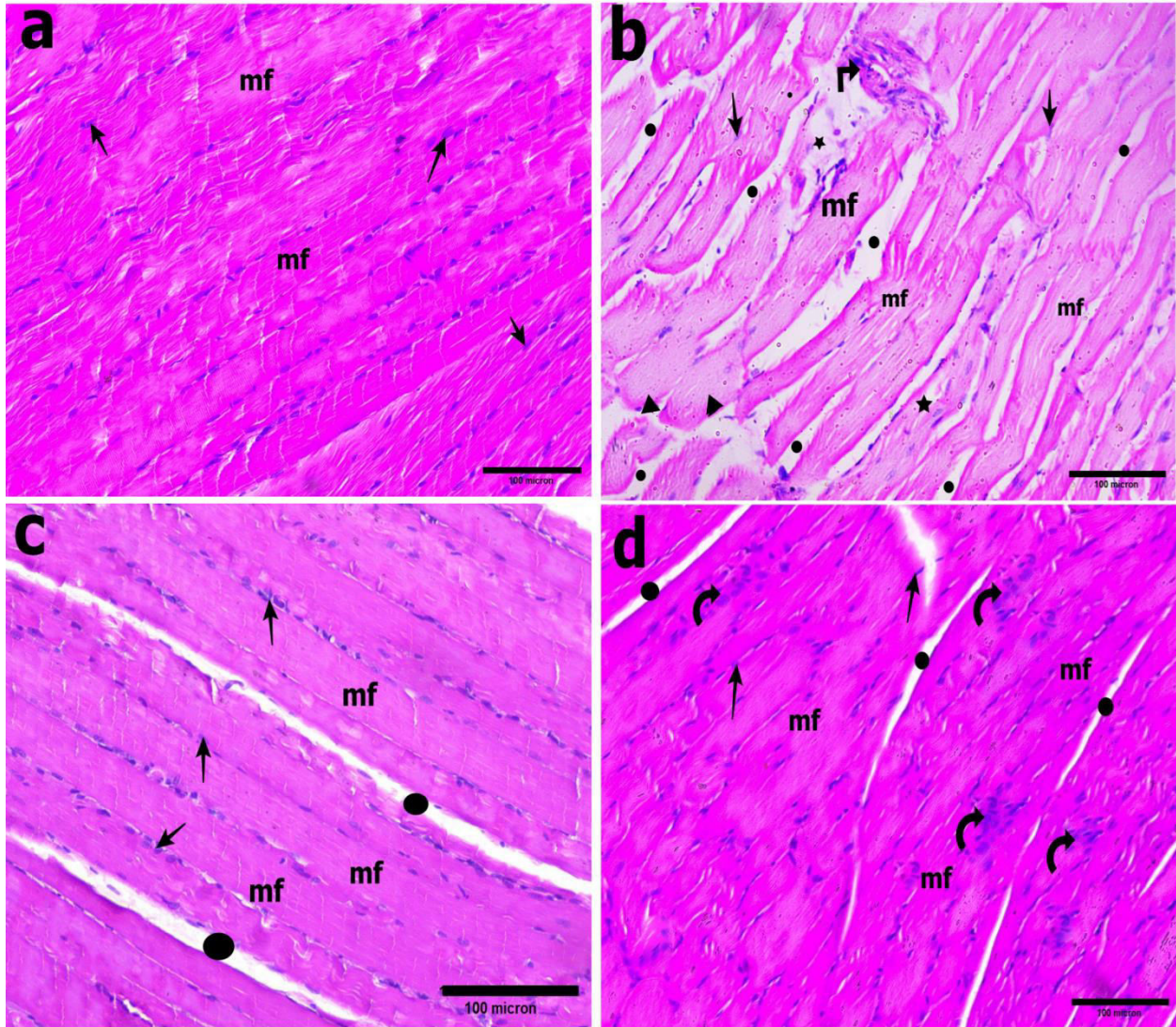


Fig.3. Photomicrographs of longitudinal section (LS) of gastrocnemius muscle stained by H&E. (a & c) represent control and ginseng groups respectively and showed that the myofibers (mf) were aligned parallel to each other, and had normal arrangement, deeply stained acidophilic sarcoplasm and multinucleated myocytes at the periphery (arrow), and normal site and size of perimysium (black circle). (b) represents dexa group showing necrosis of fibers with aggregation of connective tissue cells (broken arrow), cytoplasmic vacuolations (star), pale sarcoplasm, increased variations in size of fibers which were mostly decreased but occasionally there were swollen fibers (triangle) and increased spaces between fascicles indicating increased sized perimysium (black circle). (d) Represents treated group showing nearly normal arrangement, size and shape of myofibers, and nearly normal sites for perimysium. There are aggregations of cell in the center of myofibers (curved arrow) indicating regeneration. Scale bar = 100.

To confirm our results, the cross-sectional area of muscle fiber in transverse section of gastrocnemius muscle was evaluated using ImageJ software. It was found that the mean \pm SD of cross-sectional area

was $550.35 \pm 68.76 \mu\text{m}^2$ in control group, $174.85 \pm 50.26 \mu\text{m}^2$ in dexa group, $509.95 \pm 51.93 \mu\text{m}^2$ in the ginseng group and $568.40 \pm 178.71 \mu\text{m}^2$ in treated group ($p < 0.001$) (Fig.4).

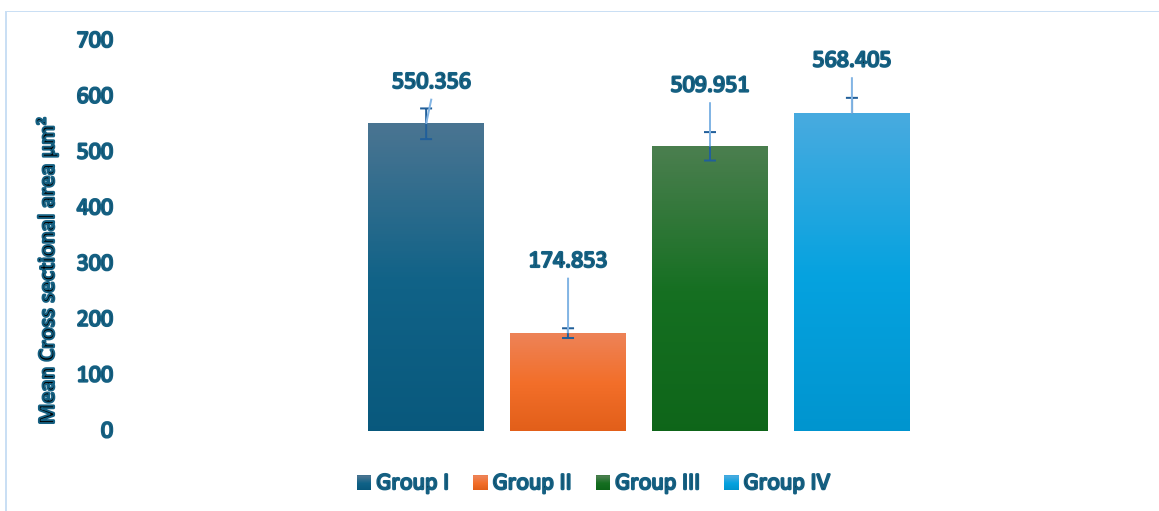


Fig.4. Mean cross-sectional areas of transversely sectioned gastrocnemius muscle fibers. Each column represents mean \pm SD of cross-sectional area of each muscle fiber in six H&E slides of each group ($n = 6$). It was observed that cross sectional area in dexa group was significantly reduced compared to control and ginseng groups ($p < 0.001$) and significantly increased in treated group compared to dexa group ($p < 0.001$).

In Masson trichrome staining (**Fig.5**), control and ginseng groups showed red stained myofibers and blue stained minimal collagen fibers between fascicle represent perimysium. Dexa group showed red stained abnormally arranged myofibers and abnormal

and abundant blue stained collagen fibers invasion, but treated group showed normally arranged red stained myofibers and there were still few invasions of collagen fibers within the myofibers.

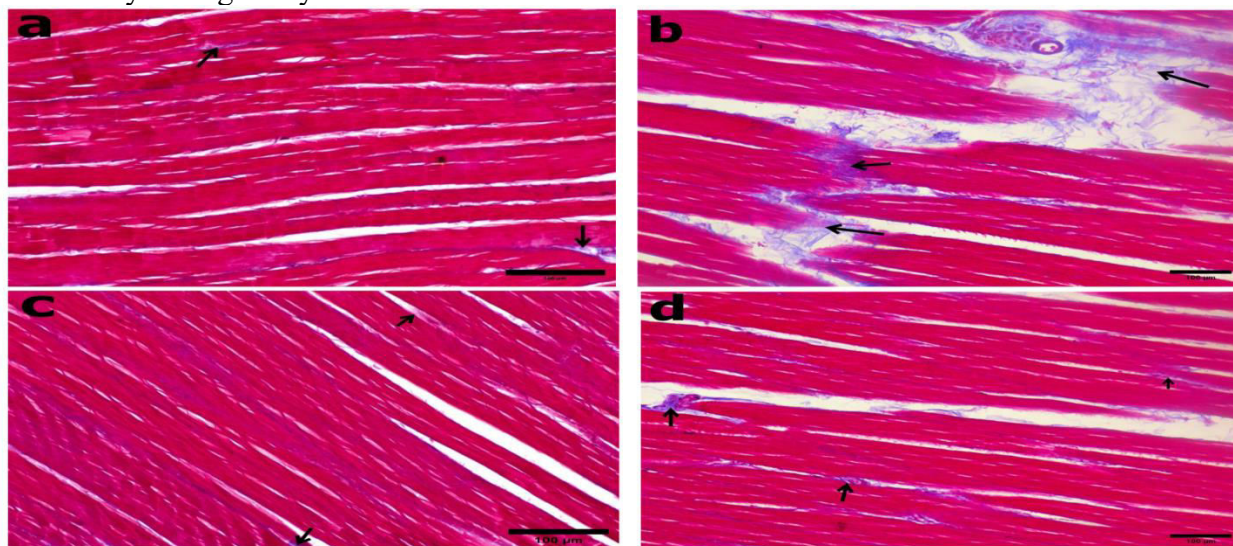


Fig.5. Photomicrographs of LS of gastrocnemius muscle stained by Masson's trichrome stain. (a & c) represent control and ginseng groups showing red stained myofibers and minimal collagen fibers between fascicles represent perimysium (arrow). (b) Represents dexa group showing abnormal arrangement of red stained myofibers and abnormal and abundant collagen fibers deposition stained blue (arrow). (d) Represents treated group showing normal arrangement of red stained myofibers and there were still few collagen fibers deposition within the myofibers. Scale bar = 100.

Immunohistochemistry staining for caspase 3 (apoptotic marker) revealed faint staining in control and ginseng groups and a strong positive reaction in the dexta group. In contrast, mild positive reaction was observed in the treated group (**Fig.6**). To confirm these results, ImageJ software was used to assess the area percentage of Caspase 3 immunostaining and it was 27.75 ± 0.28 % in

control group, 99.52 ± 0.31 % in dexta group, 21.02 ± 0.028 % in ginseng group and 44.61 ± 0.28 % in treated group. The percentage of area of Caspase 3 immunostaining was significantly increased in dexta group compared to control and ginseng groups while it was significantly decreased in the treated group ($p < 0.001$) (**Fig.7**).

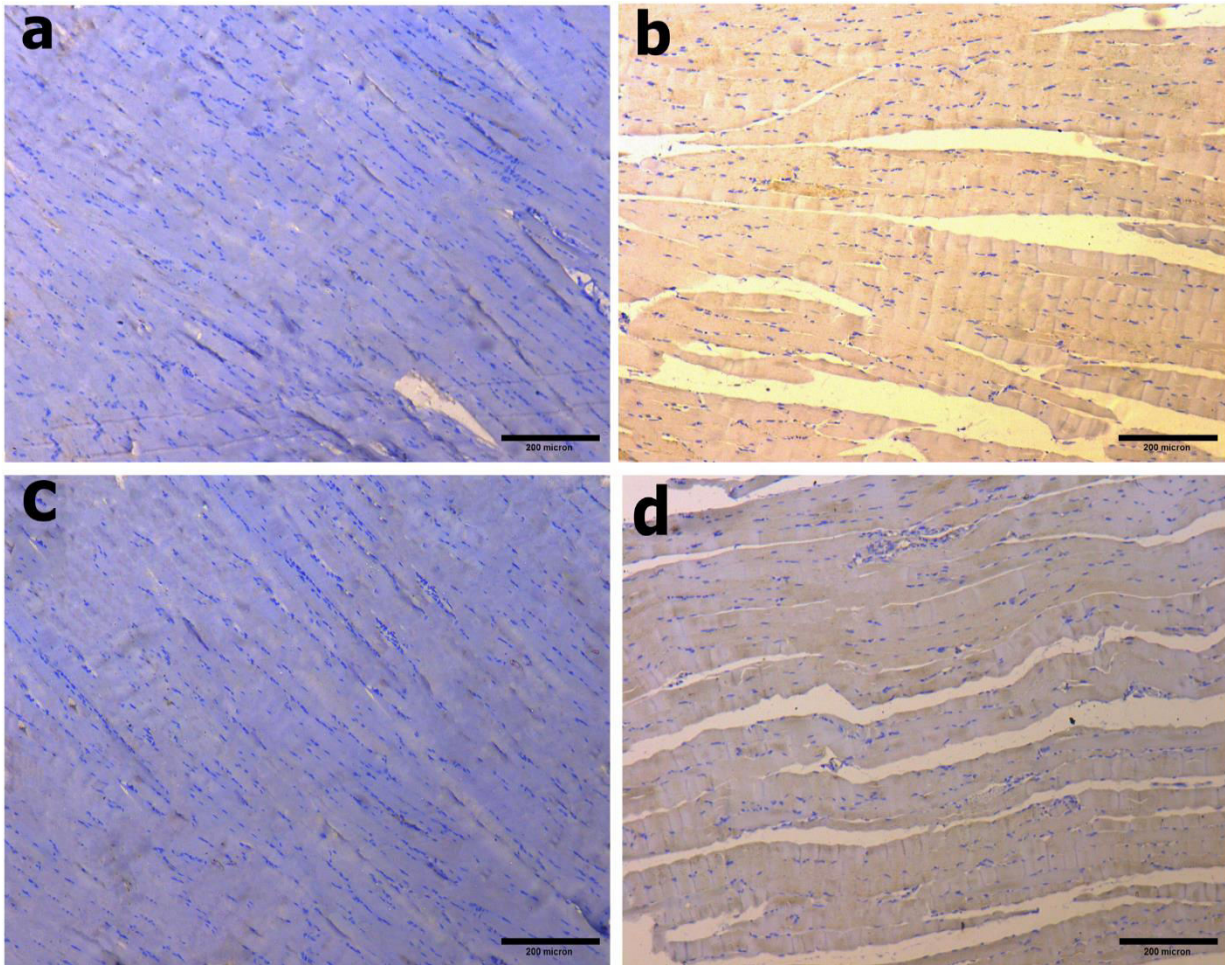


Fig.6. Photomicrographs of IHC localization of Caspase 3 marker as apoptotic marker in LS of gastrocnemius muscle in all groups presented by brown color. Control (a) and ginseng (c) groups showed faint immunostaining while in dexta group (b) the reaction was strong positive. On the other hand, treated group (d) showed weak positive reaction. Scale bar = 100 μ m.

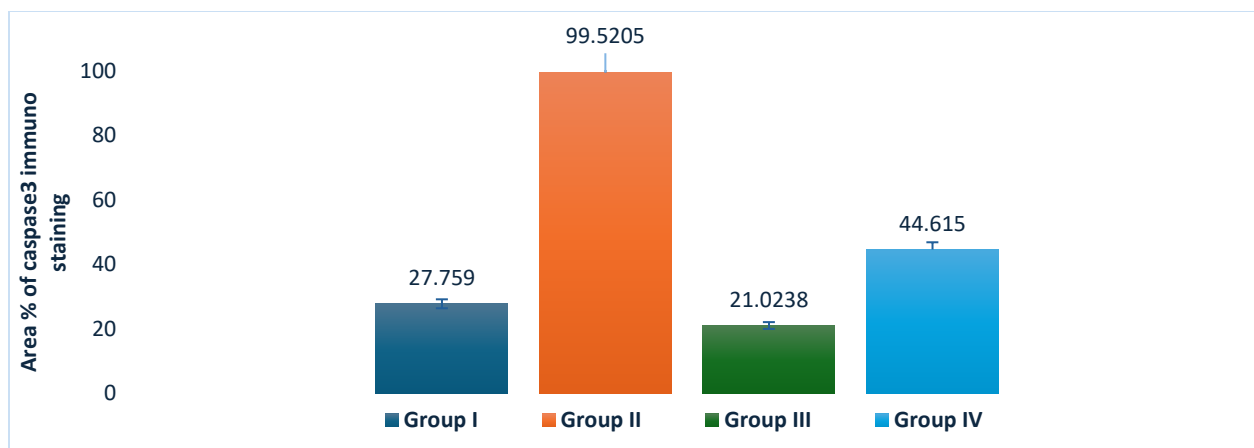


Fig.7. Graphical representation of the percentage of area of caspase 3 immunostaining evaluated by image J software. It was observed that the percentage of area of caspase 3 was 99.52 ± 0.31 in dexamethasone group, 27.75 ± 0.28 in control group, 21.02 ± 0.028 in ginseng group and 44.61 ± 0.28 in treated group. The percentage of area of caspase 3 immunostaining was significantly reduced in treated group ($p < 0.001$).

Using CD105 as a homing mesenchymal stem cell marker (Fig.8) reveals that the myofibers were faint stained in control and ginseng groups (Fig.8 a & c), strongly positive stained in group IV (Fig.8d) and less stained in dexamethasone group (Fig.8b). Confirmation of these results was done by assessment of the percentage of area of CD105 immunostaining using ImageJ

software. It was observed that the percentage of area of Caspase CD105 immunostaining was $0.40 \pm 0.001\%$ in control group, $57.17 \pm 0.53 \%$ in dexa group, $7.64 \pm 0.67 \%$ in ginseng group and $97.27 \pm 0.60\%$ in treated group. The percentage of area of CD105 immunostaining was significantly increased in treated group compared to control and ginseng groups ($p < 0.001$) (Fig. 9).

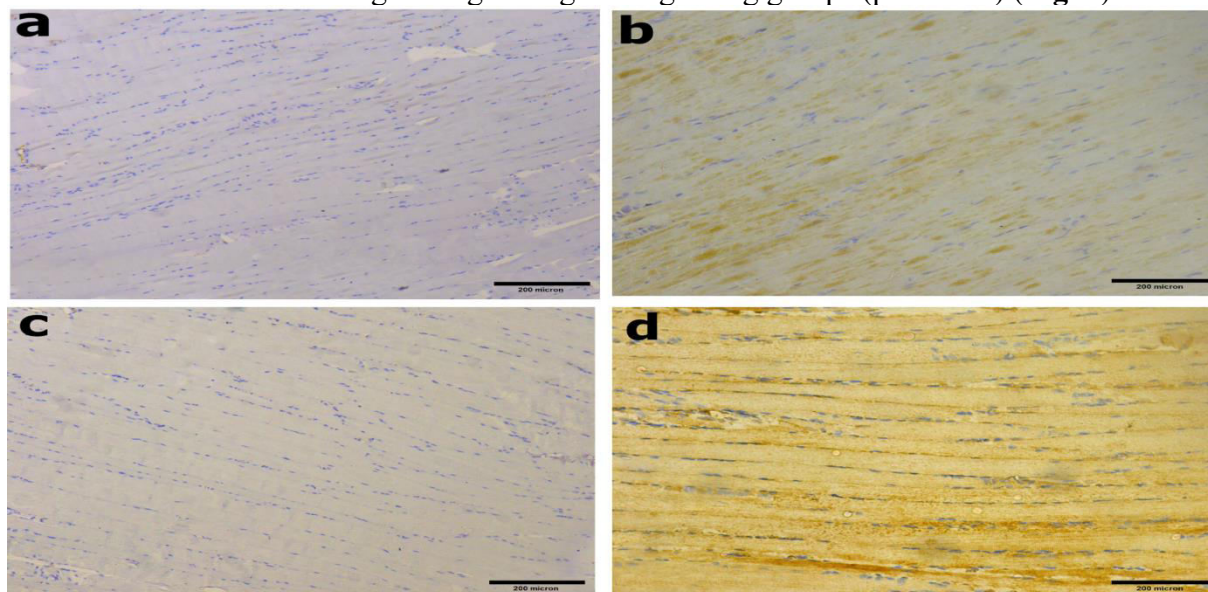


Fig.8. Photomicrographs of IHC localization of CD105 marker as a homing stem cell marker in LS of gastrocnemius muscle in all groups presented by brown color. Control (a) and ginseng (c) groups showed faint immunostaining while in dexa group (b) the reaction is mild positive. On the other hand, treated group (d) showed strong positive reaction. Scale bar = 100 μm .

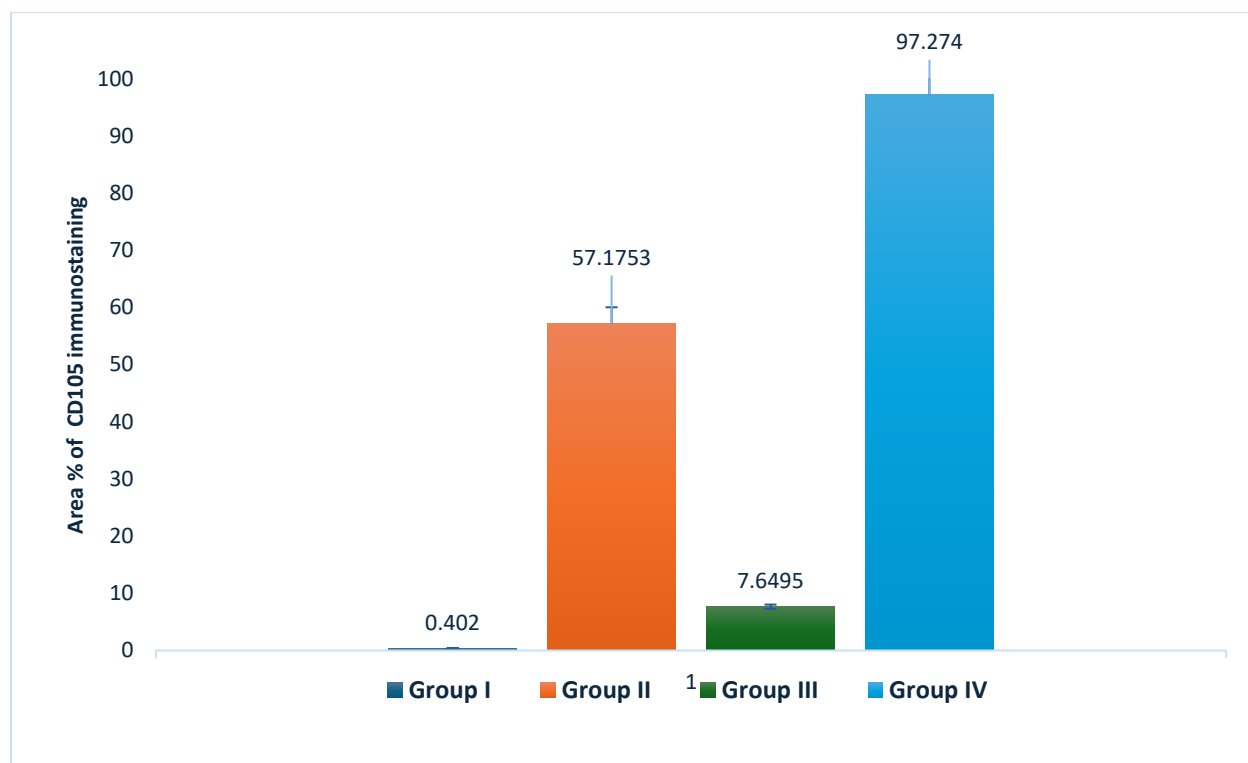


Fig. 9. Graphical representation of the area percentage of CD105 immunostaining evaluated by image J software. It was observed that the percentage of area of CD105 were 57.17 ± 0.53 in dexamethasone group, 0.402 ± 0.001 in control group, 7.64 ± 0.67 in ginseng group and 97.27 ± 0.60 in treated group. The percentage of area of CD105 immunostaining was significantly increased in treated group ($p < 0.001$)

Transmission electron microscopy

In dexamethasone group (Fig.10 b), the myofibrils were degenerated, thin, had distorted pattern and arrangement with loss of bands. The Z-lines were irregularly displaced and/or disrupted. The mitochondria of the myofibrils were small, few, spherical and irregularly distributed. In treated group (Fig.10d), the myofibrils had a relatively uniform size with occasional fibers showing partial degeneration. The myofibrils had a relatively similar diameter comparable to that of normal muscle, the degenerated areas were small in size and still there were vacuolations areas with loss of banding pattern (Fig. 10 & 11).

Total body weight

(Table.1) shows a statistically significant difference in weights of rats among the 4 groups after 2, 3, and 4 weeks ($p < 0.001$). So, post hoc testing with Tukey correction was done to determine the nature of the difference between the 4 groups during the experiment. A statistically significant changes in rats' weight were observed during the experiment in the 4 tested groups ($p < 0.001$). Post-hoc testing with Tukey-adjustment showed that there was a significant steady increase in mean weight over time in groups I and III starting from the weight before experiment through the 1st week to the 4th week after starting the experiment.

Impact of dexamethasone on the weight of the rats:

The dexa group showed a statistically significant reduction in the mean rats' weight compared to the control group after 2 weeks (147.8 ± 16.34 gm vs. 173.9 ± 12.63 gm, $p < 0.001$), after 3 weeks (136.9 ± 8.47 gm vs. 200.3 ± 20.7 gm, $p < 0.001$), and after 4 weeks (131 ± 12.36 gm vs. 256.7 ± 32.08 gm, $p < 0.001$).

Impact of ginseng on the weight of rats after exposure to dexamethasone:

The treated group (group IV) showed a statistically significant increase in rats' weight compared to the dexa group (group II) after 3 weeks (157.9 ± 12.42 gm vs. 136.9 ± 8.47 gm, $p < 0.001$) and 4 weeks (236.1 ± 18.59 gm vs. 131 ± 12.36 gm, $p < 0.001$).

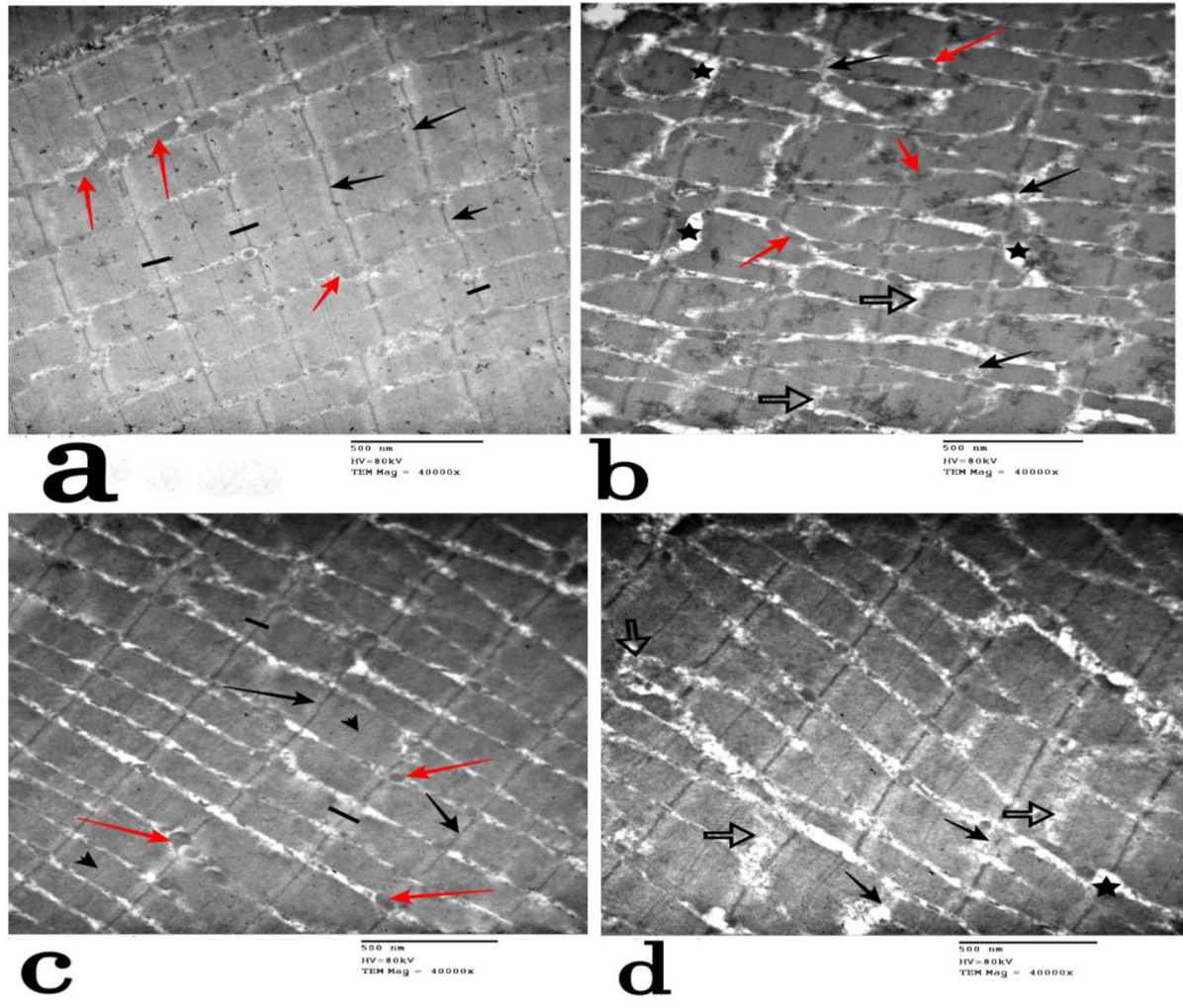


Fig.10. Transmission electron micrographs of LS of gastrocnemius muscle X40000, showing normal arrangement of myofibril with intact sarcomere, distinct normal Z line (black arrow), H band (straight line) M line (black arrow head) and normal sized and distributed mitochondria (red arrow) in both control and ginseng groups (a & c). In dexa group (b) loss of arrangement of myofibrils, degeneration of myofibrils (empty black arrow), disruption of z line (black arrow) with presence of vacuolations or spaces (star) and small sized mitochondria (red arrow) were observed. In treated group (d) nearly normal arrangement and size of myofibrils but still occasionally few degenerated myofibrils were observed. Scale bar=500nm

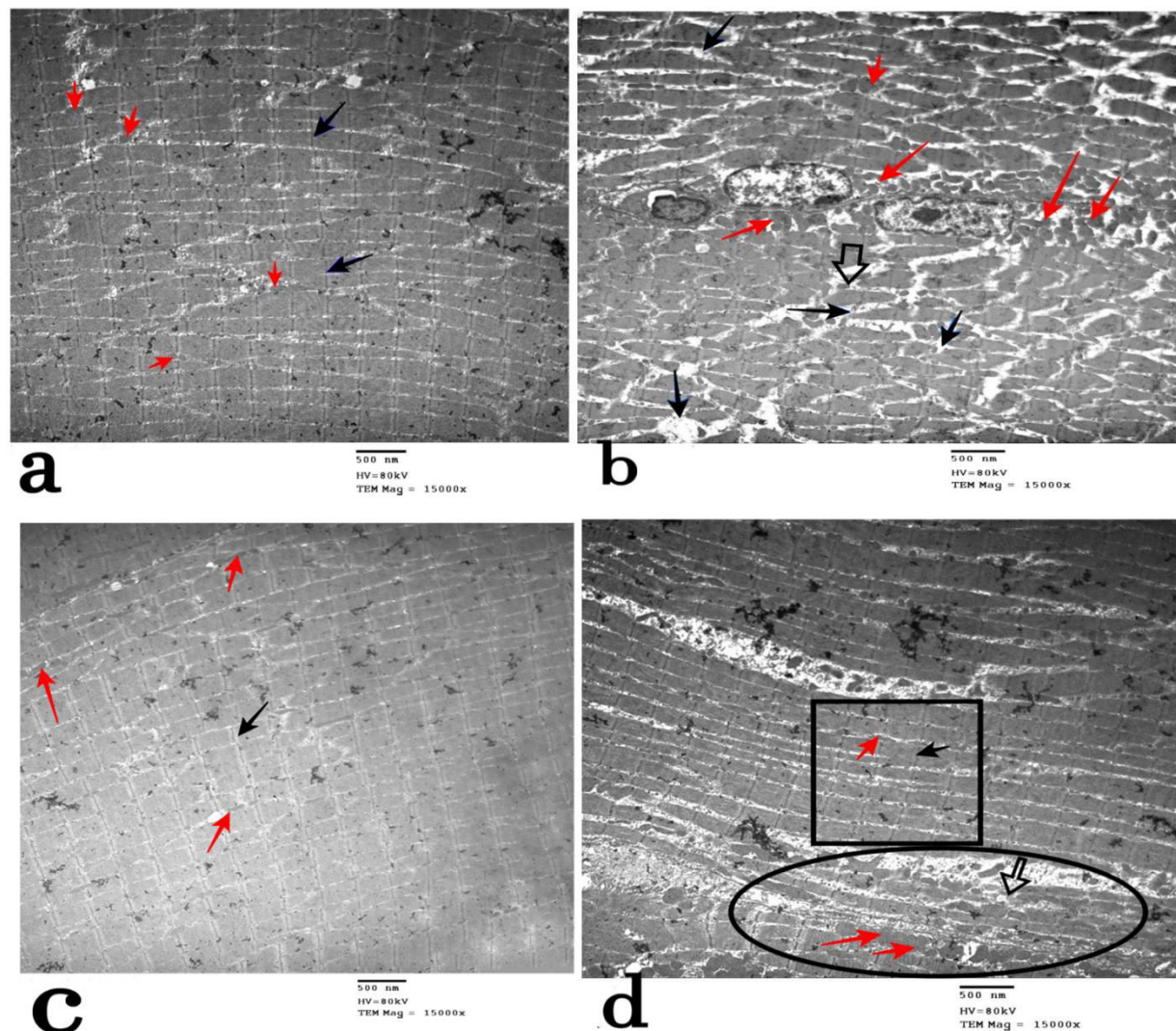


Fig.11. Transmission electron micrographs of LS of gastrocnemius muscle X 15000 showing normal arrangement of myofibril with distinct normal Z line (black arrow) and normal sized and distributed mitochondria (red arrow) in both control and ginseng groups (a & c). In dexa group (b) there was loss of arrangement of myofibrils, degeneration of myofibrils (empty black arrow), disruption of z line (black arrow) and small sized mitochondria (red arrow). In treated group (d) there was nearly normal arrangement and size of myofibrils but still degenerated myofibrils were present (empty black arrow) and disruption of Z line (black arrow). Note, there was regenerated area (square) and still there was degenerated area (oval circle) with abundant mitochondria (red arrow). Scale bar=500nm

Discussion

Many researches have been reported on proximal skeletal muscle weakening induced by glucocorticoids (Schäcke et al., 2002; Schakman et al., 2013), which are believed to have both catabolic and anti-anabolic actions, leading to the breakdown of proteins. Glucocorticoids have been shown to

produce type II muscle fiber atrophy while having little to no effect on type I muscle fibers (Schakman et al., 2008; Schakman et al., 2013). This is the main cause of using gastrocnemius muscle as the more suitable example for histopathological examination because it is classified as type II muscle fiber muscle (Augusto et al., 2017).

Treatment with dexamethasone causes a dose-dependent decrease in skeletal muscle mass and overall body weight and this was previously reported by **Ma et al., (2003)**. In the present study, histopathological examination reveals toxic effects caused by dexamethasone represented in variation in fiber size and shape was seen in the dexamethasone-treated gastrocnemius muscles. Atrophic fibers were observed occasionally. Necrotic fibers invaded by numerous macrophages were seen. A few small eosinophilic fibers with increased nuclei, indicative of atrophic change, were observed and this results were shown before by **Lee et al., (2001)**.

In the present study, Dexa group showed significant decrease in mean cross-sectional area of gastrocnemius muscle fibers compared to control group ($p < 0.001$), as previously reported by **Yamamoto et al., (2010)**. The cross sectional area of muscle fibers was improved and significantly increased in treated group compared to dexa group ($p < 0.001$), similarly, this was reported by **Jo et al., (2023)**.

In the current study, in treated group it was observed that muscle fibers were regenerated and there were improved muscle degenerative changes caused by dexamethasone. This confirms previous recent reports which recorded that Rg5 enhances muscle regeneration and can be used for therapeutic intervention of atrophy and muscle weakness (**Kim et al., 2023**). With Masson trichrome staining there was obvious collagen infiltration and deposition in dexamethasone treated group as previously reported by **Bal et al., (2009)**.

The findings in the present study showed that dexamethasone group was improved after administration of ginseng. A study done by **Seok et al., (2021)** reported that In L6 rat myoblast-derived myotubes, mountain ginseng prevents skeletal muscle atrophy by reducing E3 ubiquitin ligases

MuRF1 and atrogin1 through forkhead box O3 (FOXO3a). Furthermore, in a model of muscular atrophy produced by dexamethasone, mountain ginseng enhances the diameter of myotubes. Supplementing with mountain ginseng stops rats treated with dexamethasone from losing weight and from developing collagen in their muscles and this confirms the results of the present study. S-Rg3 therapy for 24 hours reduced the expression of cleaved caspase-3, an apoptotic marker (**Crowley and Waterhouse, 2016**), that is engaged in the activation cascade of caspases necessary for apoptosis execution in dexamethasone-induced C2C12 myotubes (**Wang et al., 2021; Wu et al., 2014**). This demonstrates the positivity of caspase 3 in dexamethasone group and decrease in this positivity after administration of ginseng.

The present study revealed the deformed pattern and organization, loss of bands, and varied size of the degeneration myofibrils, inconsistent displacement and/or disruption of the Z-lines in dexamethasone-treated rats. Also, there were tiny, spherical, and unevenly dispersed mitochondria within the myofibrils and this was previously reported by **Hussein et al., (2010)**.

It has been shown that ginsenosides Rb1, Rb2, Rd, Rg1, Rg3, and Rh2 improve muscle strength by promoting myoblast proliferation and myotube differentiation, reducing muscle breakdown, and enhancing mitochondrial biogenesis (**Dong et al., 2022**). This may explain the regeneration of myofibrils and the presence of large number of mitochondria in ginseng treated group after myopathy. The 20 (S)-ginsenoside Rg3 drives satellite cell differentiation and stimulates the production of myotubes by upregulating the expression of Myf5, MyoD, MHC, and myogenin (**Wang et al., 2020**).

Panax Total Ginseng Protein (TGP) can decrease the build-up of calcium, decreases the expression of Atrogin-1 and MuRF1, decreases protein degradation, boosts

the releases of lactate dehydrogenase (LDH), improve the viability of dexamethasone-injured myotubes, and reverses dexamethasone-induced muscle damage. Glucose transporter 4 (GLUT4) transport is regulated and GLUT4 expression is increased by activating AMPK and phosphorylating the Akt substrate AS160. It increases glucose uptake to reduce muscular atrophy induced by dexamethasone's suppression of glucose intake (**Jiang et al., 2019**).

Satellite cells (SCs) are a distinct population of stem cells normally seen in adult skeletal muscles. Quiescent SCs are triggered by muscle injury, multiply, and differentiate into mature skeletal muscle to aid in the recovery of muscle function. Adult myocytes differentiate into several phases, with SCs at the top of the hierarchy, followed by myoblasts, immature myocytes, and matured myocytes. Thus, a population of SCs that has been well-preserved is necessary to sustain the homeostasis of skeletal muscle function over an extended period of time. The satellite stem cell population needs to be preserved among the several differentiation stages since SCs are still heterogenic and lack the capacity for long-term self-renewal and differentiation. All available evidence suggest that asymmetric cell division is how SCs maintain their population (**Cheung et al., 2012; Kawabe et al., 2012; Rocheteau et al., 2012; Troy et al., 2012**). This explains the positivity of CD105 as a homing stem cell marker in dexamethasone group.

Previous study reported by **Boxall and Jones (2012)** reported that eventually these bone marrow mesenchymal stem cell (BM MSC) markers, SH2 and SH3, corresponded to CD105 and CD73 molecules, respectively (**Barry et al., 2001; Barry et al., 1999**). It should be noted that the common term for cell surface molecules is "cluster of differentiation," or "CD." The International Society of Cell Therapy (ISCT) position statement states that these two markers, along

with CD90, are positively expressed on MSCs and continue to be the principal molecules utilized to identify MSCs (**Dominici et al., 2006**). This explains the cause of using CD105 antibody as a homing stem cell marker.

The combination of G-CSF and Panax notoginseng saponins (PNS) stimulates the release of c-kit⁺ bone marrow derived mesenchymal stem cells (BMSCs) into the bloodstream, facilitating their "homing" to the sites of infarction (**Jin-Sheng et al., 2011**). Ginsenoside Rg2 (GRg2) promotes porcine mesenchymal stem cell (PMSC) proliferation, prevents D-galactose-induced oxidative stress and senescence, and increases autophagic activity through the AMPK signaling pathway. Furthermore, long-term culture with GRg2 promotes PMSC proliferation, prevents replicative senescence, and preserves stemness (**Che et al., 2023**). Previous data explained the increased positivity of CD105 in ginseng treated muscle after the occurrence of myopathy induced by dexamethasone.

In TNF- α -induced muscle atrophy, BST204 (the root of Panax ginseng) can activate the Akt/mTOR/P70S6K signaling pathways, increase protein synthesis and the expression of myosin heavy chain and myogenin, promote myoblast differentiation and myotube hypertrophy, and reduce protein degradation by inhibiting the expression of MuRF1 and Atrogin-1 (**Lee et al., 2019**).

Conclusion

The current study confirms the important curative role of panax ginseng in corticosteroid -induced myopathy through different ways like inhibition of protein degradation and through stimulation of normal stem cell.

Abbreviations

- AKT: protein kinase B
- AMPK: adenosine monophosphate-activated protein kinase
- EM: electron microscopic

- FoxO3a: forkhead transcription factor O, subtype 3a
- G-CSF: Granulocyte colony stimulating factor
- *GLUT4*: *Glucose transporter-4*
- H&E: Hematoxylin and eosin
- IHC: immunohistochemistry, immunohistochemical
- MHC/MyHC: Myosin heavy chain;
- MyoD: Myogenic differentiation;

References

- **Ahmad SS, Chun HJ, Ahmad K, Choi I. (2024).** Therapeutic applications of ginseng for skeletal muscle-related disorder management. *Journal of Ginseng Research*, 48(1): 12-19.
- **Attaix D, Ventadour S, Codran A, Béchet D, Taillandier D, Combaret L. (2005).** The ubiquitin–proteasome system and skeletal muscle wasting. *Essays in Biochemistry*, 41:173-186.
- **Attele AS, Wu JA, Yuan CS. (1999).** Ginseng pharmacology: multiple constituents and multiple actions. *Biochemical Pharmacology*, 58(11): 1685-1693.
- **Augusto V, Padovani CR, Campos GER. (2017).** Skeletal muscle fiber types in C57BL6J mice. *Journal of Morphological Sciences*, 21(2): 0-0.
- **Bal MP, de Vries WB, Steendijk P, Homoet-van der Kraak P, van der Leij FR, Baan J, et al. (2009).** Histopathological changes of the heart after neonatal dexamethasone treatment: studies in 4-, 8-, and 50-week-old rats. *Pediatric Research*, 66(1):74-79.
- **Barry F, Boynton R, Murphy M, Zaia J. (2001).** The SH-3 and SH-4 antibodies recognize distinct epitopes on CD73 from human mesenchymal stem cells. *Biochemical and Biophysical Research Communications*, 289(2):519-524.
- **Barry FP, Boynton RE, Haynesworth S, Murphy JM, Zaia J. (1999).** The monoclonal antibody SH-2, raised against human mesenchymal stem cells, recognizes an epitope on endoglin (CD105). *Biochemical and Biophysical Research Communications*, 265(1): 134-139.
- **Bodine SC, Baehr LM. (2014).** Skeletal muscle atrophy and the E3 ubiquitin ligases MuRF1 and MAFbx/atrogen-1. *American Journal of Physiology-Endocrinology and Metabolism*, 307(6): E469-E484.
- **Boxall SA, Jones E. (2012).** Markers for characterization of bone marrow multipotential stromal cells. *Stem Cells International*, 2012(1): 975871.
- **Che L, Zhu C, Huang L, Xu H, Ma X, Luo X, et al. (2023).** Ginsenoside Rg2 promotes the proliferation and stemness maintenance of porcine mesenchymal stem cells through autophagy induction. *Foods*, 12(5):1075.
- **Cheung TH, Quach NL, Charville GW, Liu L, Park L, Edalati A, et al. (2012).** Maintenance of muscle stem-cell quiescence by microRNA-489. *Nature*, 482(7386): 524-528.
- **Clarke BA, Drujan D, Willis MS, Murphy LO, Corpina RA, Burova E, et al. (2007).** The E3 Ligase MuRF1 degrades myosin heavy chain protein in dexamethasone-treated skeletal muscle. *Cell Metabolism*, 6(5): 376-385.
- **Crowley LC, Waterhouse NJ. (2016).** Detecting cleaved caspase-3 in apoptotic

- cells by flow cytometry. *Cold Spring Harbor Protocols*, 2016(11), pdb.prot087312.
- **Dominici M, Le Blanc K, Mueller I, Slaper-Cortenbach I, Marini F, Krause D, et al. (2006).** Minimal criteria for defining multipotent mesenchymal stromal cells. The International Society for Cellular Therapy position statement. *Cytotherapy*, 8(4): 315-317.
 - **Dong W, Chen W, Zou H, Shen Z, Yu D, Chen W, et al. (2022).** Ginsenoside Rb1 Prevents Oxidative Stress-Induced Apoptosis and Mitochondrial Dysfunction in Muscle Stem Cells via NF- κ B Pathway. *Oxidative Medicine and Cellular Longevity*, 2022(1):9159101.
 - **Estaki M, Noble EG. (2015).** North American ginseng protects against muscle damage and reduces neutrophil infiltration after an acute bout of downhill running in rats. *Applied Physiology, Nutrition, and Metabolism*, 40(2):116-121.
 - **Fernandez-Pernas P, Rodríguez-Lesende I, de la Fuente A, Mateos J, Fuentes I, De Toro J, et al. (2017).** CD105⁺-mesenchymal stem cells migrate into osteoarthritis joint: An animal model. *PloS one*, 12(11):e0188072.
 - **Go GY, Jo A, Seo DW, Kim WY, Kim YK, So EY, et al. (2020).** Ginsenoside Rb1 and Rb2 upregulate Akt/mTOR signaling-mediated muscular hypertrophy and myoblast differentiation. *Journal of Ginseng Research*, 44(3):435-441.
 - **Gupta A, Gupta Y. (2013).** Glucocorticoid-induced myopathy: Pathophysiology, diagnosis, and treatment. *Indian journal of Endocrinology and Metabolism*, 17(5): 913-916.
 - **Huang KH, Fang WL, Li AFY, Liang PH, Wu CW, Shyr YM, et al. (2018).** Caspase-3, a key apoptotic protein, as a prognostic marker in gastric cancer after curative surgery. *International Journal of Surgery*, 52:258-263.
 - **Huang Y, Chen K, Ren Q, Yi L, Zhu J, Zhang Q, et al. (2018).** Dihydromyricetin attenuates dexamethasone-induced muscle atrophy by improving mitochondrial function via the PGC-1 α pathway. *Cellular Physiology and Biochemistry*, 49(2):758-779.
 - **Hussein MRA, Abu-Dief EE, Kamel NF, Mostafa MG. (2010).** Steroid therapy is associated with decreased numbers of dendritic cells and fibroblasts, and increased numbers of satellite cells, in the dystrophic skeletal muscle. *Journal of Clinical Pathology*, 63(9):805-813.
 - **Jiang R, Wang M, Shi L, Zhou J, Ma R, Feng K, et al. (2019).** Panax ginseng total protein facilitates recovery from dexamethasone-induced muscle atrophy through the activation of glucose consumption in C2C12 myotubes. *BioMed Research International*, 2019(1):3719643.
 - **Jin-Sheng Z, Qing-Yong H, Tao H, Bao-Xia Z. (2011).** Effects of panax notoginseng saponins on homing of C-kit⁺ bone mesenchymal stem cells to the infarction heart in rats.[J]. *J Tradit Chin Med*, 31: 203-208.
 - **Jo SI, Park YS, Chang Y, Moon JH, Lee S, Lee H, et al. (2023).** Effects of the purified dry extract of fermented ginseng BST204 on muscle fiber regeneration. *Biochemistry and Biophysics Reports*, 35:101525.
 - **Kawabe YI, Wang YX, McKinnell IW, Bedford MT, Rudnicki MA. (2012).** *Carm1* regulates Pax7 transcriptional activity through MLL1/2 recruitment during asymmetric satellite stem cell divisions. *Cell Stem Cell*, 11(3):333-345.
 - **Kim R, Kim JW, Choi H, Oh JE, Kim TH, Go G, et al. (2023).** Ginsenoside Rg5 promotes muscle regeneration via

- p38MAPK and Akt/mTOR signaling. *Journal of Ginseng Research*, 47(6):726-734.
- **Komamura K, Shirotani-Ikejima H, Tatsumi R, Tsujita-Kuroda Y, Kitakaze M, Miyatake K, et al. (2003).** Differential gene expression in the rat skeletal and heart muscle in glucocorticoid-induced myopathy: analysis by microarray. *Cardiovascular Drugs and Therapy*, 17: 303-310.
 - **Lee EJ, Ahmad SS, Lim JH, Ahmad K, Shaikh S, Lee YS, et al. (2021).** Interaction of fibromodulin and myostatin to regulate skeletal muscle aging: an opposite regulation in muscle aging, diabetes, and intracellular lipid accumulation. *Cells*, 10(8):2083.
 - **Lee MJ, Lee JS, Lee MC. (2001).** Apoptosis of skeletal muscle on steroid-induced myopathy in rats. *Journal of Korean Medical Science*, 16(4):467.
 - **Lee SJ, Bae JH, Lee H, Lee H, Park J, Kang JS, et al. (2019).** Ginsenoside Rg3 upregulates myotube formation and mitochondrial function, thereby protecting myotube atrophy induced by tumor necrosis factor- α . *Journal of Ethnopharmacology*, 242:112054.
 - **Liu L, Koike H, Ono T, Hayashi S, Kudo F, Kaneda A, et al. (2021).** Identification of a KLF5-dependent program and drug development for skeletal muscle atrophy. *Proceedings of the National Academy of Sciences*, 118(35): e2102895118.
 - **Ma K, Mallidis C, Bhasin S, Mahabadi V, Artaza J, Gonzalez-Cadavid N, et al. (2003).** Glucocorticoid-induced skeletal muscle atrophy is associated with upregulation of myostatin gene expression. *American Journal of Physiology-Endocrinology and Metabolism*, 285(2):E363-E371.
 - **Pereira RMR, de Carvalho JF. (2011).** Glucocorticoid-induced myopathy. *Joint Bone Spine*, 78(1):41-44.
 - **Picca A, Calvani R, Bossola M, Allocca E, Menghi A, Pesce V, et al. (2018).** Update on mitochondria and muscle aging: all wrong roads lead to sarcopenia. *Biological Chemistry*, 399(5):421-436.
 - **Riaz M, Rahman NU, Zia-Ul-Haq M, Jaffar HZ, Manea R. (2019).** Ginseng: A dietary supplement as immune-modulator in various diseases. *Trends in Food Science and Technology*, 83:12-30.
 - **Rocheteau P, Gayraud-Morel B, Siegl-Cachedenier I, Blasco MA, Tajbakhsh S. (2012).** A subpopulation of adult skeletal muscle stem cells retains all template DNA strands after cell division. *Cell*, 148(1):112-125.
 - **Schäcke H, Döcke WD, Asadullah K. (2002).** Mechanisms involved in the side effects of glucocorticoids. *Pharmacology and Therapeutics*, 96(1):23-43.
 - **Schakman O, Gilson H, Thissen JP. (2008).** Mechanisms of glucocorticoid-induced myopathy. *The Journal of Endocrinology*, 197(1), 1-10.
 - **Schakman O, Kalista S, Barbé C, Loumaye A, Thissen JP. (2013).** Glucocorticoid-induced skeletal muscle atrophy. *The International Journal of Biochemistry and Cell Biology*, 45(10):2163-2172.
 - **Seok YM, Yoo JM, Nam Y, Kim, J, Kim JS, Son JH, Kim HJ. (2021).** Mountain ginseng inhibits skeletal muscle atrophy by decreasing muscle RING finger protein-1 and atrogin1 through forkhead box O3 in L6 myotubes. *Journal of Ethnopharmacology*, 270:113557.
 - **Shah OJ, Kimball SR, Jefferson LS. (2000).** Acute attenuation of translation initiation and protein synthesis by glucocorticoids in skeletal muscle. *American Journal of Physiology-*

- Endocrinology and Metabolism, 278(1):E76-E82.
- **Shi SR., Chaiwun B, Young L, Cote R, Taylo C. (1993).** Antigen retrieval technique utilizing citrate buffer or urea solution for immunohistochemical demonstration of androgen receptor in formalin-fixed paraffin sections. *Journal of Histochemistry and Cytochemistry*, 41(11): 1599-1604.
 - **Shi ZY, Zeng JZ, Wong AST. (2019).** Chemical structures and pharmacological profiles of ginseng saponins. *Molecules*, 24(13): 2443.
 - **Siti HN, Kamisah Y, Kamsiah J. (2015).** The role of oxidative stress, antioxidants and vascular inflammation in cardiovascular disease (a review). *Vascular Pharmacology*, 71:40-56.
 - **Slaoui M, Bauchet AL, Fiette L. (2017).** Tissue sampling and processing for histopathology evaluation. *Drug Safety Evaluation: Methods and Protocols*, 101-114.
 - **Tizro P, Choi C, Khanlou N. (2019).** Sample preparation for transmission electron microscopy. *Biobanking: Methods and Protocols*, 417-424.
 - **Troy A, Cadwallader AB, Fedorov Y, Tyner K, Tanaka KK, Olwin BB. (2012).** Coordination of satellite cell activation and self-renewal by Par-complex-dependent asymmetric activation of p38 α / β MAPK. *Cell Stem Cell*, 11(4): 541-553.
 - **Vaughn CJ. (2012).** Drugs and lactation database: LactMed. *Journal of Electronic Resources in Medical Libraries*, 9(4): 272-277.
 - **Wang M, Jiang R, Liu J, Xu X, Sun G, Zhao D, et al. (2021).** 20 (s)-ginsenoside-Rg3 modulation of AMPK/FoxO3 signaling to attenuate mitochondrial dysfunction in a dexamethasone-injured C2C12 myotube-based model of skeletal atrophy in vitro Corrigendum in/10.3892/mmr.2021.12259. *Molecular Medicine Reports*, 23(5):1-10.
 - **Wang M, Ren J, Chen X, Liu J, Xu X, Li X, et al. (2020).** 20 (S)-ginsenoside Rg3 promotes myoblast differentiation and protects against myotube atrophy via regulation of the Akt/mTOR/FoxO3 pathway. *Biochemical Pharmacology*, 180:114145.
 - **Wu K, Michalski A, Cortes D, Rozenberg D, Mathur S. (2022).** Glucocorticoid-induced myopathy in people with asthma: a systematic review. *Journal of Asthma*, 59(7):1396-1409.
 - **Wu Y, Yu Y, Szabo A, Han M, Huang XF. (2014).** Central inflammation and leptin resistance are attenuated by ginsenoside Rb1 treatment in obese mice fed a high-fat diet. *PloS one*, 9(3):e92618.
 - **Xu WJ, Guo K, Shi JL, Guo CT, Xu JL, Zheng R, et al. (2022).** Glucocorticoid regulates the synthesis of porcine muscle protein through m6A modified amino acid transporter SLC7A7. *International Journal of Molecular Sciences*, 23(2): 661.
 - **Yamakawa H, Kusumoto D, Hashimoto H, Yuasa S. (2020).** Stem cell aging in skeletal muscle regeneration and disease. *International Journal of Molecular Sciences*, 21(5): 1830.
 - **Yamamoto D, Maki T, Herningtyas EH, Ikeshita N, Shibahara H, Sugiyama Y, et al. (2010).** Branched-chain amino acids protect against dexamethasone-induced soleus muscle atrophy in rats. *Muscle & Nerve: Official Journal of the American Association of Electrodiagnostic Medicine*, 41(6): 819-827.
 - **Yanay N, Rabie M, Nevo Y. (2020).** Impaired Regeneration in Dystrophic Muscle—New Target for Therapy.

Frontiers in Molecular Neuroscience, 13: 69.

- **Zhou P, Xie W, Sun Y, Dai Z, Li G, Sun G, et al. (2019).** Ginsenoside Rb1 and mitochondria: a short review of the literature. *Molecular and Cellular Probes*, 43: 1-5.