

Treatment of Atrophic Post-Acne Scars

Asmaa.S.Ahmed, Essam.M.Akl and Shymaa.M.Rezk

Dermatology, Venereology and Andrology Dept., Faculty of Medicine, Benha University

E-mail: dr.asmaa.saleh.as@gmail.com

Abstract

Background: Acne scarring is one of the most chronic acne outcomes that can cause substantial psychosocial impairment. **Objectives:** This review article aims to demonstrate various treatment options for atrophic acne scarring. **Conclusions:** Atrophic post-acne scarring is a challenging problem without established guidelines for treatment so multimodal techniques can be helpful.

Keywords: Atrophic acne scarring, Platelet-rich plasma, hyaluronic acid, Microneedling, Wound healing.

Introduction

Inflammation, increased sebum production, changed microbial ecology, and aberrant keratinization are some of the variables that contribute to acne vulgaris, an inflammatory skin disorder that mostly affects teenagers [1].

Damage to the skin that occurs during the healing process of severe acne can lead to scarring. The degree to which collagen is lost or acquired determines whether a scar is atrophic or hypertrophic. Atrophic scars, caused by collagen loss, are the most common kind of acne scar, whereas hypertrophic scars and keloids are seen in a smaller percentage of cases [2].

Acne scars, especially atrophic ones, are a persistent and widespread consequence of the condition that impacts a large portion of the global population and has the potential to impair one's self-esteem, social life, and physical health. Atrophic acne scarring may be effectively treated using a range of techniques, including as micro-needling, chemical peeling, radiofrequency, dermabrasion, laser resurfacing, punch procedures, and soft-tissue augmentation [3].

We want to help dermatologists and other healthcare providers reduce the psychological and physiological implications of acne scarring by researching the numerous treatments that are available.

Microneedling, platelet-rich plasma (PRP), and non-cross-linked hyaluronic acid are some of the available therapies for acne scarring that have been examined in this extensive review research. The vulgaris acne

The pilosebaceous unit is involved in the chronic inflammatory skin disorder known as acne vulgaris. It mostly affects the face, but it may also affect the upper arms, chest, and back. The condition appears with papules, pustules, and nodules [4].

Anxiety, despair, and poor self-esteem are some of the psychological effects of acne vulgaris, one of the most prevalent skin illnesses, which impacts 85–90% of teenagers and may last into adulthood [5]. A research conducted in Egypt found that 54.2% of secondary school pupils suffer from acne vulgaris [6].

The origins of disease

Increased cutaneous sebum production, androgenic-induced sebaceous gland hyperplasia, increased keratinocyte desquamation, the presence of specific strains of *Cutibacterium acnes* (formerly known as *Propionibacterium acnes*), and infiltration of inflammatory cells are all factors in the complex and multifactorial pathogenesis of acne vulgaris [8].

Table 1

Table (1) Important pathophysiological variables in the development of acne.

Factors	Pathophysiological role
1. Role of hormones	In addition to changing the function of sebaceous glands, androgens increase sebum production and sebaceous gland development by inducing the keratinization of follicular corneocytes [9]. By increasing androgen synthesis and converting testosterone to dihydrotestosterone (DHT), insulin-like growth factor-1 (IGF-1) is an important player in the onset of acne [10].
2. Role of sebum	Reduced free fatty acids (FFAs), increased pro-inflammatory lipids, and hyperkeratinization are all results of alterations in sebum composition [11].
3. Follicular cornification and comedone formation	Follicle impaction, distention, and comedone development are caused by androgen stimulation and sebum irritants such as squalene and squalene oxide, which induce an overabundance of ductal corneocytes [12].
4. Cutibacterium acnes and inflammation	The lipase enzymes encoded by <i>Cutibacterium acnes</i> degrade sebum lipids, leading to the production of inflammatory comedogenic and chemotactic FFAs [13].

Clinical picture

Acne is a polymorphic disorder that mostly impacts the areas with a high concentration of sebaceous glands that are sensitive to hormones, such as the face, neck, chest, upper back, and upper arms [4].

Acne lesions may be either non-inflammatory or inflammatory. Comedones are non-inflammatory lesions that can take two forms: open comedones, which look like papules with a dilated follicular orifice in the center and contain keratotic material in shades of grey, brown, or black; and closed comedones, which develop when keratin and sebum block the pilosebaceous orifice under the skin, and seem like smooth, dome-shaped papules of skin-colored, white, grey, or skin-colored comedones. Nodulocystic acne is characterized by the presence of tiny red papules, pustules that may merge to become nodules, and cysts [4].

Treatment for acne

Reducing the intensity and frequency of acne lesions should be the primary targets of any treatment plan for acne vulgaris. Treatment options are based on a number of factors, including acne severity, patient age, therapeutic preferences, and response to previous treatments. [14] These suggestions have been put out by the AAD, or American Academy of Dermatology. **Figure 1**

Scars from acne

Scarring from acne is a long-term effect that may have a significant impact on a person's mental and

social health. Feelings of embarrassment, poor self-esteem, anxiety, and despair are common among acne scar sufferers, who may also worry that their looks will get in the way of their success in school, in their relationships at work, and in their chances of landing a job in the future [15].

The actual prevalence of acne scarring is likely unknown due to the paucity of epidemiologic data on the topic. Male gender, a positive family history of acne, and the severity of acne were identified as risk factors for acne scars, which impacted 47% of acne patients [16]. Scarring was higher in patients with severe inflammatory acne (3.4 to 6.8 times higher) compared to less severe acne patients [17].

Mechanism of Injury

Typically, a peri-follicular abscess will heal without scarring within 7 to 10 days after an inflammatory lesion bursts through the infra-infundibular section of the follicle. Inadequate encapsulation may lead to further rupture and fistulous tracts, but encapsulation from the epidermis and appendageal structures helps to confine the inflammatory reaction. Extensive inflammation damages subcutaneous fat and leaves behind extensive scars, in addition to damaging the hair follicle [18].

The inflammatory response and tissue damage will initiate the three-stage wound-healing process, a complicated biological mechanism:

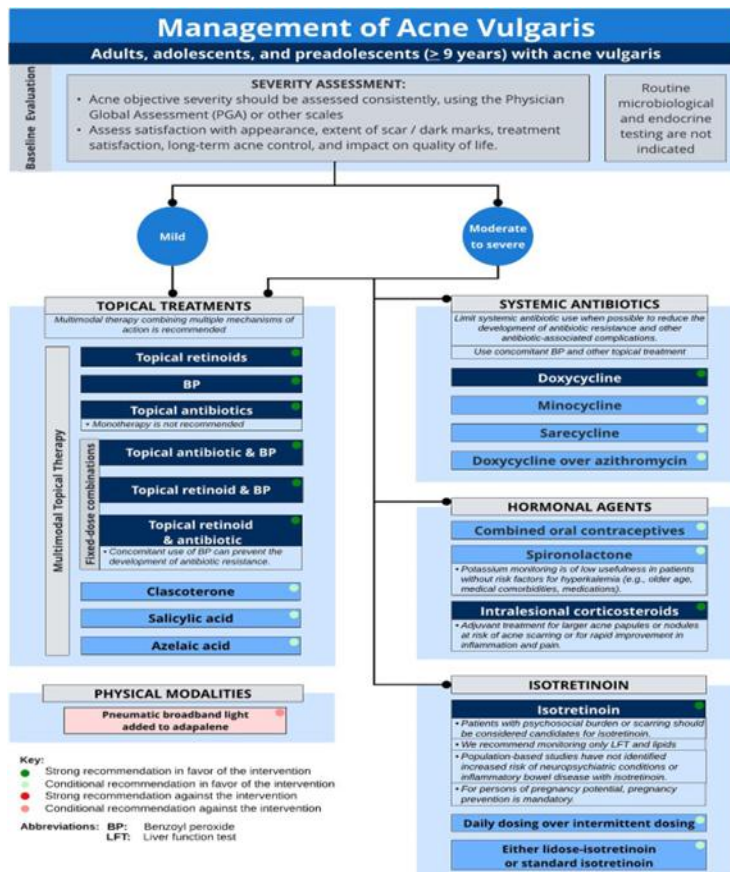


Fig.(1)Managing acne according to the AAD's guidelines [19].

1. Inflammation

Dermal When an injury occurs, a chain reaction begins that involves the activation of the coagulation cascade, the release of cytokines, the promotion of chemotaxis between neutrophils and macrophages, and the stimulation of other immune cells to prepare for the creation of granulation tissue [20].

2. The creation of granulation tissue

Within three to six weeks, the healing process progresses from inflammation to proliferation. When monocytes differentiate into macrophages, they release growth factors that encourage the migration and proliferation of fibroblasts [2].

3. Matrices remodeling

Impure scars undergo a process of maturation following wound healing that is regulated by substances such as matrix metalloproteinases (MMPs), transforming growth factor-β (TGF-β), basic fibroblast growth factor (bFGF), and epidermal growth factor (EGF), which are produced by fibroblasts and keratinocytes, respectively. Inadequate responses cause decreased collagen factor

deposition and atrophic scars, while hypertrophic scars are the consequence of too aggressive healing processes [21].

Categorization of acne scars

Scars may be characterized as either atrophic or hypertrophic depending on whether collagen is being lost or grown. While some individuals may have hypertrophic scarring or keloids, the vast majority of acne scar sufferers will develop atrophic scars [2]. Scarring from acne, especially hypertrophic scars, is unusual for acne patients generally but is more common in men with severe papular-pustular or nodular acne, especially on the back and shoulders [22]. Acne scars are often classified using a method that takes both clinical and histological factors into account. Ice pick, boxcar, and rolling scars are the three main types of atrophying acne scars that are distinguished by their breadth, depth, and three-dimensional structure. Out of all the atrophic scars, ice pick scars make up 60%–70%, boxcar scars 20%–30%, and rolling scars 15%–25% [23]. **Figure 2**

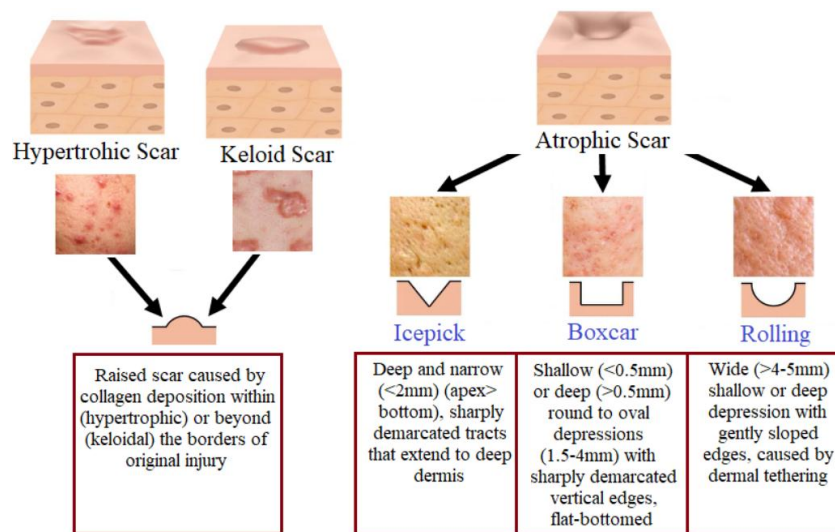






Fig.(2) Types of acne scars [24].

Grading of acne scars

Sometimes Differentiation becomes challenging when all three forms of atrophic scars manifest in a single patient. This has led to a plethora of writers proposing various scales and categories. Prior to their quantitative scale[26], Goodman and Baron created a qualitative one [25]. In order to measure acne scarring severity, Dreno et al.[27] created the ECCA scale. Based on their clinical appearance and connection to the surrounding skin, Kadunc et al. offered an additional categorization that divides acne scars into three types: elevated, dystrophic, and depressed. More than that, there are requirements for things like color, consistency, shape, and meltability

[28]. Various methods for addressing atrophic acne scars

Although there aren't any hard and fast rules for dealing with acne scars, there are a number of surgical and medicinal procedures that may considerably enhance the result. The scar's size, kind, and severity will be the primary factors in determining its treatment. Treatment for acne scars should be individualised based on the patient's age, skin type, desired outcomes, and way of life [29]. Acne scars may be better treated with a multimodal approach. It is possible to do resurfacing, lifting, excisions, and filling all at the same time or in a certain order [30]. **Figure 3**

Acne Scar Subtypes	Description		Treatment Options	Treatment Efficacy*
Icepick	<2 mm and narrow Tapers as extends to deep dermis		Punch excision	+++
			TCA CROSS	++
			Radiofrequency	+
			Laser skin resurfacing	+
Rolling	4-5 mm wide Sloped and shallow borders Caused by dermal tethering of otherwise normal skin		Subcision	+++
			Fillers	+++
			Dermabrasion	++
			Microneedling	++
			Radiofrequency	++
			Laser skin resurfacing	++
Boxcar	1.5-4 mm wide Round to oval depressions with sharply demarcated vertical edges Can be shallow (0.1-0.5 mm) or deep (>=0.5)		Shallow boxcar:	
			Punch elevation	+++
			Dermabrasion	++
			Microneedling	++
		Radiofrequency	++	
		Laser skin resurfacing	++	
			Deep boxcar:	
			Subcision	++
TCA CROSS	++			
Punch excision/ elevation	++			
Laser skin resurfacing	++			

*(+++) highly effective (++) effective (+) adequate.
CROSS, chemical reconstruction of skin scars; TCA, trichloroacetic acid.

Fig. (3) Treatment options for different types of atrophic scars [31].

- **Resurfacing:** The process of resurfacing involves peeling down the skin's layers one by one. Common methods for addressing acne scars include chemical peels, dermabrasion, micro-needling, and laser resurfacing [29].
- Facial rejuvenation procedures that use mechanical ablation to remove damaged skin and encourage re-epithelialization include dermabrasion and microdermabrasion, respectively, with dermabrasion removing the whole epidermis and microdermabrasion removing only the top layer of skin [32].
- The microneedling technique is a low-cost alternative to traditional acne scar treatments. It works by puncturing the skin, which breaks capillaries and triggers the release of growth factors and the infiltration of fibroblasts. By puncturing the basement membrane with tiny needles, keratinocytes are exposed to dermal collagen, which in turn stimulates their growth. After three or four weeks of microneedling, you should start to see an improvement in the skin's condition, and that improvement should last for months [33].
Microneedling is useful for increasing the efficacy of topical medications because it enhances drug transport to the deeper dermis and epidermis by avoiding the stratum corneum [35].
- To remove the outer layers of injured skin and hasten the healing process, a procedure known as chemical peeling is used [36]. minor to medium-depth peels, including those including TCA (20–35%), alpha hydroxy acids, salicylic acid, and

Jessener's solution, may be beneficial for minor acne lesions and shallow atrophic acne scars [2]. A technique called chemical reconstruction trichloroacetic acid (TCA) (also known as the CROSS technique) can be used to treat icepick scars. It involves using a fine wooden toothpick to apply 65 to 100% TCA to the bottom of the scars, which will cause them to turn white. The high concentrations of TCA cause coagulative necrosis of the epidermis, which in turn improves scar appearance by increasing collagen formation during wound healing [37].

- Fractional laser resurfacing, nonablative lasers, and conventional ablative lasers are the three main categories of lasers. In terms of side effects, recovery time, and effectiveness on the three distinct kinds of atrophic acne scars, these laser treatments vary widely [38].

When it comes to treating acne scars, the gold standard is ablative lasers like CO2 10,600-nm and Er: YAG 2,940-nm. They penetrate the skin's aqueous layers, damaging the dermis and epidermis while simultaneously stimulating collagen production [38].

Treatments for acne scars and face rhytides using nonablative skin remodeling systems are gaining popularity due to the decreased risk of side effects and postoperative care needed with these procedures. A safe alternative to ablative technology was developed for selective photothermolysis to the dermis, neocollagenesis, and remodeling of scarred skin using long-pulse infrared (1,450 nm diode, 1320 and 1064 nm neodymium-doped yttrium aluminum garnet

(Nd: YAG), and 1540 nm erbium glass) [39]. The advantages of both traditional ablative resurfacing and fractional laser resurfacing are combined in this procedure [40].

- A specialized needle, often 18 gauge, with the lumen or core stamped shut, is inserted percutaneously into the dermis and subcutaneous tissue during subcision to remove fibrotic scar bands. This procedure is similar to a "mini-scalpel." Neocollagenesis, which helps to elevate and smooth the surface contour, may take place underneath a tethered scar, which this approach "releases" [41].
- For severe boxcar and icepick scars, punch excision is a viable treatment option. This technique involves using a punch biopsy equipment to remove deep atrophic scar tissue up to the level of subcutaneous fat. The wound is then sutured shut. To reduce excessive traction in the skin, it is recommended to leave at least 4 to 5 mm of space between scars. Alternatively, a 4-week interval between procedures may be used to avoid these undesirable cosmetic consequences. This technique does leave a new scar, however it is usually less noticeable compared to the deep atrophic scar that was there before [42].
- Punch elevation: Whether boxcar scars are minor or deep, punch elevation will help. This technique integrates grafting with punch excision. After the scar is removed to the subcutaneous fat using a punch biopsy instrument, the tissue is pulled slightly above the skin's surface and fastened with sutures or steri-strips [42]. Results may be improved by a resurfacing treatment done 4 to 6 weeks after the punch excision or punch elevation [43].
- Transplanting fat: Due to its low cost, ease of sourcing, and lack of toxicity, fat is practically ideal as an augmentation material [44].
- Different substances that enhance the appearance of tissues: we may use fillers in two ways to cure acne scars. The first is to inject them beneath specific scars, which will make them disappear right away. Secondly, injectable volumizing fillers such calcium hydroxylapatite or poly-L lactic acid (PLLA) might be used if deep tissue atrophy or skin laxity worsen the visibility of acne scars. One theory is that injectable poly(lactic acid) (PLLA) stimulates endogenous fibroblast and, eventually, collagen synthesis [45]. PLLA is a biocompatible and biodegradable synthetic polymer.
- Hyaluronic acid: After a long list of unsuccessful tissue augmentation methods, hyaluronic acid has emerged as the preferred material [2]. Rooster combs, bacterial production, and animal or human sources are among the many possible places to get HA [46].

The structural function of the high molecular weight hyaluronic acid (HMWHA) molecule is provided by its ability to bind water at a rate of 10 to 10,000 times its weight [47]. It may fill the gap, absorb shock, and lubricate when fully hydrated because of its osmotically active properties [48].

Hydrophilic, long-chain HA with a high molecular weight is involved in wound healing. Thanks to its ability to draw water, HA has unique elastic and cushioning capabilities. It also creates a porous scaffolding network, which enables cells and proteins needed for wound healing to diffuse selectively [49].

Low molecular weight HA (LMWHA) chains, which may form during degradation of HMWHA chains, can promote inflammation. The activation of endogenous signaling pathways by these fragments causes inflammatory cytokines to be produced, as well as angiogenesis, tissue remodeling, and the activation and maturation of dendritic cells [48].

- One therapy option is platelet-rich plasma (PRP), which utilizes a patient's own concentrated platelets in plasma to speed up the healing process of wounds. The hypothesis is that the signaling proteins, growth factors, chemokines, and cytokines released by platelet-rich plasma promote cell differentiation and proliferation. There are more than 20 growth factors found in platelets, and when activated, they release signaling molecules like transforming growth factor (TGF), platelet-derived growth factor (PDGF), epidermal growth factor (EGF), vascular endothelial growth factor (VEGF), insulin-like growth factor (IGF), and interleukin-1 (IL-1). Nevertheless, further studies are required to comprehend the workings of PRP [50].

Several medical conditions, such as tendon damage, chronic ulcers, and alopecia, have made use of this concentrate because of the growth factors it contains, which promote tissue remodeling, attract macrophages, increase collagen synthesis, and encourage tissue regeneration [51]. Although research on PRP for acne scars is limited, what little there is suggests that it may be a safe therapeutic option with moderate to minor clinical improvement after intradermal or laser-assisted PRP administration [52].

- Radiofrequency: The electromagnetic radiation falls within the nonionizing spectrum and has a frequency range of 3 to 300 GHz. To promote collagen remodeling, it injures the skin and speeds up the healing process of wounds. Under the premise of "sublative rejuvenation," fractional bipolar radiofrequency (RF) causes substantial remodeling of the dermis with little damage of the epidermis. Acne scars have been

much improved with the introduction of this approach, which increases effectiveness while

Recommendations

Possible future steps in the management of acne scars include more research into combination therapies, standardized treatment protocols, possible regulation oversight, cost-effectiveness evaluations, more patient education, and personalized treatment strategies.

Conclusions

Acne As a result, treating scarring is difficult and calls an in-depth understanding of the processes involved. In various dermatological contexts, microneedling, platelet-rich plasma (PRP), and hyaluronic acid therapies are among those that have shown potential for enhancing skin texture and speeding up wound healing. Important future steps include developing more personalized strategies, innovative formulations, and studies of combination therapies. Concerns including inconsistent outcomes, cost-effectiveness, safety, and long-term result lifespan need to be resolved if these treatments are to live up to their potential.

References

- [1] Y. J. Bhat, I. Latief, and I. Hassan, "Update on etiopathogenesis and treatment of Acne.," *Indian J Dermatol Venereol Leprol*, vol. 83, no. 3, pp. 298–306, 2017.
- [2] G. Fabbrocini et al., "Acne scars: Pathogenesis, classification and treatment," 2010, Hindawi Publishing Corporation.
- [3] Y. S. Soliman, R. Horowitz, P. W. Hashim, J. K. Nia, A. S. Farberg, and G. Goldenberg, "Update on Acne Scar Treatment," 2018.
- [4] A. H. Sutaria, S. Masood, H. M. Saleh, and J. Schlessinger, *Acne Vulgaris*. 2024.
- [5] K. Bhate and H. C. Williams, "Epidemiology of acne vulgaris.," *Br J Dermatol*, vol. 168, no. 3, pp. 474–85, Mar. 2013.
- [6] E. A. El-Khateeb, N. H. Khafagy, K. M. Abd Elaziz, and A. M. Shedid, "Acne vulgaris: prevalence, beliefs, patients' attitudes, severity and impact on quality of life in Egypt.," *Public Health*, vol. 128, no. 6, pp. 576–8, Jun. 2014.
- [7] T. Vos et al., "Years lived with disability (YLDs) for 1160 sequelae of 289 diseases and injuries 1990-2010: a systematic analysis for the Global Burden of Disease Study 2010.," *Lancet*, vol. 380, no. 9859, pp. 2163–96, Dec. 2012.
- [8] D. H. Suh and H. H. Kwon, "What's new in the physiopathology of acne?," *Br J Dermatol*, vol. 172 Suppl 1, pp. 13–9, Jul. 2015.
- [9] A. Bienenfeld, S. Azarchi, K. Lo Sicco, S. Marchbein, J. Shapiro, and A. R. Nagler, "Androgens in women: Androgen-mediated skin disease and patient evaluation.," *J Am Acad Dermatol*, vol. 80, no. 6, pp. 1497–1506, Jun. 2019.
- [10] B. C. Melnik, "Linking diet to acne metabolomics, inflammation, and comedogenesis: an update.," *Clin Cosmet Invest Dermatol*, vol. 8, pp. 371–88, 2015.
- [11] P. Sánchez-Pellicer, L. Navarro-Moratalla, E. Núñez-Delegido, B. Ruzafa-Costas, J. Agüera-Santos, and V. Navarro-López, "Acne, Microbiome, and Probiotics: The Gut-Skin Axis.," *Microorganisms*, vol. 10, no. 7, Jun. 2022.
- [12] E. Makrantonaki, R. Ganceviciene, and C. Zouboulis, "An update on the role of the sebaceous gland in the pathogenesis of acne.," *Dermatoendocrinol*, vol. 3, no. 1, pp. 41–9, Jan. 2011.
- [13] M. Bek-Thomsen, H. B. Lomholt, C. Scavenius, J. J. Enghild, and H. Brüggemann, "Proteome analysis of human sebaceous follicle infundibula extracted from healthy and acne-affected skin.," *PLoS One*, vol. 9, no. 9, p. e107908, 2014.
- [14] H. Gollnick et al., "Management of acne: a report from a Global Alliance to Improve Outcomes in Acne.," *J Am Acad Dermatol*, vol. 49, no. 1 Suppl, pp. S1-37, Jul. 2003.
- [15] E. A. Tanghetti, A. K. Kawata, S. R. Daniels, K. Yeomans, C. T. Burk, and V. D. Callender, "Understanding the burden of adult female acne.," *J Clin Aesthet Dermatol*, vol. 7, no. 2, pp. 22–30, Feb. 2014.
- [16] L. Liu et al., "Prevalence and risk factors of acne scars in patients with acne vulgaris.," *Skin Res Technol*, vol. 29, no. 6, p. e13386, Jun. 2023.
- [17] J. Tan et al., "Impact of Facial Atrophic Acne Scars on Quality of Life: A Multi-country Population-Based Survey.," *Am J Clin Dermatol*, vol. 23, no. 1, pp. 115–123, Jan. 2022.
- [18] A. Tosti, M. P. De Padova, and K. R. Beer, *acne scars: classification and treatment*, First. CRC Press, 2009.
- [19] R. V. Reynolds et al., "Guidelines of care for the management of acne vulgaris.," *J Am Acad Dermatol*, vol. 90, no. 5, pp. 1006.e1-1006.e30, May 2024.
- [20] P. Martin and S. J. Leibovich, "Inflammatory cells during wound repair: the good, the bad and the ugly.," *Trends Cell Biol*, vol. 15, no. 11, pp. 599–607, Nov. 2005.
- [21] M. Chivot et al., "[Acne scars: epidemiology, physiopathology, clinical features and treatment].," *Ann Dermatol Venereol*, vol. 133, no. 10, pp. 813–24, Oct. 2006.
- [22] G. B. E. Jemec and B. Jemec, "Acne: treatment of scars.," *Clin Dermatol*, vol. 22, no. 5, pp. 434–8, 2004.
- [23] C. I. Jacob, J. S. Dover, and M. S. Kaminer, "Acne scarring: a classification system and review of treatment options.," *J Am Acad Dermatol*, vol. 45, no. 1, pp. 109–17, Jul. 2001.

- [24] M. S. Junayed, M. B. Islam, A. A. Jeny, A. Sadeghzadeh, T. Biswas, and A. F. M. S. Shah, "ScarNet: Development and Validation of a Novel Deep CNN Model for Acne Scar Classification With a New Dataset," *IEEE Access*, vol. 10, pp. 1245–1258, 2022.
- [25] G. J. Goodman and J. A. Baron, "Postacne scarring: a qualitative global scarring grading system.," *Dermatol Surg*, vol. 32, no. 12, pp. 1458–66, Dec. 2006.
- [26] G. J. Goodman and J. A. Baron, "Postacne scarring--a quantitative global scarring grading system.," *J Cosmet Dermatol*, vol. 5, no. 1, pp. 48–52, Mar. 2006.
- [27] B. Dreno et al., "ECCA grading scale: an original validated acne scar grading scale for clinical practice in dermatology.," *Dermatology*, vol. 214, no. 1, pp. 46–51, 2007.
- [28] B. V. Kadunc and A. R. Trindade de Almeida, "Surgical treatment of facial acne scars based on morphologic classification: a Brazilian experience.," *Dermatol Surg*, vol. 29, no. 12, pp. 1200–9, Dec. 2003.
- [29] W. P. Werschler, R. S. Herdener, V. E. Ross, and E. Zimmerman, "Critical Considerations on Optimizing Topical Corticosteroid Therapy.," *J Clin Aesthet Dermatol*, vol. 8, no. 8 Suppl, pp. S2-8, Aug. 2015.
- [30] D. Fife, "Practical evaluation and management of atrophic acne scars: tips for the general dermatologist.," *J Clin Aesthet Dermatol*, vol. 4, no. 8, pp. 50–7, Aug. 2011.
- [31] M. Boen and C. Jacob, "A Review and Update of Treatment Options Using the Acne Scar Classification System," *Dermatologic Surgery*, vol. 45, no. 3, pp. 411–422, Mar. 2019.
- [32] L. Alkhawam and M. Alam, "Dermabrasion and microdermabrasion.," *Facial Plast Surg*, vol. 25, no. 5, pp. 301–10, Dec. 2009.
- [33] G. Fabbrocini, N. Fardella, A. Monfrecola, I. Proietti, and D. Innocenzi, "Acne scarring treatment using skin needling.," *Clin Exp Dermatol*, vol. 34, no. 8, pp. 874–9, Dec. 2009.
- [34] H. Liebl and L. C. Kloth, "Skin cell proliferation stimulated by microneedles.," *J Am Coll Clin Wound Spec*, vol. 4, no. 1, pp. 2–6, Mar. 2012.
- [35] R. Soltani-Arabshahi, J. W. Wong, K. L. Duffy, and D. L. Powell, "Facial allergic granulomatous reaction and systemic hypersensitivity associated with microneedle therapy for skin rejuvenation.," *JAMA Dermatol*, vol. 150, no. 1, pp. 68–72, Jan. 2014.
- [36] I. Ghersetich, B. Brazzini, and T. Lotti, "Chemical peeling," in *European Handbook of Dermatological Treatments*, Berlin, Heidelberg: Springer Berlin Heidelberg, 2003, pp. 599–612.
- [37] G. Fabbrocini, S. Cacciapuoti, N. Fardella, F. Pastore, and G. Monfrecola, "CROSS technique: chemical reconstruction of skin scars method.," *Dermatol Ther*, vol. 21 Suppl 3, pp. S29-32, 2008.
- [38] J. F. Sobanko and T. S. Alster, "Management of acne scarring, part I: a comparative review of laser surgical approaches.," *Am J Clin Dermatol*, vol. 13, no. 5, pp. 319–30, Oct. 2012.
- [39] P. M. Friedman, M. H. Jih, G. R. Skover, G. S. Payonk, A. Kimyai-Asadi, and R. G. Geronemus, "Treatment of atrophic facial acne scars with the 1064-nm Q-switched Nd:YAG laser: six-month follow-up study.," *Arch Dermatol*, vol. 140, no. 11, pp. 1337–41, Nov. 2004.
- [40] M. R. Alexiades-Armenakas, J. S. Dover, and K. A. Arndt, "Fractional laser skin resurfacing.," *J Drugs Dermatol*, vol. 11, no. 11, pp. 1274–87, Nov. 2012.
- [41] D. S. Orentreich and N. Orentreich, "Subcutaneous incisionless (subcision) surgery for the correction of depressed scars and wrinkles.," *Dermatol Surg*, vol. 21, no. 6, pp. 543–9, Jun. 1995.
- [42] L. L. Levy and J. A. Zeichner, "Management of acne scarring, part II: a comparative review of non-laser-based, minimally invasive approaches.," *Am J Clin Dermatol*, vol. 13, no. 5, pp. 331–40, Oct. 2012.
- [43] G. Faghihi et al., "Efficacy of Punch Elevation Combined with Fractional Carbon Dioxide Laser Resurfacing in Facial Atrophic Acne Scarring: A Randomized Split-face Clinical Study.," *Indian J Dermatol*, vol. 60, no. 5, pp. 473–8, 2015.
- [44] G. Goodman, "Post acne scarring: a review.," *J Cosmet Laser Ther*, vol. 5, no. 2, pp. 77–95, Jun. 2003.
- [45] R. Sadove, "Injectable poly-L- lactic acid: a novel sculpting agent for the treatment of dermal fat atrophy after severe acne.," *Aesthetic Plast Surg*, vol. 33, no. 1, pp. 113–6, Jan. 2009.
- [46] B. A. McArthur, C. J. Dy, P. D. Fabricant, and A. G. Della Valle, "Long term safety, efficacy, and patient acceptability of hyaluronic acid injection in patients with painful osteoarthritis of the knee.," *Patient Prefer Adherence*, vol. 6, pp. 905–10, 2012.
- [47] B. P. Toole, "Hyaluronan in morphogenesis.," *Semin Cell Dev Biol*, vol. 12, no. 2, pp. 79–87, Apr. 2001.
- [48] P. L. Bollyky, M. Bogdani, J. B. Bollyky, R. L. Hull, and T. N. Wight, "The role of hyaluronan and the extracellular matrix in islet inflammation and immune regulation.," *Curr Diab Rep*, vol. 12, no. 5, pp. 471–80, Oct. 2012.
- [49] J. S. Frenkel, "The role of hyaluronan in wound healing.," *Int Wound J*, vol. 11, no. 2, pp. 159–63, Apr. 2014.
- [50] E. G. Freymiller, "Platelet-rich plasma: evidence to support its use.," *J Oral Maxillofac Surg*, vol. 62, no. 8, pp. 1046; author reply 1047-8, Aug. 2004.

- [51] E. Genç, S. Yüksel, A. Çağlar, O. Beytemur, and M. A. Güleç, "Comparison on effects of platelet-rich plasma versus autologous conditioned serum on Achilles tendon healing in a rat model.," *Acta Orthop Traumatol Turc*, vol. 54, no. 4, pp. 438–444, Jul. 2020.
- [52] H. I. Gawdat, R. A. Hegazy, M. M. Fawzy, and M. Fathy, "Autologous platelet rich plasma: topical versus intradermal after fractional ablative carbon dioxide laser treatment of atrophic acne scars.," *Dermatol Surg*, vol. 40, no. 2, pp. 152–61, Feb. 2014.
- [53] N. Rongsaard and P. Rummaneethorn, "Comparison of a fractional bipolar radiofrequency device and a fractional erbium-doped glass 1,550-nm device for the treatment of atrophic acne scars: a randomized split-face clinical study.," *Dermatol Surg*, vol. 40, no. 1, pp. 14–21, Jan. 2014.