

Diagnostic Significance of Aquaporin2 Expression in Primary Adrenal Gland Tumors (Immunohistochemical Study)

Sara N. Nasif, Nesma H. Mohamed, Ranih Z. Amer, Rasha M. Abd-Rabh

Abstract:

Background: Adrenal tumors affect 3–10% of world population. Aquaporin2 is water channel protein that is widely distributed among mammalian tissues and plays a major role in water homeostasis. However, little is known about the expression and significance of AQP2 in human adrenal tumors. **Aim:** To evaluate the diagnostic significance of expression of AQP2 in primary adrenal gland tumors and correlate the results with different clinico-pathological variables. **Material and Methods:** This is a retrospective, selected, controlled study carried on 44 adrenal gland lesions included (14) adrenocortical adenoma, (10) adrenocortical carcinoma and (20) pheochromocytoma. Clinicopathological characteristics of examined cases were correlated with the IHC expression of Aquaporin2. **Results:** Positive IHC expression of AQP2 was detected in 100%, 40% and 35.7% of studied cases of pheochromocytoma, ACA and ACC cases respectively. Among pheochromocytoma, 15% the cases show focal expression (+1), 40% of cases show intermediate expression (+2) and 45% of cases show diffuse expression (+3). Sensitivity and specificity of AQP2 in diagnosis of pheochromocytoma were 100% and 87.5% respectively. **Conclusion:** The results suggested that AQP2 is a diagnostic marker of pheochromocytoma and can differentiate it from adrenocortical adenoma and adrenocortical carcinoma but cannot differentiate between both adrenocortical adenoma and adrenocortical carcinoma. **Keywords:** Adrenocortical adenoma; Adrenocortical carcinoma; Pheochromocytoma; Aquaporin2.

Pathology Department, Faculty of Medicine Benha University, Egypt.

Corresponding to:
Dr. Nesma H. Mohamed.
Pathology Department, Faculty of Medicine Benha University, Egypt.
Email:
nesma.hasan21992@gmail.com

Received:
Accepted:

Introduction

The adrenal gland is a composite of two endocrine organs, one mesodermal derived (cortex) and the other neuroectodermal derived (medulla) ⁽¹⁾.

According to 2017, WHO classification of tumors of the adrenal cortex; it is classified as ACA, ACC, sex cord stromal tumors, adenomatoid tumor, mesenchymal and stromal tumors (myelolipoma and schwannoma), hematological tumors, and secondary tumors ⁽²⁾.

The tumors of adrenal medulla: it is classified as Pheochromocytoma, Extra adrenal paraganglioma, Neuroplastic tumor of the adrenal gland, Composite pheochromocytoma and Composite paraganglioma ⁽³⁾.

In Egypt, benign tumors of adrenal gland were constituting 9.01% of all suprarenal lesions and adrenocortical adenoma constitutes 40.48% of benign tumors of adrenal gland ⁽⁴⁾.

Adrenal cortical carcinoma (ACC) is a rare cancer but it is the most common primary cancer in the adrenal gland ⁽⁵⁾. The incidence of ACC is ~1 case per 1 million person-years in the general population ⁽⁶⁾. In Egypt, primary malignant suprarenal tumors represented 0.67% of all malignancy at National Cancer Institute (NCI), adrenocortical carcinoma represented 11.15% ⁽⁴⁾.

Pheochromocytomas are rare tumors, with an annual incidence of 2 to 9.1 per 1 million adults and may correspond up to 60% of all adrenal incidentalomas (epinephromas) ⁽⁷⁾. Pheochromocytoma accounts 23.8% of suprarenal gland lesion in Egypt ⁽⁴⁾.

Aquaporin2 is a typical water channel protein that plays an essential role in fluid homeostasis in normal tissues. Aquaporin2 was originally identified in the renal collecting duct cells, where it functions as the vasopressin-sensitive water channel. Its expression also has been reported in pancreatic islets, fallopian tubes, peripheral/central nerves, and gastrointestinal tissues ⁽⁸⁾.

Aquaporins not only play important roles in fluid transport in many epithelial and endothelial tissues, but they also participate in the regulation of important cellular functions, including cell proliferation, migration, apoptosis, phagocytosis and neuronal signal transduction. In neoplastic tissues, AQP subtypes were involved in invasion, migration, and proliferation of tumors in several organs, including; skin, urinary bladder, stomach, colon and kidney ⁽⁹⁾.

Little studies made on adrenal tumor in Egypt, so, we aimed in this study to assess the diagnostic role of AQP2 in adrenal tumors.

Material and Methods:

This is a retrospective, selected, controlled study carried on formalin-fixed paraffin-embedded biopsy specimens from 44 different cases of adrenal gland lesions designated as; 14 cases of adrenocortical adenoma, 10 cases of adrenocortical carcinoma, 20 cases of pheochromocytoma and Six cases of apparently normal adrenal tissue- were taken as a control. Specimens collected from National Cancer Institute (NCI) and Pathology Department at Benha faculty of Medicine, during the period from January 2011 to December 2020.

Inclusion criteria: Cases with available clinicopathological data regarding age, sex, laterality, tumor size, tumor weight, primary tumor(T), grade, lymph node status, distant metastasis and stage.

Exclusion criteria: Cases with no available paraffin blocks or clinicopathological data- were excluded from the current study.

The Ethics Committee of Faculty of Medicine, Benha University, Egypt approved this study, code (MS 26-12-2020).

The Weiss criteria were used to classify adenomas and carcinomas (Weiss score ≥ 3 indicates a diagnosis of ACC) ⁽¹⁰⁾. The grading system uses the cut-off of 20 mitoses per 10 mm² to distinguish low-

and high-grade ACC. Low-grade ACC has a mitotic activity ≤ 20 mitoses per 10 mm^2 , whereas high-grade ACC shows > 20 mitoses per 10 mm^2 ⁽¹¹⁾. The PASS score and the GAPP were used to assess metastatic potential of pheochromocytoma (PASS ≥ 4 : considered for malignancy) ⁽¹²⁾. Lymph node status was evaluated and ENSAT staging system was applied to the ACC and pheochromocytoma cases according to AJCC, 8th edition ⁽¹³⁾.

Histopathological Analysis:

Formalin fixed /Paraffin embedded blocks were cut at $5 \mu\text{m}$ thickness and stained using hematoxylin and eosin stain. Two observers reviewed the microscopic sections from all the cases.

Aquaporin2 Immunohistochemical Study:

For immunohistochemical staining, two positive slides were prepared:

1. Slides were immune-stained according to manufacturer's instructions with AQP2 rabbit polyclonal antibody (Chongqing, YPA2280, China) at a dilution of 1:50, at room temperature, overnight. Immunodetection was carried out using a standard labeled streptavidin-biotin system (Genemed, CA 94080, USA, South San Francisco). Antigen retrieval was done by using 10 mmol/L citrate monohydrate buffers (pH 6.0) and heating for 15 minutes in the microwave. The chromogen diaminobenzene (DAB, Envision TM Flex /HRP-Dako, REF K 8000) used was freshly prepared. The counter stain was Mayer's hematoxylin. Normal renal tissue used as an

external positive control ⁽¹⁴⁾. For negative control, primary antibody was replaced by Phosphate- buffered Saline.

Immunohistochemical interpretation:

Positivity for AQP2 was detected as positive cytoplasmic brownish staining without nuclear staining in tumor cells ⁽¹⁴⁾. Immunoreactivity was assessed by evaluating the extent of the stained cells, as regard for the extent of staining and percentage of positive cells was scored as: 0, negative; +1, focal (1% to 9%) positive cells; +2, intermediate (10% to 50%) positive cells; +3, diffuse (more than 50%) positive cells ⁽¹⁵⁾.

Statistical analysis:

The data were gathered, tabulated and statistically analyzed using the computer program SPSS (Statistical package for social science) version 26 (SPSS Inc., Chicago, IL, USA). P value was statistically significant when < 0.05 and highly significant when ≤ 0.001 . Receiver-operating characteristic (ROC) curve was used to estimate the sensitivity and specificity of AQP2 in diagnosis of adrenal gland tumors.

Results:

Clinicopathological results:

The age distribution of the studied cases ranged from 19 to 85 years, (Table 1).

Immunohistochemical results:

Aquaporin2 was detected as brownish cytoplasmic or membranous staining, (Figure 1).

A statistically significant relation was found between AQP2 expression and studied cases (P $= < .01$), (Table 2).

Table (1): Patients' clinicopathological data (Age, tumor size and tumor weight) in studied of ACA, ACC and pheochromocytoma cases:

Parameter	ACA	ACC	Pheo.	P.value
Age(mean \pm SD)	49.90 \pm 13.4	58.30 \pm 3.4	44.6 \pm 17.1	0.3
Tumor size (mean \pm SD)	5.10 \pm 1.9	12.70 \pm 3.3	5.1 \pm 2.4	$< 0.001^{**}$
Tumor weight (mean \pm SD)	32.8 \pm 10.1	321 \pm 140.3	242.4 \pm 409.9	0.04*

N, number; \pm SD, standard deviation; ** highly significant, * significant.

Table (2): Immunohistochemical expression of AQP2 in different adrenal tumor studied cases:

Study group	Total N (%)	Aquaporin2 expression				p-value
		0 N (%)	+1 N(%)	+2 N(%)	+3 N (%)	
Adrenocortical adenoma	14 (31.8%)	9(64.3%)	5(35.7%)	0	0	
Adrenocortical carcinoma	10(22.7%)	6(60%)	4(40%)	0	0	
Pheochromocytoma	20(45.5%)	0	3(15%)	8(40%)	9(45%)	<0.001**
Total	44 (100%)	16(35.5%)	12(26.7%)	8(17.8%)	9 (20%)	

N: Number, **: highly significant

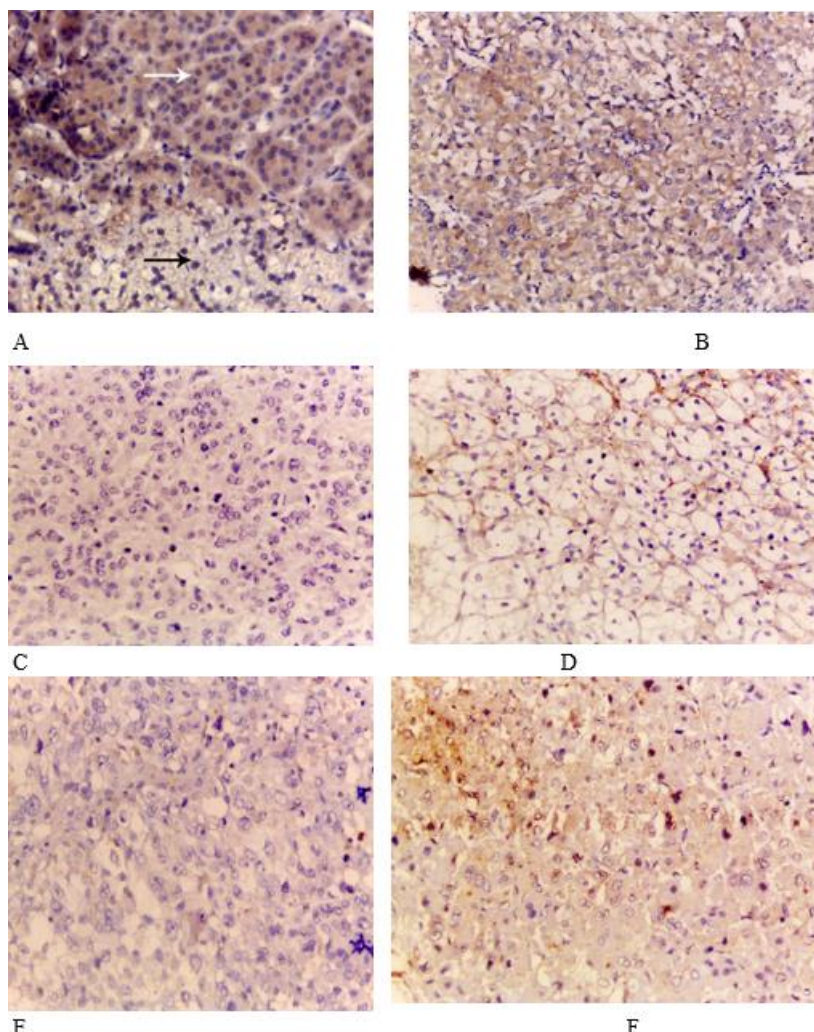


Figure (1): (A) Normal adrenal gland, cortical cells showing negative expression of AQP2(black arrow), medullary cells s showing positive diffuse cytoplasmic expression of AQP2(white arrow) (IHC, X400) (B) pheochromocytoma showing diffuse positive cytoplasmic expression of AQP2 (score+3)(IHC, X200) (C) Adrenocortical adenoma showing negative expression of AQP2 (Score0) (IHC, X400).(D) Adrenocortical adenoma showing positive focal membranous expression of AQP2 (Score1) (IHC, X400). (E) Adrenocortical carcinoma show negative expression of AQP2 (Score0) (IHC, X400) (F) Adrenocortical carcinoma showing focal positive cytoplasmic expression of AQP2 (Score1) (IHC, X400)

A statistically insignificant relation was found between AQP2 expression in both ACA and ACC(P=0.8), so, AQP2 cannot differentiate between both of them, (Table 3).

A statistically significant relation was found between AQP2 expression and primary tumor and stage of the studied adrenocortical carcinoma cases (P value <0.05) in ACC, (Table 4).

A statistically significant relation was found between AQP2 expression and tumor size (P value <0.05) in studied pheochromocytoma cases. A significant

statistically relation was found between AQP2 expression and necrosis, diffuse growth, vascular invasion and capsular invasion in studied pheochromocytoma cases (P value<0.05), (Table 5).

The diagnostic accuracy of Aquaporin2 expression for differentiating between pheochromocytoma from ACA and ACC- was determined by using ROC Curve, (Figure 2).

Sensitivity and specificity of AQP2 in differentiating pheochromocytoma from ACA and ACC were 100% and 87.5% respectively, (Table 6).

Table (3): Comparison of Aquaporin 2 expression in studied adrenocortical adenoma and carcinoma cases:

	Aquaporin2 expression				p-value
	0 No.	%	+1 No.	%	
Carcinoma	6	60.0%	4	40.0%	0.8
Adenoma	9	64.3%	5	35.7%	
Total	15	62.5%	9	37.5%	

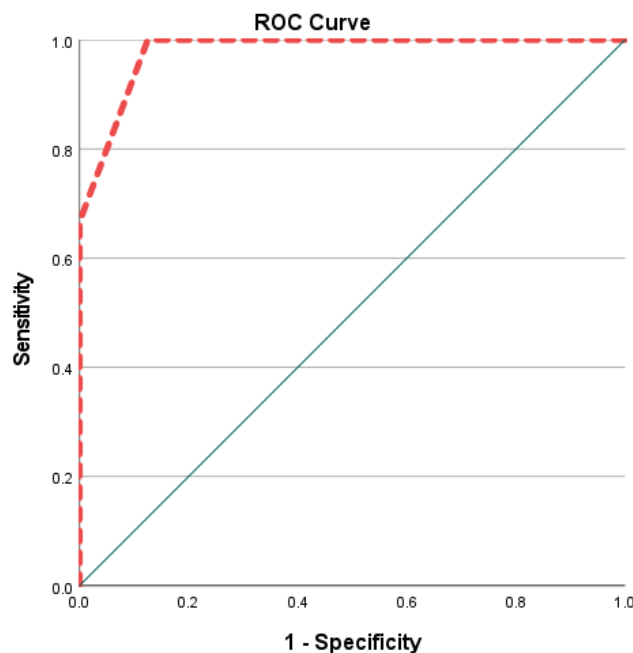


Figure (2): ROC curve for AQP2 expression as diagnostic tool for pheochromocytoma. The area under the curve represents an optimal statistic for comparing the sensitivity and specificity of AQP2 for differentiating between adrenocortical adenoma, adrenocortical carcinoma and pheochromocytoma.

Table (4): Comparison of AQP2 expression with different histopathological features in studied adrenocortical carcinoma:

		0 (n=6)		+1 (n=4)		Total		p-value
Weiss score	Low	3	75%	1	25.0%	4	40.0%	0.52
	High	3	50%	3	50.0%	6	60.0%	
T	T2	0	0%	3	100%	3	30.0%	0.036*
	T3	2	100%	0	0.0%	2	20.0%	
N	T4	4	80%	1	20.0%	5	50.0%	0.42
	N0	3	50%	3	50.0%	6	60.0%	
M	N1	3	75%	1	25.0%	4	40.0%	0.19
	M0	4	50%	4	50%	8	80.0%	
Stage	M1	2	100%	0	0.0%	2	20.0%	0.036*
	II	0	0%	3	100%	3	(30%)	
N&%	III	4	50%	1	20%	5	(50%)	0.036*
	IV	2	100%	0	0%	2	(20%)	

N, number, * significant.

Table (5): Comparison between AQP2 expression in studied pheochromocytoma cases according to tumor size and PASS score criteria:

			Aquaporin 2 expression						p-value
			1+		2+		3+		
Tumor size (cm) (mean ± SD)			4.20±1.79		4.43±2.15		6.67±1.04		0.02*
Periadrenal invasion	adipose	Present	0	0	0	0	0	0	--
		absent	3	15%	8	40%	9	45%	0.6
Mitosis 3/10HPF	more than	absent	2	13.5%	6	37.5%	8	50%	
		Present	1	25%	2	50%	1	25%	
Atypical mitosis		absent	2	11.7%	7	41.2%	8	47.1%	0.6
		Present	1	33.3%	1	33.3%	1	33.3%	
Necrosis		Absent	1	7.1%	8	57.1%	5	35.7%	0.04*
		Present	2	33.3%	0	0.0%	4	66.7%	
Cellular spindling		Absent	3	16.7%	7	38.9%	8	44.4%	0.8
		Present	0	0%	1	50%	1	50%	
Marked nuclear pleomorphism		Absent	0	0%	3	50%	3	50%	0.5
		Present	3	21.4%	5	35.7%	6	42.9%	
Cellular monotony		Absent	2	15.4%	5	38.5%	6	46.1%	0.5
		Present	1	14.2%	3	42.9%	3	42.9%	
Large nests or diffuse growth pattern		Absent	3	18.7%	4	25%	9	56.3%	0.02*
		Present	0	0%	4	100%	0	0%	
High Cellularity		Absent	3	18.7%	6	37.5%	7	43.8%	0.6
		Present	0	0%	2	50%	2	50%	
Capsular invasion		absent	1	7.1%	8	57.1%	5	35.7%	0.04*
		Present	2	33.3%	0	0.0%	4	66.7%	
Vascular invasion		absent	1	7.1%	8	57.1%	5	35.7%	0.04*
		Present	2	33.3%	0	0.0%	4	66.7%	
Hyperchromosia		Absent	2	11.7%	7	41.2%	8	47.1%	0.6
		present	1	33.3%	1	33.3%	1	33.3%	

± SD, standard deviation

*significant.

Table (6): The sensitivity, specificity, accuracy rate, positive predictive value, and negative predictive value of AQP2 in studied pheochromocytoma cases.

Area	p-value	Sensitivity	Specificity	PPV	NPV
0.979	.000	100	87.5	83.3	100

Discussion:

The management of adrenal tumors is quite challenging, mainly due to their growing frequency, diagnostic complexity, and limited availability of treatment option for adrenocortical carcinoma (ACC) ⁽¹⁵⁾.

The occurrence of adrenal incidentaloma (AI) in computed tomography series is approximately 5%. Whereas about 80% of cases are benign adenomas. More complex lesions such as adrenocortical carcinoma (ACC) or pheochromocytoma- are rarely diagnosed at a rate of about 5% each ⁽¹⁶⁾.

The most common problem encountered in the diagnosis of ACC is the differentiation pheochromocytoma from ACC. Other diagnostic pitfall includes adrenal adenomas ⁽¹⁷⁾.

Chromogranin A is the most specific marker for diagnosis of pheochromocytoma ⁽¹⁸⁾. However, chromogranin is also marker for epithelial neuroendocrine tumors (eNETs), and sometimes lead to misdiagnosis ⁽¹⁹⁾. The sensitivity of chromogranin A was only 89% of pheochromocytoma cases ⁽²⁰⁾.

Synaptophysin is also one of most common marker used in diagnosis of pheochromocytoma.

Although synaptophysin is usually positive in pheochromocytoma, diffuse positive synaptophysin staining can also be seen in adrenal cortical carcinoma which is the most significant differential diagnosis of adrenal pheochromocytoma ⁽¹⁸⁾. So, novel diagnostic biomarkers are needed to overcome this challenge .

Aquaporin2 is a member of the aquaporins (AQPs) which are a family of small membrane proteins (25~34 kDa) of 13 subtypes (AQP0–AQP12) that serve as hydrophobic and integral membrane channel proteins that facilitate rapid passive movement of water ⁽⁸⁾.

Aquaporins not only play important roles in fluid transport in many epithelial and endothelial tissues, but they also participate in the regulation of important cellular functions, including; cell proliferation, migration, apoptosis, phagocytosis and neuronal signal transduction. In neoplastic tissues, Aquaporin subtypes were involved in invasion, migration, and proliferation of tumors in several organs, including skin, urinary bladder, stomach, colon and kidney ⁽⁹⁾.

Concerning AQP2 IHC expression in this study, 64.3% and 60% of the studied cases of ACA and ACC, respectively showed negative AQP2 IHC expression. This result was close to previous study which reported that AQP2 immunohistochemistry was negative in adrenocortical adenoma and adrenocortical carcinoma ⁽¹⁴⁾.

This can be explained by AQP2 protein expressed in normal adrenal medullary cells but not in adrenal cortical cells ⁽¹⁴⁾. It has been confirmed that AQP2 is linked to vasopressin-stimulated water reabsorption in kidney ⁽²¹⁾. From this point of view, it is conceivable that AQP2 in adrenal medullary cells may play an important role in water homeostasis and other biological functions.

In this work, AQP2 showed decrease expression in both adrenocortical adenoma, adrenocortical carcinoma and cannot differentiate between both of them. This finding was in parallel with previous study which studied the expression of AQP2 in different renal cell tumors and showed that AQP2 was negative in both benign renal cell tumor (renal oncocytoma) and malignant one (chromophobe renal cell carcinoma) and cannot differentiate between both of them ⁽²²⁾.

As regards AQP2 IHC expression in this study, 35.7% and 40% of studied ACA and ACC cases, respectively showed focal positive cytoplasmic or membranous expression while 100% of pheochromocytoma showed positive AQP2 expression (15% the cases of pheochromocytoma show focal expression (+1), 40% of cases show intermediate expression (+2) and 45% of cases show diffuse expression (+3). A high significant statistical difference between cortical tumors and pheochromocytoma regarding AQP2 IHC expression ($P = <0.001$) was found.

This may be explained by the distinctive embryonic origins of the medulla (neuroectodermal) and cortex (mesodermal) of the adrenal gland. Thus, these findings also suggested that AQP2 expression may reflect the origin of adrenal gland tissues⁽¹⁴⁾.

Regarding this study, AQP2 showed focal expression in cases of adrenocortical adenoma this was in agreement with previous study which studied the expression of AQPs in benign ovarian tumors and explained this result by that AQPs family may increase the permeability of tumor epithelial cells and vessels to water and increase the transport of water⁽²³⁾.

In the current study, 40% of studied ACC cases showed focal cytoplasmic or membranous AQP2 expression. This finding agreed with previous study which reported that AQP2 expression was decreases in RCC⁽²⁴⁾. Li et al.,⁽²⁵⁾ also studied AQP2 in renal cell carcinoma and reported that AQP2 is low expressed in renal cancer. They explained this result by that increasing expression of AQP2 inhibiting EREG, EGFR and inhibiting the activation of downstream signaling pathways PI3K/AKT and RAS/ERK⁽²⁵⁾.

Regarding studied adrenocortical carcinoma cases in this study, there was inverse significant statistical relation between AQP2 expression and advanced stage. This finding was in agreement with

previous study which reported that with the promotion of RCC staging, the expression of AQP2 reduced gradually⁽²⁴⁾. Also, previous study has reported that increasing the expression of AQP2 decreasing growth and proliferation of tumor cell in RCC by cell cycle arrest in S and G2 phase and promoting apoptosis⁽²⁵⁾. This study also revealed inverse significant statistical relation between AQP2 expression in studied adrenocortical carcinoma cases with increased primary tumor (T). This finding was in agreement with who has reported that knockdown of AQP2 significantly increased RCC cell proliferation and migration by promoting cell cycle arrest in G1 phase and promoting apoptosis⁽²⁵⁾.

In the present study, there was significant statistical relation between tumor size of studied pheochromocytoma cases and IHC expression of AQP2 and tumor size (p value 0.02) as we revealed diffuse expression pattern of AQP2 were larger in diameter than those displaying focal or intermediate expression patterns. This finding was in agreement with Niu et al.,⁽¹⁴⁾ by as it is reasonable to suggest that AQP2 may be associated with the growth and/or proliferation of PCCs, and the present findings confirmed our speculation that AQP2 participates in the biological metabolism of water in the tumors⁽¹⁴⁾.

In our study, AQP2 showed significant statistical correlation with some of PASS score parameter as necrosis, diffuse growth pattern, capsular invasion and vascular invasion (P value <0.05) in studied pheochromocytoma cases. This can be explained that each type of AQP can participate as an important player during human carcinogenesis by facilitating proliferation, cellular migration with accompanying invasion, and metastasis in addition to drug resistance and potential prognostic markers in specific cancer type(s)⁽²⁶⁾. This suggests that AQP2 has an important role invasion, migration and metastasis of Pheochromocytoma and poor prognosis.

In the current study we performed sensitivity and specificity tests for AQP2 and found that the sensitivity and specificity of AQP2 in diagnosis of pheochromocytoma were 100% and 87.5% respectively. So, AQP2 is highly diagnostic for pheochromocytoma

Conclusions:

Aquaporin2 is excellent diagnostic marker for pheochromocytoma. Aquaporin2 may help to differentiate pheochromocytoma from adrenocortical adenoma, and adrenocortical carcinoma. Aquaporin2 cannot differentiate between both adrenocortical adenoma and adrenocortical carcinoma.

Conflicts of interest: No conflicts of interest.

References:

1. Auchus, R. J., Parker, K. L., and Rainey, W. E. The adrenal glands. In *Textbook of Endocrine Physiology* (Oxford University Press 2011 . pp. 346-380).
2. Giordano TJ, Chrousos GP, Kawashima A, Koch C.A Sasano H. A. and Young W.F. Adrenal cortical adenoma. In: Lloyd RV, Osamura RY, Kloppel G, RosaiJ, eds. WHO Classification of EndocrienOrgans. Lyon, France:IARC Press 2017; ,pp.169-172.
3. Tischler A. S., de Krijger R.R., Gill A., Kawashima A., Kimura N, Komminoth P., et al. Pheochromocytoma In: Lloyd RV, Osamura RY, Kloppel G, RosaiJ, eds. WHO Classification of EndocrienOrgans. Lyon, France:IARC Press 2017; ,pp.179-189.
4. Mokhtar N, Salama A, Badawy O, Khorshed E, Mohamed G, Ibrahim M, et al. Cancer pathology registry 2000-2011. Cairo, Egypt: National Cancer Institute Cairo University. Back to cited text. 2016(18).
5. Chandrasekar T, Goldberg H, Klaassen Z, Wallis CJD, Woon DTS, Herrera-Caceres JO, et al. The who, when, and why of primary adrenal malignancies: Insights into the epidemiology of a rare clinical entity. *Cancer*. 2019 Apr 1;125(7):1050-1059. doi: 101002/cncr.31916.
6. Crona, J., and Beuschlein, F. Adrenocortical carcinoma—towards genomics guided clinical care. *Nature Reviews Endocrinology* 2019, 15(9), 548-560.
7. Farrugia FA, Georgios M, Panagiotis T, Nikolaos Z, Anestis C, Dimitrios S, et al. Adrenal incidentaloma or epinephroma and review of the literature. Differential diagnosis of adrenal incidentaloma. *Khirurgiia* 2016. 82, 120–128.
8. Ranieri, Marianna, Annarita Di Mise, Grazia Tamma, and Giovanna Valenti. "Vasopressin–aquaporin-2 pathway: recent advances in understanding water balance disorders." (2019), *F1000Research* 8
9. Rubenwolf, P., Thomas, C., Denzinger, S., Hartmann, A., Burger, M., Georgopoulos, N. T., et al. Loss of AQP3 protein expression is associated with worse progression-free and cancer-specific survival in patients with muscle-invasive bladder cancer. *World journal of urology* 2015, 33, 1959-1964.
10. Lau, S. K., and Weiss, L. M. The Weiss system for evaluating adrenocortical neoplasms: 25 years later. *Human pathology* 2009, 40(6), 757-768.
11. Mete O, Erickson LA, Juhlin CC, de Krijger RR, Sasano H, Volante M, et al. Overview of the 2022 WHO Classification of Adrenal Cortical Tumors. *Endocr Pathol*. 2022 Mar;33(1):155-196. doi: 10.1007/s12022-022-09710-
12. Wachtel, H., Hutchens, T., Baraban, E., Schwartz, L. E., Montone, K., Baloch, Z., et al. Predicting metastatic potential in pheochromocytoma and paraganglioma: a comparison of PASS and GAPP scoring systems. *The Journal of Clinical Endocrinology & Metabolism* 2020, 105(12), e4661-e4670
13. Amin MB, EdgeS, Greene F, Byrd DR, Brookl and RK, Washington MK, et al. *AJCC Cancer Staging Manual*, 8th edn. American Joint Committee on Cancer 2017 (Vol. 1024)
14. Niu, D., Bai, Y., Yao, Q., Zhou, L., Huang, X., and Zhao, C. AQP2 as a diagnostic immunohistochemical marker for pheochromocytoma and/or paraganglioma. *Gland Surgery* 2020, 9(2), 200.
15. Dietrich, C. F., Correas, J. M., Dong, Y., Nolsoe, C., Westerway, S. C., and Jenssen, C. WFUMB position paper on the management incidental findings: adrenal incidentaloma. *Ultrasonography* 2020, 39(1), 11.
16. Lenders JWM, Eisenhofer G. Update on modern management of pheochromocytoma and paraganglioma.

- Endocrinol Metab (Seoul). 2017; 32(2): 152–161, doi: 10.3803/EnM.2017.32.2.152, indexed in Pubmed: 28685506.
17. Komarowska, H., Bromińska, B., Janicka-Jedyńska, M., and Ruchała, M. Adrenal incidentaloma: Nothing is ever as it seems. *The American Journal of Medicine* 2020, 133(9), 1048-1050.
 18. Duregon E, Volante M, Bollito E, Goia M, Buttigliero C, Zaggia B, et al. : Pitfalls in the diagnosis of adrenocortical tumors: a lesson from 300 consultation cases. *Hum Pathol* 2015, 46:1799–1807.
 19. Kimura, Noriko. "Dopamine β -hydroxylase: an essential and optimal immunohistochemical marker for pheochromocytoma and sympathetic paraganglioma." *Endocrine Pathology* 32.2 2021., 258-261.
 20. Gut, P., Czarnywojtek, A., Fischbach, J., Bączyk, M., Ziemnicka, K., Wrotkowska, E., et al. Chromogranin A–unspecific neuroendocrine marker. Clinical utility and potential diagnostic pitfalls. *Archives of Medical Science* 2016, 12(1), 1-9.
 21. Wilke, C., Sheriff, S., Soleimani, M., and Amlal, H. Vasopressin-independent regulation of collecting duct aquaporin-2 in food deprivation. *Kidney international* 2005, 67(1), 201-216.
 22. Molnar, A., Horvath, C. A., Czovek, P., Szanto, A., and Kovacs, G. FOXI1 immunohistochemistry differentiates benign renal oncocytoma from malignant chromophobe renal cell carcinoma. *Anticancer Research* 2019, 39(6), 2785-2790.
 23. Ma, J., Zhou, C., Yang, J., Ding, X., Zhu, Y., and Chen, X. Expression of AQP6 and AQP8 in epithelial ovarian tumor. *Journal of molecular histology* 2016, 47, 129-134.
 24. Liao, S., Huang, H., Zhang, F., Lu, D., Ye, S., Zheng, L., et al., Differential expression of epithelial sodium channels in human RCC associated with the prognosis and tumor stage: Evidence from integrate analysis. *Journal of Cancer*, 2020, 11(24), 7348.
 25. Li, M., Liu, G., Jin, X., Guo, H., Setrerrahmane, S., Xu, X., et al. Micropeptide MIAC inhibits the tumor progression by interacting with AQP2 and inhibiting EREG/EGFR signaling in renal cell carcinoma. *Molecular Cancer* 2022, 21(1), 1-15.
 26. Moon, C., and D. Moon. "Aquaporins in carcinogenesis: Water and glycerol channels as new potential drug targets." *Aquaporins in Health and Disease* (2016): 217-231.

To cite this article: Sara N. Nasif, Nesma H. Mohamed, Ranih Z. Amer, Rasha M. Abd-Rabh. Diagnostic Significance of Aquaporin2 Expression in Primary Adrenal Gland Tumors (Immunohistochemical Study). BMFJ XXX, DOI: 10.21608/bmfj.2024.237566.1903.