

## Garlic Oil ameliorates the acrylamide-induced neurotoxicity in Albino Rats via promoting Vaso-endothelial growth factor (VEGF) in brain tissue.

Hayam Hassan<sup>1</sup>, Mohamed abou-ellail<sup>1\*</sup>, Ahmed Hafez<sup>2</sup>, Obeid Shanab<sup>3</sup>

<sup>1</sup>Department of Genetics, Faculty of Agriculture and Natural Resources, Aswan University, Aswan 81528, Egypt.

<sup>2</sup>Department of Pharmacology, Faculty of Veterinary Medicine, Aswan University, Aswan 81528, Egypt.

<sup>3</sup>Department of Biochemistry, Faculty of Veterinary Medicine, South Valley University, Qena 83523.

### Abstract:

Acrylamide is an organic highly toxic compound that induces neurotoxic influences, it's extensively used in the industrial fields, especially in food products manufacturing. It is necessary to find natural compounds that can counteract their neurotoxic patterns. This study was carried out to highlight the possible neuroprotective mechanisms of garlic oil (GO) upon the biological changes induced by Acrylamide in rats. Forty rats were randomly sub-divided into four experimental groups: control, garlic oil, acrylamide, and acrylamide plus garlic oil. After recording the neurological symptoms, rats from each group were decapitated and brain tissues were excised for biochemical, molecular, and histopathological evaluation. In the Acrylamide group, rats showed ataxia and weakness followed by hind limb paralysis. On the genetic level, showing low mRNA and protein expression of the VEGF indicated acrylamide genotoxicity, affecting the brain blood supply which was confirmed histopathologically by congestion, and hemorrhage. The group of acrylamides co-treated with garlic oil, rats showed an interesting improvement in the previously mentioned clinical signs and retrieved mRNA and protein expression of the VEGF. Treatment with GO improved the biochemical and morphological features of the brain. They enhanced our hypothesis about the oral administration of GO which provides protection and healing ability upon acrylamide neurotoxicity via modulations of both antioxidant and oxidative activities.

**Keywords:** *Acrylamide, Garlic Oil, Neurotoxicity, Genotoxicity, Antioxidants.*

## 1. Introduction:

Environmental factors due to unhealthy lifestyle and industrialization have major evidence in the patterns of different pathogens. Acrylamide (ACR) is an environmental neurotoxin; it is a highly chemically active water soluble industrial materials [1]. Acrylamide mainly used in the manufacturing of cosmetics, paints and some laboratory materials [2]. Processed food is the major source for human acrylamide toxicity [3]. All tissues can be affected by ACR, but brain is the main target for ACR toxicity [4]. ACR exposure affect brain and results in neurotoxicity [5]. The ACR neurotoxicity mechanism still unclear, some studies showing that the neurotoxicity is due to low antioxidant capacity and lipid peroxidation of nerve tissue, furthermore its cytotoxic effects through ROS elevation [6]. Some studies showed that neurotropic factors such as VEGF is involved in the repair of injured peripheral nerves [7]. It was reported that ferroptosis might be used as a therapeutic strategy for treatment of acrylamide-induced nerve damage via increased the expression of VEGF and other parameters, which were down-regulated by ACR toxicity [8]. Naturally occurring antioxidant defense mechanisms have a crucial role in the amelioration of various toxic effects in the body. Some plants or its products have potent antioxidant capabilities [9–12]. Garlic (*Allium sativum*) is a plant which belongs to the genus *Allium*, widely used in cooking and also for its medicinal properties [13,14]. Garlic contains allicin which is the biologically active compound in which by its degradation can lower ROS, playing a vital role in the immune enhancement via its anti-oxidant, anti-microbial, anti-infective and anti-cancer mechanisms [15–19]. Garlic can be used as a potent therapeutic agent in diabetes, cancer and cardiovascular disease, via different mechanisms, such as its ability to induces or inhibits angiogenesis [20]. Reports have been showed that; Organo-sulfur Garlic Compounds stimulates neovascuogenesis in human EPCs and so it has a protective effect against blood vessels injuries [21]. Furthermore a study reported that; garlic possibly enhanced angiogenesis in the diabetic animal's myocardium via serum lipid modulation and the pro-angiogenic miRs expression [22]. In this study we investigated the effect of Garlic oil on blood picture, the angiogenic marker expression (VEGF) and the histopathological picture of blood vessels of brain in rats exposed to ACR.

## **2. Material and methods:**

### **2.1.Reagents:**

Acrylamide: purchased from Sigma Aldrich Company for Trading Chemicals, Medicines and Medical Appliances, Egypt. Garlic oil was obtained from the local market at Aswan Governorate.

### **2.2.Experimental animals:**

Forty adult male albino rats of 4-5 weeks old and weighting 125 gm used in the experimental investigation of this study. Rats were obtained from the Laboratory animal research center, Faculty of veterinary medicine, South Valley University. Rats housed in separate wire mesh cages and kept at constant environmental and nutritional conditions throughout the period of experiment. (Animals accommodated in appropriate normal conditions). The animals left 15 days for acclimatization before the beginning of the experiment. Animals admitted in the department of biochemistry at Faculty of Veterinary Medicine, South Valley University. Following the ethical consideration of experimental animals of South Valley no. (VM/SVU/23(2)-17).

### **2.3.Experimental design:**

The animals will be randomly divided into four groups of 10 animals each,

- 1-Group A (control group): Contained ten rats which served as control.
- 2- Group B (GO group): 10 rats' will feeds on basal ration and DW with the well-known dose of oil (50 mg/kg b.wt) diluted with corn oil via gastric tube twice a week for 28 days [23].
- 3- Group C (ACR group): 10 rats were administered ACR (25 mg/kg b.wt) daily for 28 days in drinking water according to [24].
- 4- Group D (ACR+GO group): 10 rats given at first the garlic oil with the admitted dose then after one hour given the acrylamide.

The experiment started 15 days after purchase of the rats until adaptation. At the end of experiment on 4th weeks rats of each group e scarified by cervical decapitation, brain tissue from the same rat quickly dissected out and divided into different parts. One part subjected for histopathological analysis. Another fresh tissue parts used for RNA/protein isolation and kept within -80oc.

### **2.4.Complete blood count:**

The whole blood samples were analyzed using an automatized blood analyzer (Urite, China) for red blood cell count (RBCs), hemoglobin (Hb) concentration, white blood cell count (WBC),

thrombocytes count and blood indices. The Peripheral blood films smear was examined. Differential white cell counts were performed on blood films stained with Giemsa stain.

### 2.5. Conventional-PCR:

Total RNA was extracted using QIAzol Reagent (QIAGEN®, QIAzol™) according to the manufacturer's instructions. Total RNA concentration and quality checked with a Nanodrop ND-1000 spectrophotometer. The RNA quality was estimated at the 260/280 nm absorbance ratio. The cDNA synthesized from 1 µg RNA with the RNA PCR kit with oligo(dT) primers (TaKaRa) and then used as a template for rt-PCR analysis. Band intensities quantified with the NIH Image J software the primers used for VEGF, and GADPH.

Primer for	Forward (from 5' to 3')	Reverse (from 5' to 3')
VEGF	CACTGGACCCTGGCTTTACT	GACGTCCATGAACTTCACCA
GADPH	GACATGCCGCCTGGAGAAAC	AGCCCAGGATGCCCTTTAGT

### 2.6. Western blot:

Protein fractions were isolated from the organic phase of QIAzol Reagent-treated fatty tissue samples (QIAGEN®, QIAzol™) following the manufacturer protocol, supplemented with a proteinase inhibitor cocktail (Sigma-Aldrich) and phosphatase inhibitor tablet (PhosStop, Roche). Equal amounts of protein samples loaded, separated by SDS-poly acrylamide gel electrophoresis and then blotted to a polyvinylidene difluoride membrane (PVDF, Immobilon-P, Millipore). The membranes blocked in PBS–Tween (0.1%) with 1% BSA or 5% nonfat dried milk and then probed with the primary antibodies diluted PBST-BSA or 5% nonfat dried milk. The bands were detected using Lumi-light Plus kit (Roche) and BioRAD chemidoc machine. Band intensities quantified with the NIH Image J software. All primary antibodies were used at a dilution of 1:1000.

Antibody against.	Manufacturer.	Catalog no.	Clone no.	Dilution factor.
VEGF-r1	Cell signaling	#64094	E7T9H	1/1000
VEGF-r2	Cell signaling	9698#	D5B1	1/1000
β –actin	Sigma-Aldrich	A5441	AC- 15	1/1000
Goat Anti-Rat IgG/HRP	Abcam	ab205720		1/1000

### 2.7. Histopathology analysis:

The histopathology were prepared according to [25,26]. Specimens from brain tissues fixed in 10% buffered formalin solution, then tissues suspected to different concentration of ethyl alcohol (70-

80-90-100%) and embedded in paraffin blocks, 2- $\mu$ m-thick sections were prepared. Paraffinized sections deparaffinized with xylene and rehydrated through a decreasing gradient of ethanol solutions. Slides stained with hematoxylin and eosin (H&E), cover slipped with mounting medium, and viewed under a light microscope. Slides scanned with digital scanner (MIRAX; Carl Zeiss) and then viewed with MIRAX software (Carl Zeiss).

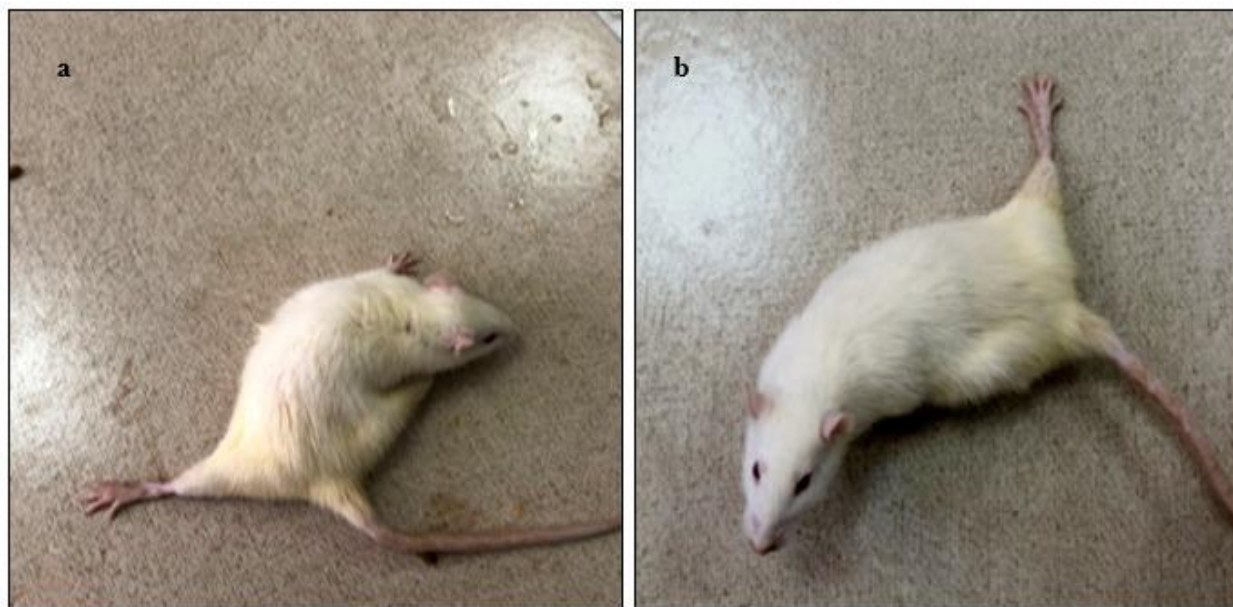
### 2.8. Statistical analysis:

We used the two-tailed Student's t-test and Mann–Whitney U-test for comparisons within each parameter, while ANOVA and Dunnett t-tests used for multiple comparisons; compare each of a number of treatments with a single control. Differences considered statistically significant when the P value was  $<0.05$ .

## 3. Results:

### 3.1. Clinical signs of ACR toxicity and the improvement via garlic oil co-treatment:

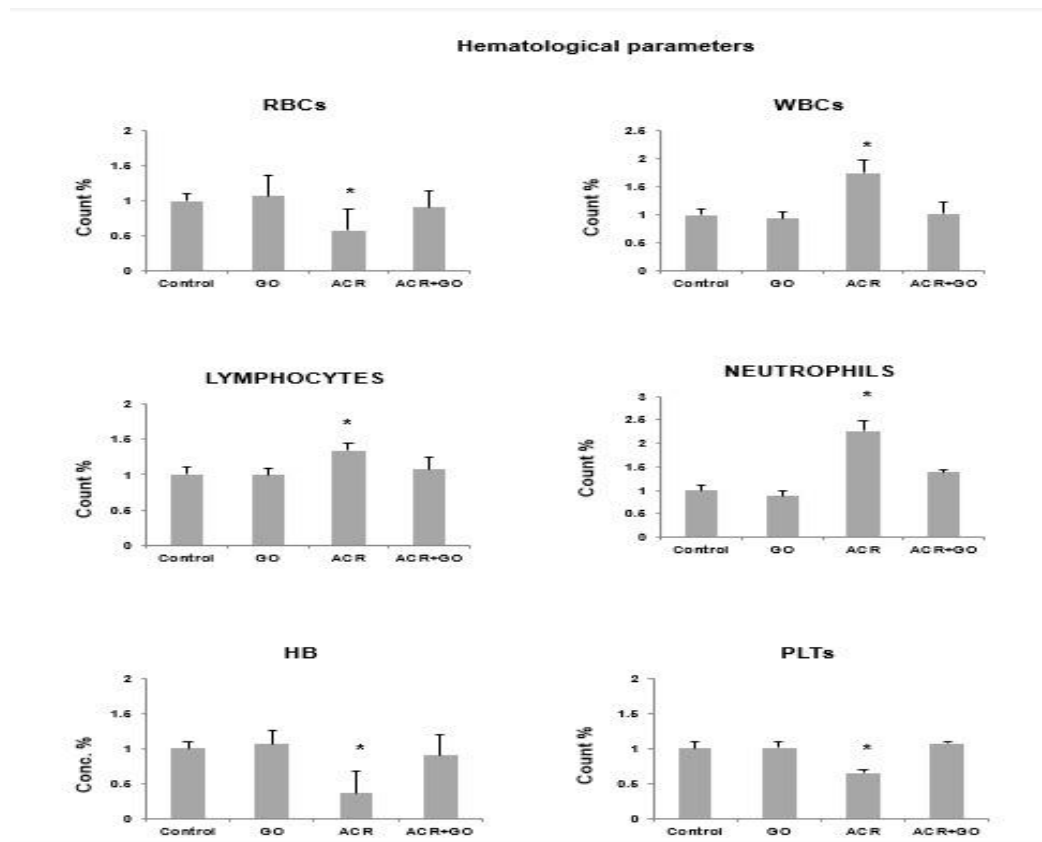
In rats intoxicated with ACR, it showed neurological abnormalities in the walking pattern including weakness and ataxia of hind limbs end with quadri-paralysis as proven in **Figure 1(a)**. In ACR + GO co-treated group: There was a significant improvement in the clinical signs along the experimental period as proven in **Figure 1(b)**.



**Figure 1.** presents the clinical signs after ACR toxicity; a) rat after 4 weeks post treatment with ACR showing weakness, ataxia, and development of Quadri-paralysis. b) Rat after 4 weeks of ACR co-treated with garlic oil showing significant improvement of the clinical signs.

### 3.2.Effect of ACR on CBC parameters and the ameliorating effect of GO in rats:

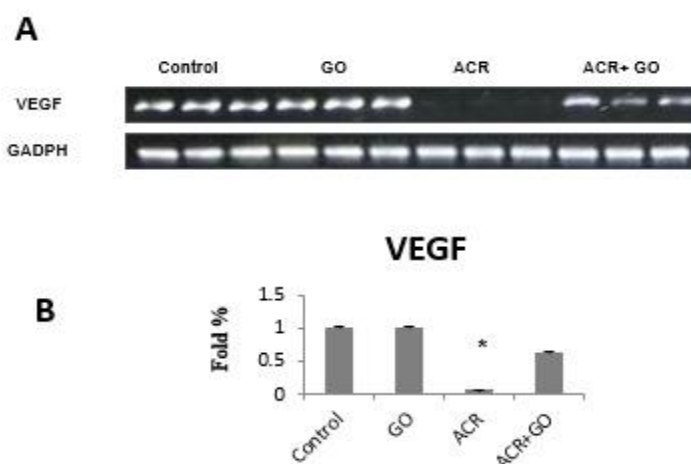
Our data revealed changes in the complete blood count; significant decrease in the number of RBCs, platelets, and hemoglobin concentration, furthermore there a significant elevation in the number of leukocytes (total WBCs, lymphocytes, and neutrophils) after exposure to ACR oral administration compared to the control group. On the other hand, ACR rats co-treated with GO showing significant amelioration enhanced by the antioxidant and protective effect of garlic oil compering with the control groups as shown in **Figure 2 (A: F)**. Mean  $\pm$  SE \*P<0.05 vs. control group.



**Figure 2. Hematological changes; RBCs (A), WBCs (B), Lymphocytes (C), Neutrophils (D), HB (E), and Platelets (F). Mean  $\pm$  SE \*P<0.05.**

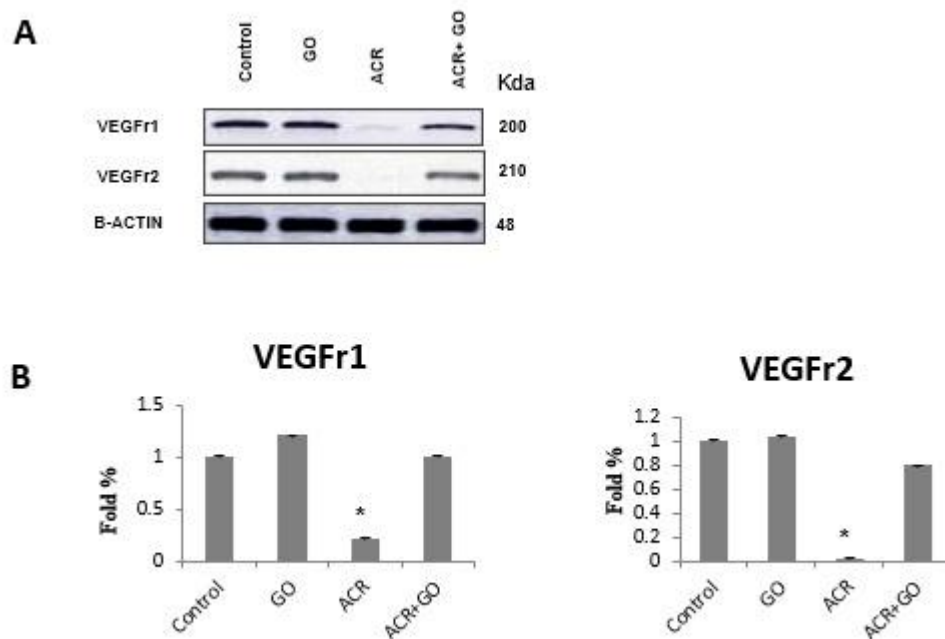
### 3.3.The mRNA expression of VEGF in brain tissue:

The mRNA expression of VEGF was detected by rt-PCR, where it is diminished significantly in ACR treated group in comparison with the control group. Interestingly after co-treatment between ACR and GO the mRNA expression of VEGF was significantly retrieved again as shown in **Figure 3 (a)**. To confirm previous result, the band intensity of the expressed VEGF was measured by using Image J software and statistically checked showing the significant increase in the expression of VEGF mRNA as showed in **Figure 3 (b)**, where the data are representative three different individuals in each group as the Mean  $\pm$  SE \*P<0.05 vs. control group.



**Figure 3.** mRNA expression of VEGF in rats brain tissue. a) The mRNA expression of VEGF in brain tissue against the level of  $\beta$ -actin measured by rt-PCR. b) The band intensity was measured by IMAGE J software, the data are representative of three different individuals from each group, Mean  $\pm$  SE \*P<0.05.

**3.4. The protein expression of VEGF receptors in brain tissue:** The protein expression of VEGF receptors (VEGF-r1 & VEGF-r2) was detected by western blotting, where it is diminished significantly in ACR treated group in comparison with the control group. Interestingly after co-treatment between ACR and GO the receptors protein expression was significantly retrieved again as shown in **Figure 4 (a)**. To confirm previous result, the band intensity of the expressed VEGF receptors was measured by using Image J software and statistically checked showing the significant increase in the expression of VEGF receptors protein as showed in **Figure 4 (b)**, where the data are representative three different



individuals in each group as the Mean  $\pm$  SE \*P<0.05 vs. control group.

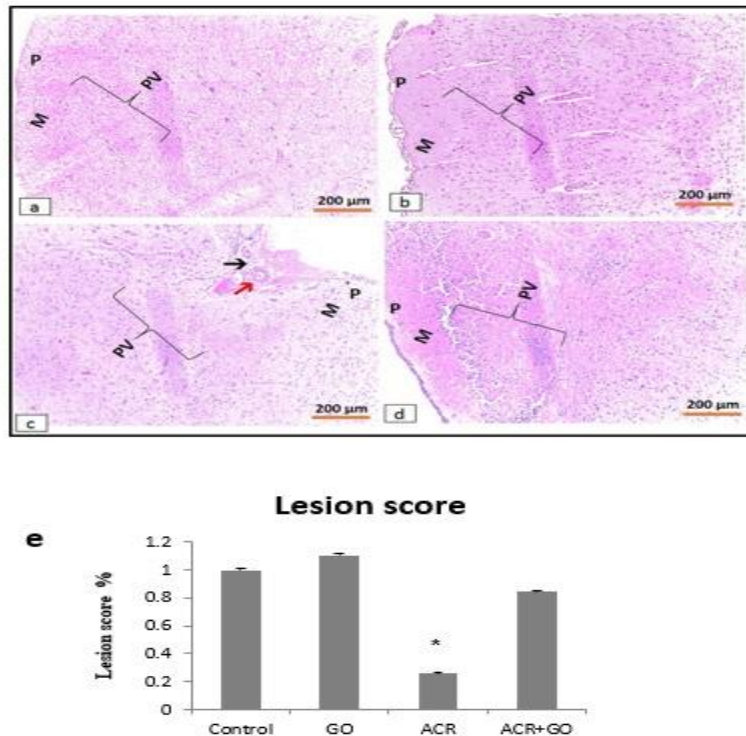
**Figure 4. Protein expression (WB) of VEGF in rats brain tissue. a) The protein expression of VEGF receptors 1 & 2 in brain tissue against the level of  $\beta$ -actin. b) The band intensity was measured by IMAGE J software, the data are representative of three different individuals from each group, Mean  $\pm$  SE \*P<0.05.**

### 3.5. Histopathological changes in the vascular tissue in the cerebrum of rats:

Histopathological sections of cerebrum stained by H&E (**Figure 5**) from control (**a**), garlic oil (**b**), acrylamide (**c**) and garlic oil +acrylamide (**d**) groups. Control and garlic oil groups showed thin piamater (P), outer molecular layer (M) and various layer of pyramidal cells (PV), where both



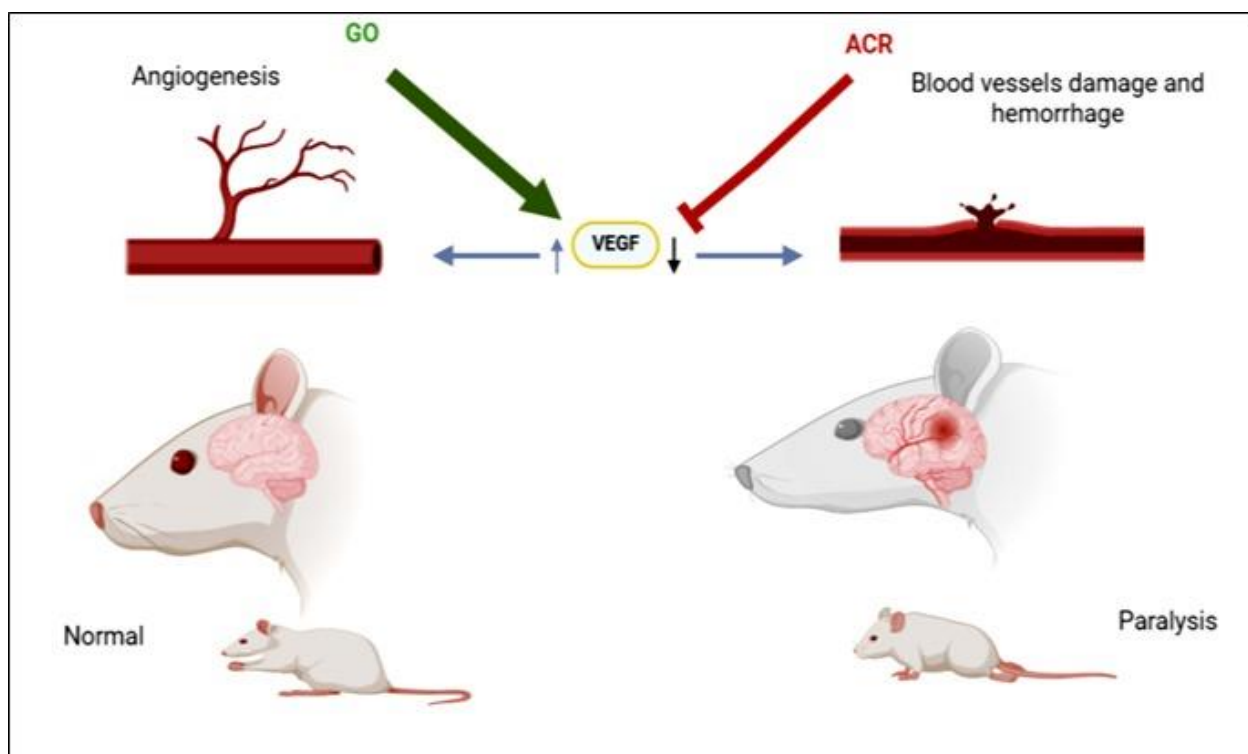
showed normal blood vessels and normal histological patterns of cerebrum. Acrylamide treated rats represented by a sever necrosis and congestion of cortical blood vessels (red arrow), interstitial hemorrhage (black arrow) with degenerated neurons. Oil and acrylamide showed mild congestion with intact endothelium in the brain blood vessels with mild degenerated neurons. (e) Total lesion scores were measured by using Image J software and statistically checked, Mean  $\pm$  SE \*P<0.05. All these data confirm the ability of garlic oil to counteract the ACR generated ROS adverse effect.



**Figure 5.** Histopathological sections of cerebrum from control (a), garlic oil (b), acrylamide (c) and garlic oil +acrylamide (d) groups. Control and oil groups showed thin pia mater (P), outer molecular layer (M) and various layers of pyramidal cells (PV). Acrylamide treated rats showed congestion of cortical blood vessels (red arrow), hemorrhages (black arrow) with degenerated neurons. Oil and acrylamide showed mild congestion and mild degenerated neurons. (e) Total lesion scores Mean  $\pm$  SE \*P<0.05.

#### Graphical abstract:

The possible mechanism of Garlic Oil on ACR generated ROS via enhancing inducible VEGF gene expression as shown in **Figure 6**.



**Figure 6.** Graphical abstract showing the possible mechanism of Garlic Oil on ACR generated ROS via enhancing inducible VEGF gene expression.

#### 4. Discussion:

The exposure to high levels of acrylamide induces neurotoxicity in brain and spinal cord in both humans and animals [27]. ROS that resulted from ACR exposure may play a crucial role in the pathogenesis induced in brain tissue. In our study, administration of ACR in drinking water with a dose of 25 mg/kg b.w, caused progressive abnormalities of hind limbs and ended with paralysis as showed in **Figure 1**. These findings are consistent with the symptoms recorded in previous studies [24,28]. The present study was designed to evaluate the chemopreventive and protective effects of garlic oil against vascular damage in the brain of rats intoxicated by acrylamide (ACR). The data in our present study after analyzing the hematological parameters showed that the levels of RBCs, hemoglobin, thrombocytes, WBCs, lymphocytes and neutrophil were significantly altered (decreased or increased according to the parameters type) in rats that were treated with 25 mg/kg acrylamide, resulting in the presence of microcytic anemia as showed in **Figure 2** in agreement with similar previous reports [29–33]. Furthermore, our data had proven that: GO supplementation had highly significant positive effects on the hematological and histopathological parameters in ACR exposed rats as shown in **Figure 1**. All these findings improved our hypothesis that GO is a

potential protective agent that can alleviate the toxic effects of ACR. As documented by previous researches which come in agreement with our study [23,34,35]. Gene expression of vascular endothelial growth factor (VEGF) including mRNA and protein expression shows significant decrease in ACR intoxicated group than control. Recent study has been demonstrated that reduced VEGF level result in neuro-degeneration in part by impairing perfusion of neural tissue, the mRNA and protein expression of VEGF was retrieved by co-treatment with garlic oil (**Figure 3 & 4**) as reported in various studies [23,28,36]. Thus, we conclude that toxicity with ACR induced ROS in brain tissue It also induced many neuro-pathological lesions. However, co-treatment with garlic oil ameliorated and prevented the oxidative damage induced by ACR neurotoxicity.

### **5. Conclusion:**

The present research study aimed to investigate the potential effects of garlic oil as a means to alleviate the detrimental neurotoxic effects of acrylamide on rats. It is noted that the inclusion of garlic oil improved brain histopathological patterns, moreover the hematological parameters. The findings of the present study indicate that the incorporation of garlic oil into acrylamide toxicity holds substantial potential for enhancing its ability of alleviation ACR adverse effects.

### **List of Abbreviations:**

GO: Garlic oil

ACR: Acrylamide.

ROS: Reactive oxygen species.

VEGF: Vasoendothelial growth factor.

### **Conflict of interest:**

The authors declare that they have no competing or conflict of interest.

**Funding and financial statement:** This work was supported financially by the Faculty of Veterinary Medicine, South Valley University, Qena 83523, Egypt.

### **Acknowledgement:**

The authors would like to Dr. Asmaa A. Metwally, Lecturer of Surgery, Anesthesiology, and Radiology, Faculty of Veterinary Medicine, Aswan University, Egypt for her helpful efforts in revising and editing the manuscript. Also, the authors would like to express our gratitude for the cell research and Molecular Physiology Research Center, department of animal physiology, Faculty of Veterinary Medicine, South Valley University, Qena 83523, Egypt for its support to accomplish

the current research. Moreover, we would like to express our thanks to Mr. Ramadan Abu Elnaga and Mr. Abu Elhassan for their technical assistance.

#### **Authors Contributions:**

Conceptualization and methodology, L.M., A. H., and H.S.; software, O.S., and A. H., validation, O.S. and H.S.; formal analysis, O.S.; resources, O.S; data curation, O.S., writing original draft preparation, all authors; writing review and editing.

#### **6. References:**

- [1] J.H. Exon, A review of the toxicology of acrylamide, *J. Toxicol. Environ. Heal. Part B.* 9 (2006) 397–412.
- [2] B.P. Riboldi, Á.M. Vinhas, J.D. Moreira, Risks of dietary acrylamide exposure: A systematic review, *Food Chem.* 157 (2014) 310–322.
- [3] E. Zamani, M. Shokrzadeh, M. Modanloo, F. Shaki, In vitro study towards role of acrylamide-induced genotoxicity in human lymphocytes and the protective effect of L-carnitine, *Brazilian Arch. Biol. Technol.* 61 (2018) e18160685.
- [4] Q. Sheng, H.-C. Zou, Z.-R. Lü, F. Zou, Y.-D. Park, Y.-B. Yan, S.-J. Yao, Effects of acrylamide on the activity and structure of human brain creatine kinase, *Int. J. Mol. Sci.* 10 (2009) 4210–4222.
- [5] R. Menéndez, T. García, A. Garateix, R.A. Morales, E.L. Regalado, A. Laguna, O. Valdés, M.D. Fernández, Neuroprotective and antioxidant effects of *Thalassia testudinum* extract BM-21, against acrylamide-induced neurotoxicity in mice, *J. Pharm. Pharmacogn. Res.* 2 (2014) 53–62.
- [6] S.N. Prasad, Mitigation of acrylamide-induced behavioral deficits, oxidative impairments and neurotoxicity by oral supplements of geraniol (a monoterpene) in a rat model, *Chem. Biol. Interact.* 223 (2014) 27–37.
- [7] J. Xiao, A.W. Wong, M.M. Willingham, S.K. Kaasinen, I.A. Hendry, J. Howitt, U. Putz, G.L. Barrett, T.J. Kilpatrick, S.S. Murray, BDNF exerts contrasting effects on peripheral myelination of NGF-dependent and BDNF-dependent DRG neurons, *J. Neurosci.* 29 (2009) 4016–4022.
- [8] S. An, J. Shi, Z. Li, M. Feng, G. Cao, The effects of acrylamide-mediated dorsal root ganglion neurons injury on ferroptosis, *Hum. Exp. Toxicol.* 41 (2022) 09603271221129786.
- [9] N. Ahmed, S.M. El-Rayes, W.F. Khalil, A. Abdeen, A. Abdelkader, M. Youssef, Z.M. Maher,

- A.N. Ibrahim, S.M. Abdelrahman, S.F. Ibrahim, Arabic gum could alleviate the aflatoxin B1-provoked hepatic injury in rat: the involvement of oxidative stress, inflammatory, and apoptotic pathways, *Toxins (Basel)*. 14 (2022) 605.
- [10] O. Shanab, L. Mostafa, A. Abdeen, R. Atia, A.Y. Nassar, M. Youssef, S.F. Ibrahim, Z.M. Maher, F. Imbrea, L. Fericean, Modulatory mechanisms of copperII-albumin complex toward N-nitrosodiethylamine-induced neurotoxicity in mice via regulating oxidative damage, inflammatory, and apoptotic signaling pathways, *Ecotoxicol. Environ. Saf.* 270 (2024) 115841.
- [11] O. Shanab, S.M. El-Rayes, W.F. Khalil, N. Ahmed, A. Abdelkader, N.H. Aborayah, A.M. Atwa, F.I. Mohammed, H.E. Nasr, S.F. Ibrahim, Nephroprotective effects of Acacia Senegal against aflatoxicosis via targeting inflammatory and apoptotic signaling pathways, *Ecotoxicol. Environ. Saf.* 262 (2023) 115194.
- [12] L. Taha, Z.M. Maher, A.Y. Nassar, M.S. Abdallah, H. Embark, M. Youssef, A. Abdeen, R.F. Moftah, H. Madhyastha, O. Shanab, Molecular mechanism of Copper Albumin Complex on NDEA induced brain vascular damage via promoting VEGF expression., *SVU-International J. Vet. Sci.* 5 (2022) 68–76.
- [13] O. Cakmakci, S. Sensoy, A.R. Alan, Bioactive constituents of *Allium vineale* L. accessions from Eastern Turkey, *Sci. Hortic. (Amsterdam)*. 303 (2022) 111203.
- [14] M.M.U. Khan, H. Khalilullah, E.E.M. Eid, F. Azam, M.A. Khan, A. Khan, N.A. Siddiqui, T. Mahmood, F. Ahsan, W.U. Khan, A dig deep to scout the pharmacological and clinical facet of garlic (*Allium sativum*), *Curr. Tradit. Med.* 8 (2022) 1–19.
- [15] H. Amagase, Clarifying the real bioactive constituents of garlic, *J. Nutr.* 136 (2006) 716S-725S.
- [16] A.L. Colín-González, R.A. Santana, C.A. Silva-Islas, M.E. Chánez-Cárdenas, A. Santamaría, P.D. Maldonado, The antioxidant mechanisms underlying the aged garlic extract- and S-allylcysteine-induced protection, *Oxid. Med. Cell. Longev.* 2012 (2012). <https://doi.org/10.1155/2012/907162>.
- [17] G. Goncagul, E. Ayaz, Antimicrobial effect of garlic (*Allium sativum*), *Recent Pat. Antiinfect. Drug Discov.* 5 (2010) 91–93.
- [18] E.A. Odongo, P.C. Mutai, B.K. Amugune, N.N. Mungai, A systematic review of medicinal plants of Kenya used in the management of bacterial infections, *Evidence-Based Complement. Altern. Med.* 2022 (2022).

- [19] A. Tsubura, Y.-C. Lai, M. Kuwata, N. Uehara, K. Yoshizawa, Anticancer effects of garlic and garlic-derived compounds for breast cancer control, *Anti-Cancer Agents Med. Chem. (Formerly Curr. Med. Chem. Agents)*. 11 (2011) 249–253.
- [20] R. Naderi, G. Mohaddes, M. Mohammadi, A. Alihemmati, R. Badalzadeh, R. Ghaznavi, R. Ghyasi, S. Mohammadi, Preventive effects of garlic (*Allium sativum*) on oxidative stress and histopathology of cardiac tissue in streptozotocin-induced diabetic rats, *Acta Physiol. Hung.* 102 (2015) 380–390.
- [21] E.-P.I. Chiang, S.-C. Chiu, M.-H. Pai, Y.-C. Wang, F.-Y. Wang, Y.-H. Kuo, F.-Y. Tang, Organosulfur garlic compounds induce neovasculogenesis in human endothelial progenitor cells through a modulation of MicroRNA 221 and the PI3-K/Akt signaling pathways, *J. Agric. Food Chem.* 61 (2013) 4839–4849.
- [22] R. Naderi, G. Mohaddes, M. Mohammadi, A. Alihemmati, A. Khamaneh, R. Ghyasi, R. Ghaznavi, The effect of garlic and voluntary exercise on cardiac angiogenesis in diabetes: the role of MiR-126 and MiR-210, *Arq. Bras. Cardiol.* 112 (2018) 154–162.
- [23] K.A. Basma, Tarek M. Amin; Manal, M. Sayed; Hossam, El-Din M. Omar; Allam, A. Nafady and Sary, Protective Effect of Garlic Oil against Acryl amide Induced Neurotoxicity in Albino Rats, *Anim. Heal. Res. J.* 4 (2016) 284–303.
- [24] E.J. Lehning, C.D. Balaban, J.F. Ross, M.A. Reid, R.M. LoPachin, Acrylamide neuropathy: I. Spatiotemporal characteristics of nerve cell damage in rat cerebellum, *Neurotoxicology.* 23 (2002) 397–414.
- [25] A.A. Metwally, A.-N.A.A. Abdel-Hady, M.A.M. Haridy, K. Ebnalwaled, A.A. Saied, A.S. Soliman, Wound healing properties of green (using *Lawsonia inermis* leaf extract) and chemically synthesized ZnO nanoparticles in albino rats, *Environ. Sci. Pollut. Res.* 29 (2022) 23975–23987.
- [26] A.A. Metwally, A.S. Soliman, A.-N.A.A. Abdel-Hady, K. Ebnalwaled, D. Mohamedien, A.A. Abdelhameed, A.A. Saied, In Vivo Wound-Healing Effect of Chemical and Green Synthesized Chitosan Nanoparticles Using *Lawsonia inermis* Ethanolic Extract, *Microsc. Microanal.* (2023) ozad026.
- [27] L. Hagmar, M. Törnqvist, C. Nordander, I. Rosén, M. Bruze, A. Kautiainen, A.-L. Magnusson, B. Malmberg, P. Aprea, F. Granath, Health effects of occupational exposure to acrylamide using hemoglobin adducts as biomarkers of internal dose, *Scand. J. Work. Environ. Health.* (2001) 219–226.

- [28] J. Shi, Y. Ma, M. Zheng, Z. Ruan, J. Liu, S. Tian, D. Zhang, X. He, G. Li, Effect of sub-acute exposure to acrylamide on GABAergic neurons and astrocytes in weaning rat cerebellum, *Toxicol. Ind. Health*. 28 (2012) 10–20.
- [29] A. Belhadj Benziane, A. Dilmi Bouras, A. Mezaini, A. Belhadri, M. Benali, Effect of oral exposure to acrylamide on biochemical and hematologic parameters in Wistar rats, *Drug Chem. Toxicol.* 42 (2019) 157–166.
- [30] I. Ghorbel, A. Elwej, M. Chaabene, O. Boudawara, R. Marrakchi, K. Jamoussi, T.S. Boudawara, N. Zeghal, Effects of acrylamide graded doses on metallothioneins I and II induction and DNA fragmentation: Biochemical and histomorphological changes in the liver of adult rats, *Toxicol. Ind. Health*. 33 (2017) 611–622.
- [31] J. Raju, A. Kocmarek, J. Roberts, M. Taylor, D. Patry, E. Chomyshyn, D. Caldwell, G. Cooke, R. Mehta, Lack of adverse health effects following 30-weeks of dietary exposure to acrylamide at low doses in male F344 rats, *Toxicol. Reports*. 3 (2016) 673–678.
- [32] J. Raju, J. Roberts, M. Taylor, D. Patry, E. Chomyshyn, D. Caldwell, G. Cooke, R. Mehta, Toxicological effects of short-term dietary acrylamide exposure in male F344 rats, *Environ. Toxicol. Pharmacol.* 39 (2015) 85–92.
- [33] E. Rivadeneyra-Domínguez, Y. Becerra-Contreras, A. Vázquez-Luna, R. Díaz-Sobac, J.F. Rodríguez-Landa, Alterations of blood chemistry, hepatic and renal function, and blood cytometry in acrylamide-treated rats, *Toxicol. Reports*. 5 (2018) 1124–1128.
- [34] I.O. Fiedan, E.A. Ahmed, H. Omar, Acrylamide induced testicular toxicity in rats: protective effect of garlic oil, *Biomarkers*. 1 (2015) 5.
- [35] T.T. Mohammed, A. Mohamed, A.A. Shaaban, A. Atwa, The possible protective roles of garlic oil and rosemary extract against neuro and geno/toxicities of acrylamide on adult male albino rats, *Zagazig J. Forensic Med. Toxicol.* 18 (2020) 68–91.
- [36] D.Y. Yoo, W. Kim, S.M. Nam, M. Yoo, S. Lee, Y.S. Yoon, M.-H. Won, I.K. Hwang, J.H. Choi, Neuroprotective effects of Z-ajoene, an organosulfur compound derived from oil-macerated garlic, in the gerbil hippocampal CA1 region after transient forebrain ischemia, *Food Chem. Toxicol.* 72 (2014) 1–7.

### **Figure Legends:**

**Figure1.** presents the clinical signs after ACR toxicity; a) rat after 4 weeks post treatment with ACR showing weakness, ataxia, and development of Quadri-paralysis. b) Rat after 4 weeks of ACR co-treated with garlic oil showing significant improvement of the clinical signs.

**Figure 2.** Hematological changes; RBCs (A), WBCs (B), Lymphocytes (C), Neutrophils (D), HB (E), and Platelets (F). Mean  $\pm$  SE \*P<0.05.

**Figure 3.** mRNA expression of VEGF in rats brain tissue. a) The mRNA expression of VEGF in brain tissue against the level of  $\beta$ -actin measured by rt-PCR. b) The band intensity was measured by IMAGE J software, the data are representative of three different individuals from each group, Mean  $\pm$  SE \*P<0.05.

**Figure 4.** Protein expression (WB) of VEGF in rats brain tissue. a) The protein expression of VEGF receptors 1 &2 in brain tissue against the level of  $\beta$ -actin. b) The band intensity was measured by IMAGE J software, the data are representative of three different individuals from each group, Mean  $\pm$  SE \*P<0.05.

**Figure 5.** Histopathological sections of cerebrum from control (a), garlic oil (b), acrylamide (c) and garlic oil +acrylamide (d) groups. Control and oil groups showed thin piamater (P), outer molecular layer (M) and various layers of pyramidal cells (PV). Acrylamide treated rats showed congestion of cortical blood vessels (red arrow), hemorrhages (black arrow) with degenerated neurons. Oil and acrylamide showed mild congestion and mild degenerated neurons. (e) Total lesion scores Mean  $\pm$  SE \*P<0.05.

**Figure 6.** Graphical abstract showing the possible mechanism of Garlic Oil on ACR generated ROS via enhancing inducible VEGF gene expression.