

Ovary Development in *Polypterus senegalus*

Mostafa A. Mousa*, Rania O. Barakat

Aquaculture Division, National Institute of Oceanography and Fisheries (NIOF), Cairo, Egypt

*Corresponding Author: mostafa_mousa2002@yahoo.com

ARTICLE INFO

Article History:

Received: Oct. 31, 2024

Accepted: Nov. 12, 2024

Online: Nov. 17, 2024

Keywords:

Histology,
Histochemistry,
Oogenesis,
Vitellogenesis,
Polypterus senegalus
(Polypteridae)

ABSTRACT

Oogenesis, the mode of developing an egg, is identified by a series of modifications to the main components of the germ cells in fish female. The previtellogenic stages and the vitellogenic or trophic phases that end with ripe or mature oocytes have been the two primary categories of these variations. The ovaries of *Polypterus senegalus* were clearly recognized as a paired elongated structures joined by a thin sheath of connective tissue. During growth of the *P. senegalus* ovary, multiple oocytes clutches were observed to mature each year. The ovarian development was found in six phases: including one prior to yolk formation (ovary with primary oocytes), four yolky ovaries containing various kinds of oocytes and ripe oocytes. The yolk's formation is composed of four phases: the stage of cortical granules, which signifies the beginning of yolk deposition, and the stages of yolk formation; primary, secondary and tertiary. Depending on the histochemical methods, two primary yolk components were seen during its deposition in *P. senegalus*: the proteinic material, which appeared as cortex granules and globules of yolk, and carbohydrate substance, which was present as polysaccharide granules. First to be deposited were cortical granules, then yolk globules. Proteins made up majority of the cortical granules and yolk globules. Initially, polysaccharides were seen as tiny granules scattered across the rim of the initial yolk oocytes and in *zona radiata*. They are stained positively with periodic acid Schiff (PAS). As the oocyte developed the granules containing polysaccharides showing an increase in number and forming manifested layer under the wall of yolky oocytes. To sum up, the current findings are essential for understanding gonadogenesis of *P. senegalus* and for supplying the fundamental knowledge needed for its effective reproduction.

INTRODUCTION

African Polypterid fishes are located in all of Africa's major river systems, all the way up to the Nile (Gosse, 1984). Species of polypterids are classified as primary freshwater fish, meaning they cannot tolerate saline water at all (Myers, 1938). It has ten species across two genera and is mostly located in shallow murky waters close to shorelines where aquatic weeds are present (Hanel & Khalid, 1992). *P. senegalus* specimens are also referred to as "bichirs" or "dinosaurs eels". Similar to most of other species of bichir, it is mainly obtained from the wild in Africa. The dorsal "flag fins" that are supported by spinous rays and combine with the caudal fin are the most obvious way

to identify them (Schäfer, 2004). The anal fin exhibits a noticeable sexual dimorphism in all *Polypterus* species. In comparison to females, males have larger, wider, and more muscular anal fins (Komagata *et al.*, 1993; Britz & Bartsch, 1998). The phylogeny and origin of polypterids, which still exhibit many primitive traits, have drawn the interest of numerous biologists. However, little is known about these fish's behavior and other facets of their lives (Sataeva & Kasumyan, 2022; Kasumyan *et al.*, 2024).

The development of fish oocytes during the reproductive cycle was examined by numerous authors using both histological and histochemical methods (Selman & Wallace, 1986; Begovac & Wallace, 1988; Corriero *et al.*, 2004; Calabro *et al.*, 2008; Reading *et al.*, 2018; Charitonidou *et al.*, 2022; Porcu *et al.*, 2022). Research on the reproductive biology of wild Polypterids shows that spawning occurs during the transitions between the rainy and dry seasons (Gosse, 1990). Additionally, we used histochemical and immunocytochemical methods to examine the location and characteristics of the various pituitary cell types in *P. senegalus* (Mousa & Khalil, 2007). Regrettably, the data are limited on the reproduction of *Polypterus* species in captivity; *P. ornatipinnis* (Wolff, 1991; Bartsch & Britz, 1996), *P. endlicheri* (Azuma, 1995), and *P. senegalus* (Bartsch *et al.*, 1997; Britz & Bartsch, 1998). The gonads development hasn't been described yet in this species. The current study's objective was to use histological and histochemical methods to examine *P. senegalus*'s ovarian development.

MATERIALS AND METHODS

Animals

The 20 mature *P. senegalus* females utilized in the present investigation were harvested alive from Lake Nasser during the season of maturation. They had a standard length about 25cm. Fish were decapitated and dissected, and their ovaries were then removed and preserved at 4°C for 72 hours in either Bouin fixative or 10% formalin buffered.

Ovarian histology and histochemistry techniques

To examine the arrangement of histology and histochemical composition of oocytes, histological sections were produced from fixed ovary based on method mentioned previously (Mousa *et al.*, 2022) at 5µm thickness. For histological examination, the sections of the ovaries were stained in accordance with the method of Conn (1953) with Harris's hematoxylin and eosin (H&E).

The following techniques were employed in order to look into the oogenesis histochemistry:

- 1- To show proteins, we made use of the technique of mercury bromophenol blue (Bonhag, 1955).
- 2- Using PAS reaction (McManus, 1948), the typical carbohydrates were demonstrated.

Ovarian classification

The average oocyte diameters that had undergone nucleus sectioning used to calculate the oocytes size. Considering the histology and histochemistry of the oocytes and their diameter, six oocytes phases were identified during ovary development; one stage before vitellogenesis and four periods of vitellogenesis, additionally to ripe oocytes-containing ovary.

RESULTS

Instead of the random scattering common in different animals, *P. senegalus* oocytes seem to be arranged in a bead-like pattern (Fig. 1A). Observations have shown that multiple clutches of the oocytes mature each year during development of ovary. To create the last stage of the oocyte growth, the oogonia go through several subsequent phases. These phases typically entail some intricate alterations to the cells' nuclei and cytoplasm.

Oogenesis and ovarian histology

The stages of ovarian classification were based on the type of oocytes, their measurements, and histological characteristics. Ovarian development is generally divided into two phases: one phase prior to vitellogenesis (pre-vitellogenesis) and four stages of vitellogenesis. The ovaries contain oocytes with cortical granules, as well as yolky oocytes: primary, secondary, and tertiary, in addition to a mature ovary with ripe oocytes (Figs. 1, 2).

Primary oocytes ovary (pre-vitellogenesis)

The ovary in the pre-yolk stage contains primary oocytes with round or oval shapes (Fig. 1A, B). These oocytes have diameters ranging from 50 to 250 μ m. Initially, the primary oocytes have a nucleus with a large nucleus, which multiplies as the oocytes grow, resulting in additional and smaller nuclei arranged adjacent to the membrane of nucleus (Fig. 1A). These oocytes are also enclosed in one layer of follicle cells (Fig. 1B).

Yolky (vitellogenic) ovaries

Cortical granules ovary

The stage of the ovary containing oocytes with peripheral granules is the characteristic stage of the beginning of yolk formation. The oocytes at this stage have diameters of 250-400 μ m, and have round or oval central nuclei (Fig. 1B, C). A number of peripheral granules appear in the outer region of the cytoplasm of these oocytes, which gradually increase in number and size to become denser at the periphery (Fig. 1C). The oocytes at this stage have a wall consisting of three layers; the outer theca, the middle granulosa, and the thick inner zona radiata (Fig. 1D).

Early yolk ovary

The early yolk stage ovary had oocytes with diameters of 400-700 μ m and had nuclei that were roughly oval or round in shape. As demonstrated by the structure of

histology, the yolk globules appear initially in the cytoplasm's outer region, and then grow in both quantity and dimension as the oocytes grow (Fig. 1E). Later, the globules become more prominent, forming a thick continuous layer. At this point, the ovary's oocytes have a wall like the earlier stage (Fig. 1F).

Mid yolk ovary

The mid yolk stage had oocytes with diameters of 700-800 μ m. The nuclei of these oocytes were oval in shape and migrated toward one pole (Fig. 2A). The nuclear membrane began to disintegrate. The cytoplasm of the oocytes of this secondary yolk stage became more filled with yolk globules (Fig. 2A). The *zona radiata* also became thicker (Fig. 2B).

Late yolk ovary

The yolky oocytes of the late yolk ovary were 800 to 1200 μ m in diameter. The nuclei of these yolk oocytes were called "germinal vesicles"; they had irregular borders and were not centrally located (Fig. 2C). The yolk globules became more densely packed throughout the cytoplasm (Fig. 2C). The *zona radiata* layer was thicker than in the previous stages (Fig. 1D).

Ripe ovary

As shown in Fig. (2E), the nucleus of ripe or mature oocytes disappeared as a special structure within the cytoplasm. The yolk became a homogeneous layer. The ripe oocytes diameters ranged from 1200 to 1500 μ m. The oocyte wall was thin and stretched due to its rapid growth. This stage was also distinguished by the existence of micropylar cells covering and protruding into the micropyle, which is situated above an oocyte component that contains cytoplasmic majority and a homogeneous substance of fine yolk granules and is next to the germinal vesicle (Fig. 2F).

Oogenesis histochemistry

The principal reason for oocyte enlargement is the buildup of yolk material, which is an essential part of all oocytes. In *P. senegalus*, two different kinds of the yolk substance were identified; polysaccharide granules, protein cortical granules and globules of yolk.

Protein histochemistry (Cortical granules and Yolk globules)

As demonstrated by their staining, proteinic materials were detected in both yolk globules and *zona radiata* (Fig. 3). In the periphery of oocytes' ooplasm, a few tiny spherical cortical granules initially represented the buildup of proteid yolk (Fig. 3A, B). Consequently, they were observed to gradually grow in both quantity and size concurrently with the development of the yolky oocytes. They eventually aggregated as groups of yolky globules in the cytoplasm of yolky and ripe oocytes (Fig. 3C-F).

Carbohydrate histochemistry

The polysaccharide granules initially showed up as tiny granules dispersed around the oocytes' periphery; their positive PAS-reaction indicated that they contained carbohydrates (Fig. 4A, B). The granules number of polysaccharide, which formed a

Ovary Development in *Polypterus senegalus*

highly stained layer underneath the membrane of vitellogenic oocyte, increased in parallel with the oocytes' growth, as shown in Fig. (4C, D). Upon completion of vitellogenesis, these granules were seen dispersed throughout the ooplasm (Fig. 4E). Additionally, as shown by their intense staining with PAS (Fig. 4B, D, and F), carbohydrate substance was abundant in *zona radiata* (ZR).

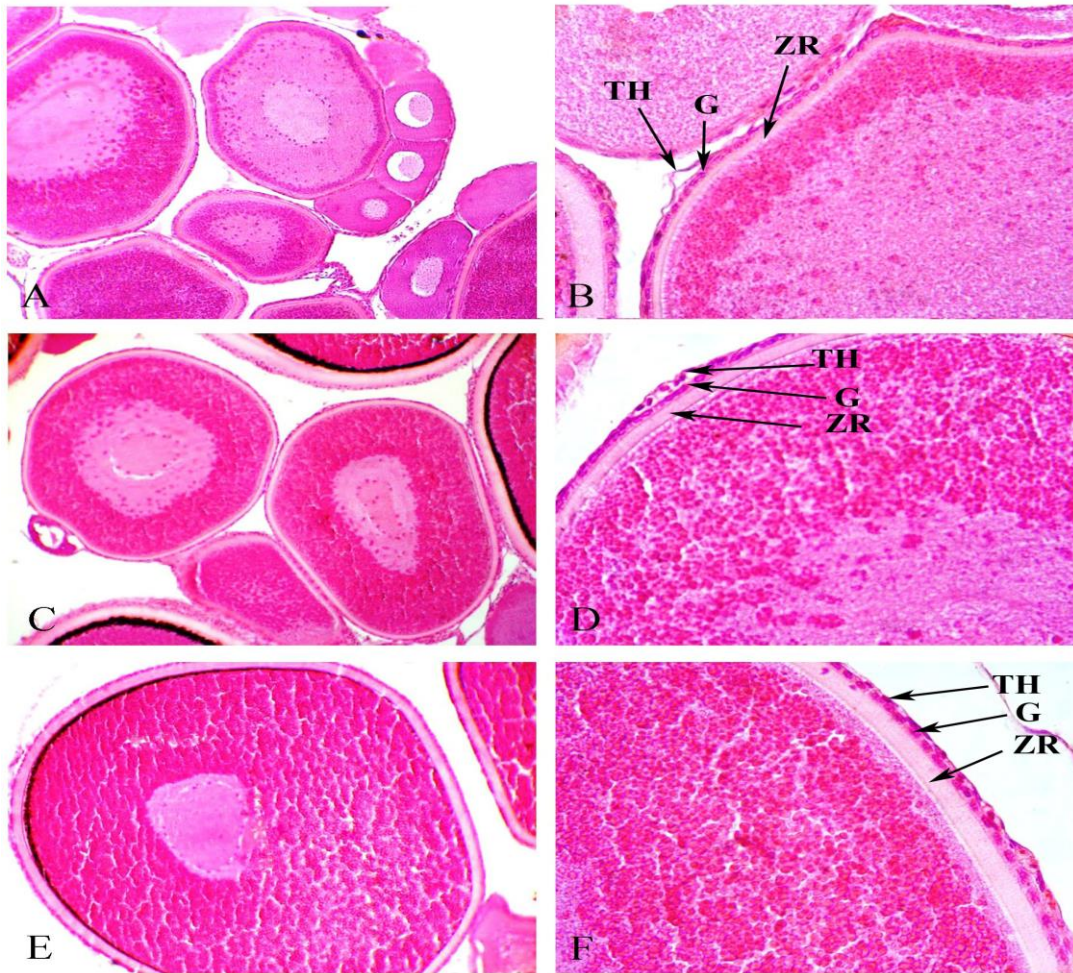


Fig. 1. Histological view of *P. senegalus* ovaries sections stained with H&E. (a) Early yolk ovary with primary oocytes and early yolk oocytes. X100. (b) Magnified section of (a) showing the primary oocyte wall layers; theca (TH), granulosa (G), and zona radiata (ZR). X400. (c) Mid-yolk ovary containing primary yolk oocytes. Yolk globules appear initially in the exterior cytoplasm. X100. (d) Magnified section of (c) showing the oocyte wall layers; TH, G, and ZR. X400. (e) Late yolk ovary showing secondary yolk oocytes with numerous yolk globules in the cytoplasm. X100. (f) Magnification of (e) showing the three oocyte wall layers ZR, G, and TH. X400

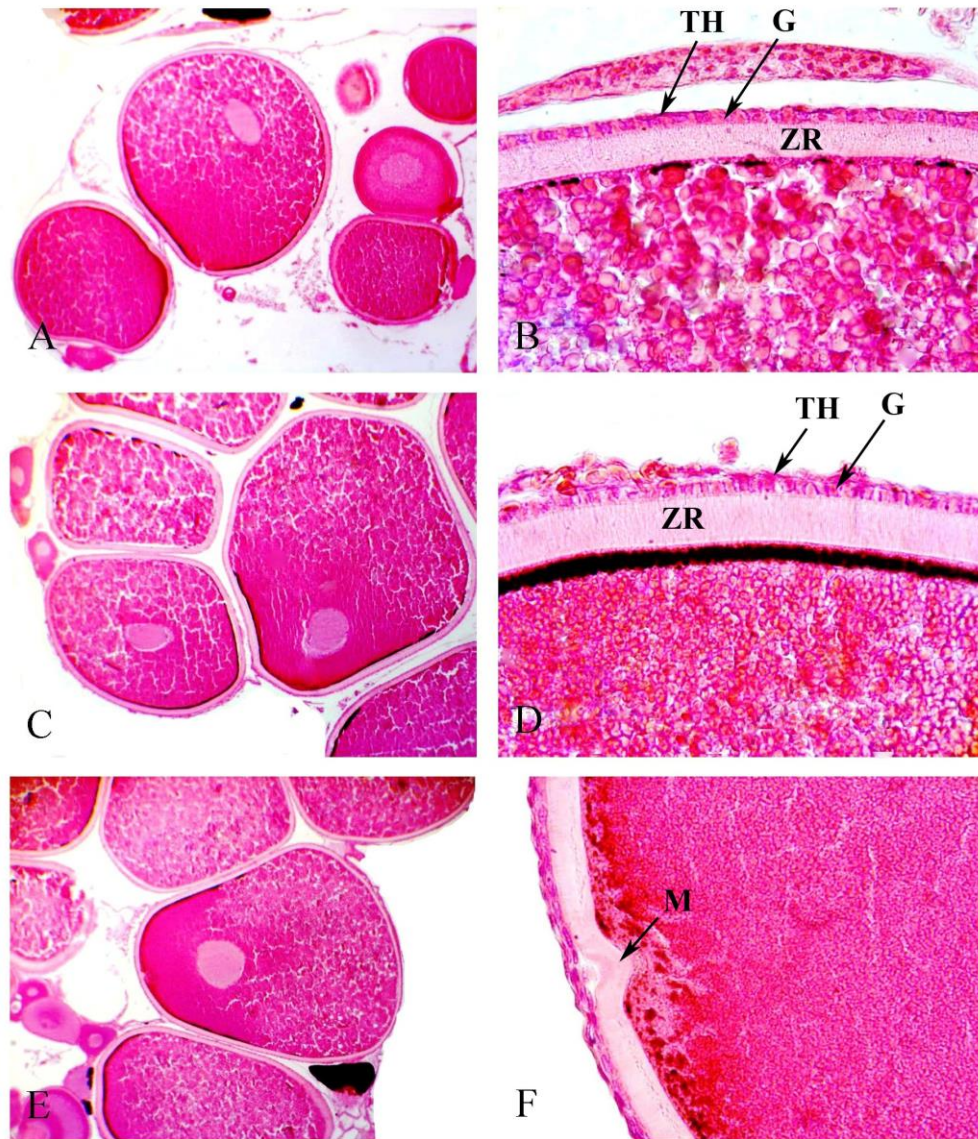


Fig. 2. Sections of mature *P. senegalus* ovaries stained with H&E. (a) Post-yolk ovary of ripe female showing oocyte in tertiary yolk stage yolk globule-impregnated and with a margin-located nucleus. X40. (b) Magnification of (a) showing the three layers wall of the oocyte; TH, G, and ZR. X400. (c) Post-yolk mature ovary showing early maturation of the oocyte as evidenced by yolk globule aggregation and migration of the nucleus. X40. (d) Magnified section of (c) showing the aggregated yolk globules and the oocyte wall layers; ZR, G, and TH. X400. (e) Mature ovary with mature oocytes with a lateral nucleus and advanced yolk globules. X40. (f) Magnified section of a mature oocyte showing zona radiata at the site of invasion of the micropyle (M) by micropyle cells. The cytoplasmic region below the micropyle opening is also shown to be free of yolk globules. X400

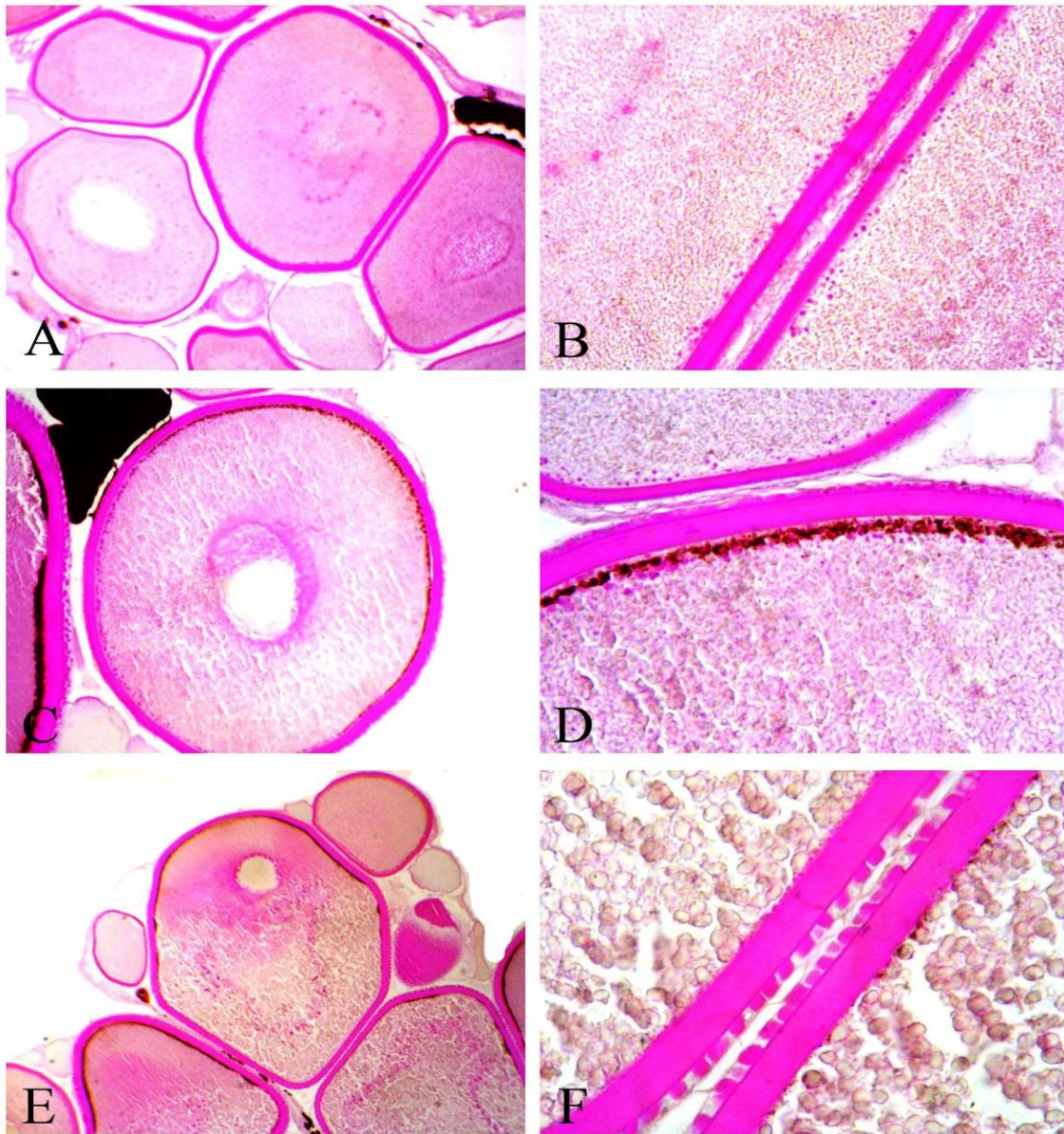


Fig. 3. Sections stained with PAS to illustrate the carbohydrates histochemistry during oocyte growth in *P. senegalus*. (a), (c) and (e) at magnification of X100, (b), (d) and (f) magnified to X400. Small polysaccharide granules positively reacted with PAS appear in the outer cortex initially of the early yolk oocyte (a and b) and become more prominent in the primary yolk oocyte at the start of yolk formation (c and d). After yolk deposition, the cytoplasm was filled with these granules. (e) *Zona radiata* also contains a high quantity of carbohydrate substance as shown by the strong reaction with PAS (b, d and f).

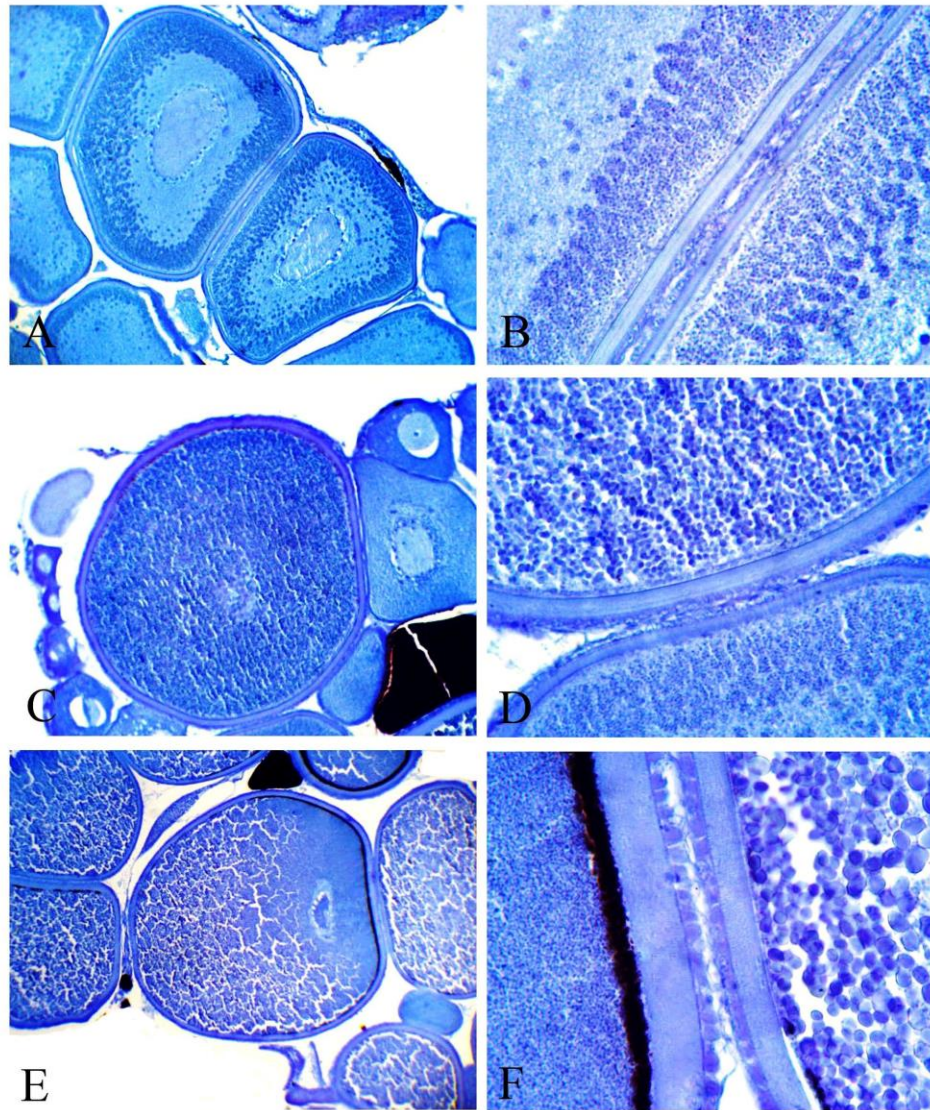


Fig. 4. Sections of developing oocytes of *P. senegalus* were stained with bromophenol blue for protein histochemistry. The magnification of (a), (c) and (e) was X100, (b), (d) and (f) was X400. Cortical granules reacted positively with bromophenol blue. They appear in the cortex's outer layer initially. In early yolk-forming oocytes (a and b), growing in prominence in late yolk-forming (c and d) and maturation (e and f) stages. As the oocyte matures, yolk globules coalesce and appear compressed throughout the cytoplasm, with numerous small yolk granules clustered around the migrating nucleus (e and f). The follicular cells and *zona radiata* also contain moderate amounts of protein, as shown by their moderate stain (b, d and f).

DISCUSSION

Numerous criteria, viz. the size, quantity, and distribution of different cell inclusions particularly yolk granules in addition to the nuclei and nucleoli seeming, have been employed to differentiate between the different phases of oogenesis. In *P. senegalus*, the successive stages of oogenesis are primary oocytes, cortical granules, and primary, secondary, and tertiary yolk, and ripe oocytes. Similar phases were recognized in *M. cephalus* (Mousa, 1994) and *L. ramada* (Mousa et al., 2022). Yolk deposition in *P. senegalus* included the cortical granules, and the yolky stages: primary, secondary and tertiary. In numerous teleostean species, comparable vitellogenic stages were documented, such as *Carassius auratus* (Khoo, 1979), *Gadus morhua* (Kjesbu & Kryvi, 1989), *M. cephalus* (Mousa, 1994) and *L. ramada* (Mousa et al., 2022). The yolky stages in certain other fishes were only divided into two periods: vacuoles formation and deposition of yolk in *Clarias gariepinus* (Zaki et al., 1986) and *Chrysichthyes auratus* (Ashour et al., 1990) in addition to the vesicles of lipid deposition and formation of yolky protein in *Macrodon ancylodon* (Vizziano & Berois, 1990). N'Da and Deniel (1993), however, distinguished three yolky stages in *Mullus surmuletus*. The present findings of the histology showed that the vitellogenic oocytes of *P. senegalus*, like most teleosts, have non-cellular inner zona radiate, granulosa and theca cell layers.

Not all teleosts had the same prevalence of the different kinds of yolk inclusions in their oocytes; in certain fish, only yolk granules and vesicles were seen (Yamamoto, 1956; Khoo, 1979). As stated in the current histological and histochemical results, *P. senegalus* produces two different kinds of yolky material during yolk formation: polysaccharide granules and proteinic cortical granules and yolk globules. First to be deposited were cortical granules, then yolk globules. There were notable variations in the morphology, tinctorial qualities, and chemical makeup of these yolk inclusions. Proteins made up most of both the globules of yolk and the cortical granules. Polysaccharides initially manifested as tiny granules scattered across the periphery of ooplasm in the firstly yolk oocytes and in zona radiata. Their strong reaction with PAS suggested that they contained carbohydrate materials. As the oocytes grew, the polysaccharide granules number increased as well, forming a highly expressed layer underneath the yolky oocyte membrane. During the growth of oocyte in *M. cephalus* and *L. ramada*, three different kinds of yolk constituents were produced: lipid droplets, proteinic globules of yolk, and polysaccharides cortical granules (Mousa, 1994; Mousa et al., 2022). However, Anderson (1968) noted that both polysaccharides and proteins were present in the cortical alveoli of *Fundulus heteroclitus* and *Syngnathus fuscus* oocytes. Moreover, Khoo (1979) noted that polysaccharides and proteins made up these vesicles. About the yolk granules chemical makeup, it was noted that they are primarily composed of lipoprotein and protein (Guraya, 1965; Rastogi, 1969). In *Carassius auratus*, yolk granules were found to contain neutral lipids, phospholipids and proteins (Khoo, 1979). However, in

Fundulus heteroclitus and *Syngnathus fuscus*, they were found to have phospholipids in it (Anderson, 1968). Nonetheless, Maksimova (1991) showed that proteins, along with a trace amount of glycol-proteins and glycogen, made up the granules of yolk in *Thymallus arcticus* oocytes.

The proteinic yolk originates exogenously and is initially located in the cortex's outer layer, where it is sequestered as distinct granules. The precursor of yolk protein was discovered to be vitellogenin (Wallace, 1978). In line with the dominant theory, the developing oocytes specifically sequester the hepatically produced vitellogenin under the influence of gonadotropin (Wallace & Selman, 1981; Tyler *et al.*, 1987, 1991). Granules of polysaccharides liberated their contentment into the space of perivitelline during the maturation cortical reaction, so they not strictly classified as yolks.

In summary, this study explains the histochemical makeup of yolk containments during *P. senegalus* oogenesis and the mode of ovary development. The current findings are necessary for understanding *P. senegalus*' reproductive endocrinology and for providing the fundamental knowledge needed for its effective propagation.

REFERENCES

- Anderson, E. (1968). Cortical alveoli formation and vitellogenesis during oocytes differentiation in the pipefish, *Syngnathus fuscus*, and the killifish, *Fundulus heteroclitus*. *J. Morphol.*, 125: 23-59.
- Ashour, M.B.; Zaher, M.M. and Rida, S. (1990). Ecological studies on the female reproductive cycle of some fishes of the river Nile at Beni Suef area III. Histological studies of the seasonal cycle of the ovary of *Chrysichthyes auratus*. *J. Egypt. Ger. Soc. Zool.*, 2: 287-297.
- Azuma, H. (1995): Breeding *Polypterus endlicheri*. *Tropical Fish Hobbyist.*, 44: 116-128.
- Bartsch, P. and Britz, R. (1996). Die Zucht und Entwicklung von *Polypterus ornatipinnis*. *Die Aquarien und Terrarienzeitschrift*, 1 (9):15-20.
- Bartsch, P.; Gemballa, S. and Piotrowski, T. (1997). The embryonic and larval development of *Polypterus senegalus* Cuvier, 1829: 1st staging with reference to external and skeletal features, behaviour and locomotory habits. *Acta Zoologica*, 78: 309-328.
- Begovac, P. C. and Wallace, R. A. (1988). Stages of oocyte development in the pipefish, *Syngnathus scovelli*. *J. Morphol.*, 197: 353-369.
- Bonhag, P.F. (1955). Histochemical studies of the ovarian neres tissue and oocytes of the milkweed bug, *Oncopeltus fasciatus* (Dallas). I. Cytology, nucleic acids, and carbohydrates. *J. Morphol.*, 96 (3): 381-439.

- Britz, R. and Bartsch, P.** (1998). On the reproduction and early development of *Erpetoichthys calbaricus*, *Polypterus senegalus* and *Polypterus ornatipinnis* (Actinopterygii: Polypteridae). Ichthyol. Explor. Freshwater, 9: 325-334.
- Calabro, C.; Albanese, M.P.; Bertuccio, C.; Licata, A. and Gentile, N.** (2008). Histological, histochemical and immunohistochemical study on the growing oocytes of the abyssal teleost *Hoplostethus mediterraneus* (V). Folia Histochemica Cytobiologica., 46 (1): 97-102.
- Charitonidou, K.; Panteris, E. and Ganias, K.** (2022). Oogonial proliferation and early oocyte dynamics during the reproductive cycle of two Clupeiform fish species. Journal of Fish Biology, 1–9. <https://doi.org/10.1111/jfb.15236>
- Conn, H.J.** (1953). A biological stains. (Williams and Wilkins Company, Baltimore).
- Corriero, A.; Acone, F.; Desantis, S. and Zubani, D.** (2004). Histological and immunohistochemical investigation on ovarian development and plasma estradiol levels in the swordfish (*Xiphias gladius* L.). European Journal of Histochemistry, 48 (4), 413–422. <https://doi.org/10.4081/915>
- Gosse, J.P.** (1984). Mormyridae pp. In: Daget J, Gosse JP, Thys van den Audernaerde DFE (eds) Check list of the Freshwater Fishes of Africa, Vol 1. Tervuren ORSTOM Paris, pp 63-122.
- Gosse, J.P.** (1990). Polypteridae. In: (Lévêque C, Paugy D, TEUGELS GG (eds) Faune des poissons d'eaux douces et saumâtres d'Afrique de l'Ouest. Tome I. Coll. Faune Tropicale n° XXVIII. Musée Royal de l'Afrique Centrale, Tervuran and ORSTOM, Paris, pp79-87.
- Guraya, S.S.** (1965). A comparative histochemical study of the fish *Channa maruleus* and amphibian *Bufo stomaticus* oogenesis. Z. Zellforsch. Mikrosk. Anat., 65: 662-700.
- Hanel, L. and Khalid, A.M.** (1992). Morphometrical and ecological note on *Polypterus senegalus* (Pisces, Polyteridae) from the reservoir Gebel Aulia (Sudan). Acta Societatis Zoologicae Bohemoslovaca 56: 109-114.
- Kasumyan, A. O.; Zdanovich, V. V. and Sataeva, V. V.** (2024). Locomotor Activity of the Intact and Visually Deprived Senegal Bichir *Polypterus senegalus* (Cladistia) at Different Water Temperatures. Journal of Ichthyology, 64 (3): 541-547.
- Khoo, K.H.** (1979). The histochemistry and endocrine control of vitellogenesis in goldfish ovaries. Can. J.Zool., 57: 617-626.
- Kjesbu, O.S. and Kryvi, H.** (1989). Oogenesis in cod, *Gadus morhua* L., studies by light and electron microscopy. J. Fish Biol., 34: 735-746.
- Komagata, K.; Suzuki, A. and Kuwabara, R.** (1993). Sexual Dimorphism in the Polypterid Fishes, *Polypterus senegalus* and *Calarnoichthys calabaricus*. Japanese Journal of Ichthyology, 39 (4): 387-390.
- McManus, J. F. A.** (1948). Histological and histochemical uses of periodic acid. Stain Technol., 23: 99.

- Mousa, M.A.** (1994). Biological studies on the reproduction of mullet (*Mugil cephalus* L.) in Egypt. Ph.D. Thesis. Ain Shams University. pp278.
- Mousa, M.A. and Khalil, N.A.** (2007). Immunohistochemical and histochemical identification and distribution of the cell types in the pituitary gland of *Polypterus senegalus* (Polypteridae). J. Egypt. Ger. Soc. Zool., 54 (C): 101-122.
- Mousa, M.A.; El-messady, F.A.; Kora, M.F. and Khalil, N.A.** (2022). Histochemistry of oogenesis in flathead grey mullet *Mugil cephalus* (Mugilidae) in natural habitat. Egypt. J. Aquat. Biol. & Fish., 26 (6): 1083- 1094.
- Myers, G.S.** (1938). Fresh water fishes and West Indian zoogeography. Smithsonian Report, 1937: 339-364.
- N'Da, K. and Déniel, C.** (1993). Sexual cycle and seasonal changes in the ovary of the red mullet, *Mullus surmuletus*, from the southern coast of Brittany. J.Fish Biol., 43 (2): 229-244.
- Porcu, C.; Lai, E.; Bellodi, A.; Carbonara, P.; Cau, A.; Mulas, A.; Pascale, N.; Porceddu, R. and Follesa, M.C.** (2022). Investigating the ovarian microstructure in the genera *Helicolenus* and *Scorpaena* (Teleostei, Sub-Order Scorpaenoidei) with implications for ovarian dynamics and spawning. *Animals*, 12 (1412): 1-19. <https://doi.org/10.3390/ani12111412>
- Rastogi, R. K.** (1969). Studies on the fish oogenesis. III. Viltellogenesis in some fresh water teleosts. Ant. Anz., 125: 34-36.
- Reading, B.J.; Andersen, L.K.; Ryu, Y.-W.; Mushiobira, Y.; Todo, T. and Hiramatsu, N.** (2018). Oogenesis and egg quality in finfish: Yolk formation and other factors influencing female fertility. *Fishes*, 3 (45): 1-28. Doi:10.3390/fishes3040045.
- Sataeva, V. V. and Kasumyan, A. O.** (2022). Orosensory preferences and feeding behavior of Cladistia: A comparison of gray bichir *Polypterus senegalus* and saddle bichir *P. endlicherii* (Polypteridae). *Journal of Ichthyology*, 62 (7): 1501-1520.
- Schäfer, F.** (2004). *Polypterus* Flösselhechte Bichirs. Aqualog Verlag ACS GmbH, Germany.
- Selman, K. and Wallace, R.A.** (1986). Gametogenesis in *Fundulus heteroclitus*. *Am. Zool.*, 26: 173-192.
- Tyler, C., Sumpter, J. and Bromage, N.** (1987). The hormonal control of vitellogenic uptake into cultured ovarian follicles of the rainbow trout. In: D.R. Idler, L.W. Crim and J.M. Walsh (Editors), Proc. Third Int. Symp. Reprod. Physiol. Fish. St. Johns, Newfoundland, Canada, 2-7 August 1987, p. 220.
- Tyler, C.R.; Sumpter, J.P.; Kawachi, H. and Swanson, P.** (1991). Involvement of gonadotropin in the uptake of vitellogenin into vitellogenic oocytes of the rainbow trout, *Oncorhynchus mykiss*. *Gen. Comp. Endocrinol.*, 84: 291-299.

Ovary Development in *Polypterus senegalus*

- Vizziano, D. and Berois, N.** (1990). Histology of the gonad of *Macrodon ancylodon* (Black and Schneider, 1801) Teleostei: *Sciaenidae* Oogenesis, Post-Ovulatory Follicles. *Atresia. Rev. Brasil. Biol.*, 50 (2): 523-536.
- Wallace, R.A.** (1978). Oocyte growth in nonmammalian vertebrates. In: *The Vertebrate ovary*. (R.E. Jones, ed.), pp. 469-502. New York: Plenum Press.
- Wallace, R. A. and Selman, K.** (1981). Cellular and dynamic aspects of oocyte growth in teleosts. *Am. Zool.*, 21: 325-343.
- Wolff, E.** (1991). Die Zucht von *Polypterus ornatipinnis* in zweiter Generation. *Jahresbericht Löbbecke Museum und Aquazoo, Düsseldorf*, 1991: 58-61.
- Yamamoto, K.** (1956). Studies on the formation of the fish eggs. I. Annual cycle in the development of ovarian eggs in the flounder, *Liopsetta obscura*. *J. Fac. Sci. Hokkaido Univ. Ser. VI*, 12: 362-374.
- Zaki, M.I.; Dowidar, M.N. and Abdala, A.** (1986). Reproductive biology of *Clarias gariepinus* (Syn. *Lazera*) Burchell (*Clariidae*) in lake Manzalah, Egypt. I. Structure of the ovaries. *Folia Morphologica*, XXXIV (3): 301-306.