

Role of Flow Volume (FV) and Peak Systolic Velocity (PSV) in Predicting the Success Rate of Hemodialysis AVF Using Spectral Doppler Ultrasound

Sherif M. Abdelal; MD¹, Gehan S. Seifeldein; MD¹, Marwa K. Khairallah MD², Lina M. Farid; MSc^{*1}, Hamdy M. Ibrahim; MD¹.

¹*Department of Diagnostic Radiology, Faculty of Medicine, Assiut University, Egypt.*

²*Department of Nephrology Internal Medicine, Faculty of Medicine, Assiut University, Egypt.*

***Corresponding Author:** Lina M. Farid

E-mail: Lina.m.farid@gmail.com

Abstract

Background: The global use of Doppler ultrasound (DUS) can extend the survival of recently created arteriovenous fistula (AVF) by facilitating the early detection of complications and easing early management.

Our study aims to provide a view of the possible applications of DUS during maturation and postoperative follow-up of AVFs.

Results: 87 patients with end-stage renal disease who underwent AVF participated in this study: 54 males and 33 females with a mean age of 49.38 ± 11.8 years. The study depicted 56 (64.3%) mature/well-functioning AVFs and 31 immature/complicated AVFs. At the site of the fistula, the mean peak systolic velocity (PSV) and mean flow volume (FV) in the mature group were 256 ± 230 cm/s vs. 76 ± 116 cm/s and 810 ± 183 ml/min vs. 370 ± 520 ml/min in the immature/complicated group respectively ($p < 0.001$).

Conclusions: FV and PSV are done through DUS, a bedside examination, a safe, non-invasive, low-cost, readily available, and reliable technique that can be used for regular follow-up, observing maturation, and early detection of complications.

Keywords: Color Doppler ultrasound; arteriovenous fistula; hemodialysis access; flow volume; peak systolic velocity.

Background:

A surgically constructed arteriovenous fistula (AVF) is a gold vascular access for hemodialysis patients. In comparison to the central venous catheters and grafts, AVFs are more durable and have a lesser incidence of complications (1), (2), and (3).

Although AVF is the preferred access for hemodialysis, there is still a high rate of failed maturation in clinical practice. Therefore, well-known criteria are applied early after the creation of a fistula by periodic monitoring of the fistula. (4).

The widespread use of Doppler ultrasound (DUS) has increased the number of patients qualified for AVF creation by making the identification of vessels eligible

for fistula construction (preoperative vascular mapping). DUS is the only imaging modality that offers both morphological and functional analysis on the native AVFs and evaluates the inflow and outflow sides of the fistula. Furthermore, ultrasound is an easy bedside technique with no ionizing radiations or iodinated intravenous contrast media and a low-cost and accessible imaging modality (2).

Objectives:

This study aims to provide an overview of the possible applications of DUS during maturation and postoperative follow-up of AVFs to establish a relationship between DUS parameters, including flow volume, outflow vein diameter, outflow vein depth, and its ability in early detection of complications in the access.

Patients and Methods:

This prospective cross-sectional study took place in the Radiodiagnosis Department in collaboration with the nephrology unit of the Internal Medicine Department at Assiut University Hospitals (AUH) from March 2021 to May 2022. It was managed after approval of the Ethical Committee of the Faculty of Medicine (IRB: 17100751) and clinical trial approval. All examinations were done confidentially, with consent obtained from all patients.

The minimal sample size was calculated based on the sample size calculation done by the public health department at AUH. A total sample size of 120 with a minimal sample size of 84 patients is the enough required sample to detect a standardized effect. The sample size was calculated using Gpower version 3.1.9.2 (Dusseldorf, Germany).

Inclusion Criteria:

Both male and female patients who were diagnosed with ESRD and required a hemodialysis AVF for the 1st time in the adult age group (18-67 years old), Patients who had malfunctioning AVF and required new creation of fistula at the other limb, and Patients who attended follow-up postoperative and for dialysis sessions.

Exclusion Criteria:

Patients with poor vascularity (such as obvious vessel wall calcification and small calibers), patients subjected to renal transplantation, and any fistula failure within one week are considered surgical failure and excluded.

Equipment and Supplies:

Our project was done during the epidemic of COVID-19 and due to the high flow rate in our university hospitals, we did our technique on more than one ultrasound (US) scanner. The US scanners were the GE logiq P7 R2 and the GE logiq F6 Ultrasound systems. The transducer used in the study is the linear probe with a frequency of 6-12MHz. Other standard supplies for ultrasound exams are sterile gel, wipes, gloves, pillow(s), or foam pad to position the patient comfortably.

Technique of Examination:

The study was performed on a non-dialysis day because the measurements will be equivocal, as most patients will undergo a hypotension phenomenon, and because the dressings cover the AVF site (5).

I. Clinical assessment of the AVF:

The consultant nephrologist in the Internal Medicine Department used a checklist for data collection about each patient before the examination.

II. Positioning the patient:

The patient lies supine with the arm to be examined externally, rotated, extended and abducted from the body to a 45-degree angle.

III. B-mode assessment of the AVF:

By evaluating the inflow artery followed by the fistula and ended with the draining vein in the transverse plane. This plane helps give an overall appreciation of the anatomy.

IV. Duplex assessment of the AVF:

Most of the duplex study is carried out in a longitudinal plane, allowing for greater accuracy in the Doppler angle. This view also provides a greater appreciation of flow, as seen in the images of the color flow. Color images are used to evaluate the direction of flow. The following parameters are obtained and added to the checklist:

1. Peak systolic velocity (PSV) of inflow artery, outflow vein, and fistula site.
2. End-diastolic velocity (EDV) of inflow artery, outflow vein, and fistula site.
3. Three flow volume (FV) measurements are taken at the fistula site, and the mean value is determined.

V. Interpretation of the AVF examination data:

According to the history taken before DUS, the fistula can be classified into four types: mature, immature, complicated, and well-functioning.

The following clinical criteria are put into consideration for AVF maturation: being easily visible and palpated superficial vein, the vein has an adequate diameter for easy needling (3-4 mm), sufficient length (≥ 10 cm, for enough distance between the

inflow and outflow needles) and uniform thrill (7, 8, 9).

Statistical Analysis:

Data were verified, coded by the researcher, and analyzed using IBM-SPSS 24.0 (IBM-SPSS Inc., Chicago, IL, USA). Test of significances: Chi-square/Fisher's significant variables from the univariate analysis were entered in a multivariable logistic regression model to test the independent predictors of AVF Maturity in patients with ESRD on hemodialysis using odds ratio (OR), 95% confidence interval (CI), and p-value.

ROC curve depicted the diagnostic performance of Color-DUS for diagnosis of AVF complication, analyzed as the area under the curve (AUC), standard error (SE), and 95% CI. Significant test results were considered when the value was ≤ 0.05 .

Results:

I. Demographic and Medical Data:

Eighty-seven patients were included in this population; 52 patients (59.5%) had brachiocephalic (BC) fistula. Half of the patients were in the right upper limb (44). All are detailed in Table (1). (23.8%) have comorbid diseases.

Table (1): Baseline Characteristics of the studied Cohort

Variable	Category	N=87
Age/ years	- Mean \pm SD	49.38 \pm 11.8
	- Median (Range)	49.5 (18 – 67)
Sex	- Female	33 (38.1%)
	- Male	54 (61.9%)
Side of fistula	- Left	43 (49.4%)
	- Right	44 (50.5%)
Site of fistula	- Brachiocephalic (BC)	52 (59.5%)
	- Radiocephalic (RC)	35 (40.5%)
Duration of fistula/months	- Mean \pm SD	3.67 \pm 3.7
	- Median (Range).	1.75 (1 – 15)
Previous Access	- No	65 (76.2%)
	- Rt. RC	2 (2.4%)
	- Rt. BC	4 (4.8%)
	- Lt. RC	4 (4.8%)
	- Lt. BC	12 (14.3%)

*Rt. RC: right radiocephalic, Rt. BC: right brachiocephalic, Lt. RC: left radiocephalic, and Lt. BC: left brachiocephalic.

II. DUS Data:

The overall mean diameter of the inflow artery is 3.61 ± 0.9 mm, ranging between 2- 7 mm. Meanwhile, the mean diameter of the fistula site is 3.60 ± 1.1 mm, ranging between 1-7 mm. The mean diameter of the outflow vein is 6.81 ± 3.4 mm, ranging between 2-15 mm.

The inflow artery's mean peak systolic velocity (PSV) is 99.42 ± 43.6 cm/s, ranging between 35 - 250 cm/s. The mean PSV at the fistula site is 189.80 ± 130.2 cm/s, ranging between 0 - 368 cm/s. The mean PSV of the outflow vein is 145.02 ± 93.8 cm/s, ranging between 0 - 300 cm/s.

Outcomes of the AVF:

Focusing on the main factors to determine the outcomes, the flow volume (FV) at the fistula site shows a mean value of 810 ml/min, ranging between 0 - 6344 ml/min., with a significant difference among them (p-value < 0.001), as shown in Figure (1).

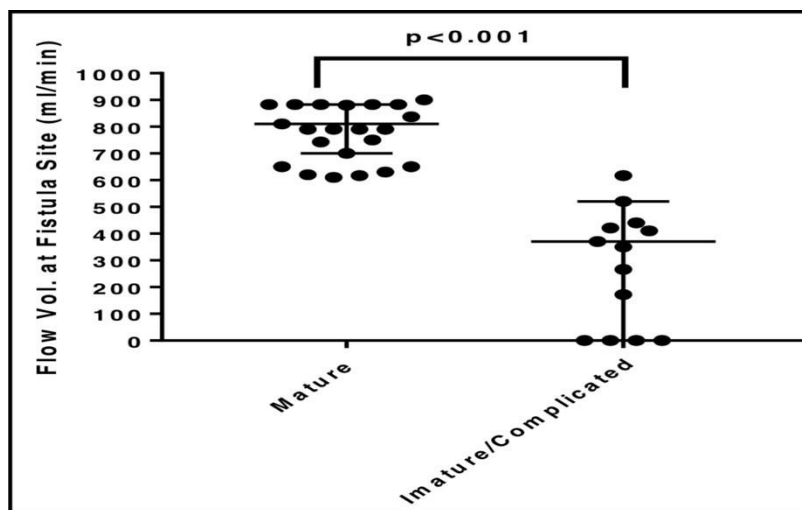


Figure (1): Flow Volume at Fistula Site for the Outcome Measure.

For example, Figure (2) shows aneurysmal dilatation at the proximal cephalic vein with a laminating thrombus inside. DUS parameters are proof of well-functioning AVF

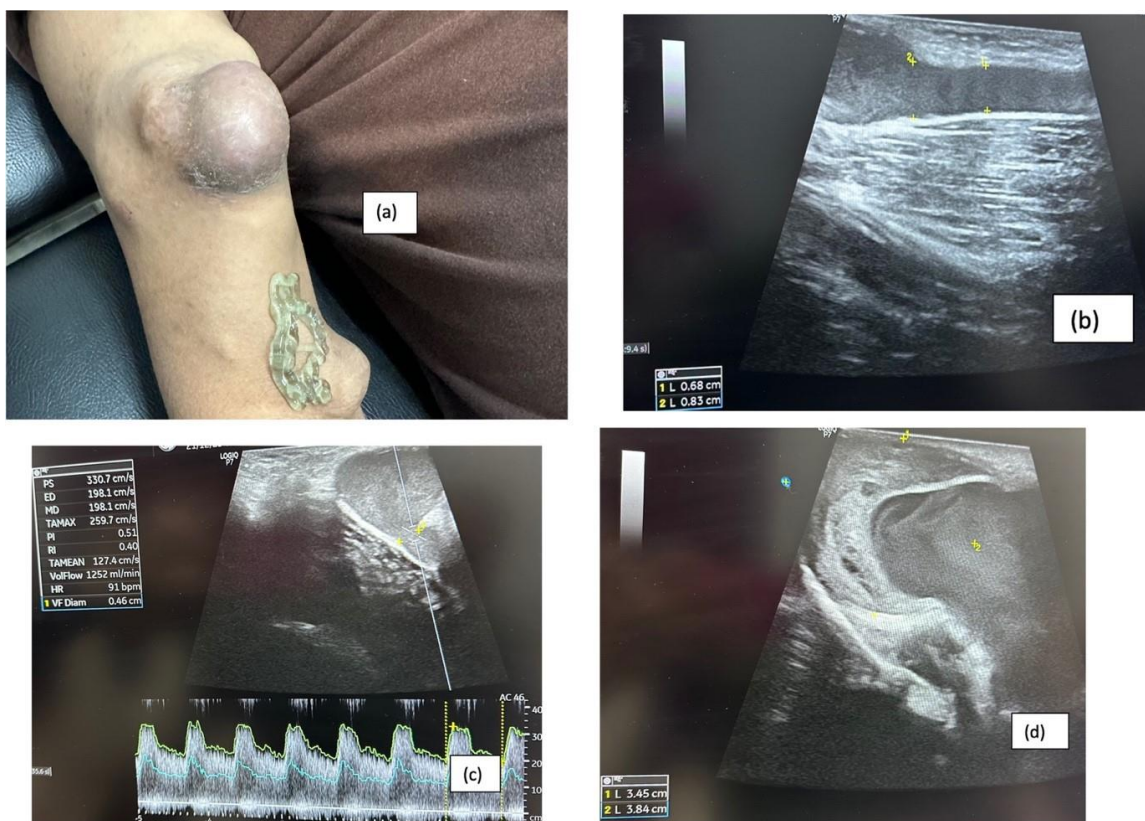


Figure (2): 44 A 44-year-old male presented to our department for a follow-up of his right BC AVF after the appearance of aneurysmal dilatation following a recent dialysis session. DUS examination shows a well-functioning fistula despite the partially thrombosed aneurysm.

Regarding maturation and complication evaluation of the total 87 fistulas, 56 (64.3%) are considered mature/well-functioning, 31 cases are immature/complicated (Thirteen fistulas (26.19% of all patients) have immature new accesses, and 18 cases (28.57% of all patients) are complicated).

Table (2) shows DUS parameters and focusing on the in-flow artery, the mean value of the PSV in the mature group is 123 cm/s, and the mean diameter is 4 mm, while the mean PSV in the immature/complicated group is 67 cm/s, and the mean diameter is 3 mm. (p-value is 0.001 and 0.078, respectively).

Table (2): Colour Doppler U/S Correlates of AVF Maturation among the studied Cases:

		Mature (n=56)	Immature/complicated (n=31)	P-value
In-flow Artery	Patency	8 (14.8%)	8 (26.7%)	= 0.203*
	PSV (cm/sec)	123 (30)	67 (26)	= 0.001**
	Diameter (mm)	4 (1)	3 (1)	= 0.078**
Fistula	Patency	4 (7.4%)	12 (40%)	= 0.016*
	PSV (cm/sec)	256 (230)	76 (116)	< 0.001**
	Diameter (mm)	3 (1.2)	4 (1.5)	= 0.049**
Outflow Vein	Patency	8 (14.8%)	18 (60%)	= 0.003*
	PSV (cm/sec)	230 (144)	64 (72)	< 0.001**
	Diameter(mm)	8 (4)	4 (3)	= 0.041**
Depth from Skin (mm)		3 (2)	2.9 (2)	= 0.810**
FV at Fistula Site (ml/min)		810 (183)	370 (520)	< 0.001**
Affected Superficial VS		1 (3.7%)	4 (26.7%)	= 0.043*

*Fisher's Exact test was used to compare the frequency between groups

**Mann Whitney U test was used to compare the median between groups.

The mean FV at the fistula site in the mature group is 810+/- 183 ml/min; in the immature/complicated group, the mean FV is 370 ml/min. (p < 0.001).

Complications:

The most common complication detected was thrombosis (17 out of 46 patients, 35%), followed by hematomas (12 patients, 25%). Other complications are stenosis and steal phenomena (8 patients, 17 %). While seven patients had aneurysms (15%), respectively. The last two complications observed in the studied cohort were infection and central venous congestion. They represented two patients with a percentage of 4 % each.

Table (3) displayed the independent predictors of AVF complication among the studied cohort. In the final multivariable regression model, after adjusting for age and sex, there were seven predictors: fistula site, previous access, diastolic blood pressure (DBP), fistula PSV, and outflow vein patency/PSV/diameter.

Table (3): Predictors of AVF Complications among Cases: Multivariable Regression:

Predictor	OR (95% CI)	P-value
Age/years	0.987 (0.934 – 1.043)	= 0.651
Sex (male)	1.902 (0.495 – 5.308)	= 0.349
Fistula site (RC)	0.068 (0.006 – 0.730)	= 0.026
Previous access	0.090 (0.007 – 0.853)	= 0.029
DBP (mmHg)	1.082 (1.011 – 1.210)	= 0.035
PSV fistula (cm/s)	1.045 (1.002 – 1.102)	= 0.044
vein patency (Absent)	12.555 (3.036 – 35.911)	= 0.047
PSV of vein (cm/s)	0.878 (0.737 – 0.998)	= 0.046
vein diameter (mm)	2.689 (1.008 – 7.171)	= 0.048
PSV of artery (cm/s)	0.983 (0.918 – 1.052)	= 0.214

OR= Odds Ratio; CI, Confidence Interval

III. Accuracy of the DUS parameters of AVF:

The diagnostic value of Colour Doppler U/S Parameters for diagnosis of AVF complication was depicted in Table (4)

Table (4): Validity of Colour Doppler U/S Parameters for AVF Complication Prediction:

Diagnostic Criteria	PSV	OFV Patency	PSV OFV	OFV Diameter	Flow Volume at fistula site
AUC	0.841	0.726	0.891	0.651	0.874
95% CI	0.714-0.967	0.555-0.897	0.761-1.000	0.563-0.838	0.715-1.000
SE**	0.065	0.087	0.066	0.069	0.081
P-value***	< 0.001	= 0.016	< 0.001	= 0.041	< 0.001
Cut-off	94 cm/s	-----	76 cm/s	4 mm	565 ml/min.
Accuracy	79.5%	80.5%	88%	68.5%	9%
Sensitivity%	85%	89%	96%	77%	100%
Specificity%	74%	60%	80%	60%	80%
PPV%	76.5%	84%	83%	66%	83.3%
NPV%	83%	69%	95%	72%	100%

*AUC=Area under the Curve **SE=Standard Error CI=Confidence Interval ***Null hypothesis: true area=0.5 ----Sensitivity (true positives/all diseased); specificity (true negatives/all non-diseased); PPV (true positives/all test positives); NPV (true negatives/all test negatives).

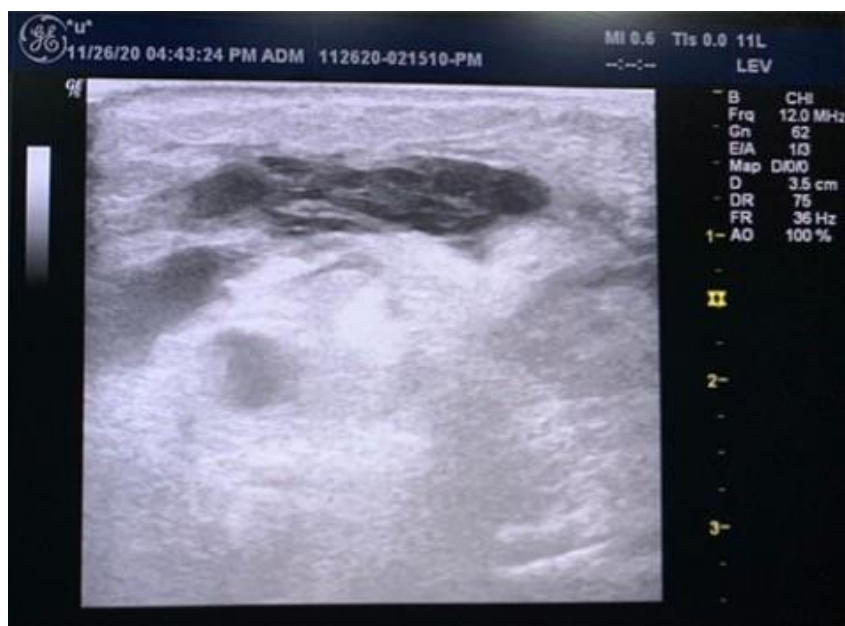

Figure (3): an examination of a 63-year-old Female patient referred to our department to check the maturity of the newly formed right brachiocephalic fistula (6 weeks duration). Faint thrill detected and intact overlying skin. No history of previous accesses. The Figure represents a grey-scale assessment of the cephalic vein in the longitudinal axis with complete thrombosis and failure to dilate.

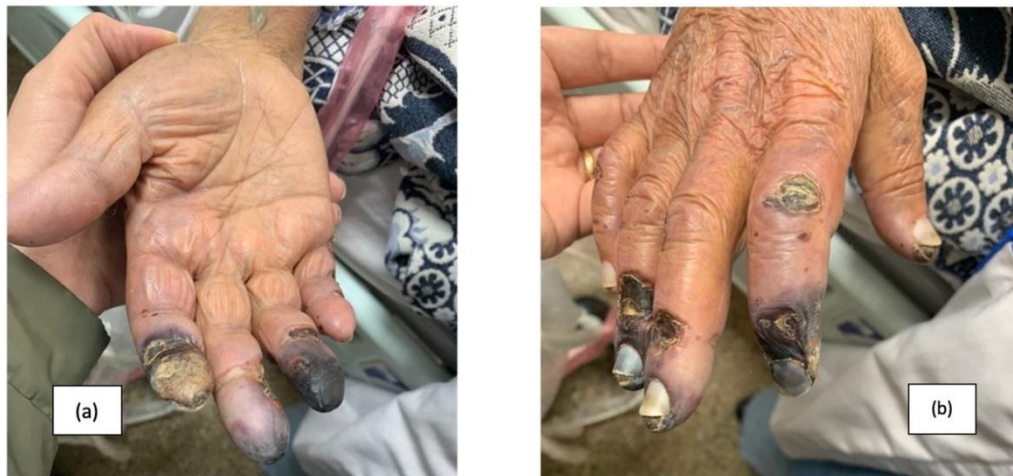

Figure (4): A 67-year-old female patient was admitted to the Critical Care Unit. The patient started to develop gangrenous fingertips of the right hand, which is known as ESRD on RD through right BC AVF; she was diagnosed with a "steal phenomenon" with very low radial and ulnar arteries PSVs on DUS; 17 and 12 cm/s, respectively. Tracing the AVF, we found a distal stenotic segment to the fistula at the outflow vein (cephalic vein).

Discussion

AVF is the preferred vascular access for hemodialysis. The maturation and maintenance of AVFs for successful hemodialysis are serious issues. Therefore, it will be extremely useful to follow well-defined criteria to help identify fistulas that are likely to fail early after creation; this will be achieved by periodic monitoring of the fistula. DUS is the most suitable tool for that (1, 2).

There were no differences in survival between RC and BC AVFs in a study done by Huber et al. (8) Through which their data support the Kidney Disease Outcomes Quality Initiative (K-DOQI) guidelines for using RC vessels first, if possible, before progressing to upper arm AVF site. This is consistent with the current study, which reported no significant site prevalence in immature/complicated cases.

The term maturation refers to developing some physical characteristics that guarantee an AVF is suitable for easy cannulation with large needles (8). The term non-maturation is the reason an AVF cannot be used. In different case series, a study by Zamboli et al. (10) stated that the incidence of failed maturation for RC AVFs ranged from 30 to 60 %, less than our study that reported that the incidence of failed maturation is 20-30%.

The purpose of our study was to test the ability of DUS examination for three important points: Firstly, tracking the procedure of fistula maturation before use as a line for dialysis; secondly, approving full maturation and ready or used fistula in the first session of dialysis (mature / well-functioning) and finally detection of complications, e.g., thrombosis either before maturation (immature complicated fistula) or after achieving maturation (mature complicated fistula).

It is known that AVF's main disadvantage is the high incidence of failed maturation, with approximately 20%–50% (one-third), according to a study done by Bashar et al. (11). Our study depicted relatively higher maturation failure (64.7%).

In the current study, the most common complication was thrombosis 36.9%, as shown in Figure (10), followed by hematomas 26.08%, then stenosis 17.3%; Figure (11). Aneurysms composed only 15.2% of all cases in our study. The least two complications reported were central venous congestion and infection, which together depicted 4.2%. This was similar to a study by Monroy-Cuadros et al., who stated that 81% of the examined patients had thrombosis (12).

The results of a study done by Cavallaro et al. were inconsistent with the

aforementioned data. They reported that the most common complication was aneurysm followed by thrombosis. (13) On the other hand, Aljuaid et al. (4) reported that the most common complication was "ischemic neuropathy" (29.6%), followed by "aneurysm at the site of AVF" (25%).

Focusing on the vein diameter and its outcome on AVF, a study by Abreu et al. (14) depicted that smaller vein diameter was a predictor of early thrombosis.

According to Farber et al. (15), the AVF maturation study showed a higher risk of failure in the 2-3mm diameter veins. The cut-off point in our study for cephalic vein diameter is 4 mm (p-value = 0.041). Moreover, with every mm decrease in outflow vein diameter, there was a 2.7 times rise in the risk of complication (OR=2.69, 95% CI: 1.01–7.17), which was statistically significant (p=0.048). Also, with every cm/s decrease in outflow vein PSV, there was a 12% reduction in the risk of complication (OR=0.88, 95% CI: 0.74–0.99), which was statistically significant (p=0.046). Moreover, patients with absent outflow vein patency were 12.6 times more liable to AVF complication (OR=12.56, 95% CI: 3.04–35.91), which was statistically significant (p=0.047).

Regarding the inflow artery diameter, in a study by Mauro et al. (16), the diameter of the stenosis area is smaller than that of the feeding artery. Our study depicted no relationship between the diameter of the artery and the diameter of the stenosed area, as causes of stenosis vary.

A study done by Ren et al. (17) found that the brachial artery diameter in the complicated group was significantly lower than that in the noncomplicated group. The incidence of AVF complications decreased as the brachial artery diameter increased, and when the brachial artery diameter was 5.40 mm, the complication incidence was high. This is inconsistent with our study because 56 mature/non-complication group cases had a brachial artery mean diameter of about 4 mm.

DUS measurement of FVs at the fistula site is perhaps the only imaging tool that can

be used to monitor the fistula, even during its maturation. (18) Conversely, in a study by Ishii et al. (19), FV of <500 mL/min in fistulas may have a high risk of thrombosis development. The validity of FV measurement is controversial; however, Aragoncillo et al. (20) study reported favorable fistula outcomes among patients in whom an FV of <500 mL on DUS was considered an indication for fistulography or surgery.

Moreover, a study by Tessitore et al. (21) stated that the incidence of stenosis was great when the FV was <650mL/min. Another study by Aragoncillo et al. (20) reported that the incidence of thrombosis was great when the FV was <500 mL/min or decreased >25%. The cut-off point was slightly lower in this study, probably due to the overall lower FVs of Chinese patients.

Furthermore, the NKF-K/DOQI clinical practice guidelines of the year 2020 for AVF maturity recommend the rule of six: A FV greater than 600 ml/min, a diameter greater than 0.6 cm, and a depth of approximately 0.6 cm (22).

This study had some limitations. Firstly, it was a cross-sectional, single-institutional study. Some complicated/immature patients may have presented elsewhere. Secondly, we utilized multiple machines to measure spectral Doppler parameters. Lastly, the study took place during the pandemic era of COVID-19, which contributed to variations in our data and small cohort sample size.

Conclusions:

Regular DUS follow-ups with FV values can predict future thrombosis and stenosis in patients with established fistulas. Also, DUS is the only tool that predicts the maturity of AVFs. The most important predictors are FV and PSV (at the access site).

In conclusion, DUS was considered a mandatory primary predictive tool to detect maturity in new cases and an early detective tool for complications in follow-up patients. The cut-off values of FV (565 ml/min) and PSV (94 cm/s) at the fistula site were good predictors for mature well-functioning AVF.

List of Abbreviations:

DUS: Doppler Ultrasound.	IQR: Interquartile Range.
AVF: Arteriovenous Fistula.	OR: Odds Ratio.
PSV: Peak Systolic Velocity.	CI: Confidence Interval.
FV: Flow Volume.	AUC: Area Under The Curve.
ESRD: End Stage Renal Disease.	SE: Standard Error.
AUH: Assiut University Hospitals	PPV: Positive Predictive Value.
US: Ultrasound.	NPV: Negative Predictive Value.
B: Brightness.	BC: Brachiocephalic
C: Color.	RC: Radiocephalic.
PW: Pulsed wave.	DBP: Diastolic Blood Pressure.
HD: Hemodialysis.	K-DOQI: Kidney Disease Outcomes Quality Initiative.
EDV: End Diastolic Velocity.	

References:

1. Richards J, Hossain M, Summers D, Slater M, Bartlett M, Kosmoliaptsis V, et al. Surveillance arterioveNous fistulAs using ultRasound (SONAR) trial in haemodialysis patients: a study protocol for a multicentre observational study. *BMJ Open*. 2019;9(7):e031210.
2. Meola M, Ibeas J, Lasalle G, Petrucci I. Basics for performing a high-quality color Doppler sonography of the vascular access. *J Vasc Access*. 2021;22(1_suppl):18–31.
3. Abdelrady A, Alsagheer M, Mbbch MA. Role of color Doppler ultrasonography in evaluation of the arteriovenous fistulae in patients with renal failure. *MJMR*. 2018;28(3):134.
4. Aljuaid MM, Alzahrani NN, Alshehri AA, Alkhalidi LH, Alosaimi FS, Aljuaid NW, et al. Complications of arteriovenous fistula in dialysis patients: Incidence and risk factors in Taif city, KSA. *J Fam Med Prim Care*. 2020;9(1):407.
5. Sars B, van der Sande FM, Kooman JP. Intradialytic hypotension: mechanisms and outcome. *Blood Purif*. 2020;49(1–2):158–67.
6. Farrington CA, Robbin ML, Lee T, Barker-Finkel J, Allon M. Early predictors of arteriovenous fistula maturation: a novel perspective on an enduring problem. *J Am Soc Nephrol JASN*. 2020;31(7):1617.
7. Hakim AJ, Brooke BS, Beckstrom JL, Sarfati MR, Kraiss LW. Rules of 6 criteria predict dialysis fistula maturation but not all rules are equal. *J Vasc Surg*. 2022;76(1):232–8.
8. Huber TS, Berceli SA, Scali ST, Neal D, Anderson EM, Allon M, et al. Arteriovenous fistula maturation, functional patency, and intervention rates. *JAMA Surg*. 2021;156(12):1111–9.
9. Besarab A. Resolved: Fistulas are preferred to grafts as initial vascular access for dialysis. *J Am Soc Nephrol*. 2008;19(9):1629–33.
10. Zamboli P, Fiorini F, D'Amelio A, Fatuzzo P, Granata A. Color Doppler ultrasound and arteriovenous fistulas for hemodialysis. *J Ultrasound*. 2014;17(4):253–63.
11. Bashar K, Healy D, Browne LD, Kheirseid EA, Walsh MT, Moloney MC, et al. Role of far infra-red therapy in dialysis arterio-venous fistula maturation and survival: systematic review and meta-analysis. *PLoS One*. 2014;9(8):e104931.
12. Monroy-Cuadros M, Yilmaz S, Salazar-Bañuelos A, Doig C. Risk factors associated with patency loss of hemodialysis vascular access within 6 months. *Clin J Am Soc Nephrol*. 2010;5(10):1787–92.
13. Cavallaro G, Taranto F, Cavallaro E, Quatra F. Vascular complications of native arteriovenous fistulas for

- hemodialysis: role of microsurgery. *Microsurgery*. 2000;20(5):252–4.
14. Abreu R, Rioja S, Vallespin J, Vinuesa X, Iglesias R, Ibeas J. Predictors of early failure and secondary patency in native arteriovenous fistulas for hemodialysis. *Int Angiol J Int Union Angiol*. 2018;37(4):310–4.
 15. Farber A, Imrey PB, Huber TS, Kaufman JM, Kraiss LW, Larive B, et al. Multiple preoperative and intraoperative factors predict early fistula thrombosis in the Hemodialysis Fistula Maturation Study. *J Vasc Surg*. 2016;63(1):163–70.
 16. Mauro R, Pini R, Faggioli G, Donati G, Facchini MG, D'Amico R, et al. Impact of duplex ultrasound surveillance program on patency of prosthetic arteriovenous graft for hemodialysis: a single-center experience. *Ann Vasc Surg*. 2015;29(6):1211–7.
 17. Ren C, Chen J, Wang Y, Huang B, Lu W, Cao Y, et al. Application of ultrasonography in monitoring the complications of autologous arteriovenous fistula in hemodialysis patients. *Medicine (Baltimore)*. 2018;97(44).
 18. Davidson I, Chan D, Dolmatch B, Hasan M, Nichols D, Saxena R, et al. Duplex ultrasound evaluation for dialysis access selection and maintenance: a practical guide. *J Vasc Access*. 2008;9(1):1–9.
 19. Ishii T, Suzuki Y, Nakayama T, Ohmori M, Masai S, Sasagawa N, et al. Duplex ultrasound for the prediction of vascular events associated with arteriovenous fistulas in hemodialysis patients. *J Vasc Access*. 2016;17(6):499–505.
 20. Aragoncillo I, Amézquita Y, Caldés S, Abad S, Vega A, Cirugeda A, et al. The impact of access blood flow surveillance on reduction of thrombosis in native arteriovenous fistula: a randomized clinical trial. *J Vasc Access*. 2016;17(1):13–9.
 21. Tessitore N, Bedogna V, Melilli E, Millardi D, Mansueto G, Lipari G, et al. In search of an optimal bedside screening program for arteriovenous fistula stenosis. *Clin J Am Soc Nephrol*. 2011;6(4):819–26.
 22. Lok CE, Huber TS, Lee T, Shenoy S, Yevzlin AS, Abreo K, et al. KDOQI clinical practice guideline for vascular access: 2019 update. *Am J Kidney Dis*. 2020;75(4):S1–164.