

PRESENCE OF MIDDLE MESIAL CANALS IN PERMANENT MANDIBULAR MOLARS USING CONE BEAM COMPUTED TOMOGRAPHY VERSUS DENTAL OPERATING MICROSCOPE (IN VITRO STUDY)

Khaled M. Abdullah^{1*} BDS, Nayera A. Mokhless² PhD, Mahmoud R. Abdolseoud³ PhD

ABSTRACT

INTRODUCTION: successful root canal therapy should access, shape and clean biomechanically the complex root canal system in a three-dimensional manner without missing any anatomical variations. Recent advancements in the radiographic imaging technology and the visual aids have enabled the precise detection of extra canals.

OBJECTIVES: To detect the presence of middle mesial canals (MM) in permanent mandibular molars using Cone Beam Computed Tomography (CBCT) versus the (Gold standard) Dental Operating Microscope (DOM).

METHODOLOGY: One hundred extracted permanent mandibular molars were collected and preoperative CBCT scans were done for all teeth. Digital periapical radiographs and conventional access cavities were done to all teeth. Initial scouting of mesial canals and the number of orifices found in the mesial roots was recorded. Access cavities were rechecked and additional canal scouting using ultrasonics in teeth in which the MM canals were not found was done. All teeth were checked under the DOM for further detection and search of the MM canals, if not found initially in the previous stages. The CBCT taken previously were checked. Recording the presence of MM canals according to CBCT readings. Readings from CBCT and DOM were compared.

RESULTS: The DOM identified MM canals in 41teeth and CBCT detected MM canals in only 14 teeth. The weighted Kappa value was 0.38 (95% CI: 0.22-0.54), indicating fair agreement between the two methods. CBCT demonstrated a sensitivity of 34.15% and a specificity of 100%. Overall accuracy of CBCT in detecting MM canals was 73%.

CONCLUSIONS: The DOM is more accurate than cone-beam computed tomography in detecting the presence of MM canals in mandibular molars.

KEYWORDS: Cone Beam Computed Tomography, Dental Operating Microscope, Middle Mesial Canals, Mandibular Molars

RUNNING TITLE: Presence of middle mesial canals in mandibular molars

1-BDS, 2013, Conservative Dentistry, Faculty of Dentistry, Pharos University, Alexandria, Egypt

2-Assistant Professor of Endodontics, Conservative Dentistry Department, Faculty of Dentistry, Alexandria University, Alexandria, Egypt

3-Lecturer in Endodontics, Conservative Dentistry Department, Faculty of Dentistry, Alexandria University, Alexandria, Egypt

**Corresponding author:*

drkhaled_abdullah@hotmail.com

INTRODUCTION

In-depth knowledge of root canal anatomy, careful radiographic examination, and modification of the conventional access cavity preparation are essential to recognize and treat teeth with complex anatomic variations (1). This is followed by negotiation, shaping and cleaning, and obturation of the entire canal system in three dimensions (2). Missed canal anatomy is considered one of the major causes for failure of the root canal treatment. According to Hoen and Pink (3) the incidence of missed roots or canals in the teeth that needed retreatment was 42%.

Complexity of internal and external anatomic variations of roots and root canals has been documented in which the first attempts were

made by Hess and Zurcher who visualized lateral canals and isthmi (4). Vertucci et al. (5, 6) suggested a classification that is still used despite the recent implementation of further subclasses.

Factors contributing to variations in the root canal anatomy of permanent teeth can be linked to ethnic background, age, and gender of the population (7).

Mandibular molars are the most teeth prone to endodontic treatment and they exhibit several variations in root canal anatomy. Mandibular molars usually have two roots and three or four root canals. However, several variations such as an additional distolingual or distobuccal root, C-shaped root canal system, and isthmuses connecting the canals may also be present (8). Moreover, sometimes a third

canal may be present in the isthmus between the MB and mesiolingual (ML) canal known as the middle mesial (MM) canal (9).

Numerous techniques have been developed and implemented to investigate root canal anatomy, such as modified canal staining techniques, digital and conventional radiography (10, 11).

Since the introduction of CBCT in dentistry, its use in endodontics was valuable. CBCT allowed for detailed visualization of the root canal system, and demonstrates anatomic features in three dimensions that intraoral and panoramic images cannot (12).

With the new advancements in visual and magnification technology currently available, the dental operating microscope is useful in locating and negotiating difficult root canal anatomy in mandibular molars, because microscopes provide 3x to 30x magnification with the ability to change views with a simple turn of a dial. Microscopes (DOM) offer a wider field of view and allow for deeper depth of view than traditional dental loupes. This allows better precision of the DOM due to the increased magnification that, allows the endodontist to access small, narrow canal opening without unnecessarily removing tooth structure (13-15).

The aim of this work was to determine whether the CBCT is reliable in detecting fine anatomical variations such as the presence of MM canal in permanent mandibular molars when compared to the DOM.

The null hypothesis of this study was that there will be no difference between the two methods in the detection of MM canals.

MATERIALS AND METHODS

This study was conducted after receiving the approval of the ethical committee at the Faculty of Dentistry, Alexandria University, Egypt (IRB 00010556 – IORG 0008839).

Sample Size Calculation: Based on previous studies (16, 17), a sample size was determined to be 100 teeth by using a power of 95% ($1 - \beta = 0.95$), a level of significance 95% ($\alpha = 0.05$).

This in vitro study was carried out on one hundred freshly extracted permanent mandibular first and second molars that were collected from the Oral and Maxillofacial Surgery Department at Alexandria University.

Teeth included were with fully formed apices, intact pulp chambers, no developmental anomalies, and absence of resorption.

After extraction, the teeth were placed in 5% sodium hypochlorite and rinsed under running tap water, then stored in physiological saline until the beginning of the experiment and throughout the study to prevent dehydration. Preoperative digital

periapical radiographs were taken for each tooth in both buccolingual and mesiodistal views to confirm adherence to the inclusion criteria.

Teeth excluded from the current study were those with fracture lines, cracks, C-shaped canals, previous root canal treatment, posts, crown restorations, or calcified canals.

Methodology

The methodology comprised five stages, each designed to progressively identify and manage the MM canals using different techniques.

The steps during conducting this in vitro study followed the Preferred Reporting Items for Laboratory studies in Endodontology (PRILE), 2021 guidelines (18). **(Figure 1)**

Initially, all teeth were scanned using CBCT. Subsequent stages involved conventional access, troughing, magnification, and final CBCT evaluation, with all findings recorded and compared as follows:

1:Preoperative CBCT Scanning: The teeth were embedded in rubber base condensation silicone (Zhermack, S.p.A., Italy) to standardize angulation. CBCT (Vatech, Korea) scans of all teeth were performed with parameters set to 90 kV, 8 mA, Endo mode 4*4 cm field of view, and a voxel size of 50 μ m. Scans were not evaluated at this stage.

2:Conventional Access and Canal Exploration: Access cavities were done for all teeth using round carbide bur #4 (SS White, NJ, USA) and Endo Z bur (Dentsply Maillefer, Switzerland). The pulp chamber was irrigated with 5% NaOCl to clear all debris and DG-16 endodontic explorer (Hu-Friedy, Chicago, IL, USA) was used to detect MB and ML canal orifices and exploration of additional MM canal in the isthmus connecting both canal orifices. **(Figure 2)**

3:Troughing, Exploration, and Microscopic Examination: Troughing was performed using ET20 D (Acteon Satelec, France) in cases where the MM canal was not visible, and the area was then explored again to locate the MM canal. K-file #8 was then introduced in the MM canal if found and coronal flaring of the MM canal was done using Sx ProTaper Gold rotary files (Dentsply Maillefer, Switzerland). **(Figure 3)**

All teeth in the previous steps were examined under the dental operating microscope (CJ-Optik GmbH & Co. KG, Germany) at various magnifications to detect and scout MM canals not found in earlier stages. **(Figure 4)**

4:CBCT Evaluation: Preoperative CBCT scans were re-evaluated by two independent specialists to determine the presence of MM canals, ensuring blinding to earlier results. Intra- and inter-examiner reliability was assessed. **(Figure 5)**

Statistical analysis

Data were analyzed using IBM SPSS for Windows (Version 22.0) and significance was inferred at p value <0.05. Frequencies, percentage, means,

standard deviation (SD), median and interquartile range (IQR) were calculated. McNemar's test was applied to analyze differences in sensitivity and specificity as measured by the DOM and CBCT. The agreement between both groups was done using weighted Kappa Coefficient. Results of CBCT were compared with the DOM using receiver operating characteristic (ROC) analysis to evaluate diagnostic ability.




Figure 1: Prile Flowchart

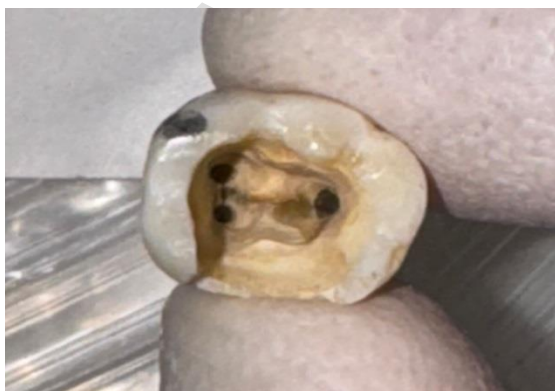

Figure 2: Access cavity of a mandibular molar with naked eye

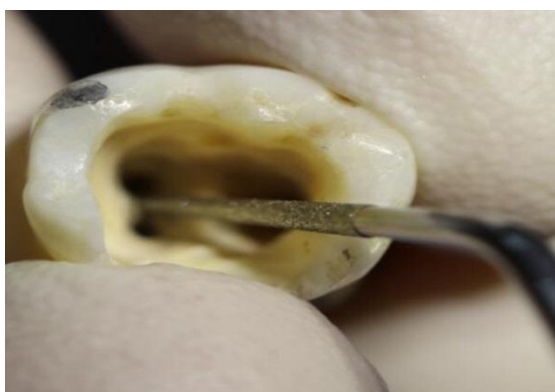

Figure 3: Troughing of the MM using an ultrasonic tip

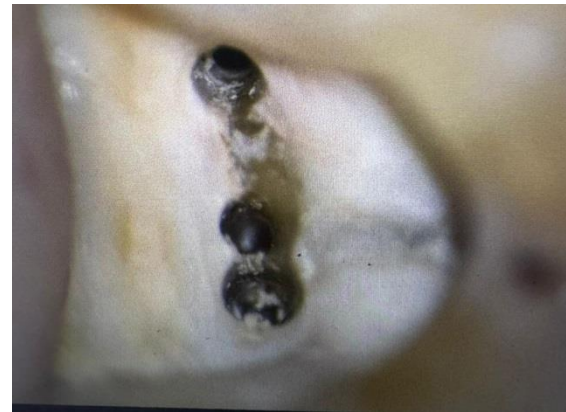

Figure 4: Microscopic view of the MM canal

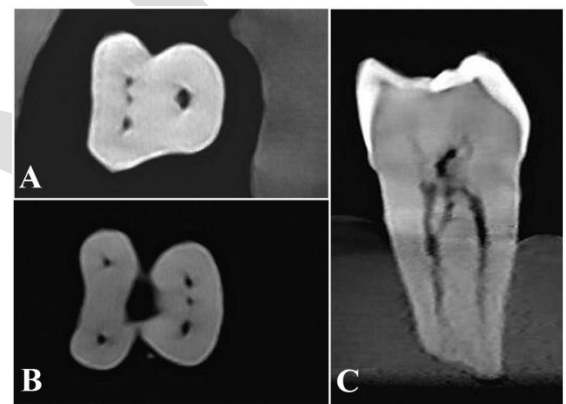


Figure 5: CBCT of MM canals (A&B) in the axial view, (C) coronal view

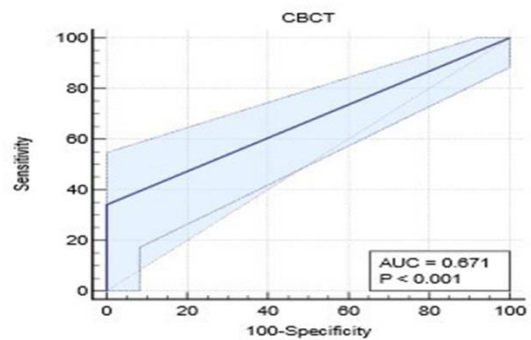


Figure 6: Accuracy of CBCT in detecting MM canals

RESULTS

Two distinct techniques were employed (DOM and CBCT) to evaluate the presence of MM canals in the mandibular molar samples. The DOM proved to be a more effective tool for identifying MM canals compared to CBCT. Specifically, the DOM identified MM canals in 41 out of the 100 teeth examined, corresponding to a detection rate of 41%. In contrast, CBCT detected MM canals in only 14 out of the 100 teeth, resulting in a significantly lower detection rate of 14%. Table 1

Comparison of DOM and CBCT Findings

The DOM and CBCT agreed on the absence of MM canals in 59 teeth (59%). However, the DOM identified MM canals in 27 teeth (27%) that were not detected by CBCT. Conversely, CBCT did not identify any MM canals that were not detected by the DOM. The difference in the detection of MM canals between the two methods was statistically significant ($P < 0.0001$). **Table 2**

Agreement between DOM and CBCT

The weighted Kappa value was 0.38 (95% CI: 0.22-0.54), indicating fair agreement between the two methods.

Diagnostic Accuracy of CBCT

CBCT demonstrated a sensitivity of 34.15% (95% CI: 20.08-50.59) and a specificity of 100% (95% CI: 93.94-100). The positive predictive value was

100% (95% CI: 76.84-100), while the negative predictive value was 68.6% (95% CI: 63.67-73.15). The overall accuracy of CBCT in detecting MM canals was 73% (95% CI: 63.20-81.39). **Table 3**

The area under the ROC curve was 0.67 (95% CI: 0.57-0.76), indicating moderate diagnostic accuracy of CBCT in detecting MM canals. **(Figure 6)**

Reliability Assessment

Calibration on was done for two examiners, intra- and inter-examiner reliability were assessed, and kappa coefficient ranged from 0.82-0.88 for DOM, and from 0.76-0.79 for CBCT indicating moderate to excellent agreement between examiners, and across time.

Table 1: Presence of middle mesial canals as measured by the DOM and CBCT

| | DOM (n=100) | CBCT (n=100) |
|-------------------|----------------|-----------------|
| Yes: n (%) | 41 (41%) | 14 (14%) |
| No: n (%) | 59 (59%) | 86 (86%) |

Table 2: Cross tabulation of presence of middle mesial canals as measured by the DOM and CBCT

| | | DOM | |
|----------------|----------|----------|----------|
| | | Negative | Positive |
| CBCT | Negative | 59 (59%) | 0 (0%) |
| | Positive | 27 (27%) | 14 (14%) |
| <i>p</i> value | | <0.0001* | |

*Statistically significant difference at p value < 0.05

Table 3: Diagnostic Accuracy of CBCT in detecting middle mesial canal in comparison to DOM

| | CBCT vs DOM | | |
|------------------------|-------------|-------------|-------------|
| | Value | 95% CI | |
| | | Lower limit | Upper limit |
| Sensitivity | 34.15% | 20.08 | 50.59 |
| Specificity | 100% | 93.94 | 100 |
| +Ve Predictive Value | 100% | 76.84 | 100 |
| -Ve Predictive Value | 68.6% | 63.67 | 73.15 |
| Accuracy | 73% | 63.20 | 81.39 |
| Area Under Curve (AUC) | 0.67 | 0.57 | 0.76 |

DISCUSSION

The present study was conducted to investigate the detection and scouting of MM canals in mandibular molars. The accurate detection and proper management of the root canal system is crucial for the success of endodontic treatment (19). The MM canal, a common anatomical variation in mandibular molars, poses a significant challenge for clinicians due to its complex morphology and location (20). This study aimed to compare the diagnostic accuracy of the CBCT to the DOM in

detecting fine anatomical variations such as the presence of MM canals in mandibular molars.

CBCT offers several significant advantages that are crucial in the field of endodontics. One of the primary benefits of CBCT is its ability to provide three-dimensional imaging, allowing clinicians to visualize the root canal system from multiple angles and obtain a comprehensive understanding of the tooth's anatomy. This can be particularly beneficial in complex cases where conventional two-

dimensional imaging might not reveal the full extent of anatomical variations or pathologies (12).

In the present study, the DOM detected MM canals in 41% of the examined teeth, while CBCT detected 14% only, this discrepancy can be attributed to the enhanced visualization and magnification capabilities of the DOM, which facilitate the identification of intricate anatomical details (21). Conversely, CBCT failed to detect these challenging anatomical variations which may be due to the inherent limitations of this imaging modality, such as potential artifacts or the inability to resolve fine anatomical structures with the same level of detail as the DOM (22).

The results of our study are in line with Versiani et al. (20) who reported in a micro-CT study that the prevalence of MM canals was 42.9% in a Turkish population, although their method of assessment was different.

The present study evaluated the diagnostic accuracy of CBCT in detecting MM canals, using the DOM as the reference standard. The results revealed a sensitivity of 34.15% and a specificity of 100% for CBCT, indicating its limited ability to accurately identify these anatomical variations. The overall accuracy of CBCT in detecting MM canals was 73%.

Numerous studies have consistently shown that the DOM improves the detection and management of additional canals in various tooth types (23-25). For instance, Kar et al. (23) reported that the incidence of MM canals detected using the DOM was 10%, compared to 7.5% when using CBCT. Similarly, Sherwani et al. (24) found that 28.3% of mandibular first molars exhibited negotiable MM canals when inspected under the DOM. Furthermore, Prade et al. (25) demonstrated that the use of DOM with ultrasonic troughing increased the detection rate of MM canals from 9.52% to 12.38%.

The superior performance of the DOM in detecting MM canals can be attributed to several factors. First, the enhanced visualization and magnification provided by the DOM allow for a more detailed examination of the pulp chamber floor, enabling the identification of subtle anatomical features that may indicate the presence of additional canals (26). Second, the DOM facilitates the use of specialized instruments, such as ultrasonic tips and micro-openers, which can aid in the exploration and negotiation of these intricate anatomical structures (27). Third, the DOM provides improved ergonomics and illumination, reducing eye strain and fatigue, which can contribute to better detection rates (21).

CBCT has certain limitations, primarily due to its lower resolution compared to the high magnification offered by dental operating microscopes. CBCT images can suffer from artifacts and noise, which can obscure fine anatomical details, making it challenging to

identify small or intricate structures like MM canals. Additionally, the voxel size in CBCT, although relatively small, may not be sufficient to capture the minute variations and complexities of root canal anatomy (28,29). In the present study, a smaller voxel size and a more focused field of view were utilized compared to other studies. The use of a smaller voxel size was intended to enhance the resolution and detail of the CBCT images, theoretically improving the detection of MM canals. Despite these optimized parameters, the detection rate of MM canals using CBCT in our study was not significantly improved. This outcome suggests that even with better imaging parameters, the inherent limitations of CBCT, such as its resolution capabilities and susceptibility to artifacts, still hinder its effectiveness in identifying these challenging anatomical variations. These factors contribute to the reduced sensitivity of CBCT in detecting MM canals, as evidenced by the current results.

While the present study highlights the diagnostic limitations of CBCT in detecting MM canals, it is important to note that CBCT remains a valuable diagnostic tool in endodontics, particularly for preoperative assessment of root canal anatomy, identification of additional roots or canals, and evaluation of periapical lesions (30, 31). Another significant advantage of CBCT is its capability to provide multiplanar imaging, allowing for the visualization of anatomical structures in various planes, such as coronal, axial, and sagittal. This feature clinicians to thoroughly examine the root canal system from multiple perspectives, which is not possible with conventional two-dimensional imaging techniques. Viewing the root canal anatomy in different planes helps in identifying complex canal configurations, locating additional canals, and assessing the spatial relationships between root canals and surrounding structures. This comprehensive visualization aids in accurate diagnosis, treatment planning, and the assessment of treatment outcomes (32). However, the findings of this present study suggest that CBCT should be used in conjunction with other diagnostic methods, such as the DOM and careful clinical examination, to enhance the detection and management of MM canals, accordingly the null hypothesis for this study was accepted.

It is worth mentioning that this study had some limitations as the sample size was relatively small and the use of extracted teeth may not fully represent the clinical scenario, as factors such as patient-related variables and the presence of restorations or caries can influence the detection of MM canals (33). In a clinical setting, the visibility and accessibility of the pulp chamber floor can be compromised by existing restorations, caries, or calcifications, potentially hindering the identification of additional canals. Furthermore,

patient-related factors, such as anatomical variations and the presence of preoperative pain or infection, may impact the detection and management of MM canals. Although micro-CT is considered the gold standard radiographic technique for detection of fine anatomical variants, it was not used in the current study as it is not available in Egypt. Finally, the reliability and validation of cbct in detecting MM canals should be compared to the high resolution micro-CT radiographic technique, and it is recommended that further research should be conducted using micro-CT to validate the accuracy of DOM in detecting MM canals as well.

CONCLUSIONS

The DOM is more effective than cone-beam computed tomography in detecting the presence of MM canals in mandibular molars. The enhanced visualization and magnification provided by the DOM enable the identification and management of these challenging anatomical variations, potentially improving treatment outcomes and reducing the risk of failures associated with missed canals.

CONFLICT OF INTEREST

The authors declare that they have no conflict of interest.

FUNDING STATEMENT

The authors received no specific funding for this work

REFERENCES

- de Oliveira SH, de Moraes LC, Faig-Leite H, Camargo SE, Camargo CH. In vitro incidence of root canal bifurcation in mandibular incisors by radiovisiography. *J Appl Oral Sci.* 2009;17:234-9.
- Ingle JJ. A standardized endodontic technique utilizing newly designed instruments and filling materials. *Oral Surg Oral Med Oral Pathol.* 1961;14:83-91.
- Hoehn MM, Pink FE. Contemporary endodontic retreatments: an analysis based on clinical treatment findings. *J Endod.* 2002;28:834-6.
- Hess W, Zürcher E. The anatomy of the root-canals of the teeth of the permanent dentition: J. Bale, sons & Danielsson, Limited; 1925.
- Vertucci F, Seelig A, Gillis R. Root canal morphology of the human maxillary second premolar. *Oral Surg Oral Med Oral Pathol.* 1974;38:456-64.
- Vertucci FJ. Root canal anatomy of the human permanent teeth. *Oral Surg Oral Med Oral Pathol.* 1984;58:589-99.
- Cleghorn BM, Christie WH, Dong CC. The root and root canal morphology of the human mandibular first premolar: a literature review. *J Endod.* 2007;33:509-16.
- Garg AK, Tewari RK, Kumar A, Hashmi SH, Agrawal N, Mishra SK. Prevalence of three-rooted mandibular permanent first molars among the Indian population. *J Endod.* 2010;36:1302-6.
- Ahmed SAB, Pawar MG. An in vivo study of variations in the canal anatomy of maxillary and mandibular first molar using surgical operating microscope. *World J Dent.* 2013;4:47-55.
- Weng XL, Yu SB, Zhao SL, Wang HG, Mu T, Tang RY, et al. Root canal morphology of permanent maxillary teeth in the Han nationality in Chinese Guanzhong area: a new modified root canal staining technique. *J Endod.* 2009;35:651-6.
- Pattanshetti N, Gaidhane M, Al Kandari AM. Root and canal morphology of the mesiobuccal and distal roots of permanent first molars in a Kuwait population--a clinical study. *Int Endod J.* 2008;41:755-62.
- D'Addazio PS, Campos CN, Özcan M, Teixeira HG, Passoni RM, Carvalho AC. A comparative study between cone-beam computed tomography and periapical radiographs in the diagnosis of simulated endodontic complications. *Int Endod J.* 2011;44:218-24.
- Srinivasan R, Ravishanker P. Management of middle mesial canal under dental operating microscope. *Med J Armed Forces India.* 2015;71:S502-5.
- Chavda S, Garg S. Advanced methods for identification of middle mesial canal in mandibular molars: An in vitro study. *Endodontology.* 2016;28:92-6.
- Honap MN, Devadiga D, Hegde MN. To assess the occurrence of middle mesial canal using cone-beam computed tomography and dental operating microscope: An in vitro study. *J Conserv Dent.* 2020;23:51-6.
- Liao JJ. Sample size calculation for an agreement study. *Pharm Stat.* 2010;9:125-32.
- Pannucci CJ, Wilkins EG. Identifying and avoiding bias in research. *Plast Reconstr Surg.* 2010;126:619-25.
- Nagendrababu V, Murray PE, Ordinola-Zapata R, Peters OA, Rôças IN, Siqueira JF Jr, et al. PRILE 2021 guidelines for reporting laboratory studies in Endodontology: A consensus-based development. *Int Endod J.* 2021;54:1482-90.
- Vertucci FJ. Root canal morphology and its relationship to endodontic procedures. *Endodo Topics.* 2005;10:3-29.
- Versiani MA, Ordinola-Zapata R, Keleş A, Alcin H, Bramante CM, Pécora JD, et al. Middle mesial canals in mandibular first molars: A micro-CT study in different populations. *Arch Oral Biol.* 2016;61:130-7.
- Carr GB, Murgel CA. The use of the operating microscope in endodontics. *Den Clin N Am.* 2010;54:191.
- Vizzotto M, Silveira P, Arús N, Montagner F, Gomes B, Silveira Hd. CBCT for the

- assessment of second mesiobuccal (MB 2) canals in maxillary molar teeth: effect of voxel size and presence of root filling. *Int Endod J*. 2013;46:870-6.
23. Kar S, Bera S, Maity A, Pal P, Das G, Singh, A. Assessment of the occurrence of middle mesial canal in mandibular molars using cone-beam computed tomography and dental operating microscope: An in vitro study. *Glob J Res Anal*. 2022;11:42-4.
 24. Sherwani OA, Kumar A, Tewari RK, Mishra SK, Andrabi SM, Alam S. Frequency of middle mesial canals in mandibular first molars in North Indian population-An in vivo study. *Saudi Endod J*. 2016;6:66-70.
 25. Prade AC, Mostardeiro RDT, Tibúrcio-Machado CDS, Morgental RD, Bier CAS. Detectability of Middle Mesial Canal in Mandibular Molar After Troughing Using Ultrasonics and Magnification: An Ex Vivo Study. *Braz Dent J*. 2019;30:227-31.
 26. Karapinar-Kazandag M, Basrani BR, Friedman S. The operating microscope enhances detection and negotiation of accessory mesial canals in mandibular molars. *J Endod*. 2010;36:1289-94.
 27. Azim AA, Deutsch AS, Solomon CS. Prevalence of middle mesial canals in mandibular molars after guided troughing under high magnification: an in vivo investigation. *J Endod*. 2015;41:164-8.
 28. Nagarajappa AK, Dwivedi N, Tiwari R. Artifacts: The downturn of CBCT image. *J Int Soc Prev Community Dent*. 2015;5:440-5.
 29. Ríos-Osorio N, Quijano-Guauque S, Briñez-Rodríguez S, Velasco-Flechas G, Muñoz-Solís A, Chávez C, et al. Cone-beam computed tomography in endodontics: from the specific technical considerations of acquisition parameters and interpretation to advanced clinical applications. *Restor Dent Endod*. 2023;49:e1.
 30. Matherne RP, Angelopoulos C, Kulild JC, Tira D. Use of cone-beam computed tomography to identify root canal systems in vitro. *J Endod*. 2008;34:87-9.
 31. Cotton TP, Geisler TM, Holden DT, Schwartz SA, Schindler WG. Endodontic applications of cone-beam volumetric tomography. *J Endod*. 2007;33:1121-32.
 32. Venkatesh E, Elluru SV. Cone beam computed tomography: basics and applications in dentistry. *J Istanbul Univ Fac Dent*. 2017;51:S102-21.
 33. Krasner P, Rankow HJ. Anatomy of the pulp-chamber floor. *J Endod*. 2004;30:5-16.