

## Assessment of Choroidal Thickness in Primary Open Angle Glaucoma Patients; an OCT Study

Ashraf H. El-Habbak, Mohamed A. Awwad, Heba M. Abdallah

Department of Ophthalmology  
Faculty of Medicine; Benha  
University. Egypt.

**Correspondence to:** Heba M. Abdallah, Department of Ophthalmology Faculty of Medicine; Benha University. Egypt.

**Email:**

mostafaali1257@gmail.com

**Received:**

**Accepted**

### Abstract

**Background:** There has been increasing interest in investigating the role of choroids in the pathogenesis of glaucomatous optic neuropathy. **Purpose:** To assess the choroidal thickness of patients with primary open-angle glaucoma using Optical Coherence tomography (OCT) and compare it with that of healthy subjects. **Patients and methods:** Our study included 50 participants above 18 years of age. Twenty-five 25 participants with healthy eyes (15 male and 10 female) as a control group (**Group A**) and 25 participants (9 female and 16 male) with eyes suffering from Primary open-angle glaucoma (**Group B**). All patients signed a written general consent form to participate in the study. A T-test at  $P < 0.05$  was used to compare Group A and Group B. Measurement of the subfoveal choroidal thickness was done using OCT-A. **Results:** Our results indicated that Group A belongs to the normal IOP group while Group B is POAG group. In POAG patients, there was a significant negative correlation between SFCT and age ( $r = -0.760$ ,  $P < 0.001$ ) and axial length ( $r = -0.482$ ,  $P = 0.015$ ) while there was a significant positive correlation between SFCT and temporal thickness at 1- ( $r = 0.997$ ,  $P < 0.001$ ) and 3-mm ( $r = 0.996$ ,  $P < 0.001$ ), nasal thickness at 1- ( $r = 0.987$ ,  $P < 0.001$ ) and 3-mm ( $r = 0.985$ ,  $P < 0.001$ ), and MCT ( $r = 0.997$ ,  $P < 0.001$ ). **Conclusion:** Primary open-angle glaucoma patients have a thinner choroidal thickness than normal subjects. Age and axial length were the main factors affecting choroidal thickness in these patients.

**Keywords:** Choroidal thickness, primary open-angle glaucoma, optical coherence tomography, IOP.

## Introduction

Primary open-angle glaucoma (OAG) represents the second leading cause of blindness worldwide. OAG is a primary chronic optic neuropathy characterized by an open angle of the eye, loss of retinal ganglion cells, and associated progressive and irreversible vision loss.[1]

The main goals of OAG treatment are to lower IOP into a target range to prevent progressive visual field, optic nerve, and retinal nerve fiber layer (RNFL) damage and preserve visual function and quality of life.[2]

There has been increasing interest in investigating the role of the choroid in the pathogenesis of glaucomatous optic neuropathy (GON). Previous studies have found an association between GON and impaired choroidal circulation or blood flow to the optic nerve head (ONH)[3]

As with RNFL thickness, the choroid tissue depth is largely seen as a biomarker of healthy functional tissue margins. Physiologically, the choroid encompasses most of the blood flow to the eye, and the retinal pigment epithelium distinctly depends on the choriocapillaris for its perfusion and metabolism [4,5]

Choroidal thickness, the distance between the retinal pigment epithelium and the sclera, varies across different eye regions and among individuals. Optical coherence tomography (OCT) has revolutionized the measurement of choroidal thickness. Variations in choroidal thickness are influenced by

factors such as age, axial length, and ocular pathology .[6]

Optical coherence tomography (OCT) parallels medical ultrasound due to its analogous operational principles. Both techniques direct waves towards the target tissue, where the waves reflect off tissue structures. By analyzing the echoes and measuring their delay, the depth of the reflecting structure is determined. In OCT, near-infrared light offers a swifter propagation than ultrasound. Direct measurement of back-reflected wave delays is impractical, necessitating a reference measurement. This is achieved through an interferometer, which splits the light into two paths: one directed towards the sample and the other towards a reference arm of known length.[7]

As one of the objective biomarkers for the evaluation of choroid, Choroidal thickness is dependent on the physiological and pathological factors of the body and varies with age, refractive, axial length, or diurnal variation. Many studies have confirmed that age and axial length are the primary factors influencing ChT, and both are negatively correlated with Choroidal thickness.[8,9]

Nevertheless, disruptions in choroidal blood flow and function, stemming from the neurodegenerative changes observed in glaucoma, can have profound consequences. As retinal ganglion cells and their axons degenerate, they may no longer transmit signals that prompt appropriate adjustments in choroidal blood flow. This disruption in the coordination

between neural activity and blood flow regulation may result in inadequate oxygen and nutrient delivery to the outer retina, potentially contributing to the progression of glaucoma [10].

## Patients and Methods

Our study was a comparative case-control study, involved adult patients collected from the outpatient ophthalmic clinic of Benha University Hospital from February 2023 to December 2023

### Sample size:

The sample size was calculated using the G\* power program version 3.1.9.4, and based on that, the effect size between open-angle glaucoma patients and the control group was 0.8.

So, the sample size was 50 (25 in each group). Sample size was calculated with confidence level 95% and power 80%.

### Participant selection:

Participants for this study were selected using a systematic random sampling technique. Initially, a complete list of eligible individuals was obtained. From this list, every 5<sup>th</sup> individual was chosen to participate, where five were determined by dividing the total number of eligible individuals by the desired sample size. This approach ensured that everyone had an equal and unbiased chance of being included in the study, thereby enhancing the representativeness and generalizability of the findings.

This study included 25 participants with healthy eyes; they were selected as a

control group (**Group A**). In addition, 25 participants with eyes suffering from Primary Open Angle Glaucoma were selected as **Group B**. Written informed consents were obtained from all participants. The study was approved by the ethics committee on research involving human subjects of Benha faculty of Medicine.

### Inclusion criteria:

**Control group (Group A):** Age: >18 years. No previous history of intra ocular surgery. No family history of glaucoma. Normal intra ocular pressure not more than 21 mmHg.

**Patient group (Group B):** Age: >18 years. Previously diagnosed with primary open angle glaucoma by measuring IOP, fundus examination, visual field test, O.C.T of optic disc and gonioscopy of angle of anterior chamber.

**Exclusion criteria for both groups were** Patients on systemic or topical steroid therapy, undergoing complicated ocular surgery, patients have systemic disease that affects IOP, corneal pathology or surgery that might influence the study, uncontrolled IOP, any drugs causing elevations of IOP, allergy to mydriatic agents and topical anaesthetic drops.

**Each patient was subjected to the following:**

**Full history taking:** Including personal, present, past and family history as well as other ocular diseases or operations.

### **Clinical examination:**

**Ocular examination:** Examination of lids, orbit, lacrimal system and ocular motility. Visual acuity assessment: unaided and best corrected. Using Snellen chart to measure VA.

**a. a-Slit-Lamp bio-microscopic**

**examination:** Full examination of the anterior segment was performed for cornea, sclera, anterior chamber, iris, pupil and lens.

**b. b-Intra-ocular pressure**

**measurement:** Using Goldmann Applanation Tonometer.

**c. c-Fundus examination:**

Using indirect ophthalmoscope. Non-contact double aspheric biconvex lens.(Volk's lens, +90)

**d. d-Gonioscopic examination:**

Using Gonioscopy Goldmann 3-mirror lens.

**e. e-Optical coherence Tomography**

**Angiography (OCT-A)** macular cube scan 6mm x 6mm manually measuring Choroidal thickness from Retinal Pigment epithelium (RPE) to large vessels using optovue OCT-A (Angio Vue; optovue Inc, Fremont,(California, USA)

**Approval code : MS 21-12-2022**

### **Statistical design:**

Statistical analysis was done by SPSS v26 (IBM Inc., Armonk, NY, USA).

Shapiro-Wilks test and histograms were used to evaluate the normality of the distribution of data.

Quantitative parametric data were presented as mean and standard deviation (SD) and were analyzed by unpaired student t-test. Quantitative non-parametric data were presented as the median and interquartile range (IQR) and were analyzed by Mann Whitney-test.

Qualitative data were presented as frequency and percentage (%) and were analyzed using the Chi-square test or Fisher's exact test when appropriate.

Pearson's correlation was performed to estimate the degree of correlation between two quantitative parametric variables.

Spearman's correlation was performed to estimate the degree of correlation between two quantitative non-parametric variables.

A two-tailed P value  $\leq 0.05$  was considered statistically significant.

### **Results**

This case-control study was carried out on 50 subjects at the outpatient ophthalmic clinic of Banha University Hospital.

#### **They were divided into two groups:**

- **Group 1:** 25 healthy individuals.
- **Group 2:** 25 POAG patients.

PSD was significantly higher in POAG patients group 2 than healthy individuals group 1 (**Table 1 Figure 1**).

SFCT was significantly lower in POAG patients (group 2) than in healthy participants (group 1) (P values =0.024,

0.032, and 0.039, respectively). (**Table 2, Figure 2**). In POAG patients, there was a significant negative correlation between SFCT and age ( $r = -0.760$ ,  $P$

$<0.001$ ) and axial length ( $r = -0.482$ ,  $P = 0.015$ ) (**Table 3, Figure 3 – Figure 4**).

**Table 1:** Ophthalmic examination of the studied groups.

		Group 1 (n=25)	Group 2 (n=25)	P value
BCVA (LogMAR)	Median	0.6	0.6	0.463
	IQR	0.15 - 0.64	0 - 0.6	
Axial length (mm)	Mean $\pm$ SD	23.44 $\pm$ 0.82	23.64 $\pm$ 1.08	0.463
	Range	22 - 25	22 - 25	
IOP (mmHg)	Mean $\pm$ SD	15.24 $\pm$ 4.17	25.72 $\pm$ 4.14	<b>&lt;0.001*</b>
	Range	9 - 20	21 - 30	
MD (dB)	Median	0.11	-1.4	0.485
	IQR	-0.76 - 0.6	-4 - -2.1	
PSD (dB)	Median	1.7	5.7	<b>&lt;0.001*</b>
	IQR	1.3 - 2.2	3.4 - 8.2	
Refractive error (D)	Median	0	0	0.915
	IQR	-1.2 - 0.8	-1.4 - 0.8	

BCVA: best-corrected visual acuity, IOP: intraocular pressure, MD: mean deviation, PSD: pattern standard deviation, \*: significant as  $P$  value  $\leq 0.05$

BCVA was insignificantly different between the studied groups.

IOP and PSD were significantly higher in POAG patients (group 2) than in healthy participants (group 1) ( $P$  value  $<0.001$ )

**Table 2:** Adjusted choroidal thickness of the studied groups.

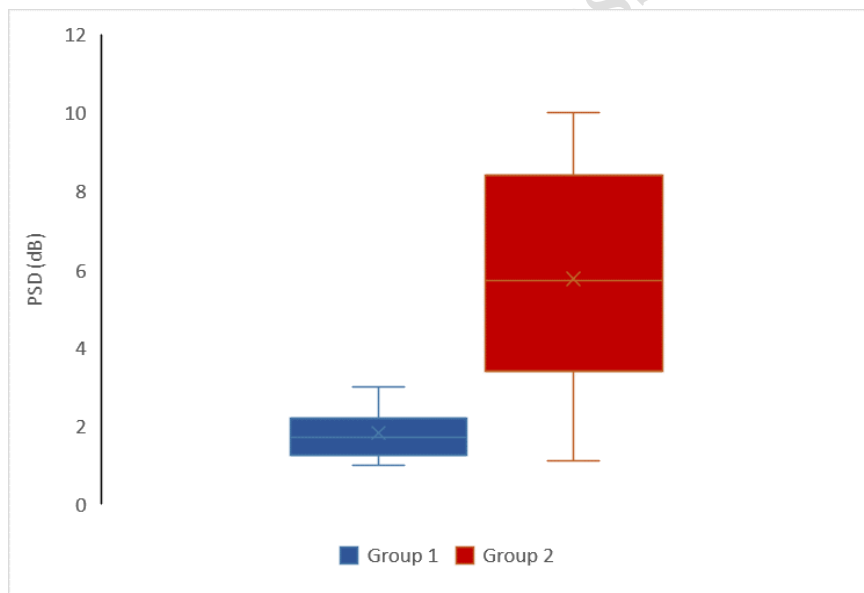
		Group 1 (n=25)	Group 2 (n=25)	P value
SFCT	Mean $\pm$ SD	241.52 $\pm$ 39.58	216.76 $\pm$ 35.23	<b>0.024*</b>
	Range	174 - 304	159 - 270	
Temporal at 1mm	Mean $\pm$ SD	240.72 $\pm$ 39.76	217.2 $\pm$ 35.56	<b>0.032*</b>
	Range	175 - 301	156 - 275	
Temporal at 3mm	Mean $\pm$ SD	223.4 $\pm$ 40.44	200.68 $\pm$ 35.11	<b>0.039*</b>
	Range	157 - 285	140 - 258	
Nasal at 1mm	Mean $\pm$ SD	222.8 $\pm$ 39.73	210.48 $\pm$ 35.19	0.252
	Range	156 - 277	158 - 269	
Nasal at 3mm	Mean $\pm$ SD	205.24 $\pm$ 39.63	192.48 $\pm$ 35.16	0.234
	Range	140 - 262	139 - 250	
MCT	Mean $\pm$ SD	226.74 $\pm$ 39.49	207.52 $\pm$ 35.11	0.075
	Range	162.2 - 285.6	150.4 - 264.4	

SFCT: subfoveal choroidal thickness, MCT: macular choroidal thickness, \*: significant as  $P$  value  $\leq 0.05$

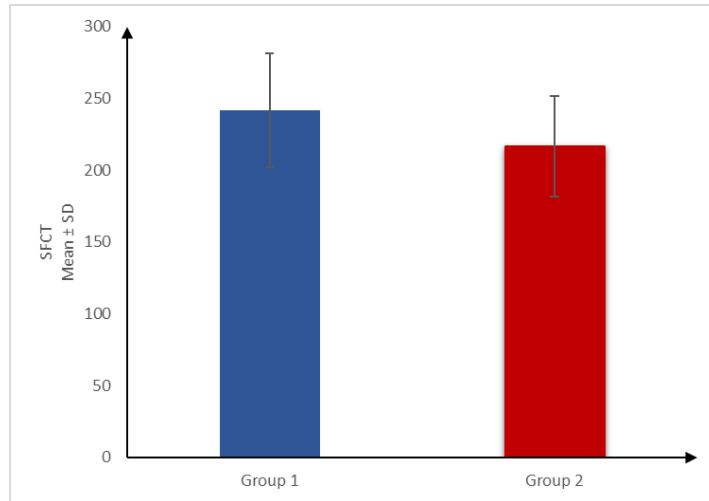
**Table 3:** Correlation between SFCT and different parameters in POAG patients.

	SFCT	P value
	r	
Age (years)	-0.760	<0.001*
SBP (mmHg)	-0.278	0.179
DBP (mmHg)	-0.315	0.126
BCVA (LogMAR)	0.098	0.643
Axial length (mm)	-0.482	<b>0.015*</b>
IOP (mmHg)	-0.311	0.130
MD (dB)	-0.107	0.610
PSD (dB)	-0.368	0.070
Refractive error (D)	0.010	0.964
Temporal thickness at 1mm	0.997	<0.001*
Temporal thickness at 3mm	0.996	<0.001*
Nasal thickness at 1mm	0.987	<0.001*
Nasal thickness at 3mm	0.985	<0.001*
MCT	0.997	<0.001*

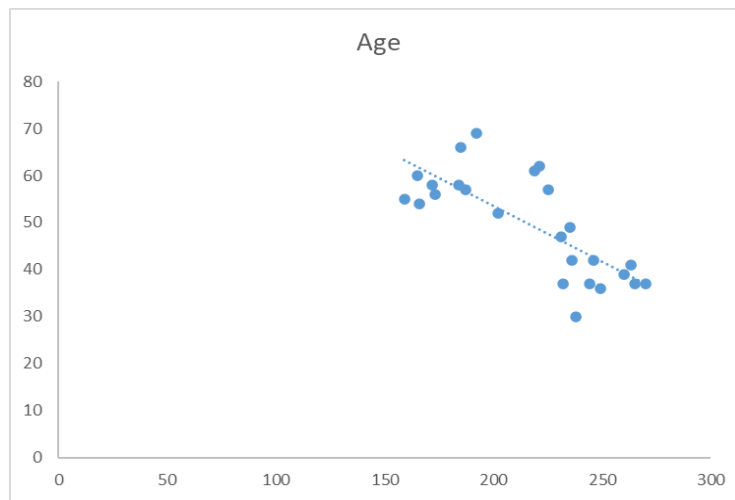
POAG: primary open-angle glaucoma, SBP: systolic blood pressure, DBP: diastolic blood pressure, BCVA: best-corrected visual acuity, IOP: intraocular pressure, MD: mean deviation, PSD: pattern standard deviation, SFCT: subfoveal choroidal thickness, MCT: macular choroidal thickness, \*: significant as P value  $\leq 0.05$ , r: correlation coefficient



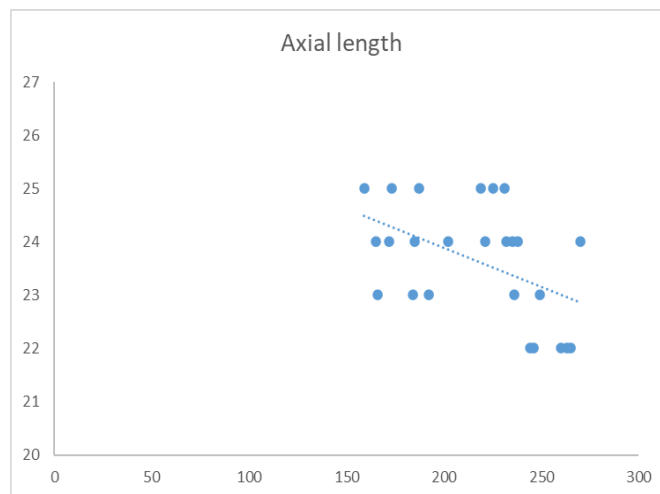
**Figure 1:** PSD of the studied groups.



**Figure 2:** SFCT of the studied groups.



**Figure 3:** Correlation between SFCT and age in POAG patients.



**Figure 4:** Correlation between SFCT and axial length in POAG patients.

## Discussion

Choroid tissue depth is essentially a biomarker of healthy functional tissue margins. Physiologically, choroids encompass most of the blood flow to the eye, and the retinal pigment epithelium distinctly depends on the choriocapillaris for its perfusion and metabolism. The relative weight of choroidal tissue's vascular and/or structural insult to the glaucomatous process has been discussed for many decades; however, it has been historically difficult to image and quantify choroidal tissue due to its deep orbital anatomical location.[11]

Only over the past decade have advances in optical coherence tomography (OCT), OCT angiography (OCTA), and applications of enhanced depth imaging (EDI) allowed for the quantification of CT in human subjects. EDI-OCTA has provided a methodology for pilot studies to quantify CT and investigate its association with certain aspects of glaucoma.[12]

In the present study, it was found that IOP and PSD were significantly higher in POAG patients.

Axial length, refractive error and BCVA were insignificantly different between the studied groups. SFCT and temporal thickness at 1- and 3-mm were significantly lower in POAG patients (group 2) than in normal cases (group 1) (P value = 0.024, 0.032, and 0.039, respectively). Nasal thickness at 1- and 3-mm and MCT insignificantly differed between the studied groups.

Parallel to our results, Li et al. conducted a retrospective, comparative, cross-sectional study about thirty-one POAG patients with unilateral visual field loss and 31 healthy controls were included. Eyes were divided into three groups: 31 eyes in group A (eyes with visual field loss), 31 eyes in group B (perimetrically unaffected fellow eyes), and 31 eyes in group C (age- and sex-matched controls) to investigate whether peripapillary choroidal thickness in perimetrically affected eyes of primary open-angle glaucoma (POAG) patients differs from that in perimetrically unaffected fellow eyes and eyes of healthy controls.[13]. They found a significant difference between glaucoma and control groups before and after adjusting for age and axial length; in glaucoma patients, the mean adjusted SFCT was 209.90  $\mu\text{m}$  (193.19 to 226.61  $\mu\text{m}$ , 95% CI) compared with 234.78  $\mu\text{m}$  (218.08 to 251.49  $\mu\text{m}$ , 95% CI) in control subjects (P = 0.042.[14], [15], [16]

On the other hand, Yin and associates [17] found a widespread thinner choroid in 25 postmortem POAG eyes compared with normal controls. [17] Conversely, Spraul and associates [18] histologically detected significant thickening of the choroid in POAG [18]

In most publications, there was no significant difference between the macular choroidal thickness values of patients with glaucoma compared to those in the control group. However, the vascular theory of glaucoma suggests that ischemia occurs in the prelaminar area of the optic nerve. The



blood supply of this region is derived from the branches within the peripapillary choroid. In addition, glaucoma is often a disease of focal damage, such as disc rim thinning in the inferotemporal or superotemporal regions. Thus, peripapillary choroidal thickness may be more likely to be involved in glaucoma. To date, studies have reported on peripapillary choroidal thickness as measured by OCT in eyes with glaucoma [19].

The mixed results of those reports justify the need for more studies in this area .

## Conclusion

Our statistical analysis showed that Primary open-angle glaucoma patients have a thinner choroidal thickness than normal subjects. Age and axial length were the main factors affecting choroidal thickness in these patients. Further studies with long-term follow-up and research were suggested to confirm our results.

## Reference

1. **Quigley HA, Broman AT.** The number of people with glaucoma worldwide in 2010 and 2020. *Br J Ophthalmol.* 2006, 90:262-7.10.1136/bjo.2005.081224.
2. **Tham Y.C., Li X., Wong T.Y., Quigley H.A., Aung T., Cheng C.Y.** Global prevalence of glaucoma and projections of glaucoma burden, A systematic review and meta-analysis. *Ophthalmology*:2014;121:2081–2090. doi: 10.1016/j.ophtha. 2014.05.013.
3. **GALASSI F., SODI A., UCCI F.:** 'Ocular hemodynamics and glaucoma prognosis: A color Doppler imaging study', *Arch. Ophthalmol.*, 2006.121: 1711-1715,.
4. **Weinreb, R. N., Leung, C. K. S., Crowston, J. G., Medeiros, F. A., Friedman, D. S., Wiggs, J. L., & Martin, K. R.** Primary open-angle glaucoma. *Nature reviews Disease primers*, 2016.2(1), 1-19 .
5. **Weinreb, R.N.; Aung, T.; Medeiros, F.A.** **The pathophysiology and treatment of glaucoma: A review.** *JAMA* 2014, 311, 1901–1911. [CrossRef] [PubMed].
6. **Abdolrahimzadeh, S., Parisi, F., Scavella, V., & Recupero, S. M.** Optical coherence tomography evidence on the correlation of choroidal thickness and age with vascularized retinal layers in normal eyes. *Retina*, 2016.36(12), 2329-2338 .
7. **Santarelli, M. F., Giovannetti, G., Hartwig, V., Celi, S., Positano, V., & Landini, L.** The core of medical imaging: State of the art and perspectives on the detectors. *Electronics*, 2021.10(14), 1642 .
8. **Spaide, R. F.** Age-related choroidal atrophy. *Am J Ophthalmol*, 2009.147, 801-10
9. **Spaide, R. F., Koizumi, H. & Pozonni, M. C.** Enhanced depth imaging spectral-domain optical coherence tomography. *Am J Ophthalmol*, 2008. 146, 496-500.
10. **Shalaby, W. S., Ahmed, O. M., Waisbourd, M., & Katz, L. J.** A review of potential novel glaucoma therapeutic options independent of intraocular pressure. *Survey of Ophthalmology*, 2022. 67(4), 1062-1080.
11. **Liu, L., Jia, Y., Takusagawa, H. L., Pechauer, A. D., Edmunds, B., Lombardi, L.** Optical coherence tomography angiography of the peripapillary retina in glaucoma. *JAMA Ophthalmol*, 2015.133, 1045-52.
12. **Altinkaynak, H., Ceylan, E., Kartal, B., Keleş, S., Ekinci, M. & Olcaysu, O. O.** Measurement of choroidal thickness following caffeine intake in healthy subjects. *Curr Eye Res*, 2016.41, 708-14.

13. **Li, L., Bian, A., Zhou, Q. & Mao, J.** Peripapillary choroidal thickness in both eyes of glaucoma patients with unilateral visual field loss. *Am J Ophthalmol*, 2013. 156, 1277-84.
14. **Mwanza, J.-C., Hochberg, J. T., Banitt, M. R., Feuer, W. J. & Budenz, D. L.** Lack of association between glaucoma and macular choroidal thickness measured with enhanced depth-imaging optical coherence tomography. *Investig Ophthalmol Vis Sci*, 2011a.52, 3430-5.
15. **Mwanza, J.-C., Hochberg, J. T., Banitt, M. R., Feuer, W. J. & Budenz, D. L.** Lack of association between glaucoma and macular choroidal thickness measured with enhanced depth-imaging optical coherence tomography. *Investigative ophthalmology & visual science*, 2011b. 52, 3430-3435
16. **Mwanza, J.-C., Sayyad, F. E. & Budenz, D. L.** Choroidal thickness in unilateral advanced glaucoma. *Investig Ophthalmol Vis Sci*, 2012. 53, 6695-701.
17. **Yin, Z. Q., Millar, T. J., Beaumont, P. & Sarks, S.** Widespread choroidal insufficiency in primary open-angle glaucoma. *J Glaucoma*, 1997. 6, 23-32.
18. **Spraul, C. W., Lang, G. E., Lang, G. K. & Grossniklaus, H. E.** Morphometric changes of the choriocapillaris and the choroidal vasculature in eyes with advanced glaucomatous changes. *Vis Res*, 2002. 42, 923-32.
19. **Hirooka, Roberts, K., Fujiwara, A., Shiragami, C., Baba, T. & Shiraga, F.** Relationship between progression of visual field damage and choroidal thickness in eyes with normal-tension glaucoma. *Clinical & experimental ophthalmology*, 2012. 40, 576-582.

**To cite this article:** Ashraf H. El-Habbak, Mohamed A. Awwad, Heba M. Abdallah. Assessment of Choroidal Thickness in Primary Open Angle Glaucoma Patients; an OCT Study. *BMFJ XXX*, DOI: 10.21608/bmfj.2024.329070.2232