

## Zagazig Journal of Forensic Medicine and Toxicology

Journal homepage: <https://zjfm.journals.ekb.eg/>

### Original article

#### Mandibular Dimensions as a Predictor of Sex in a Sample of Assiut Governorate population Eman Mahmoud Metwally<sup>1</sup>, Aml A. Mohamed<sup>1</sup>, Zein Abdou Shatat<sup>2</sup>, Noha Esmael Ebrahim<sup>2</sup>

<sup>1</sup> Department of Forensic Medicine and Clinical Toxicology, Faculty of Medicine-Assiut University-Egypt

<sup>2</sup> Oral and Maxillofacial Radiology, Faculty of dentistry, Assiut University, Egypt

### ARTICLE INFO

### Abstract

#### Article history

Received: 07- 08- 2024

Revised: 28- 09- 2024

Accepted: 03- 10- 2024

**Keywords:** Cone-beam computed tomographic, mandible, sex.

**Background:** Sex determination is a critical component of identification. The mandible, the most dimorphic, largest, and strongest bone in the skull that is often recovered largely intact, is important for determining gender in situations where a whole dry skull cannot be found. According to studies, cone beam computed tomography (CBCT) was better than conventional techniques. A low radiation dose can be obtained by using CBCT equipment to produce 3D images that are undistorted and of high quality. Measurement of the morphometric parameters of the 3D mandible models in the Assiut Governorate population, as well as assessment of how well measures could be used to identify gender, were the goals of this study. **Subject and Methods:** CBCT radiographs of 200 mandibles of males and females with varying ages ranging from (18-80) years at the Department of Oral and Maxillofacial Radiology Department, Faculty of Dentistry, Assiut University. Five mandibular parameters were measured in mm using the mouse-driven method. **Results:** Several mandibular parameters were measured and compared, including gonial angle (GA), Mandibular ramus length (MRL), Mandibular ramus breadth (MRB), Mandibular body length (MBL), and Mandibular canine tooth length (MCL). All mandible variables on CBCT models demonstrated a statistically significant difference among the sexes ( $p < 0.05$ ). Females had a markedly larger mean GA than males, while males displayed significantly greater mean MRL, MRB, MBL, and MCL. This indicates clear sexual dimorphism patterns in these mandibular measurements. **Conclusion:** Mandibular measurements are a useful tool for sex determination.

## I. Background

The gender of human skeletal remains is considered a first step in their identification and is vital for subsequent investigation (Ozer et al., 2006). The diagnosis of sex in bone fragments is necessary in forensic practice and forensic anthropology (Rösing et al., 2007). The age assessment at

death and stature follows a notably distinct pattern in males and females.

Sex identification, which is mostly based on accessible bone fragments, is vital in mass mortality circumstances where bodies have been shattered beyond recognition (Raj and Ramesh, 2013). Identifying sex from human remains is

crucial in forensic medicine and anthropology (Saini and Sadan, 2013). When skeletal elements are in good condition, physical evidence of sexual dimorphism allows an accurate diagnosis of sex in more than 95% of cases (Kimmerle *et al.*, 2008). When the entire adult skeleton is available for analysis, sex can be determined with 100 percent accuracy; however, in cases of mass disasters, where fragmented bones are common, sex determination with 100 percent accuracy is not possible, and it is largely dependent on the parts of the skeleton that are available (Indira *et al.*, 2012). Previous studies have shown that the skull is the most dimorphic and readily sexed bone after the pelvis, with accuracy rates as high as 92 percent (Saini *et al.*, 2011).

The mandible, the largest and strongest skull bone, exhibits sexual dimorphism. It is typically retrieved largely intact and may play a critical role in sex evaluation in situations where a full skull is not found (Gamba *et al.*, 2016). Osteometric assessment using discriminant function analysis is commonly applied for sex estimation from skeletal material (Saini and Sadan, 2013).

The mandible is the last bone in the skull to stop growing; it is susceptible to adolescent growth spurts and has a better-preserved state than any other bone. As a result, anthropologists and forensic dentists frequently use morphological aspects of the mandible to diagnose gender (Singal and Sharma, 2016).

Utilizing data from a particular population is crucial since sexual dimorphism varies throughout populations. Forensic dentistry has long used sexual dimorphism as a means of identifying people. This approach works better in adults due to morphological effects on bone production, such as hormones that drive growth, bone alteration, and puberty development (Gamba *et al.*, 2016).

Based on variables such as the number of teeth present, the number of missing teeth, the structure of the crown, the morphology of the roots, the architecture of the pulp, the occlusion, the wear and tear of the tooth structure, pathology, various treatment methods, etc., this data is evaluated. Identification is successful when these elements are compared and interpreted correctly (Kumar *et al.*, 2015). Mandibular canines exhibit the highest sexual dimorphism (Yuwanati *et al.*, 2012).

CT imaging has a high spatial resolution and good tissue contrast. This allows dentists to use CT scans to examine the facial structure and teeth in more detail; for example, 3D CT

is an extremely useful technique for surgical reconstruction after facial injuries (Shakera and Seifeldeina, 2021).

CBCT is extremely accurate and reproducible in the axial and coronal image planes. In linear measurements and different areas of the maxillofacial region (Moshfeghi *et al.*, 2012). Compared to systems based on Multidetector Computed Tomography (MDCT), CBCT is a more compact and cost-effective technology that loses none of the MDCT images' reliability and accuracy (Mowafey *et al.*, 2015).

Assessment of the accuracy of different mandibular parameters in the determination of gender in a sample of Egyptian Population utilizing cone beam computerized tomography (CBCT) is the purpose of this study. Our methods strengthen the construction of biological profiles from fragmentary remains to promote victim identification where traditional techniques fail. Standardizing these analytical protocols across forensic settings establishes best practices for evidence-based testimony.

## II. Material and Methods

This research was carried out at the Department of Oral and Maxillofacial Radiology, Faculty of Dentistry, Assiut University.

**Study design:** This cross-sectional study was conducted using 200 cone beam computed tomography of a sample of Assiut Governorate population of both sexes within the age group between 18 and 80 years with a documented date of birth, 95 females and 105 males participated in the study. The study period is from 1<sup>st</sup> March 2021 to the end of February 2023 at the Department of Oral and Maxillofacial Radiology, Faculty of Dentistry, Assiut University.

### Methods

#### Inclusion Criteria

- I. Assiut Governorate population
- II. Images showing mandible with complete ramus.
- III. Images with high quality.

#### Exclusion Criteria

We excluded any case with any of the following criteria:

- I. Mandible fractures.
- II. Bone tumors.
- III. Systemic diseases affecting bone metabolism.
- IV. Growth disorders.
- V. Missing canine teeth.

The mandibular parameters were digitally measured using CBCT from lateral reconstructed 3D images of both sides of the mandible (see Photo 1, 2 and 3). This measurement was conducted through a mouse-driven method, which involved moving the cursor and utilizing designated markers on the CBCT images to draw lines in millimeters. The imaging was performed with the Genoray Papaya 3D Plus Combination Imaging System, manufactured by Genoray in Korea, which integrates multiple imaging modalities to facilitate comprehensive diagnostic assessments. According to the previous study, all the measurements were made by considering the anatomical landmarks of a single observer to avoid inter-observer bias (Hussein *et al.*, 2023). All cases were measured more than once to verify the reliability and validity of the results.

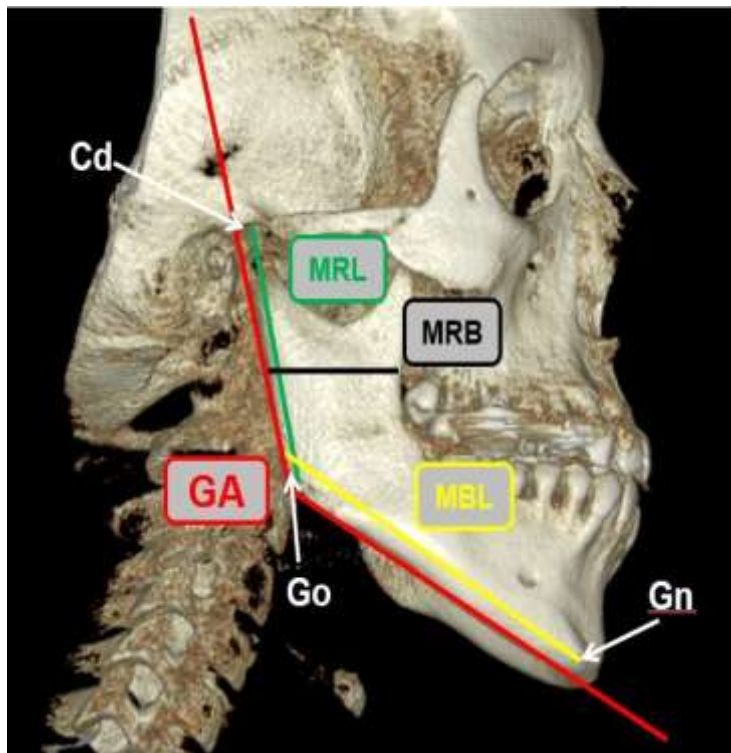


Photo (1): Three-dimensional hard tissue reconstruction, computed tomography image of the mandible (lateral reconstruction): Cd = condylion, Go = gonion, Gn = gnation, Red line =gonial angle (GA), Green line= ramus length (MRL), Black line= mandibular ramus breadth [minimum] (MRB), Yellow line= mandibular body length (MSL).

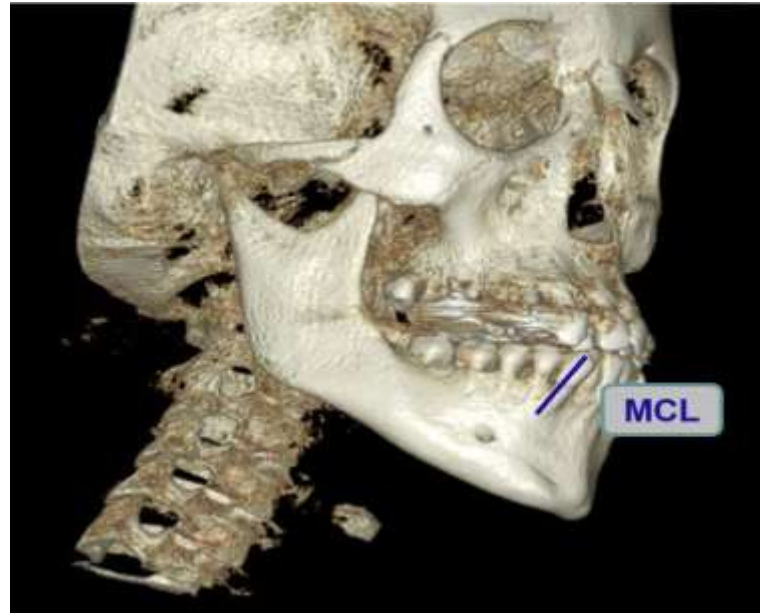

Photo (2): Three-dimensional hard tissue reconstruction, computed tomography image of the mandible (lateral reconstruction): Blue line= mandibular canine tooth length MCL.

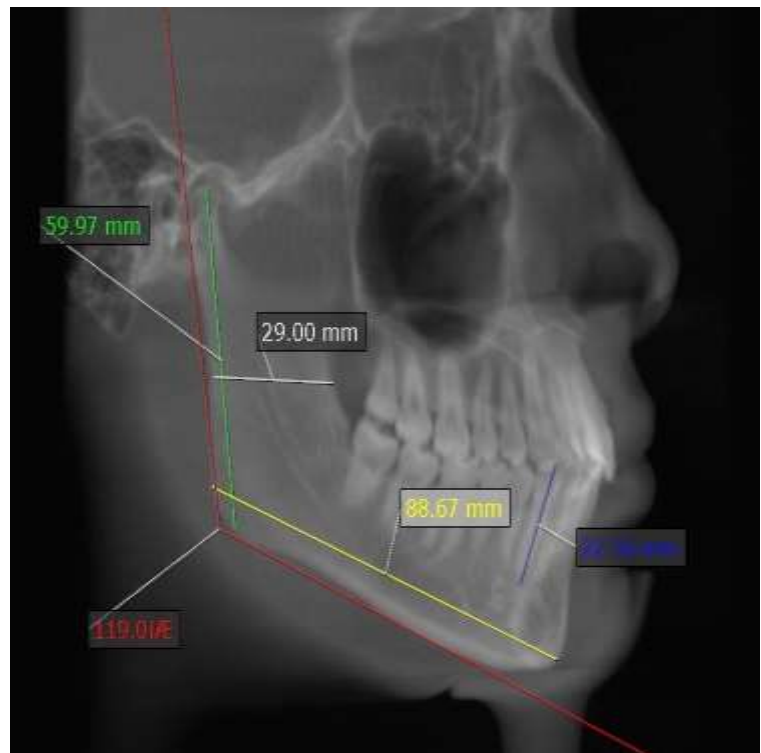


Photo (3): Mandibular parameters were measured from the lateral reconstructed CBCT image of the Male (RT side): Utilizing the mouse-driven method (entails moving the mouse and using selected marks on the CBCT image to draw lines) in mm, Redline =gonial angle, Green line= ramus length, White line= mandibular ramus breadth [minimum], Yellow line= mandibular body length, Blue line= mandibular canine tooth length.

Mandibular measurements were defined in (Table 1).

Table (1) Description of the parameters of the mandible

	Abbreviation	Definition
Gonial	GA	The angle formed by the intersection of the lines running from the most superior point on the mandibular condyle and the gnathion to the gonion.
Mandibular ramus length	MRL	Distance between the condylion and gonion.
Mandibular ramus breadth (minimum breadth)	MRB	Distance from the most concave point of the anterior edge of the ramus to the most concave point of the posterior edge of the ramus.
Mandibular body length	MBL	Distance from the gonion to the gnathion.
Mandibular canine tooth length	MCL	The maximum length of the tooth.

All the cases were obtained using Genoray Papaya 3Dx CBCT dental unit (Korea) (Scan time 18 - 34 s, Effective exposure time 2.4 - 6 s, Focal spot 0.5 mm. kV 60- 90, mA 4- 10) (Hussein *et al.*, 2023). Digital Imaging and Communications in Medicine (DICOM format) was used to save the patient's CBCT scans (Okkesim & Sezen Erhamza, 2020). The sagittal, coronal, and axial images were replicated using OnDemand program 3D software (Seoul, Korea) (Albalawi *et al.*, 2019). The scans were processed using a colorful LCD computer screen in addition to optimum background lighting (the layer thickness = 20 mm). Images were viewed using a Dell monitor (15.6" Full HD 1920 x 1080 display) in a dimmed light room. The distance between the screen and the examiner was approximately 30 cm in a sitting position (Hussein *et al.*, 2023).

**Data analysis:** Data analysis was performed using a statistical package for the social science (IBM-SPSS) version 26.0 software. All numerical variables were tested before evaluation to determine the normality of data by the Shapiro–Wilk test and mean  $\pm$  SD (range) was used to express data. Frequencies and percentages expressed qualitative data. Independent samples student's t-test was used to compare the mean difference of mandibular parameters between males and females. Roc curve analysis was done to identify diagnostic ability mandibular parameters in gender prediction; the area

under the curve, sensitivity, specificity, positive predictive value, and negative predictive value were calculated. The significance level was considered at a P-value  $<$  0.05 (Atef *et al.*, 2021).

### III. Results

It was figured out that all variables of mandible on CBCT models demonstrated a statistically significant difference between the genders ( $p <$  0.05).

Table (2) Illustrates age and sex distribution among studied group ( $n=200$ ). The mean  $\pm$  standard deviation (SD) values for age was  $35.30 \pm 13.52$  years with a minimum of 18 and a maximum of 80 years old, as regards sex, 95 females and 105 males participated in the study. Figure (1) shows the gender distribution of the studied participants (47.5% of cases were females while 52.5% were males).

Table (2): Demographic data of the studied participants

Number of cases= 200		
Age (Years): Mean $\pm$ SD/ (range)	35.30 $\pm$ 13.52 (18-80)	
Gender		
□ Male	105	52.5%
□ Female	95	47.5%

Data were expressed as frequency and % or mean  $\pm$  SD.

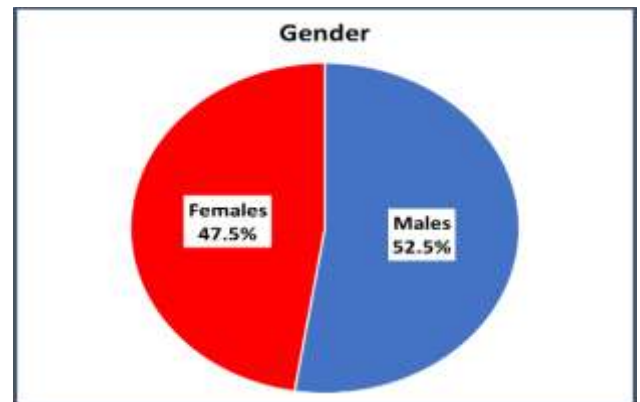
Figure (1): Gender distribution of the studied participants ( $n=200$ ).

Table (3) Shows the mandibular parameters of the studied participants; the mean of Gonial angle was ( $118.62 \pm 7.06$ ), the mean of mandibular ramus length was ( $61.77 \pm 7.35$ ) mm, the mean of mandibular ramus breadth [minimum] was ( $27.44 \pm 2.48$ ) mm, the mean of mandibular body length was ( $88.43 \pm 5.69$ ) mm and the mean of mandibular canine tooth length was ( $22.61 \pm 2.10$ ) mm.

Table (3): Mandibular parameters of the studied participants

Mandibular parameters	Mean $\pm$ SD (range)
Gonial Angle ( $^{\circ}$ )	118.62 $\pm$ 7.06 (107.11-148.37)
M. Ramus length	61.77 $\pm$ 7.35 (26.57-75.06)
M. Ramus breadth	27.44 $\pm$ 2.48 (16.13-31.80)
M. Body length	88.43 $\pm$ 5.69 (73.72-99.97)
M. Canine length	22.61 $\pm$ 2.10 (18.54-28.51)

Data were expressed as mean  $\pm$  SD.

Table (4) shows a comparison of mandibular parameters between males and females; there was a statistically significant lower mean Gonial angle among males compared to females (115.65 $\pm$ 5.99 vs 121.92 $\pm$ 6.71 respectively). However, there was a statistically significant higher mean M.

Ramus length among males in comparison to females (65.05 $\pm$ 6.79 vs. 58.14 $\pm$ 6.16 respectively) and M. ramus breadth among males in comparison to females (28.40 $\pm$ 2.07 vs. 26.38 $\pm$ 2.48, respectively) and M. body length among males in comparison to females (89.29 $\pm$ 5.72 vs. 87.33 $\pm$ 5.86 respectively) and M. canine length among males in comparison to females (22.95 $\pm$ 2.25 vs. 22.23 $\pm$ 1.83, respectively). Females were significantly ( $p < 0.001$ ) higher than males regarding G-angle. Meanwhile, males were significantly ( $p < 0.001$ ) higher than females regarding M. Ramus length, M. Ramus breadth, M. Body length, and M. Canine length.

Table (4): Comparison of the mandibular parameters between Males and Females

	Males (n=105)	Females (n=95)	<i>p</i> -Value
Gonial Angle	115.65 $\pm$ 5.99	121.9 $\pm$ 6.71	<0.001**
M. Ramus length	65.05 $\pm$ 6.79	58.14 $\pm$ 6.16	<0.001**
M. Ramus breadth	28.40 $\pm$ 2.07	26.38 $\pm$ 2.48	<0.001**
M. Body length	89.29 $\pm$ 5.72	87.33 $\pm$ 5.86	0.016**
M. Canine length	22.95 $\pm$ 2.25	22.23 $\pm$ 1.83	0.015**

Data were expressed as mean  $\pm$  SD. \*\* significant P-Value

Independent Sample T-test compares the mean difference of mandibular parameters between males and females, with significance when  $p$ -value  $< 0.05$ .

Table (5) and Figure (2) Show the diagnostic ability of mandibular parameters to predict males compared to females.

Regarding the Gonial angle, at a cut of point  $\leq 120$ , it has an accuracy of 72.5%, a sensitivity of 82.0%, a specificity of 63.2%, a positive predictive value of 71.1%, and a negative predictive value of 76.0% in prediction of male gender, AUC=0.764 and P-value  $< 0.001$ .

Regarding M. ramus length, at a cut of point  $> 57.25$ , it has an accuracy of 74.0%, a sensitivity of 85.0%, a specificity of 63.0%, a positive predictive value of 70.6%, and a negative predictive value of 78.5% in prediction of male gender, AUC=0.771 and P-value  $< 0.001$ .

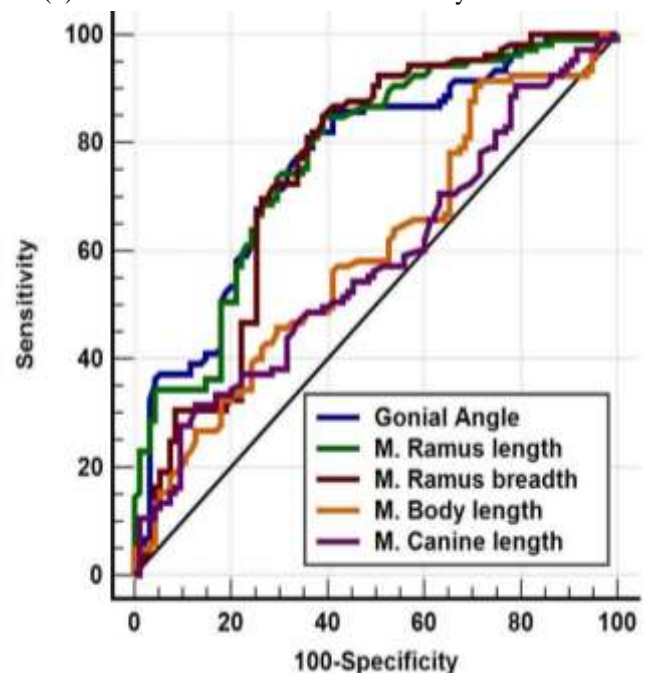
Regarding M. ramus breadth, at a cut of point  $> 26.58$ , it has an accuracy of 73.0%, a sensitivity of 84.8%, a specificity of 61.1%, a positive predictive value of 70.6%, and a negative predictive value of 78.4% in prediction of male gender, AUC=0.749 and P-value  $< 0.001$ .

Regarding M. body length, at a cut of point  $> 87.6$ , it has an accuracy of 56.0%, a sensitivity of 62.0%, a specificity of 50.0%, a positive predictive value of 56.5%, and a negative predictive value of 53.0% in prediction of male gender, AUC=0.596 and P-value =0.016.

Regarding M. canine length, at a cut of point  $> 22.14$ , it has an accuracy of 52.5%, a sensitivity of 60.0%, a specificity of 45.0%, a positive predictive value of 53.0%, and a negative predictive value of 48.1% in prediction of male gender, AUC=0.577 and P-value =0.045.

On Combined Gonial angle, M. ramus length, and M. ramus breadth, they have an accuracy of 76.5%, a sensitivity of 83.0%, a specificity of 70.0%, a positive predictive value of 75.0% and negative predictive value of 77.6% in prediction of male gender, AUC=0.804 and P-value  $< 0.001$ .

Figure (2) shows a Roc curve for the ability of the mandibular



parameters to predict males from females.

Table (5): Diagnostic ability of the mandibular parameters to predict Males from Females

	Gonial Angle	M. Ramus length	M. Ramus breadth	Combined parameters*	M. Body length	M. Canine length
AUC (95% CI)	0.764 (0.699-0.821)	0.771 (0.777-0.848)	0.749 (0.683-0.808)	0.804 (0.742-0.857)	0.596 (0.525-0.665)	0.577 (5050.646)
Cut off	≤120.0	>57.25	>26.58		>87.6	>22.14
Accuracy	72.5%	74.0%	73.0%	76.5%	56.0%	52.5%
Sensitivity	82.0%	85.0%	84.8%	83.0%	62.0%	60.0%
Specificity	63.2%	63.0%	61.1%	70.0%	50.0%	45.0%
PPV	71.1%	70.6%	70.6%	75.0%	56.5%	53.0%
NPV	76.0%	78.5%	78.4%	77.6%	53.0%	48.1%
p-value	<0.001**	<0.001**	<0.001**	<0.001**	0.016**	0.045**

PPV= Positive Predictive value, NPV= Negative Predictive value, AUC= area under the curve, 95% CI=95% confidence interval Combined parameters (Gonial angle, M. ramus length, and M. ramus breadth)

\*\* Significant p-Value.

Table (6) presents the results of univariate logistic regression analysis, indicating that the significant mandibular parameters associated with male gender prediction are: decreased Gonial Angle, increased Mandibular Ramus Length, Ramus Breadth, Body Length, and Canine Length. Multivariate logistic regression analysis further confirmed that decreased Gonial Angle (AOR=0.90, P=0.009), increased Mandibular Ramus Length (AOR=1.11, P=0.004), and increased Mandibular Body Length (AOR=1.13, P=0.001) are the key predictors of male gender.

Table (6): The univariate and multivariate logistic regression analysis for mandibular parameters associated with male gender prediction

Parameters	univariate logistic regression	P-Value	Multivariate logistic regression	P-Value
	OR (95% CI)		AOR (95% CI)	
Gonial Angle	0.85 (0.81-0.90)	<0.001	0.90 (0.84-0.97)	0.009
M. Ramus length	1.17 (1.11-1.23)	<0.001	1.11 (1.03-1.20)	0.004
M. Ramus breadth	1.51 (1.29-1.76)	<0.001	1.10 (0.89-1.35)	0.354
M. Body length	1.06 (1.01-1.11)	0.018	1.13 (1.05-1.22)	0.001
M. Canine length	1.18 (1.03-1.36)	0.018	1.16 (0.97-1.39)	0.101

OR: odds ratio, AOR: adjusted odds ratio

95% CI: 95% confidence interval (lower-upper)

#### IV. Discussion:

Mandibular sexual variations can be influenced by genetic, hormonal, or environmental factors (Macaluso, 2010)

. Diet, sexual division of labor, and cultural activities affect sexual dimorphism. Males exert greater masticatory forces, influencing bone size (Al-Shamout *et al.*, 2012). Lifestyle, chewing habits, and ethnicity influence mandible size and shape (Captier *et al.*, 2006). Mandibular maturation around age 16 in males versus 14 in females makes the flexure more pronounced in males alongside weaker masticatory forces in females, contributing to smaller mandibles (Rosas *et al.*, 2002).

Mandibles were used for the study for two reasons: First, there appears to be a lack of standards utilizing this element, and second, this bone is often recovered mostly intact (Franklin *et al.*, 2008).

The mandibular condyle and ramus, in particular, are generally the most sexually dimorphic as they are the sites associated with the greatest morphological changes in size and remodeling during growth (Humphrey *et al.*, 1999; Franklin *et al.*, 2006; Indira *et al.*, 2012; Abu-Taleb and El Beshlawy, 2015). Hence, in the present study, the mandibular ramus was selected for sex estimation.

In the current analysis, males showed higher mean values for all mandibular measurements except GA, which was larger in females.

The present study confirmed a statistically significant difference in gonial angles between males and females. Specifically, the mean gonial angle for males (115.65±5.99) was significantly lower than that for females (121.92±6.71).

The ROC curve analysis for the gonial angle in CBCT showed that a gonial angle of  $\leq 120.0$  degrees predicted male gender with an accuracy of 72.5%. Overall, females had a statistically significantly higher mean gonial angle than males.

This was in agreement with the study of [Jambunath et al. \(2016\)](#) and [Fekonja and Čretnik \(2022\)](#). In contrast, [Al-Shamout et al. \(2012\)](#) and [Gamba et al. \(2016\)](#) found larger male GA values. Meanwhile, [Dutra et al. \(2004\)](#) and [Uthman \(2007\)](#) found no significant difference between males and females. Meanwhile, [Dutra et al. \(2004\)](#) and [Uthman \(2007\)](#) found no significant differences between males and females.

In Saudi Arabia, the gonial angle was assessed by [Albalawi et al. \(2019\)](#) to ascertain the sex dimorphism, which varied between  $129.9 \pm 11.9$  for males and  $126.7 \pm 12.6$  for females. His research showed that a prediction rate of 66.7% for males, 67.3% for females, and an overall 67% could be projected using the recorded characteristics of the mandible. This prediction rate is low when compared to the prediction rate suggested by our current study. The methodological component of the variation may differ, and CBCT readings were more precise.

Population differences in skeletal anatomy also make applying generalized GA standards difficult. The current study shows that GA exhibits substantial variation rather than clear-cut sex differences. A multivariate approach examining numerous skull landmarks is likely more reliable for identification. Further research on the population is needed to clarify sources of inconsistency. Overall, current evidence suggests GA alone is not a definitive indicator of sex owing to high variability from multiple factors. Using a combination of mandibular measurements will improve precision. Additional studies on GA trends are necessary to understand variability and evaluate its applicability for sex estimation.

MRL was the most accurate measurement for sex estimation. The use of discriminant analysis confirmed a statistically significant difference in MRL. The study explicitly revealed that males' mean values ( $65.05 \pm 6.79$ ) had statistically significantly higher values than females' ( $58.14 \pm 6.16$ ). ROC curve to diagnose males in comparison to females. In CBCT, when the mandibular ramus length was  $> 57.25$  mm with an accuracy of 74.0%, it indicated males. It was the best and most important indicator for males.

The study explicitly revealed that males had a statistically significantly higher mean MRL than females. This finding agreed with the study of [Inci et al. \(2016\)](#) and [Alias et al. \(2018\)](#), who found higher male MRL values. [Motawei et al. \(2020\)](#) and [Ismaili Shahroudi Moqaddam et al. \(2022\)](#) found that the accuracy rates of sex prediction were 69-80% when using MRL. [De Oliveira et al. \(2015\)](#) studied the length of the ramus of the mandible as an indicator of the sex in a group of Brazilians. They found that the sex could not be distinguished based on the mandibular ramus length measurement until the age of 18 years. That measurement could be used to determine sex with an accuracy of only 54 % using lateral cephalometric radiographs.

This finding means that, compared with conventional CT or X-ray imaging, CBCT was reliable and safe with minimal radiation exposure. The CBCT increases the efficacy of the ramus length as a tool for sex identification ([Motawei et al., 2020](#)).

Formulas to estimate sex were developed based on MRB, which was among the top three most accurate measurements for sex at 73% accuracy. The current study explicitly revealed that males' mean values ( $28.40 \pm 2.07$ ) were statistically significantly higher than females' mean values ( $26.38 \pm 2.48$ ). To diagnose males in comparison to females, the ROC curve for MRB in CBCT, when MRB breadth was  $> 26.58$  mm with an accuracy of 73.0%, it indicates males.

This was in agreement with the study of [İlgüy et al. \(2014\)](#) and [Fekonja and Čretnik \(2022\)](#), who found larger male MRB but contradicts the study of [Pakdeewong and Sudwan \(2009\)](#) and [Gamba et al. \(2016\)](#) who found no significant sex differences in MRB. The greater MRB in males likely relates to more active bone remodeling influenced by thicker masseter and temporalis muscles than females.

As regards the mandibular body length, the study explicitly revealed that males' mean values ( $89.29 \pm 5.72$ ) had statistically significantly higher values than females' mean values ( $87.33 \pm 5.86$ ) with p-value (0.016). This was in accordance with the study of [Pakdeewong and Sudwan \(2009\)](#) and [Shaw et al. \(2010\)](#), who reported significant results. However, the contrary was found in the study of [Chandrasekhar Chandrasekhar et al. \(2021\)](#), who found insignificant results.

ROC curve to diagnose males compared to females; in CBCT, when the mandibular body length was  $> 87.6$  mm with an accuracy of 56.0%, it indicates males.

It was found that dimorphism is generally more marked in the mandibular ramus than in the mandibular body. Mandibular ramus can differentiate between sexes as the process of mandibular development, and masticatory forces are different for males and females, influencing the ramus's shape (Franklin *et al.*, 2006).

Regarding mandibular canine length, the current study explicitly revealed that males' mean values ( $22.95 \pm 2.25$ ) were statistically significantly higher than females' mean values ( $22.23 \pm 1.83$ ). Males had a statistically significantly higher mean mandibular canine length than females, with p-value (0.045). This was in agreement with the study of Banerjee *et al.* (2016) and Manhaes-Caldas *et al.* (2019), who noted significantly larger male canine dimensions, but the contrasts were found with the study of Paewinsky *et al.* (2005) and Jeevan *et al.* (2011) who found no significant sex differences. The lack of correlation may reflect minimal masticatory stress effects on the internal canine morphology.

ROC curve to diagnose males compared to females; in CBCT, when the mandibular canine length was  $> 22.14$  mm with an accuracy of 52.5%, it indicates males.

Overall, the results corroborate previous evidence that the mandibular ramus exhibits high sexual dimorphism and has significant value for sex estimation along with GA. The quantifiable sex differences can aid identification when more complete skeletal material is unavailable.

Okkesim and Sezen Erhamza (2020) observed that there was a statistically significant difference ( $p < 0.05$ ) in all mandibular ramus variables on CBCT models among the sexes in a sample of the Turkish population.

The present study demonstrates the utility of CBCT-derived mandibular morphometrics for sex estimation based on quantifiable changes over the lifespan and sexual dimorphism patterns. The five measurements showed measurable sex differences, enabling the development of objective predictive models. By providing foundational data on an understudied Egyptian population, this work represents an incremental advance toward enhancing mandibular-based forensic identification analysis.

## VI. Conclusions

The mandible was advantageous for the analysis of sex due to its high survival rate in skeletal remains and the profound growth changes it undergoes, reflecting its developmental state. As the largest and strongest facial bone, mandibular identification is essential in forensic and

anthropological contexts when more complete skeletal material is unavailable.

This study examined the utility of CBCT-derived mandibular measurements for developing objective models to estimate sex in a sample of Egyptian adults aged 18-80 years. The study also highlights the accuracy of mandibular measurements in providing sex estimation, with MRL demonstrating the highest discrimination among the sexes. Moreover, quantitative models based on CBCT offer the capability to estimate sex from the mandible with moderate to high accuracy. Using GA, MRL, and MRB combined provided 76.5% accuracy for sex prediction based on discriminant analysis. This highlights the significant sexual dimorphism presents in these mandibular landmarks.

By enhancing the scientific foundations and reference data for this Egyptian population, this study represents an incremental advance toward improving the objectivity of mandible-based forensic identification practices.

Additional comprehensive research across diverse populations is warranted to fully delineate worldwide patterns in age and sex relationships of mandibular structures. This will help establish more universal standards.

## Declarations

### Funding

This research received no specific grant from funding agencies in the public, commercial, or not-for-profit sectors.

### Ethical approval

Informed valid consent was taken from the patients. The proposal was reviewed, and all requirements were fulfilled as governed by the Declaration of Helsinki. Approval from the Institutional Review Board of the Faculty of Medicine in Assiut University was obtained. Institutional Research Board (IRB) number: 17101439.

### Data availability statement

All data generated in the current study are available from the corresponding author on reasonable request.

### Conflict of interest

The authors declared no potential conflicts of interest concerning this article's research, authorship, and/or publication.

## References

Abu-Taleb, N., & El Beshlawy, D. (2015). Mandibular Ramus and Gonial Angle Measurements as Predictors of Sex



and Age in an Egyptian Population Sample: A Digital Panoramic Study. *Journal of Forensic Research*, 06. <https://doi.org/10.4172/2157-7145.1000308>

Albalawi, A. S., Alam, M. K., Vundavalli, S., Ganji, K. K., & Patil, S. (2019). Mandible: An Indicator for Sex Determination - A Three-dimensional Cone-Beam Computed Tomography Study. *Contemporary clinical dentistry*, 10(1), 69–73. [https://doi.org/10.4103/ccd.ccd\\_313\\_18](https://doi.org/10.4103/ccd.ccd_313_18)

Alias, A., Ibrahim, A., Abu Bakar, S. N., Swarhib Shafie, M., Das, S., Abdullah, N., Noor, H. M., Liao, I. Y., & Mohd Nor, F. (2018). Anthropometric analysis of mandible: an important step for sex determination. *La Clinica terapeutica*, 169(5), e217–e223. <https://doi.org/10.7417/CT.2018.2082>

Al-Shamout, R., Ammouh, M., Alrbata, R., & Al-Hababhab, A. (2012). Age and gender differences in gonial angle, ramus height and bigonial width in dentate subjects. *Pakistan Oral & Dental Journal*, 32(1).

Atef, M., sobhy, A., Khalid, A., Ismail, M. (2021). Role of Three Dimensional Computed Tomography in Age Estimation from Mandible of a Sample of Libyan Population in Tripoli. *Zagazig Journal of Forensic Medicine and Toxicology*, 19(2), 13-30. doi: <https://10.21608/zjfm.2021.52407.1068>.

Banerjee, A., Kamath, V. V., Satelur, K., Rajkumar, K., & Sundaram, L. (2016). Sexual dimorphism in tooth morphometrics: An evaluation of the parameters. *Journal of Forensic Dental Sciences*, 8(1), 22–27. <https://doi.org/10.4103/0975-1475.176946>.

Captier, G., Lethuillier, J., Oussaid, M., Canovas, F., & Bonnel, F. (2006). Neural symmetry and functional asymmetry of the mandible. *Surgical and Radiologic Anatomy: SRA*, 28(4), 379–386. <https://doi.org/10.1007/s00276-006-0104-1>.

Chandrasekhar M., Charitha, M., Ayesha, Chandrasekhar, G., & Naik, N. (2021). Sex estimation from mandible using lateral cephalogram: A short study. *Journal of Indian Academy of Forensic Medicine*, 43(2), Article 2. <https://doi/10.5958/0974-0848.2021.00030.0>.

de Oliveira, F. T., Soares, M. Q. S., Sarmiento, V. A., Rubira, C. M. F., Lauris, J. R. P., & Rubira-Bullen, I. R. F. (2015). Mandibular ramus length as an indicator of chronological age and sex. *International Journal of Legal Medicine*, 129(1), 195–201. <https://doi.org/10.1007/s00414-014-1077-y>

Dutra, V., Yang, J., Devlin, H., & Susin, C. (2004). Mandibular bone remodelling in adults: Evaluation of panoramic radiographs. *Dento Maxillo Facial Radiology*, 33(5), 323–328. <https://doi.org/10.1259/dmfr/17685970>

Fekonja, A., & Čretnik, A. (2022). Gender and Age Differences in Mandibular Ramus and Body Measurements: A Radiographic Study. *Journal of Hard Tissue Biology*, 31(1), 9–14. <https://doi.org/10.2485/jhtb.31.9>

Franklin, D., Cardini, A., O’Higgins, P., Oxnard, C. E., & Dadour, I. (2008). Mandibular morphology as an indicator of human subadult age: Geometric morphometric approaches. *Forensic Science, Medicine, and Pathology*, 4(2), 91–99. <https://doi.org/10.1007/s12024-007-9015-7>

Franklin, D., O’Higgins, P., Oxnard, C. E., & Dadour, I. (2006). Determination of sex in South African blacks by discriminant function analysis of mandibular linear dimensions: A preliminary investigation using the zulu local population. *Forensic Science, Medicine, and Pathology*, 2(4), 263–268. <https://doi.org/10.1385/FSMP:2:4:263>

Gamba, T. de O., Alves, M. C., & Haiter-Neto, F. (2016). Mandibular sexual dimorphism analysis in CBCT scans. *Journal of Forensic and Legal Medicine*, 38, 106–110. <https://doi.org/10.1016/j.jflm.2015.11.024>

Humphrey, L. T., Dean, M. C., & Stringer, C. B. (1999). Morphological variation in great ape and modern human mandibles. *Journal of Anatomy*, 195 ( Pt 4), 491–513. <https://doi.org/10.1046/j.1469-7580.1999.19540491.x>

Hussein, S., Mohamed, N., & Amer, M. (2023). Accuracy Of Various Parameters Of The Mandible For Sex Determination By Cone Beam Computed Tomography (Retrospective Study). *Egyptian Dental Journal*, 69(3), 1887-1892. <https://doi.org/10.21608/edj.2023.197506.2475>

İlgüy, D., İlgüy, M., Ersan, N., Dölekoğlu, S., & Fişekçioğlu, E. (2014). Measurements of the foramen magnum and mandible in relation to sex using CBCT. *Journal of Forensic Sciences*, 59(3), 601–605. <https://doi.org/10.1111/1556-4029.12376>

Inci, E., Ekizoglu, O., Turkay, R., Aksoy, S., Can, I. O., Solmaz, D., & Sayin, I. (2016). Virtual Assessment of Sex: Linear and Angular Traits of the Mandibular Ramus Using Three-Dimensional Computed Tomography. *The Journal of craniofacial surgery*, 27(7), e627–e632. <https://doi.org/10.1097/SCS.0000000000002979>

Indira, A. P., Markande, A., & David, M. P. (2012). Mandibular ramus: An indicator for sex determination - A digital radiographic study. *Journal of Forensic Dental Sciences*, 4(2), 58–62. <https://doi.org/10.4103/0975-1475.109885>

Ismaili Shahrudi Moqaddam, Z., Jamshidi, M., Fares, F., Aghabiklooei, A., & Saberi Isfeedvajani, M. (2022). The Diagnostic Value of 3-dimensional Computerized

- Tomography (3D-CT) Scan Indicators of Mandible Bone in Sex Determination of Selected Individuals in Tehran. *Medical Journal of the Islamic Republic of Iran*, 36, 160. <https://doi.org/10.47176/mjiri.36.160>
- Jambunath, U., & Govindraju, P. (2016). *Sex Determination by using Mandibular Ramus and Gonial Angle – a Preliminary Comparative Study*. 3(11).
- Jeevan, M. B., Kale, A. D., Angadi, P. V., & Hallikerimath, S. (2011). Age estimation by pulp/tooth area ratio in canines: Cameriere's method assessed in an Indian sample using radiovisiography. *Forensic Science International*, 204(1), 209.e1-209.e5. <https://doi.org/10.1016/j.forsciint.2010.08.017>
- Kimmerle, E. H., Ross, A., & Slice, D. (2008). Sexual dimorphism in America: Geometric morphometric analysis of the craniofacial region. *Journal of Forensic Sciences*, 53(1), 54–57. <https://doi.org/10.1111/j.1556-4029.2007.00627.x>
- Kumar, R., Athota, A., Rastogi, T., & Karumuri, S. K. (2015). Forensic radiology: An emerging tool in identification. *Journal of Indian Academy of Oral Medicine and Radiology*, 27(3), 416. <https://doi.org/10.4103/0972-1363.170478>
- Macaluso, P. J. (2010). Sex determination from the acetabulum: Test of a possible non-population-specific discriminant function equation. *Journal of Forensic and Legal Medicine*, 17(6), 348–351. <https://doi.org/10.1016/j.jflm.2010.04.011>
- Manhaes-Caldas, D., Oliveira, M. L., Groppo, F. C., & Haiter-Neto, F. (2019). Volumetric assessment of the dental crown for sex estimation by means of cone-beam computed tomography. *Forensic Science International*, 303, 109920. <https://doi.org/10.1016/j.forsciint.2019.109920>
- Moshfeghi, M., Tavakoli, M. A., Hosseini, E. T., Hosseini, A. T., & Hosseini, I. T. (2012). Analysis of linear measurement accuracy obtained by cone beam computed tomography (CBCT-NewTom VG). *Dental Research Journal*, 9(Suppl 1), S57-62.
- Motawei, S., Helaly, A., Aboelmaaty, W., Elmahdy, K., Shabka, O., & Liu, H. (2020). Length of the ramus of the mandible as an indicator of chronological age and sex: A study in a group of Egyptians. *Forensic Science International: Reports*, 2, 100066. <https://doi.org/10.1016/j.fsir.2020.100066>
- Mowafey, B., Van de Castele, E., Youssef, J. M., Zaher, A. R., Omar, H., Politis, C., & Jacobs, R. (2015). Can mandibular lingual canals be used as a forensic fingerprint?. *The Journal of forensic odonto-stomatology*, 33(2), 26–35.
- Okkesim, A., & Sezen Erhamza, T. (2020). Assessment of mandibular ramus for sex determination: Retrospective study. *Journal of oral biology and craniofacial research*, 10(4), 569–572. <https://doi.org/10.1016/j.jobcr.2020.07.019>
- Ozer, I., Katayama, K., Sağır, M., & Güleç, E. (2006). Sex determination using the scapula in medieval skeletons from East Anatolia. *Collegium antropologicum*, 30(2), 415–419.
- Paewinsky, E., Pfeiffer, H., & Brinkmann, B. (2005). Quantification of secondary dentine formation from orthopantomograms—A contribution to forensic age estimation methods in adults. *International Journal of Legal Medicine*, 119(1), 27–30. <https://doi.org/10.1007/s00414-004-0492-x>
- Pakdeewong, N., & Sudwan, P. (2009). Gender differences in Thai mandibles using metric analysis. *Chiang Mai Med J.*, 48.
- Raj, J., & Ramesh, S. (2013). Sexual Dimorphism in Mandibular Ramus of South Indian Population. *Antrocom Online Journal*, 9, 253–258.
- Rosas, A., Bastir, M., Martínez-Maza, C., & Bermúdez de Castro, J. M. (2002). Sexual dimorphism in the Atapuerca-SH hominids: The evidence from the mandibles. *Journal of Human Evolution*, 42(4), 451–474. <https://doi.org/10.1006/jhev.2001.0536>
- Rösing, F. W., Graw, M., Marré, B., Ritz-Timme, S., Rothschild, M. A., Röttscher, K., Schmeling, A., Schröder, I., & Geserick, G. (2007). Recommendations for the forensic diagnosis of sex and age from skeletons. *Homo: Internationale Zeitschrift Fur Die Vergleichende Forschung Am Menschen*, 58(1), 75–89. <https://doi.org/10.1016/j.jchb.2005.07.002>
- Saini, V., & Sadan, S. (2013). Metric study of fragmentary mandibles in a North Indian population. *Null*. <https://www.scinapse.io/papers/2182811223>
- Saini, V., Srivastava, R., Shamal, S. N., Singh, T. B., Pandey, A. K., & Tripathi, S. K. (2011). Sex determination using mandibular ramus flexure: A preliminary study on Indian population. *Journal of Forensic and Legal Medicine*, 18(5), 208–212. <https://doi.org/10.1016/j.jflm.2011.02.014>
- Shakera, J., & Seifeldeina, G. (2021). The diagnostic efficacy of multiplanar and 3-dimensional MDCT in Evaluation of Traumatic Maxillofacial Injuries. *Egyptian Journal of Oral and Maxillofacial Surgery*, 12(2), 110–120. <https://doi.org/10.21608/omx.2021.86992.1127>
- Shaw, R. B., Katzel, E. B., Koltz, P. F., Kahn, D. M., Giroto, J. A., & Langstein, H. N. (2010). Aging of the mandible and its aesthetic implications. *Plastic and Reconstructive Surgery*,

125(1), 332–342.  
<https://doi.org/10.1097/PRS.0b013e3181c2a685>

Singal, K., & Sharma, S. (2016). Gender Determination by Mental Foramen Using Linear Measurements on Radiographs: A Study in Haryana Population. *Indian Journal of Forensic Medicine & Toxicology*, 10, 44.  
<https://doi.org/10.5958/0973-9130.2016.00011.6>

Uthman, A. T. (2007). Retromolar space analysis in relation to selected linear and angular measurements for an Iraqi

sample. *Oral Surgery, Oral Medicine, Oral Pathology, Oral Radiology, and Endodontology*, 104(4), e76–e82.  
<https://doi.org/10.1016/j.tripleo.2007.05.013>

Yuwanati, M., Karia, A., & Yuwanati, M. (2012). Canine tooth dimorphism: An adjunct for establishing sex identity. *Journal of forensic dental sciences*, 4(2), 80–83.  
<https://doi.org/10.4103/0975-1475.109892>

**How to cite:** Metwally, E., Aly, A., Shatat, Z., Ebrahem, N. (2025). Mandibular Dimensions as a Predictor of Sex in a Sample of Assiut Governorate population. *Zagazig Journal of Forensic Medicine and Toxicology*, 23 (1): 8-18, -. doi: 10.21608/zjfm.2024.305937.1196