

CLINICAL COMPARISON OF TOPICAL APPLICATION OF CURCUMIN GEL VERSUS GELATIN SPONGE IN PAIN MANAGEMENT AND WOUND HEALING AFTER FREE GINGIVAL GRAFT HARVESTING: A RANDOMIZED CONTROLLED CLINICAL TRIAL

Tansim Khaled Tawfik Abdelrahman * , Manal Mohamed Hosny** 
and Mohamed Atef*** 

ABSTRACT

Objectives The aim of this study was to compare the effect of using 2% curcumin gel versus gelatin sponge when applied as wound dressing to palatal donor site on pain perception and wound healing after epithelialized gingival graft (EGG) harvesting.

Methodology The present study included 30 patients with mucogingival defects that can be treated by application of EGG. The patients were allocated to 2 groups, an intervention group and control group. The palatal donor site received a hemostatic gelatin sponge and 2% curcumin gel in the control and intervention groups respectively after EGGs harvesting from the palate. Patients were observed for 4 weeks, evaluating the pain level by using the visual analogue scale and the consumption of analgesic during the first postoperative week. Soft tissue healing and re-epithelialization of the palatal wound were evaluated for 4 weeks post-surgery.

Results There was significant difference between both groups in pain scores assessed from the 3rd to the 7th days after surgery. The number of analgesic tablets taken by the patients in the control group was significantly higher than that of the intervention from the on 3rd day and 4th days. On the second week wound healing, scores measured in the intervention group were significantly higher than the control group ($p=0.035$). For wound re-epithelialization for all intervals, there was no significant difference between groups ($p>0.05$).

Conclusions Curcumin gel represents a useful palatal wound dressing material that has features that enhances palatal wound re-epithelialization and healing and can reduce post-operative pain.

KEYWORDS Pain management. Autogenous soft tissue graft. Wound healing.

* B.D.Sc (2017), Cairo University

** Professor of Oral medicine and Periodontology, Faculty of Dentistry, Cairo University.

*** Lecturer of Periodontology, Faculty of Dentistry, Cairo University

INTRODUCTION

Periodontal plastic surgery has been efficiently used for treating gingival recessions and mucogingival abnormalities for a long time⁽¹⁾. Autogenous gingival grafts remain the gold standard for both single and multiple root coverage due to their established clinical performance, with the palate serving as the most common donor site. Clinically, epithelialized gingival grafts (EGG) obtained from the hard palate are the primary tissue source for increasing the zones of keratinized gingiva, and they offer a high level of predictability⁽²⁾. However, clinical trials have indicated greater postoperative discomfort and morbidity linked with epithelial gingival graft (EGG)⁽³⁻⁵⁾.

Various approaches have been used to manage palatal donor sites after harvesting of autogenous gingival grafts, including mechanical barriers (periodontal pack, palatal stent)⁽⁶⁾, wound dressing (gelatin sponges, collagen, platelet rich fibrin)⁽⁷⁾, biologic agents (hyaluronic acid, emdogain, erythropoietin)⁽⁸⁻¹⁰⁾ and physical agents that stimulate wound healing (ozone, low level biostimulation)⁽¹¹⁾.

Herbal products have recently attracted worldwide study interest due to their medical capabilities, which include excellent biocompatibility, anti-microbial, and anti-inflammatory properties, making them ideal for wound healing^(12,13).

The primary constituent in turmeric, curcumin, is extracted from the rhizomes of *Curcuma longa* L. It serves as the perfect dressing or agent for wound healing, preventing bacterial infections and accelerating the healing process⁽¹⁴⁾. It can stimulate angiogenesis, trigger the proliferation of mesenchymal cells, and increase the deposition of granulation tissue. It can also positively affect the inflammatory phase of wound healing⁽¹⁵⁾. Moreover, it can accelerate tissue maturation and remodeling as well as collagen deposition. In addition, curcumin has anti-inflammatory, antibacterial, antifungal, and antioxidant qualities.

Curcumin was shown to improve clinical results when used as an adjuvant to non-surgical periodontal care⁽¹⁶⁾. It was used to treat inflammatory oral lesions including lichen planus and recurrent aphthous ulcer (RAU) reducing their symptoms and encouraging their remission⁽¹³⁾. The current study was conducted to evaluate the application of curcumin as palatal wound dressing after harvesting of autogenous gingival graft.

MATERIALS AND METHODS.

This study was designed as a prospective controlled randomized clinical trial with a parallel design to assess patients' morbidity after EGG harvesting from the palate, in accordance with the CONSORT statement⁽¹⁷⁾. In the control group, the palatal wound was treated with an absorbable gelatin sponge (Cutanplast Standard, Mascia Brunelli S.p.a, Milano, Italy), while in the test group, 2% curcumin gel was applied topically. Figure 1 shows the study's flow chart.

For this study, thirty patients in need of a mucogingival treatment requiring EGG harvesting—either a de-epithelialized gingival graft or a free gingival graft—were chosen at random. After providing both written and verbal informed consent, only voluntarily participating individuals were included in the study.

This randomized controlled trial was approved by the ethical committee of Cairo University's Faculty of Dentistry (approval number: 34/7/22) and carried out in compliance with the Helsinki Declaration, which was revised in Tokyo in 2004 for the ethical principles for medical research involving human subjects. NCT05819632 was the registration number for the study when it was registered on www.clinicaltrials.gov.

The study was carried out from December 2023 to June 2024 at Cairo University's Faculty of Dentistry, Periodontology Department. In the current study, participants who met the following

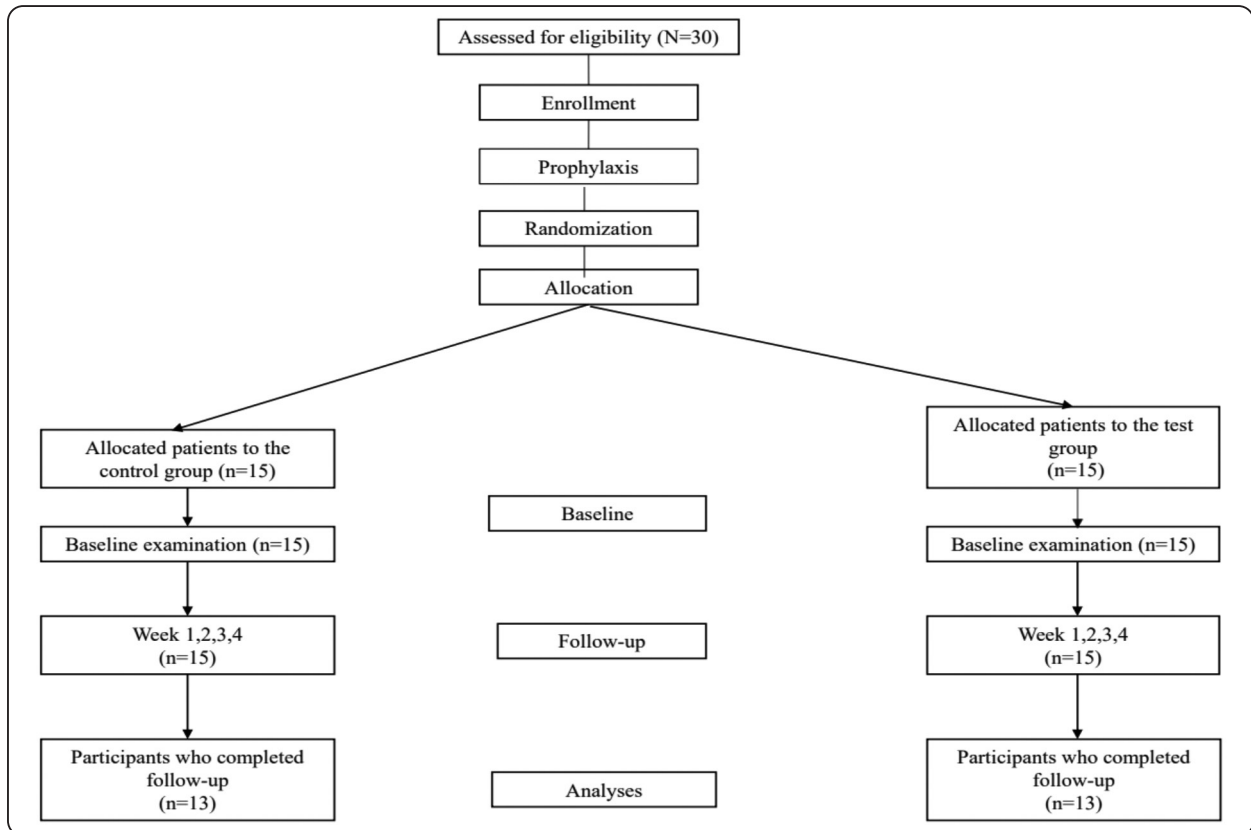


Fig. (1) CONSORT (Consolidated Standards of Reporting Trials) flowchart showing the study design

inclusion criteria were enrolled: (i) patients with mucogingival deficiencies scheduled for EGG; (ii) patients who are systemically healthy (American Society of Anesthesiology classes I and II); (iii) patients who maintain appropriate oral hygiene. The following were the criteria for exclusion: (i) A history of recent periodontal surgery at the donor site; (ii) smoking; (iii) pregnancy and lactation; (iv) individuals allergic to the drugs utilized; (v) a severe gag reflex; (vi) an incapacity or refusal to give informed permission.

Sample size and randomization.

Sample size was calculated using the PS software. As regarding the primary outcome (post-operative pain) it was calculated that 13 patients per group will be an appropriate sample size for the study with total sample size 26 patients (2 groups) as the power is 80% and α error probability = 0.05. The effect

size used in calculation was 1.15. The magnitude of the effect to be detected was estimated as mean and standard deviation of the variable of interest and obtained from the scientific literature⁽⁷⁾. The sample size was increased to 30 patients to compensate for dropout 20%.

A random sequence from 1 to 30 was created using computer software (<http://www.random.org/>) and organized into two columns. When the graft harvesting operation was finished during surgery, the operator was informed of each patient's group assignment through a sealed envelope that was unsealed.

Preparation of Curcumin Gel

The gel formulation was prepared according to Nasra et al. (2017)⁽¹⁸⁾. Curcumin powder was dissolved in Carbopol-poloxamer mixture. First Carbopol P34 was dissolved in deionized water

and the solution was cooled in an ice bath. Second pluronic F127 was added and stirred continuously. The mixture was kept for 24 hours at - 4 degrees. Third curcumin powder was added to the previous mixture preparing a 2% w/w gel (Figure 2).

Pre-surgical treatment

At least three weeks before their scheduled operation, every research subject got thorough supragingival scaling and polishing as well as instructions on dental hygiene. The patients received instruction on how to use interdental brushes, dental floss, and/or toothbrushes correctly.

Surgical procedures

The main surgical site that needed to have soft tissue graft was ready. The graft's dimensions were calculated and then applied to a tin foil template to achieve the required size and form. Using a precise dissection of the donor site tissue, an EGG of the template size was retrieved to create a partial thickness graft that was about 1.5 mm thick and comprised of a layer of underlying connective tissue and epithelium. The graft was utilized for the intended goal of being either extra-orally de-epithelialized or left intact (2). A continuous, thin layer of curcumin gel was administered topically to the denuded palatal region in the intervention group, whereas absorbable gelatin sponge was cut to fit the size of the palatal wound and placed in the control group. Compressive palatal sling sutures were used to hold the sponge in place after it had been manually compressed. For seven days, patients in the test group were told to apply a thin layer of curcumin gel three times a day (Figures 3&4).

Postsurgical instruction

It was recommended to take 400 mg tablets of ibuprofen as needed, with a maximum dosage of 1 tablet every eight hours. For two weeks following surgery, patients were instructed to rinse twice a day with a 0.12% chlorhexidine digluconate solution.

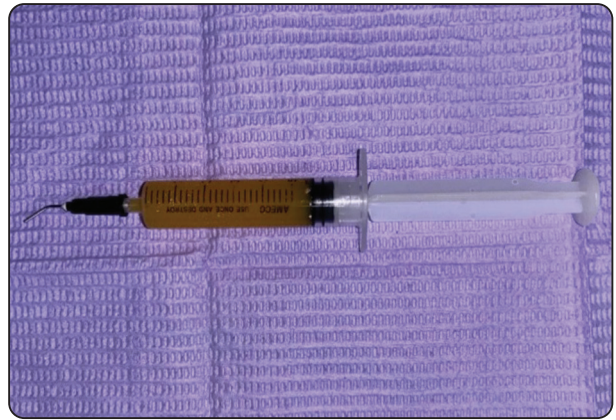


Fig. (2) Curcumin gel applied using plastic gel syringe

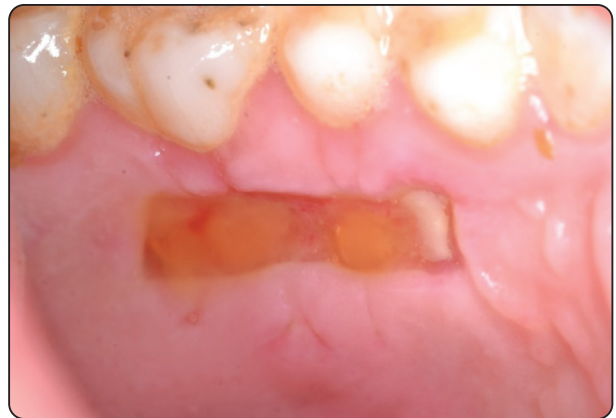

Fig. (3) The denuded palatal area was superficially covered with a continuous thin layer of curcumin

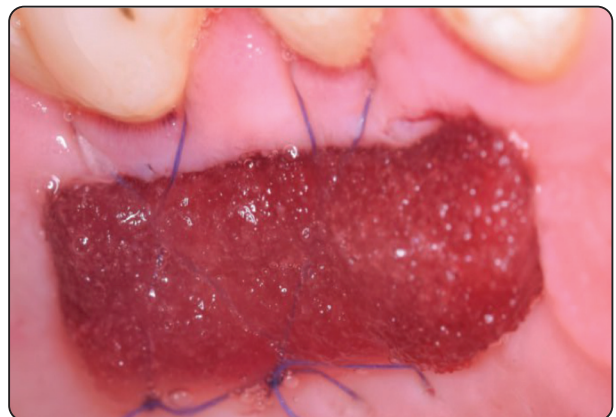

Fig (4) Absorbable gelatin sponge applied to palatal wound

Healing index	Tissue color	Bleeding on palpation	Granulation tissue	Incision margin	Suppuration
1 - Very Poor: 2 or more signs are present	≥ 50% of red gingiva	yes	yes	not epithelialized, with loss of epithelium beyond incision margin	yes
2 - Poor	≥ 50% of red gingiva	yes	yes	not epithelialized, with exposed connective tissue	no
3 - Good	25 - 50% of red gingiva	no	no	no exposed connective tissue	no
4 - Very Good	< 25% of red gingiva	no	no	no exposed connective tissue	no
5 - Excellent	all pink tissues	no	no	no exposed connective tissue	no

Fig. (5) Landry et al., modified healing index

14 days following the procedure, the sutures were removed. Before the sutures were removed, patients were instructed not to clean the palatal surface of their maxillary teeth. Antibiotics were not prescribed.

Clinical outcomes

Post-operative pain was assessed during the first postoperative week. To assess postoperative pain, patients were required to complete a 10-cm VAS and classify the intensity of pain experienced on the palatal site from 0 to 10, with 10 representing the worst pain ever encountered⁽⁷⁾. Postoperative pain was indirectly assessed through use of analgesics for seven days postoperatively, reported as the number of analgesic tablets per day for seven days⁽¹⁹⁾. For the 1st, 2nd, 3rd and 4th weeks after surgery soft tissue healing of the palatal wound was evaluated by the modified healing index of Landry et al.⁽²⁰⁾ (Figure 5). Re-epithelialization of the palatal wound was assessed by means of bubble formation after dripping hydrogen peroxide (3%) to the wound and re-epithelialization was ranked as total, partial or none^(7, 21). These outcomes were measured by

a PhD student enrolled in the PhD periodontics program in the department of Periodontology and Oral Medicine (Figure 6).

Statistical analysis

Frequency and percentage numbers were used to display both ordinal and categorical data. The chi-square test was utilized to assess categorical data. The mean, standard deviation (SD), median, and interquartile range (IQR) values were used to depict numerical data. Shapiro-Wilk's test and an examination of the data distribution were used to determine whether they were normal. The age data were subjected to an independent t-test analysis, using a normal distribution. The remaining data were non-parametric and were examined using ordinal data using Friedman's test and the Mann-Whitney U test for intragroup comparisons and intragroup comparisons, respectively. P-values were modified using the False Discovery Rate (FDR) technique to account for multiple comparisons. For every test, the significance threshold was set at $p < 0.05$. The R statistical analysis software, version 4.4.1, was used to conduct statistical analysis for Windows.

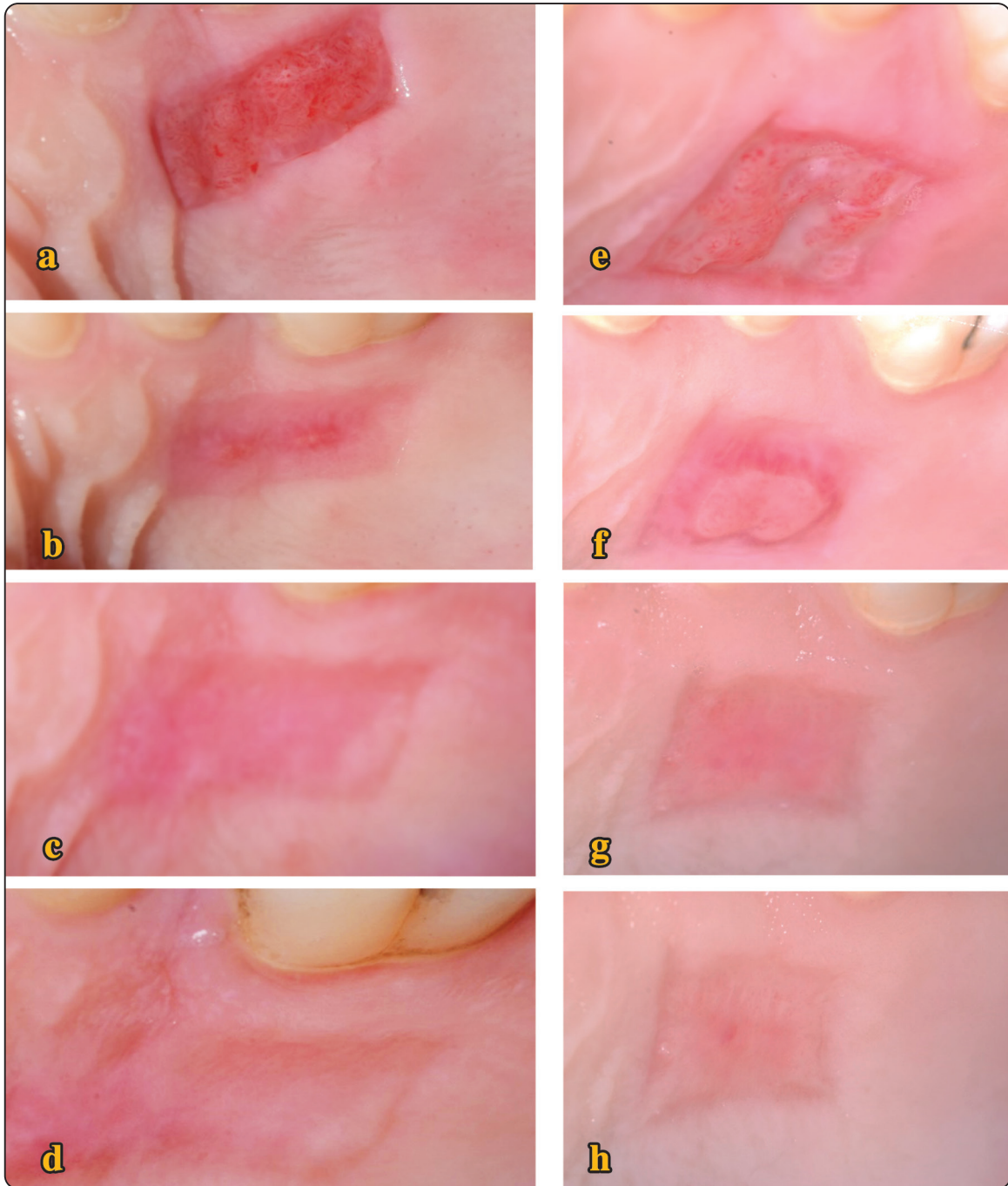


Fig. (6) a, b, c, d wound healing at test sites after 1,2,3 and 4 weeks. e, f, g, h wound healing at control sites after 1,2,3 and 4 weeks.

RESULTS

The study was conducted on 30 cases (i.e., 15 cases per group). Two cases were excluded from each group as they did not show up for follow-up for unknown reasons. The number of statistically analyzed cases was 26 (i.e., 13 cases per group). There were two males and eleven females in each group. Patients in the intervention group had an average age of 31.15±6.91 years, whereas those in the control group had an average age of 32.69±8.51 years. Regarding the various test parameters, there was no discernible difference between the two groups (p>0.05). Table 1 displays the research participants' demographic data.

There was a significant difference between both groups in pain scores measured from the 3rd to the 7th days (Table 2). This was reflected by higher analgesic intake on the 3rd and 4th days in the control group compared to the intervention group (Table 3) The scores of the modified wound healing index of Landry et al., recorded on the 2nd week in the intervention group were significantly higher than the control group (p=0.035). For other intervals, the difference was not statistically significant (p>0.05) (Table 4). For all intervals of wound epithelialization, there was no significant difference between groups (p>0.05). For both groups, there was a significant increase in the percentage of wounds with complete epithelization by time (p< 0.001) (Figure 7).

TABLE (1) Intergroup comparisons and summary statistics for demographic data

Parameter	Intervention	Control	p-value
Gender			
Male	2 (15.38%)	2 (15.38%)	1ns
Female	11 (84.62%)	11 (84.62%)	
Age			0.618ns
Mean±SD	31.15±6.91	32.69±8.51	
Median (IQR)	31.00 (12.00)	32.00 (10.00)	

ns not significant.

TABLE (2) Inter and intragroup comparisons, summary statistics for (VAS).

Time	Mean+SD	(VAS)		p-value
		Intervention	Control	
Day 1	Mean+SD	10.00±0.00A	10.00±0.00A	NA
	Median (IQR)	10.00 (0.00)A	10.00 (0.00)A	
Day 2	Mean+SD	9.23 ±0.43 A	9.31 ± 0.95 A	0.42
	Median (IQR)	9 (0.5) A	10 (1) A	
Day 3	Mean+SD	5.46± 1.12AB	8.23± 1.09 AB	0.0001*
	Median (IQR)	5 (1) AB	8 (1.5)AB	
Day 4	Mean+SD	4.69 ± 1.32 B	6.62 ± 1.33 B	0.002*
	Median (IQR)	4 (2) B	7 (2.5) B	
Day 5	Mean+SD	2.46 ± 1.26 BC	4.23 ± 1.69 BC	0.01*
	Median (IQR)	2 (2)BC	5 (4) BC	
Day 6	Mean+SD	0.62±0.51 C	2.61 ± 1.89 C	0.005*
	Median (IQR)	1 (1) C	2 (3.5) C	
Day 7	Mean+SD	0.07 ±0.28 C	1.76 ± 2.13 C	0.03*
	Median (IQR)	0(0) C	1 (4) C	
		<0.001*	<0.001*	

NA Not Applicable, Values with different superscripts within the same vertical column are significantly different, • significant (p<0.05), ns not significant.

TABLE (3) Inter and intragroup comparisons, summary statistics for number of analgesic tablets.

Time	Mean±SD	Number of analgesic tablets		p-value
		Intervention	Control	
Day 1	Mean±SD	2.23±0.60 ^A	2.08±0.86 ^B	0.794ns
	Median (IQR)	2.00 (1.00) ^A	2.00 (1.00) ^B	
Day 2	Mean±SD	2.77±0.44 ^A	2.62±0.87 ^A	0.944ns
	Median (IQR)	3.00 (0.00) ^A	3.00 (0.00) ^A	
Day 3	Mean±SD	0.69±1.03 ^B	2.46±0.97 ^{AB}	<0.001*
	Median (IQR)	0.00 (1.00) ^B	3.00 (1.00) ^{AB}	
Day 4	Mean±SD	0.00±0.00 ^C	2.00±1.29 ^B	<0.001*
	Median (IQR)	0.00 (0.00) ^C	3.00 (2.00) ^B	
Day 5	Mean±SD	0.00±0.00 ^C	0.38±0.87 ^C	0.079ns
	Median (IQR)	0.00 (0.00) ^C	0.00 (0.00) ^C	
Day 6	Mean±SD	0.23±0.83 ^C	0.15±0.55 ^C	1ns
	Median (IQR)	0.00 (0.00) ^C	0.00 (0.00) ^C	
Day 7	Mean±SD	0.23±0.83 ^C	0.08±0.28 ^C	1ns
	Median (IQR)	0.00 (0.00) ^C	0.00 (0.00) ^C	
	p-value	<0.001*	<0.001*	

Values with different superscripts within the same vertical column are significantly different, * significant ($p<0.05$), ns not significant.

TABLE (4) Inter and intragroup comparisons, summary statistics for wound healing score.

Time	Mean±SD	Wound healing score		p-value
		Intervention	Control	
Week 1	Mean±SD	2.00±0.00 ^D	2.00±0.00 ^C	NA
	Median (IQR)	2.00 (0.00) ^D	2.00 (0.00) ^C	
Week 2	Mean±SD	2.92±0.49 ^C	2.46±0.52 ^C	0.035*
	Median (IQR)	3.00 (0.00) ^C	2.00 (1.00) ^C	
Week 3	Mean±SD	3.92±0.76 ^B	3.38±0.51 ^B	0.063ns
	Median (IQR)	4.00 (1.00) ^B	3.00 (1.00) ^B	
Week 4	Mean±SD	4.77±0.44 ^A	4.54±0.52 ^A	0.237ns
	Median (IQR)	5.00 (0.00) ^A	5.00 (1.00) ^A	
	p-value	<0.001*	<0.001*	

NA Not Applicable, Values with different superscripts within the same vertical column are significantly different, * significant ($p<0.05$), ns not significant.

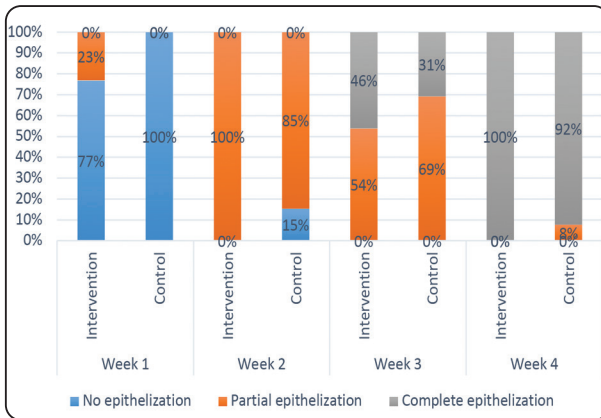


Fig. (7) Stacked bar chart showing wound re-epithelization status.

DISCUSSION

The necessity to harvest epithelialized gingival grafts has increased due to the use of autogenous gingival grafts in periodontal and implant surgery to expand the zone of keratinized tissues and enhance gingival and peri-implant tissue phenotypes⁽²²⁾. The EGG harvesting technique offers several benefits. It is a relatively quick procedure that yields a higher quality graft with less glandular and fatty tissue, and it achieves a more uniform thickness. This technique is equally beneficial for thin palatal fibromucosa. The EGG method allows clinicians to employ the graft with or without epithelium, resulting in a graft that is dense, stable, and less prone to shrink than typical connective tissue graft (CTG) harvesting procedures. Many strategies have been proposed to preserve the ensuing partial thickness wound at the palatal donor site, making it more comfortable and helping the process of re-epithelialization. They also protect the palatal connective tissue from chemical and physical harm, as well as the oral bacteria that inhabit the area^(22,23).

Herbal and natural products as wound dressing agents have shown benefits with respect to acceleration of healing and reduction of patient related outcomes^(19,24). As a pure plant extract with a natural origin, curcumin does not irritate or harm the oral mucosa⁽²⁵⁾. It also represents an ideal wound

healing dressing or agent to protect the wound tissue from bacterial infection, lowers inflammation, and stimulates cell proliferation to aid in the repair of injured tissues⁽²⁶⁾. Curcumin wound healing abilities are linked to its biochemical properties, which include anti-inflammatory, anti-infectious, and antioxidant properties.

Curcumin has anti-inflammatory properties that include raising adrenal gland production of cortisone, lowering histamine levels, blocking prostaglandin synthesis, and impairing neutrophil activity. Additionally, it suppresses the generation of pro-inflammatory cytokines and represses nuclear factor kappa β and activator protein 1 activation^(27,28).

This study is the first to employ 2% curcumin gel to promote the healing of wounds caused by secondary intention. However, researches by Jalaluddin et al., 2019; Meghana et al., 2020^(29,30) have used 1% extract. Patients of test group were instructed to apply thin layer of the curcumin gel three times per day for 7 days according to Bakhshi et al., (2022)⁽¹³⁾ who compared the efficacy of topical application of 1% curcumin nano micelle gel and 2% curcumin gel for treatment of recurrent aphthous ulcer as patients were asked to apply it 3 times/day for 1 week. This is also in accordance with the study of Alasfar et al., (2023)⁽²⁵⁾ that evaluated 3 times daily application of 10% turmeric gel for protection of palatal donor sites after harvesting of EGG.

Gelatin is a collagen that has been thermally denaturalized from tendons, bone, or skin of cows or pigs. It is typically extracted either acidically or alkalinely and then hydrolyzed⁽³¹⁾. Absorbable gelatin sponge has been recommended as a typical wound dressing material because of its exceptional hemostatic and tissue-adhering qualities^(31,32). Apart from its absence of antigenicity, gelatin sponges offer other advantages over collagen dressings such as their simplicity in manufacture and extraction⁽³³⁾.

In this study, curcumin gel and absorbable gelatin sponge were found to be equally efficient as palate

wound dressings for reducing postoperative pain, increasing wound healing, and facilitating wound re-epithelialization. The curcumin gel group experienced notably lower analgesic use and pain scores on the 3rd and 4th days compared to the control group. This can be explained by the ability of curcumin to relieve pain through a number of routes. Initially, curcumin can stop prostaglandin E2 (PGE2) from being synthesized⁽³⁴⁾. It is a crucial mediator created in damaged neurons and promotes the creation of chemicals that cause pain⁽³⁵⁾. Second, curcumin block potassium channels and deplete neurotransmitter chemicals at the nerve ends to induce corticosteroid release from the adrenal gland⁽³⁴⁾.

Over time, both treatments led to a decrease in postoperative pain scores, consistent with previous research on pain and palatal wound healing^(7, 24, 25). This finding is similar to Alasfar et al., 2023 who reported that When 10% turmeric extract gel was used instead of the Coe-Pak dressing, post-operative discomfort was reduced and the study by Hassan et al., 2021 who reported statistically significant decrease in analgesic intake from day 1 to day 7 when MEBO was compared to Hyaluronic acid gel on application on palatal wounds⁽¹⁹⁾.

The evaluation of changes in postoperative pain was performed by VAS score. Although it is subjective in recording pain perception yet it is widely employed in previous researches^(7, 19, 24), and it has demonstrated a good efficiency in the evaluation of outcome of different therapies.

Concerning wound healing, on the 2nd week scores measured in the curcumin group were significantly higher than the control group ($p=0.035$). This finding is consistent with Alasfar et al., (2023) who reported that 10% turmeric extract gel showed higher wound healing scores when compared to the Coe-Pak dressing⁽²⁵⁾. Additionally, the findings of the Rujirachotiawat & Suttamanatwong (2021) in vitro research demonstrated curcumin's capacity to increase the expression of RNA-m for growth factors such as epidermal growth factor receptor,

keratinocyte growth factor-1(EGFR, KGF-1) and the collagen type-1 gene (COL1) that accelerate wound healing⁽³⁶⁾.

For wound re-epithelialization, the palatal donor sites in the curcumin group exhibited higher degree of surface re-epithelialization at all follow-up periods. This observation can be explained by curcumin's capacity to enhance collagen deposition and accelerate the process of re-epithelialization^(26, 37, 38). Similar findings have been reported by Alasfar et al., in 2023⁽²⁵⁾. Rats with cutaneous wounds treated with curcumin had much quicker wound healing, as evidenced by increased rates of epithelialization and wound contraction⁽³⁹⁾.

One of the limitations of this study is that a stent was not used to protect the palatal wound after application of curcumin gel as this would have maintained prolonged contact of the gel with palatal wound. This was not applied in fear of the patient's inability to remove and place the stent without inducing further trauma to the frail palatal wound.

CONCLUSION

The current randomized controlled trial shows that curcumin gel is a useful palatal wound dressing material that has features that enable palatal wound re-epithelialization and reduces post-operative pain.

REFERENCES

1. Cairo F, Pagliaro U, Nieri M. Treatment of gingival recession with coronally advanced flap procedures: a systematic review. *J Clin Periodontol.* 2008;35(8 Suppl):136-62.
2. Zucchelli G, Mele M, Stefanini M, Mazzotti C, Marzadori M, Montebugnoli L, et al. Patient morbidity and root coverage outcome after subepithelial connective tissue and de-epithelialized grafts: a comparative randomized-controlled clinical trial. *J Clin Periodontol.* 2010;37(8):728-38.
3. Del Pizzo M, Modica F, Bethaz N, Priotto P, Romagnoli R. The connective tissue graft: a comparative clinical evaluation of wound healing at the palatal donor site. A preliminary study. *J Clin Periodontol.* 2002;29(9):848-54.

4. Tatakis DN, Chambrone L, Allen EP, Langer B, McGuire MK, Richardson CR, et al. Periodontal soft tissue root coverage procedures: a consensus report from the AAP Regeneration Workshop. *J Periodontol.* 2015;86(2 Suppl):S52-5.
5. Griffin TJ, Cheung WS, Zavras AI, Damoulis PD. Post-operative complications following gingival augmentation procedures. *J Periodontol.* 2006;77(12):2070-9.
6. Baghani Z, Kadhodazadeh M. Periodontal dressing: a review article. *J Dent Res Dent Clin Dent Prospects.* 2013;7(4):183-91.
7. Femminella B, Iaconi MC, Di Tullio M, Romano L, Sinjari B, D'Arcangelo C, et al. Clinical Comparison of Platelet-Rich Fibrin and a Gelatin Sponge in the Management of Palatal Wounds After Epithelialized Free Gingival Graft Harvest: A Randomized Clinical Trial. *J Periodontol.* 2016;87(2):103-13.
8. Yıldırım S, Özener H, Doğan B, Kuru B. Effect of topically applied hyaluronic acid on pain and palatal epithelial wound healing: An examiner-masked, randomized, controlled clinical trial. *J Periodontol.* 2018;89(1):36-45.
9. Miguel MMV, Mathias-Santamaria IF, Rossato A, Ferraz LFF, Rangel TP, Casarin RCV, et al. Enamel matrix derivative effects on palatal mucosa wound healing: Randomized clinical trial. *J Periodontal Res.* 2021;56(6):1213-22.
10. Yaghobee S, Rouzmeh N, Aslroosta H, Mahmoodi S, Khorsand A, Kharrazifard MJ. Effect of Topical Erythropoietin (EPO) on palatal wound healing subsequent to Free Gingival Grafting (FGG). *Braz Oral Res.* 2018;32:e55.
11. Isler SC, Uraz A, Guler B, Ozdemir Y, Cula S, Cetiner D. Effects of Laser Photobiomodulation and Ozone Therapy on Palatal Epithelial Wound Healing and Patient Morbidity. *Photomed Laser Surg.* 2018;36(11):571-80.
12. Nagpal M, Sood S. Role of curcumin in systemic and oral health: An overview. *J Nat Sci Biol Med.* 2013;4(1):3-7.
13. Bakhshi M, Mahboubi A, Jaafari MR, Ebrahimi F, To-fangchiha M, Alizadeh A. Comparative Efficacy of 1% Curcumin Nanomicelle Gel And 2% Curcumin Gel For Treatment of Recurrent Aphthous Stomatitis: A Double-Blind Randomized Clinical Trial. *Journal of Evidence-Based Dental Practice.* 2022;22(2):101708.
14. Zielińska A, Alves H, Marques V, Durazzo A, Lucarini M, Alves TF, et al. Properties, Extraction Methods, and Delivery Systems for Curcumin as a Natural Source of Beneficial Health Effects. *Medicina (Kaunas).* 2020;56(7).
15. Silva ACd, Santos PDdF, Silva JTdP, Leimann FV, Bracht L, Gonçalves OH. Impact of curcumin nanoformulation on its antimicrobial activity. *Trends in Food Science & Technology.* 2018;72:74-82.
16. Bhatia M, Urolagin SS, Pentyala KB, Urolagin SB, K BM, Bhoi S. Novel therapeutic approach for the treatment of periodontitis by curcumin. *J Clin Diagn Res.* 2014;8(12):Zc65-9.
17. Moher D, Hopewell S, Schulz KF, Montori V, Gøtzsche PC, Devereaux PJ, et al. CONSORT 2010 explanation and elaboration: updated guidelines for reporting parallel group randomised trials. *Int J Surg.* 2012;10(1):28-55.
18. Nasra M, Ebada H, Ali H, Abdallah O. Formulation, in-vitro characterization and clinical evaluation of curcumin in-situ gel for treatment of periodontitis. *Drug Delivery.* 2017;24:133-42.
19. Hassan A, Ahmed E, Ghalwash D, Elarab AE. Clinical Comparison of MEBO and Hyaluronic Acid Gel in the Management of Pain after Free Gingival Graft Harvesting: A Randomized Clinical Trial. *Int J Dent.* 2021;2021:2548665.
20. Landry RG, Turnbull RS, Howley T. Effectiveness of benzzydamyne HCl in the treatment of periodontal post-surgical patients. *Res Clin Forums* 1988;10:105-118
21. Keceli HG, Aylikci BU, Koseoglu S, Dolgun A. Evaluation of palatal donor site haemostasis and wound healing after free gingival graft surgery. *J Clin Periodontol.* 2015;42(6):582-9.
22. Zucchelli G, Tavelli L, McGuire MK, Rasperini G, Feinberg SE, Wang HL, et al. Autogenous soft tissue grafting for periodontal and peri-implant plastic surgical reconstruction. *J Periodontol.* 2020;91(1):9-16.
23. Tavelli L, Barootchi S, Stefanini M, Zucchelli G, Giannobile WV, Wang H-L. Wound healing dynamics, morbidity, and complications of palatal soft-tissue harvesting. *Periodontology 2000.* 2023;92(1):90-119.
24. Ehab K, Abouldahab O, Hassan A, Fawzy El-Sayed KM. Alvogyl and absorbable gelatin sponge as palatal wound dressings following epithelialized free gingival graft harvest: a randomized clinical trial. *Clin Oral Investig.* 2020;24(4):1517-25.
25. Alasfar Z, Saymeh R, Khazem M. The effectiveness of Turmeric gel in the healing of donor site for Free Gingival Graft. *Dentistry 3000.* 2023;11.

26. Akbik D, Ghadiri M, Chrzanowski W, Rohanizadeh R. Curcumin as a wound healing agent. *Life Sci.* 2014;116(1):1-7.
27. Nagasri M, Madhulatha M, Musalaiah SV, Kumar PA, Krishna CH, Kumar PM. Efficacy of curcumin as an adjunct to scaling and root planning in chronic periodontitis patients: A clinical and microbiological study. *J Pharm Bioallied Sci.* 2015;7(Suppl 2):S554-8.
28. Anuradha BR, Bai YD, Sailaja S, Sudhakar J, Priyanka M, Deepika V. Evaluation of Anti-Inflammatory Effects of Curcumin Gel as an Adjunct to Scaling and Root Planing: A Clinical Study. *J Int Oral Health.* 2015;7(7):90-3.
29. Jalaluddin M, Jayanti I, Gowdar IM, Roshan R, Varkey RR, Thirutheri A. Antimicrobial Activity of Curcuma longa L. Extract on Periodontal Pathogens. *J Pharm Bioallied Sci.* 2019;11(Suppl 2):S203-s7.
30. Meghana MVS, Deshmukh J, Devarathanamma MV, Asif K, Jyothi L, Sindhura H. Comparison of effect of curcumin gel and noneugenol periodontal dressing in tissue response, early wound healing, and pain assessment following periodontal flap surgery in chronic periodontitis patients. *J Indian Soc Periodontol.* 2020;24(1):54-9.
31. Djagny VB, Wang Z, Xu S. Gelatin: a valuable protein for food and pharmaceutical industries: review. *Crit Rev Food Sci Nutr.* 2001;41(6):481-92.
32. Jang HJ, Kim YM, Yoo BY, Seo YK. Wound-healing effects of human dermal components with gelatin dressing. *J Biomater Appl.* 2018;32(6):716-24.
33. Tomizawa Y. Clinical benefits and risk analysis of topical hemostats: a review. *J Artif Organs.* 2005;8(3):137-42.
34. Sahbaie P, Sun Y, Liang D-Y, Shi X-Y, Clark JD. Curcumin Treatment Attenuates Pain and Enhances Functional Recovery after Incision. *Anesthesia & Analgesia.* 2014;118(6).
35. Ma W, Quirion R. Does COX2-dependent PGE2 play a role in neuropathic pain? *Neurosci Lett.* 2008;437(3):165-9.
36. Rujirachotiawat A, Suttamanatwong S. Curcumin Promotes Collagen Type I, Keratinocyte Growth Factor-1, and Epidermal Growth Factor Receptor Expressions in the In Vitro Wound Healing Model of Human Gingival Fibroblasts. *Eur J Dent.* 2021;15(1):63-70.
37. Chaushu S, Becker A, Zeltser R, Vasker N, Chaushu G. Patients' perceptions of recovery after surgical exposure of impacted maxillary teeth treated with an open-eruption surgical-orthodontic technique. *Eur J Orthod.* 2004;26(6):591-6.
38. Chaushu S, Becker A, Zeltser R, Branski S, Vasker N, Chaushu G. Patients perception of recovery after exposure of impacted teeth: a comparison of closed- versus open-eruption techniques. *J Oral Maxillofac Surg.* 2005;63(3):323-9.
39. Panchatcharam M, Miriyala S, Gayathri VS, Suguna L. Curcumin improves wound healing by modulating collagen and decreasing reactive oxygen species. *Mol Cell Biochem.* 2006;290(1-2):87-96.