

## GASTROINTESTINAL PARASITES IN DOMESTIC CATS (*FELIS CATUS*) IN SOHAG GOVERNORATE, EGYPT: A CROSS-SECTIONAL STUDY

SAMIA MOHAMMED ABDELLAH<sup>1</sup>; AHMED KAMAL DYAB<sup>2</sup>;  
MADIHA DARWISH<sup>3</sup> and SALWA MAHMOUD ABD-ELRAHMAN<sup>4</sup>

<sup>1</sup> Private Veterinary Clinic. [m.samia89a@gmail.com](mailto:m.samia89a@gmail.com)

<sup>2</sup> Department of Medical Parasitology, Faculty of Medicine, Assiut University, Assiut 71515, Egypt, Department of Parasitology, School of Veterinary Medicine, Badr University in Assiut, New Nasser City, Assiut, Egypt. (ORCID: <https://orcid.org/0000-0002-4021-7904>)

<sup>3</sup> Department of Animal and Poultry Behavior and Management, Faculty of Veterinary Medicine, Assiut University, 71526, Egypt

<sup>4</sup> Department of Parasitology, Faculty of Veterinary Medicine, Assiut University (71526), Assiut, Egypt. [Salwamahmoud@aun.edu.eg](mailto:Salwamahmoud@aun.edu.eg) (ORCID: <https://orcid.org/0000-0002-0319-7713>)

**Received:** 16 October 2024; **Accepted:** 19 November 2024

---

### ABSTRACT

Cats, as widely embraced companions in various settings, are at risk of significant health threats due to gastrointestinal infections. The current study investigates the prevalence of gastrointestinal parasitic infection in domestic cats from Tahta, Sohag Governorate, Egypt. Two hundred fecal samples were collected and examined using various techniques: direct smear examination, simple sedimentation, formal ether sedimentation, and flotation with Sheather's solution. The flotation method demonstrated the highest efficacy in isolating *Toxocara spp.* eggs and protozoan oocysts. The findings reveal a significant prevalence of gastrointestinal parasitic infections, with 71% of the cats examined carrying at least one species of parasite. The most frequently identified parasite was *Toxocara leonine* (47.5%), followed by *Toxocara cati* (10%) and mixed infections of both species (6.5%). Other less prevalent parasites included hookworm eggs (2%), *Giardia spp.* (2%), *Cryptosporidium spp.* (1%), *Entamoeba spp.* (1%), and Mite infections (1%). Notably, embryonation of *Toxocara spp.* eggs was achieved using a 0.01% sodium bicarbonate solution, resulting in embryonation of 60% of incubated eggs. The prevalence of parasitic infections showed no significant variation based on age or gender, however, seasonal factors significantly influenced the rate of infection ( $P \leq 0.05$ ). These findings underscore the high prevalence of gastrointestinal parasites among domestic cats in Sohag Governorate, highlighting the urgent need for effective parasite control strategies to safeguard feline and public health.

**Keywords:** Cat, Helminths, protozoan, embryonation, sedimentation, flotation.

---

Corresponding author: Ahmed Kamal Dyab

E-mail address: [ahmed2015@aun.edu.eg](mailto:ahmed2015@aun.edu.eg)

Present address: Department of Medical Parasitology, Faculty of Medicine, Assiut University, Assiut 71515, Egypt.

## INTRODUCTION

Domestic cats (*Felis catus*) are the common felines living exclusively in close contact with humans (Adhikari *et al.*, 2023). Gastrointestinal parasites are a common and often overlooked health concern for domestic cats. They are one of the most significant causes of morbidity in domestic cats in Egypt and worldwide (Khalafalla, 2011). They can be infected with various parasites (Endo-parasites, or Ecto-parasites) (Yousef *et al.*, 2024). GIT parasites are primarily caused by helminths, such as roundworms, hookworms, and tapeworms, or by one-celled protozoan parasites like *Isospora*, *Giardia*, *Toxoplasma*, and *Cryptosporidium*. These microscopic invaders can inhabit the digestive tract, leading to various symptoms. Some individuals may be asymptomatic, while others may experience issues such as weight loss, diarrhea, vomiting, anemia, loss of appetite, respiratory infections, coughing, and the presence of mucus or bloody feces. In severe cases, these infections can result in life-threatening complications. Additionally, a cat heavily infected with gastrointestinal parasites becomes more susceptible to secondary infections caused by viruses, bacteria, or fungi (Adhikari *et al.*, 2023).

Cats can serve as reservoirs, carriers, transmitters, and definitive hosts for various parasites. They significantly contaminate the environment by discharging helminth eggs like *Toxocara cati*, protozoan oocysts such as *Toxoplasma gondii*, insect larvae, and adult arthropods into public areas. (Abbas *et al.*, 2022). The impact of these parasites goes beyond affecting individual cats, as they can also pose a risk to human health, especially in young children and those with weakened immune systems (Qadir *et al.*, 2011). They are the primary source of a wide range of parasitic diseases in tropical and subtropical regions, leading to health issues in both humans and animals, such as toxoplasmosis, giardiasis, ocular and visceral larva migrans syndrome, and cutaneous larva migrans in humans (Morelli *et al.*, 2021). Abbas *et al.*,

(2022) and Khalafalla, (2011) conducted a separate study on gastrointestinal parasites in cats, concluding that *Toxocara cati* was the most prevalent parasite. This indicates the risk of occurrence of visceral larva migrans syndrome, which involves the formation of larval stages within various vital tissues, such as the lung and liver (Adeel, 2020). Residing of the larvae within the tissue makes it resistant to various treatments like albendazole. There is an urgent need for the development of new therapies to overcome this infection (Abd-Elrahman *et al.*, 2021) (Elossily *et al.*, 2024). It's important to note that various factors can affect the prevalence of these parasites, including gender, age, breed of the cat, living conditions, animal density, nutritional status, immune status, anthelmintic treatments, and owner's social status (Yousef *et al.*, 2024).

The prevalence and diversity of gastrointestinal parasites in cats in Sohag have not been thoroughly investigated. Therefore, this study aims to examine their prevalence, the impact of these parasites on feline health, and the importance of effective control measures to protect both cats and their human companions. The findings will be crucial for treating cat parasites and controlling potential zoonotic diseases.

## MATERIAL AND METHODS

### Study Area and Animals

This study was conducted in Tahta, Sohag Governorate, Egypt at (26.6-27.9° N, 31.13-32.36° E). 200 cats were randomly collected from various locations in Tahta. The animals underwent clinical examinations to identify clinical manifestations, such as anemia, emaciation, decreased weight gain, vomiting, and diarrhea. Cats were divided into three age groups: less than 1 year (n=89), 1-3 years (n=59), and more than 3 years (n=53). There were 96 male cats and 104 female cats. Additionally, the cats were categorized based on the seasons: spring, summer, autumn, and winter, as mentioned by (Kamel *et al.*, 2024).

## **Fecal samples collection**

Fecal samples were collected from each cat in a clean plastic cup labeled with the cat's data (age, sex, and date). The samples were transferred to the parasitology lab of the Faculty of Veterinary Medicine, Assiut University for further examination (Abd el-rady *et al.*, 2021).

## **1-Macroscopic examination of fecal samples**

The naked eye examination identified the consistency, color, presence or absence of blood, undigested food, mucus, adult helminths, or other unusual constituents (Mohamed *et al.*, 2021).

## **2- Parasitological examination**

### **2.1- Direct smear examination**

One gram of the fecal sample was mixed with a drop of 0.9% saline, thoroughly mixed till forming a uniform smear, then put on a clean slide and examined under the light microscope using an X100 objective lens. Confirmation was made by switching to an X400 objective lens for detection of any parasitic stage (eggs and cysts) (Abd-ELrahman *et al.*, 2023).

### **2.2- Concentration Techniques**

#### **2.2.1- Ordinary sedimentation technique**

In short, the fecal matter was mixed with (0.9%) a saline solution, filtered, and then left to settle for 30 minutes. The liquid above the settled material was then removed. The remaining material was mixed with more saline solution and strained until the liquid on top was clear. A drop from the sediment was placed on a glass slide, and examined under a microscope (Abd-ELrahman *et al.*, 2022).

#### **2.2.2- Formalin Ether Concentration Technique (FECT)**

Fecal samples were mixed in 0.9% saline, strained, and left to settle for 30 minutes. The liquid on top was poured off, and then 7mL of 10% formal saline and 3mL of ether were added to the remaining sediment. The tube was shaken vigorously and centrifuged at 3,000 rpm for 3 minutes, resulting in three distinct layers. The top three layers were

poured off, and the remaining sediment was used to prepare slides for microscopic examination (Mohamed *et al.*, 2024).

#### **2.2.3- Flotation-centrifugation method**

Fecal samples were processed using Sheather's sugar solution at a specific gravity of 1.25 (prepared by combining 355 mL of water and 454 g of (sucrose) granulated sugar) (Zajac *et al.*, 2012). Mix 3–5 g (1 teaspoonful) of feces with a small amount of flotation solution in a plastic cup. Strain the mixture of feces through a double layer of cheesecloth or gauze. Pour the mixture into a 15-mL centrifuge tube. Spin the mixture in a bench top centrifuge for 5 minutes at approximately 2500 rpm. Place the centrifuge tube in a test tube rack. Fill the tube with additional flotation solution to form a reverse meniscus. Place a coverslip on the tube and allow it to sit for an additional 15 minutes, before removing the coverslip and placing it on a slide. Coverslips were utilized to retrieve eggs from each sample, which were then examined under light microscopy to detect *Toxocara* eggs and protozoan cysts (Jarosz *et al.*, 2021).

#### **2.3- Modified Zeihl-Neelsen staining technique (special stain)**

The fecal smears were air-dried and fixed with 95% ethanol. They were then stained with concentrated carbol fuchsin and heated until vapor appeared. After 5 minutes, the stain was rinsed off with water. Next, 1% sulfuric acid was used for 1 minute for decolorization, followed by a wash. Finally, 1% methylene blue was used for counterstaining for 1 minute. After air drying, the slide was viewed under 100x magnification. When observed under oil immersion, *Cryptosporidium* oocysts appeared as oval pinkish-red structures on a blue background (Lamido *et al.*, 2022).

#### **2.4- Preservation and fixation of nematodes using lactophenol**

The collected nematodes were preserved in a solution of 70% alcohol with 5% glycerin. For fixation and identification, the nematodes should be cleared in lactophenol for 24 hours,

and then mounted in glycerin jelly, as described by (Van Bezooijen, 2006).

### 2.5- Fecal culture and embryonating of *Toxocara spp.* egg

The fecal samples testing positive for *Toxocara sp.* eggs were collected using standard sedimentation techniques. The collected eggs were centrifuged at 1000 rpm for 10 minutes. After that, the eggs were placed in a solution of 0.01% sodium bicarbonate and left at room temperature for 15 days, with a regular addition of 0.01% sodium bicarbonate, to maintain proper humidity. After three weeks, the embryonated eggs were separated using flotation techniques (Mohamed *et al.*, 2024).

#### Statistical analysis

The chi-square test was used to calculate the association between risk factors (age, gender, and season) and internal parasite infection in cats. A statistically significant p-value was

considered if  $P \leq 0.05$  (Abd-Elrahman *et al.*, 2024).


#### Approval for ethical conduct

The present study was conducted following the guidelines of the Ethical Committee of the Faculty of Veterinary Medicine, Assiut University, Assiut, Egypt, Approval number (06/2024/0216).

## RESULT

### 1- Clinical manifestation of infected animals:

About 82.39% (117/142) of cats infected with parasitic infection showed signs of poor body condition in general, with specific indicators of parasitic infection such as diarrhea, weight loss, ruffled hair, lethargy, anemia, and anorexia, as shown in Fig.1.



**Fig. (1)** shows various signs observed in cats infected with parasites: A) severe emaciation of the cat with hair loss, B) bad health and decrease in weight, and C) fecal samples indicating the presence of diarrhea.

### 2- Prevalence of gastrointestinal parasitic infection in the examined cats.

The overall rate of gastrointestinal parasitic infection in cats testing positive for at least one type of parasite was 71.0% (142/200). The breakdown of the infections showed that 66% (132/200) were infected with helminths, 4% (8/200) with protozoa, and 1% (2/200) with arthropods, as shown in Table (1). Three

species of helminth parasites were detected: *Toxocara leonine*, *Toxocara cati*, and *Hookworm*, with infection rates of 47.5%, 10%, and 2% respectively. There are also mixed infections between *Toxocara cati* and *Toxocara leonine*, accounting for 6.5% of cases. Additionally, three protozoan parasites were detected: *Entamoeba spp.*, *Giardia spp.*, and *Cryptosporidium spp.*, with infection rates of 1%, 2%, and 1% respectively. Finally, *Mite* was detected with an infection rate of 1%, as shown in Table (2).

**Table 1: Prevalence of parasitic infection in the examined fecal samples of cats.**

Infection type	Number of cases	Infection rate	P value
Total infected animals	142/200	71.0%	$P \leq 0.05$
Total non-infected	58/200	29%	
Helminthes infection	132/200	66%	$P \leq 0.05$
Protozoan infection	8/200	4%	
arthropods infection	2/200	1%	

Statistically Significant  $P \leq 0.05$

**Table 2: Prevalence of each parasitic infection in the examined fecal samples of cat.**

Infection type	Number of cases	Infection rate
<b>Helminthes infection</b>		66%
<i>Toxocara leonine</i>	95/200	47.5%
<i>Toxocara cati</i>	20/200	10%
Mixed infection of <i>T. cati</i> & <i>T. leonine</i>	13/200	6.5%
Hookworm infection	4/200	2%
<b>Protozoan infection</b>		4%
<i>Entamoeba</i> spp.	2/200	1%
<i>Giardia</i> spp.	4/200	2%
<i>Cryptosporidium</i> spp.	2/200	1%
<b>Arthropods infection</b>		1%
Mite	2/200	1%

### 3- Risk factors for identified gastrointestinal parasites in examined cats, considering age, sex, and season.

The prevalence of parasitic infection in cats was found 75.3% for those less than 1 year old, 72.9% for cats aged 1-3 years, and 61.5% for cats older than 3 years. When considering the effects of sex on the infection rate, it was observed that the rate was 75% for male cats and 67.3% for female cats. Furthermore, the

infection rates varied by season, with rates of 54% in spring, 42% in summer, 94% in autumn, and 94% in winter. The study found that the total infection rate was only significantly affected by the season ( $P \leq 0.05$ ), while no significant difference was observed related to age and sex. The impact of age, sex, and season on the infection rate of each parasite is specified in Table (3).

**Table 3: Risk factors for identified gastrointestinal parasites in examined cats, considering age, sex, and season.**

Parasite	Age			Gender		Season			
	Less than 1 year n=89	1:3 years n=59	More than 3 years n=52	Tom n=96	Queen n=104	Spring n=50	Summer n=50	Autumn n=50	Winter n=50
<b>Total GIT parasitic infection</b>	67 75.3%	43 72.9%	32 61.5%	72 75%	70 67.3%	27 54%	21 42%	47 94%	47 94%
<b>p. value</b>		.207		.149			.000*		
<b><i>T. leonine</i></b>	50 56.2%	27 45.8%	18 34.6%	47 49.0%	48 46.2%	19 38.0%	15 30.0%	25 50.0%	36 72.0%
<b>p. value</b>		.045*		.399			.000*		
<b><i>T. cati</i></b>	9 10.1%	5 8.5%	6 11.5%	8 8.3%	12 11.5%	4 8.0%	2 4.0%	7 14.0%	7 14.0%
<b>p. value</b>		.865		.303			.261		
<b><i>Hookworm infection</i></b>	2 2.2%	2 3.4%	0 0%	1 1.0%	3 2.9%	0 0%	2 4.0%	1 2.0%	1 2.0%
<b>p. value</b>		.434		.341			.564		
<b><i>Entamoeba sp.</i></b>	2 2.2%	0 0%	0 0%	0 0%	2 1.9%	0 0%	1 2.0%	0 0%	1 2.0%
<b>p. value</b>		.284		.269			.568		
<b><i>Giardia sp.</i></b>	3 3.4%	1 1.7%	0 0%	2 2.1%	2 1.9%	1 2.0%	0 0%	1 2.0%	2 4.0%
<b>p. value</b>		.379		.659			.564		
<b><i>Cryptosporidium</i></b>	2 2.2%	0 0%	0 0%	2 2.1%	0 0%	0 0%	0 0%	1 2.0%	1 2.0%
<b>p. value</b>		.284		.229			.568		
<b><i>Mite</i></b>	0 0%	2 3.4%	0 0%	0 0%	2 1.9%	0 0%	0 0%	0 0%	2 4.0%
<b>p. value</b>		.089		.269			.109		

\*Statistically Significant  $P \leq 0.05$ 

#### 4- Morphological characteristics of different parasitic stages detected by gross and microscopic examination.

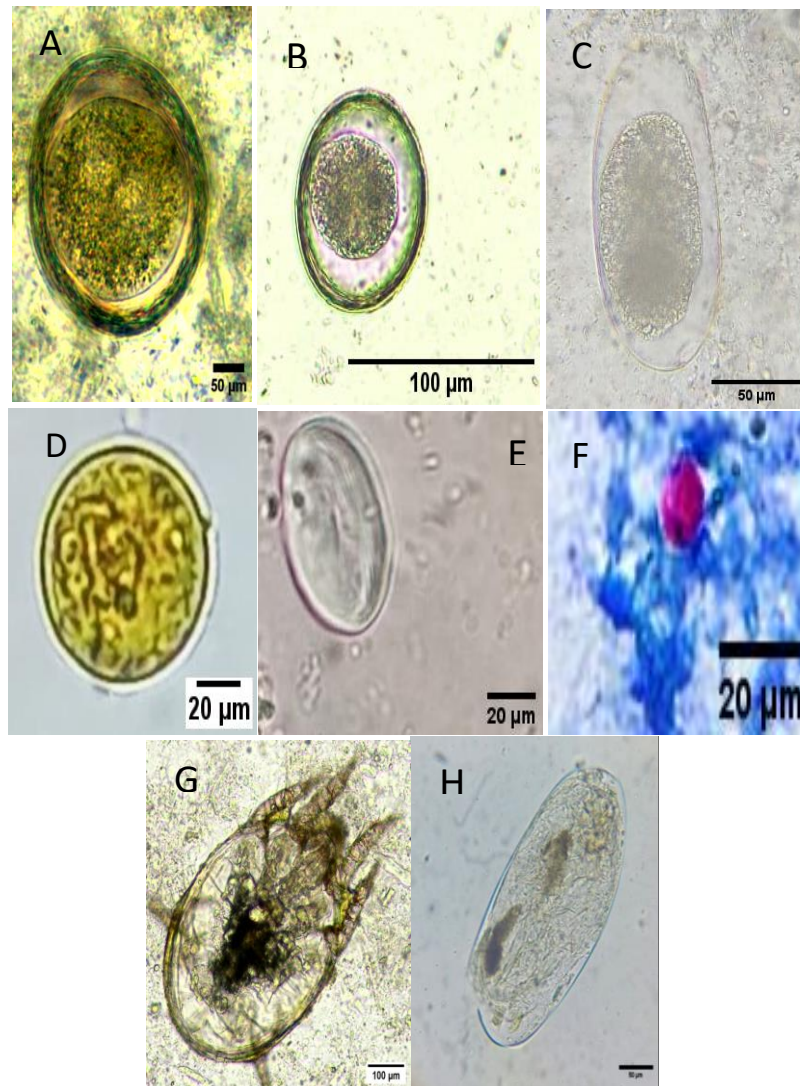
The recovered parasitic stages were identified morphologically using established identification keys. (Bowman *et al.*, 2002, Zajac and Conboy, 2012).

*Toxocaris leonine* eggs are nearly medium-sized ( $75-85 \times 60-75 \mu\text{m}$ ), oval with a dense, smooth outer shell wall containing a light-colored, single-celled embryo. The internal surface of the shell wall appears rough or wavy due to the vitelline membrane. *Toxocara cati* eggs are medium-sized ( $65 \times 75 \mu\text{m}$ ), have a dark, round, single-celled embryo contained in a thick shell wall. While hookworm eggs are medium-sized ( $52-79 \times 28-58 \mu\text{m}$ ), elliptical, have smooth shell

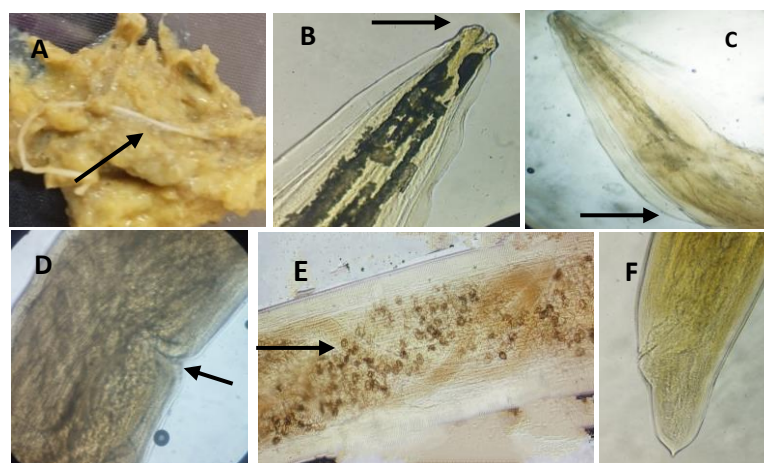
walls containing a grapelike cluster of cells (morula). Various cysts of protozoan parasites were found. The *Entamoeba sp.* cysts were spherical, measuring ( $10-15 \mu\text{m}$ ) in diameter and containing 4 nuclei. The *Giardia* cyst was oval, with 4 nuclei at one pole measuring ( $9-13 \times 7-9 \mu\text{m}$ ). The *Cryptosporidium* oocysts appeared as pale to bright pink spheres, measuring ( $7 \times 5 \mu\text{m}$ ) in diameter, against a blue background as shown in (Fig.2).

Female worms of *Toxocara leonine* were detected in 1% of *Toxocara leonine*-infected samples, measuring 2–10 cm in length and 1.8–2.4 mm in width. They appear cream to pinkish and have a dorsal curvature at the anterior end. Additionally, they possess long, narrow, lanceolate cervical alae that taper gradually into the body (Fig.3).





**Fig. (2):** Morphological character of detected parasites. A) *Toxocara cati* un embryonated egg, B) *Toxocara leonina* un embryonated egg, C) Hookworm un embryonated egg, D) *Entamoeba* sp. cyst, E) *Giardia* sp. cyst, F) *Cryptosporidium* sp. cyst. G) *Mite* spp. adult H) *Mite* spp. egg.

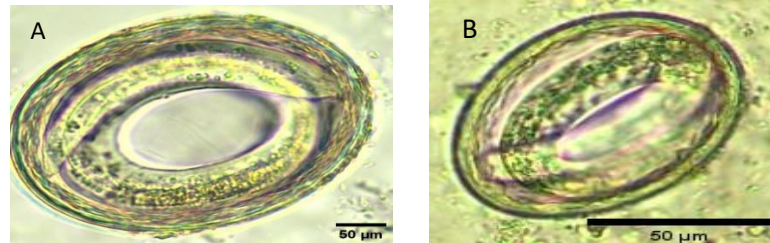


**Fig. 3:** Gross and microscopic examination of *Toxascaris leonine* adult worm A) *T. leonine* in fecal samples B) *T. leonine* anterior end showing three lips (arrow), C) *T. leonine* anterior end showing cervical Alea D) *T. leonine* female region of the vulva E) *T. leonine* female uterus filled with egg F) *T. leonine* female posterior end.

### 5- Fecal culture and embryonation of *Toxocara spp.* egg.

A 0.01% sodium bicarbonate solution successfully induced the embryonation of *Toxocara* eggs, with approximately 60% of

the eggs becoming embryonated. After 15 to 20 days, fecal culture samples were examined using direct smear and flotation methods to confirm the presence of motile larvae inside the eggs as shown in Fig. 4.



**Fig.4:** showing A) *Toxocara cati* embryonated egg, B) *Toxocara leonina* embryonated egg

## DISCUSSION

In Egypt, cats coexist with humans, sharing the same environmental spaces and resources. This close relationship can have implications for public health. Our study is the first to report the prevalence and diversity of gastrointestinal parasites in cats from Sohag Governorate, Egypt. This research will help us develop effective preventive measures and control strategies against feline endoparasite infections. Ultimately, it aims to enhance the well-being of cats and improve public health overall.

Various methods were employed to isolate parasites from fecal samples, including direct smear examination, simple sedimentation, formal ether sedimentation, and flotation technique using Sheather's solution. Among these techniques, the flotation method was found to be the most effective for isolating and collecting *Toxocara* eggs and protozoan oocysts (Abbas *et al.*, 2022)

Our result revealed a high overall prevalence of 71.0%, which was lower than that reported by (Khalafalla, 2011) in Kafer-Elsheikh (91%) and (Sharif *et al.*, 2007) in Northern Iran (90%) and more than that reported by (Abbas *et al.*, 2022), who found that the prevalence of the GIT parasitic infection in cats was 52.4% in Gharbia governorate and (Genchi *et al.*, 2021) in Italy was 35.9%. This variation in prevalence may be due to

differences in geographical areas, medical care, seasons, cat habitats, hygiene, and feeding habits (El-Seify *et al.*, 2017).

The results of the current study revealed that the prevalence of helminthic infection was 66%, the most prevalent parasites were *T. leonina* (47.5%), *T. cati* (10%), followed by hookworm infection (2%), *T. cati* is considered as the most prevalent helminthic parasites in cats worldwide (Rostami *et al.*, 2020). The prevalence of *T. leonina* (47.5%) is higher than that detected by (Khalafalla, 2011) (5%) and (Abbas *et al.*, 2022) who proved that *T. leonina* was 22%. The prevalence of *T. cati* (10%) was lower than that reported by Abbas *et al.* (2022) (30%) and (Hadi & Faraj, 2014) who proved that the prevalence of *T. cati* in Baghdad was (12.9). The higher prevalence of *Toxocara sp.* eggs may be attributed to their ability to persist in the environment. This is supported by research that shows *Toxocara sp.* eggs have frequently been found in soil samples in Egypt, with high concentrations ranging from 13 to 19 eggs per 10 grams of soil (El-Shazly *et al.*, 2009). The high prevalence of *Toxocara sp.* in both stray and domestic cat populations serves as a significant reservoir for the parasite. This leads to the ongoing release of infectious eggs into the surrounding soil, grass, and other surfaces. As a result, there are important implications for human health, including the risk of serious cases of visceral larval migrans. (Adeel,



2020).

The prevalence of hookworm infection was found 2%, which is lower than the previously reported 4.5% (Giannelli *et al.*, 2017) and 8.4% (Abbas *et al.*, 2022). The lower prevalence of hookworm infection in cats, compared to other helminthic infections, may be attributed to the specific habits and transmission methods of the hookworm's infective larvae, these larvae typically require adequate humidity and moisture levels to successfully develop and still viable until they are transmitted to the host.

The overall prevalence rate of protozoan infection, was 4%, with 1% for *Entamoeba* spp., 2% for *Giardia* spp., and 1% for *Cryptosporidium* spp. Our findings showed a lower prevalence compared to previous research by (Abbas *et al.*, 2022). The prevalence of *Giardia* (2%) matched the findings of (Khalafalla, 2011), while the prevalence of *Cryptosporidium* spp. was 1% lower than that reported by (Hamnes *et al.*, 2007) and (Meng *et al.*, 2021). From our findings, the protozoal infections (*Entamoeba* spp., *Giardia* spp., and *Cryptosporidium* spp.) are not prevalent and do not have a significant impact on examined cats, this is in agreement with (Zajac *et al.*, 2012).

In our examination, only 1% of the cats tested positive for mite infections. No research studies have found mites, whether adult or in egg form, in the fecal samples of cats. Therefore, we can conclude that mite infections may occur accidentally when cats groom themselves or may be transmitted through contaminated food and water carrying different mite species.

The present study examined the prevalence of various infections based on age, sex, and season. Cats less than 1 year old had the highest prevalence (75%), and there was a decrease in the infection rate with age, with no significant differences between different age groups. The findings are consistent with those reported by (Gennari *et al.*, 2016), (El-

Seify *et al.*, 2021), and (de Oliveira *et al.*, 2021), who demonstrated a decrease in parasitic infection with age. This could be due to the complex life cycle of *Toxocara*, which leads to kittens getting infected through various means, such as ingesting embryonated eggs or being exposed to infective larvae through their infected mother's milk, or it could be attributed to the development of parasite-specific immunity that typically occurs as cats age, or possibly as a result of single or repeated infestations. This contrasts with the findings of (Mohsen & Hossein, 2009 and Genchi *et al.* (2021)), who reported that age does not affect the prevalence of *Toxocara*.

In terms of gender, there was no significant difference in the prevalence of GIT parasitic infection between males and females, This is in agreement with (Ridwan *et al.*, 2023). Our findings showed that females are more affected by *T. leonine* than males. This is in agreement with (El-Seify *et al.* 2021 and Darabi *et al.*, 2021), who demonstrated that the prevalence of *Toxocara* in female cats was higher than in male cats. Our research revealed that the infection rates varied by season. The rate of parasitic infection was 94% in autumn, 94% in winter, 54% in spring, and 42% in summer. There were significant differences in the prevalence of gastrointestinal (GIT) parasitic infections across different seasons ( $P < 0.05$ ). These variations may be attributed to the requirements of eggs and protozoan cysts, which need humid weather for embryonation and development, rather than hot and dry conditions.

Although *Toxocara* spp. eggs can easily embryonate in the soil spontaneously, it is challenging to replicate this process in the lab. We used sodium bicarbonate to embryonate the eggs and observed that 60% of the eggs were successfully embryonated after being collected using flotation techniques.

## CONCLUSION

This study highlights the significant prevalence of gastrointestinal parasites among domestic cats in Sohag Governorate, Egypt, with 71% of the examined cats infected. The findings emphasize the dominance of *Toxocara leonine* and *Toxocara cati*, alongside other less prevalent parasites. Notably, seasonal factors influenced infection rates, while age and gender did not show a significant impact. These results underscore the urgent need for effective parasite control measures to protect feline health and mitigate potential public health risks.

## REFERENCES

- Abbas, I.; Al-Araby, M.; Elmishmishy, B. and El-Alfy, E.-S. (2022): Gastrointestinal parasites of cats in Egypt: high prevalence high zoonotic risk. *BMC Veterinary Research*, 18(1), 420. <https://doi.org/10.1186/s12917-022-03520-0>
- Abd-Elrahman, S.M.; Dyab, A.K.; Kamel, F.A.; Khedr, A.A.; Khalifa, M.M.; Mohamed, S.M. and Abdel-Hakeem, S.S. (2024): Assessment of cattle tick infestation: Molecular insights into *Rhipicephalus annulatus* and the efficacy of garlic oil and nanoemulsion as acaricidal agents. *Veterinary Parasitology*, 329(May), 110211. <https://doi.org/10.1016/j.vetpar.2024.110211>
- Abd-Elrahman, S.M.; Dyab, A.K.; Mahmoud, A.E.S.; Alsharif, F.M.; Mohamed, S.M.; Abomughaid, M.M. and Elossily, N.A. (2021): Influence of chemically and biosynthesized silver nanoparticles on in vitro viability and infectivity of *Trichinella spiralis* muscle larvae. *Annals of Parasitology*, 67(4), 591–602. <https://doi.org/10.17420/ap6704.375>
- Abd-ELrahman, S.M.; Gareh, A.; Mohamed, H.I.; Alrashdi, B.M.; Dyab, A.K.; El-Khadragy, M.F.; Khairy Elbarbary, N.; Fouad, A.M.; El-Gohary, F.A.; Elmahallawy, E.K. and Mohamed, S.A.A. (2023): Prevalence and Morphological Investigation of Parasitic Infection in Freshwater Fish (Nile Tilapia) from Upper Egypt. *Animals*, 13(6), 1–16. <https://doi.org/10.3390/ani13061088>
- Abd-ELrahman, S.M.; Mohamed, S.A.A.; Mohamed, S.E.; El-Khadragy, M.F.; Dyab, A.K.; Hamad, N.; Safwat, M.M.; Nasr, A.A.E.; Alkhaldi, A.A.M.; Gareh, A. and Elmahallawy, E.K. (2022): Comparative Effect of Allicin and Alcoholic Garlic Extract on the Morphology and Infectivity of *Eimeria tenella* Oocysts in Chickens. *Animals*, 12(22). <https://doi.org/10.3390/ani12223185>
- Abd El-Rady, L.M.; Dyab, A.K.; Abd-Elrahman, S.M. and Mohamed, S.A. (2021): Prevalence Of Gastrointestinal Parasites In Horses In Luxor, Egypt. *Assiut Veterinary Medical Journal*, 67(171), 12–20. <https://doi.org/10.21608/avmj.2021.205162>
- Adeel, A.A. (2020): Chapter Twenty-Five - Seroepidemiology of human toxocariasis in North Africa. In D. D.B. T.-A. in P. Bowman (Ed.), *Toxocara and Toxocariasis* (Vol. 109, pp. 501–534). Academic Press. <https://doi.org/https://doi.org/10.1016/bs.apar.2020.01.023>
- Adhikari, R.B.; Dhakal, M.A.; Ale, P.B.; Regmi, G.R. and Ghimire, T.R. (2023): Survey on the prevalence of intestinal parasites in domestic cats (*Felis catus* Linnaeus, 1758) in central Nepal. *Veterinary Medicine and Science*, 9(2), 559–571. <https://doi.org/https://doi.org/10.1002/vms3.999>
- Darabi, E.; Kia, E.B.; Moheballi, M.; Mobedi, I.; Zahabiun, F.; Zarei, Z.; Khodabakhsh, M.; and Khanaliha, K. (2021): Gastrointestinal Helminthic Parasites of Stray Cats (*Felis catus*) in Northwest Iran. *Iranian Journal of Parasitology*, 16(3), 418–425. <https://doi.org/10.18502/ijpa.v16i3.709>

- 5
- De Oliveira, A.G.L.; Sudré, A.P.; Bergamo do Bomfim, T.C. and Santos, H.L.C. (2021): Molecular characterization of *Cryptosporidium* spp. in dogs and cats in the city of Rio de Janeiro, Brazil, reveals potentially zoonotic species and genotype. *PLoS One*, 16(8), e0255087. <https://doi.org/10.1371/journal.pone.0255087>
- El-Seify, M.A.; Aggour, M.G.; Sultan, K. and Marey, N.M. (2017): Gastrointestinal helminths of stray cats in Alexandria, Egypt: A fecal examination survey study. *Veterinary Parasitology, Regional Studies and Reports*, 8, 104–106. <https://doi.org/10.1016/j.vprsr.2017.03.003>
- El-Seify, M.A.; Marey, N.M.; Satour, N.; Elhawary, N.M. and Sultan, K. (2021): Prevalence and Molecular Characterization of *Toxocara cati* Infection in Feral Cats in Alexandria City, Northern Egypt. *Iranian Journal of Parasitology*, 16(2), 270–278. <https://doi.org/10.18502/ijpa.v16i2.6319>
- El-Shazly, A.M.; Mohammed, R.M.; El-Beshbishi, S.N.; Azab, M.S.; El-Ghareeb, A.S.; Abdeltawab, A.H. and Zalook, T.K.H. (2009): Soil-parasites particularly *Toxocara* eggs in Egypt. *Journal of the Egyptian Society of Parasitology*, 39(1), 151–162.
- Elossily, N.; Salwa, Mohamed, A.; Dyab, A.; Mahmoud, E.; Mohamed, S.; Abd, A.; Fahd, Alsharif, F.; Alsaadawy, M.; Sayed, K. and Khalifa, M. (2024): Light microscopical and parasitological analyses revealed the beneficial effects of silver nanoparticles and various myrrh extracts against *Trichinella spiralis* infection in mice. *Microscopy Research and Technique*. <https://doi.org/10.1002/jemt.24542>
- Genchi, M.; Vismarra, A.; Zanet, S.; Morelli, S.; Galuppi, R.; Cringoli, G.; Lia, R.; Diaferia, M.; Frangipane di Regalbono, A.; Venegoni, G.; Solari Basano, F.; Varcasia, A.; Perrucci, S.; Musella, V.; Brianti, E.; Gazzonis, A.; Drigo, M.; Colombo, L. and Kramer, L. (2021): Prevalence and risk factors associated with cat parasites in Italy: a multicenter study. *Parasites and Vectors*, 14(1), 475. <https://doi.org/10.1186/s13071-021-04981-2>
- Gennari, S.M.; Ferreira, J.I.G. Da S.; Pena, H.F.De J.; Labruna, M.B. and Azevedo, S.D.S. (2016): Frequency of gastrointestinal parasites in cats seen at the University of São Paulo Veterinary Hospital, Brazil. *Revista Brasileira de Parasitologia Veterinaria = Brazilian Journal of Veterinary Parasitology: Orgao Oficial Do Colegio Brasileiro de Parasitologia Veterinaria*, 25(4), 423–428. <https://doi.org/10.1590/S1984-29612016082>
- Giannelli, A.; Capelli, G.; Joachim, A.; Hinney, B.; Losson, B.; Kirkova, Z.; René-Martellet, M.; Papadopoulos, E.; Farkas, R.; Napoli, E.; Brianti, E.; Tamponi, C.; Varcasia, A.; Margarida Alho, A.; Madeira de Carvalho, L.; Cardoso, L.; Maia, C.; Mircean, V.; Mihalca, A.D. and Otranto, D. (2017): Lungworms and gastrointestinal parasites of domestic cats: a European perspective. *International Journal for Parasitology*, 47(9), 517–528. <https://doi.org/10.1016/j.ijpara.2017.02.003>
- Hadi, A.M. and Faraj, A.A. (2014): Role of Domestic Cats *Felis Catus* as Reservoir Hosts of Internal Parasites and Protozoa in Baghdad. <https://api.semanticscholar.org/CorpusID:198163733>
- Hammes, I.S.; Gjerde, B.K. and Robertson, L.J. (2007): A longitudinal study on the occurrence of *Cryptosporidium* and *Giardia* in dogs during their first year of life. *Acta Veterinaria Scandinavica*, 49(1), 22. <https://doi.org/10.1186/1751-0147-49-22>
- Jarosz, W.; Durant, J.-F.; Ireng, L. M. W. B.; Fogt-Wyrwas, R.; Mizgajski-Wiktor, H. and Gala, J.-L. (2021):

- Optimized DNA-based identification of *Toxocara* spp. eggs in soil and sand samples. *Parasites and Vectors*, 14(1), 426. <https://doi.org/10.1186/s13071-021-04904-1>
- Kamel, F.A.; Dyab, A.K.; Khedr, A.A. and Abd-Elrahman, S.M. (2024): Epidemiological And Clinical Manifestations Of Blood Parasitic Infections In Cattle In Assiut Governorate Egypt. *Assiut Veterinary Medical Journal*, 70 (181), 8–16. <https://doi.org/10.21608/avmj.2024.246898.1203>
- Khalafalla, R.E. (2011): A survey study on gastrointestinal parasites of stray cats in northern region of Nile delta, Egypt. *PloS One*, 6(7), e20283. <https://doi.org/10.1371/journal.pone.0020283>
- Lamido, T.Z.; Yahaya, Y.; Yahaya, S.U.; Jummai, G.F. and Adebola, O. (2022): Comparison of Modified Ziehl Neelsen Staining Technique With Antigen Detection Using ELISA in the Diagnosis of Cryptosporidiosis at a Tertiary Hospital in North-Western Nigeria. *African Journal of Microbiology Research*, 16(9), 296–300. <https://doi.org/10.5897/AJMR2022.9646>
- Meng, X.-Z.; Li, M.-Y.; Lyu, C.; Qin, Y.-F., Zhao, Z.-Y.; Yang, X.-B.; Ma, N.; Zhang, Y. and Zhao, Q. (2021): The global prevalence and risk factors of *Cryptosporidium* infection among cats during 1988-2021: A systematic review and meta-analysis. *Microbial Pathogenesis*, 158, 105096. <https://doi.org/10.1016/j.micpath.2021.105096>
- Mohamed, S.A.-A., Dyab, A.K.; Raya-Álvarez, E.; Abdel-Aziz, F.M.; Osman, F.; Gareh, A.; Farag, A.M.M.; Salman, D.; El-Khadragy, M.F.; Bravo-Barriga, D.; Agil, A. and Elmahallawy, E.K. (2024): Molecular identification of *Haemonchus contortus* in sheep from Upper Egypt . In *Frontiers in Veterinary Science* (Vol. 10). <https://www.frontiersin.org/articles/10.3389/fvets.2023.1327424>
- Mohamed, S.E.; Dyab, A.K.; Mohamed, S.A. and Abd-Elrahman, S.M. (2021): Prevalence of Coccidiosis in Chicken in Sohage Governorate. *Assiut Veterinary Medical Journal (Egypt)*, 67(171), 1–11. <https://doi.org/10.21608/AVMJ.2021.205152>
- Mohsen, A. and Hossein, H. (2009): Gastrointestinal parasites of stray cats in Kashan, Iran. *Tropical Biomedicine*, 26(1), 16–22.
- Morelli, S.; Diakou, A.; Di Cesare, A.; Colombo, M. and Traversa, D. (2021): Canine and Feline Parasitology: Analogies, Differences, and Relevance for Human Health. *Clinical Microbiology Reviews*, 34(4), e0026620. <https://doi.org/10.1128/CMR.00266-20>
- Qadir, S.; Dixit, A.K.; Dixit, P. and Sharma, R.L. (2011): Intestinal helminths induce haematological changes in dogs from Jabalpur, India. *Journal of Helminthology*, 85(4), 401–403. <https://doi.org/10.1017/S0022149X10000726>
- Ridwan, Y.; Sudarnika, E.; Dewi, T.I.T. and Budiono, N.G. (2023): Gastrointestinal helminth parasites of pets: Retrospective study at the veterinary teaching hospital, IPB University, Bogor, Indonesia. *Veterinary World*, 16(5), 1043–1051. <https://doi.org/10.14202/vetworld.2023.1043-1051>
- Rostami, A.; Sepidarkish, M.; Ma, G.; Wang, T.; Ebrahimi, M.; Fakhri, Y.; Mirjalali, H.; Hofmann, A.; Macpherson, C.N.L.; Hotez, P.J. and Gasser, R.B. (2020): Global prevalence of *Toxocara* infection in cats. *Advances in Parasitology*, 109, 615–639. <https://doi.org/10.1016/bs.apar.2020.01.025>
- Sharif, M.; Nasrolahei, M.; Ziapour, S.P.; Gholami, S.; Ziaei, H.; Daryani, A. and Khalilian, A. (2007): *Toxocara cati*

- infections in stray cats in northern Iran. *Journal of Helminthology*, 81(1), 63–66.  
<https://doi.org/10.1017/S0022149X07214117>
- Van Bezooijen, J. (2006). Methods and Techniques for Nematology. 1–118.
- Yousef, A.M.; Abdel-Radi, S.; Dyab, A.K.; Khedr, A.A. and Abd Elrahman, S.M. (2024): A study on ectoparasites infesting domestic cats in Giza Governorate, Egypt. *Assiut Veterinary Medical Journal*, 70(182), 192–207.  
<https://doi.org/10.21608/avmj.2024.198094.1235>
- Zajac, A.M.; Conboy, G.A.; Greiner, E.C.; Smith, S.A. and Snowden, K.F. (2012): Fecal Examination for the Diagnosis of Parasitism. In *Veterinary Clinical Parasitology*.

## دراسة حول انتشار الطفيليات المعوية في القطط المنزلية بمحافظة سوهاج، مصر

سامية محمد عبد الله ، احمد كمال دياب ، سلوى محمود عبد الرحمن

Email: [ahmed2015@aun.edu.eg](mailto:ahmed2015@aun.edu.eg) Assiut University web-site: [www.aun.edu.eg](http://www.aun.edu.eg)

تشكل الطفيليات المعوية تهديداً كبيراً لصحة القطط المنزلية على مستوى العالم، بما في ذلك مصر. تُعتبر هذه الدراسة الأولى التي تحقق في وجود الطفيليات المعوية في براز القطط المنزلية في محافظة سوهاج، مصر. تم جمع ٢٠٠ عينة براز من أنواع مختلفة من القطط المنزلية وتم تحليلها باستخدام المجهر الضوئي في كلية الطب البيطري بجامعة أسيوط. تم استخدام عدة تقنيات لعزل مراحل الطفيليات المختلفة، بما في ذلك فحص المسحة المباشرة، والترسيب البسيط، والترسيب باستخدام الإيثير الفورمالي، وتقنية الطفو باستخدام محلول السكر المشبع. وقد أظهرت طريقة الطفو أعلى كفاءة في عزل بيض التوكسوكارا والأكياس الأولية للطفيليات. تشير نتائجنا إلى انتشار عالٍ للعدوى بالطفيليات المعوية، حيث كانت ٧١٪ من القطط التي تم فحصها تحمل على الأقل نوعاً واحداً من الطفيليات. وكان الطفيل الأكثر شيوعاً هو التوكسوكارا كاتي (47.5%)، يليه التوكسوكارا ليونينا (10%)، وحالات العدوى المختلطة من كلا النوعين (٦,٥%). وشملت الطفيليات الأخرى الأقل انتشاراً بيض الديدان الانكليستوما (٢٪)، والجيارديا (2%)، والكريبتوسبورديم (1%)، والانتيميا (1%)، وعدوى العث (١٪). ومن الملاحظ أن عملية تكوين الأجنة لبيض التوكسوكارا قد تمت باستخدام محلول بيكرينات الصوديوم بتركيز ٠,٠١٪، مما أدى إلى تكوين أجنة لأكثر من ٦٠٪ من البيض. لم تُظهر معدلات انتشار العدوى بالطفيليات اختلافات كبيرة بناءً على العمر أو الجنس؛ ومع ذلك، كانت العوامل الموسمية تؤثر بشكل كبير على المعدلات. تؤكد هذه النتائج على الانتشار العالي للطفيليات المعوية بين القطط المنزلية في محافظة سوهاج، مما يبرز الحاجة الملحة إلى استراتيجيات فعالة لمكافحة الطفيليات لحماية صحة القطط وصحة المجتمع.