

# Follow-up after Heller cardiomyotomy for achalasia, combined prospective and retrospective study

Original  
Article

Mohamed F. Elharoun, Helmy Ezzat, Ahmed Elghawalby, Mohamad Elrefai and Ali Salem

Department of General Surgery, Faculty of Medicine, Mansoura University, Mansoura, Egypt.

## ABSTRACT

**Background:** Achalasia is an idiopathic esophageal motility disorder characterized by nonrelaxation of the lower esophageal sphincter. The purpose of achalasia treatment is symptom improvement, which is achieved by reducing lower esophageal sphincter resting pressure thus enabling the food bolus passage into the stomach.

A combination of Heller myotomy with Dor fundoplication is recommended to decrease postoperative pathologic gastroesophageal reflux.

**Aim:** To evaluate the postoperative outcomes after Heller cardiomyotomy and Dor fundoplication for patients diagnosed with achalasia.

**Patients and Methods:** This combined prospective and retrospective study included 362 patients who underwent the Heller procedure for achalasia. Patients were asked to score their symptom severity based on the Eckardt scoring system, which was comprised of four symptoms: dysphagia, regurgitation, retrosternal pain, and weight loss. All cases were followed for at least one year after operation.

**Results:** The procedure was associated with a significant decline in Eckardt dysphagia, Eckardt chest pain, Eckardt regurgitation, and weight loss scores over the 2-year follow-up period. Eating assessment tool score expressed a significantly decline over the 2-year follow-up period. The total Eckardt score showed a significant decline after the procedure compared with the baseline value. Gastroesophageal Reflux Disease-Health-Related Quality-of-Life Scale increased significantly after the myotomy procedure, as it had increased follow-up values compared with the corresponding baseline ones.

**Conclusion:** The Heller-Dor operation provides sustained symptom relief and a satisfactory quality of life 2 years after surgery.

**Key Words:** Achalasia, Eckardt scoring system, esophageal manometry, gastroesophageal reflux disease-health-related quality-of-life scale, Heller cardiomyotomy.

**Received:** 13 July 2024, **Accepted:** 7 August 2024, **Published:** 1 January 2025

**Corresponding Author:** Mohamed F. Elharoun, MD, Department of General Surgery, Faculty of Medicine, Mansoura University, Mansoura, Egypt. **Tel.:** 01002054058, **E-mail:** mohamedelharoun61@gmail.com

**ISSN:** 1110-1121, January 2025, Vol. 44, No. 1: 20–27, © The Egyptian Journal of Surgery

## INTRODUCTION

Achalasia is an idiopathic esophageal motility disorder in which the lower esophageal sphincter (LES) does not relax normally and peristalsis is either absent or abnormal<sup>[1,2]</sup>. With an annual incidence of about 1/100 000 people and a prevalence of 10/100 000, achalasia is an extremely rare condition<sup>[3]</sup>.

Achalasia is thought to occur due to the degeneration of the myenteric plexus and vagus nerve fibers of the LES. There is a loss of inhibitory neurons containing vasoactive intestinal peptide and nitric oxide synthase at the esophageal myenteric plexus, but in severe cases, it also involves cholinergic neurons<sup>[4,5]</sup>. The exact etiology of this degeneration is unclear though many theories have

been proposed. These theories include an autoimmune phenomenon, viral infection, and genetic predisposition<sup>[5]</sup>.

Dysphagia for solids and liquids and regurgitation of undigested food or saliva are the most frequent symptoms in patients with achalasia. Other symptoms include chest pain, heartburn, and difficulty belching<sup>[6]</sup>.

Esophageal manometry is required to establish the diagnosis. In patients with equivocal esophageal manometric results, a barium esophagram should be performed to assess esophageal emptying and esophagogastric junction morphology. Upper endoscopy should be performed in all patients with achalasia to exclude an esophagogastric malignancy<sup>[7,8]</sup>.

Reduction of the LES resting pressure facilitates the food bolus passage into the stomach, which is the goal of achalasia treatment. There are currently two types of therapy options for primary idiopathic achalasia: nonsurgical and surgical. Pharmacotherapy, endoscopic injection of botulinum toxin, and pneumatic dilatation are nonsurgical alternatives. Peroral endoscopic myotomy and Heller myotomy are the available surgical treatments<sup>[9,10]</sup>.

For nearly 20 years, Heller myotomy has been the gold standard for treatment<sup>[11,12]</sup>. A potential side effect of this procedure is gastroesophageal reflux. Therefore, combining Heller myotomy with anterior (Dor) fundoplication is recommended to decrease postoperative pathologic gastroesophageal reflux<sup>[13]</sup>.

### ***Aim***

The current study aimed to evaluate the postoperative outcomes after Heller cardiomyotomy and Dor fundoplication for patients diagnosed with achalasia.

### **PATIENTS AND METHODS:**

This was a combined prospective and retrospective study that was conducted at the Gastrointestinal Surgical Center, Mansoura University, Mansoura, Egypt. This study included 362 patients who underwent the Heller procedure for achalasia. The retrospective part of the study included 312 patients who underwent the Heller procedure in our center for achalasia during the period between January 2011 and March 2022. This study excluded patients with previous gastric or esophageal operations, patients with esophageal peptic stricture, uncontrolled systemic comorbidities, and patients contraindicated to general anesthesia and operation.

### ***Ethical consideration***

The study got approval from the local scientific committee and Institutional Review Board (IRB) of the Faculty of Medicine, Mansoura University. Informed written consent was obtained from all participants after complete explanation of the benefits and drawbacks of each intervention. Patients felt free to withdraw from the study at any time point, based on their request. Patient confidentiality was ensured, and the collected data was used only for scientific purposes.

### ***Methods***

Every patient was subject to history taking that included name, age, sex, occupation, residence, and special habits, current complaint with its analysis, previous medical, endoscopic, or surgical interventions for the same complaint (like balloon dilatation or botulinum toxin injection), systemic comorbidities, current medications, and any previous surgical history.

Patients were asked to score their symptom severity based on the Eckardt scoring (ES) system, which is comprised of four symptoms: dysphagia, regurgitation, retrosternal pain, and weight loss. It attributes points (0 to 3 points) for each of the four symptoms of the disease, with the total score ranging from 0 to 12<sup>[14]</sup>.

Dysphagia was assessed using the Eating assessment tool (EAT-10), which comprised 10 items to be rated on a five-point response scale (0–4) with labels at the extremes of ‘0=No problem’ and ‘4=Severe problem’, resulting in a range of 0–40<sup>[15]</sup>. Preoperative reflux symptoms were evaluated via the Gastroesophageal Reflux Disease-Health-Related Quality-of-Life Scale (GERDHRQL). The GERDHRQL score was derived from simply adding the scores from each of the nine items. The best possible score is zero (i.e., asymptomatic in each item) and the worst possible score is 45<sup>[16]</sup>.

Every patient had a general and local abdominal examination. The routine laboratory investigations included complete blood count (CBC), liver and kidney function tests, random blood sugar, international normalized ratio (INR), and virology markers (hepatitis C antibody, hepatitis B surface antigen, and HIV Ab).

Barium meal study was ordered for all cases to confirm the exact site of stricture and to exclude malignant causes of dysphagia. Patients will be classified as having straight or sigmoid esophagus. Upper gastrointestinal endoscopy was done for all cases to exclude patients with pseudoachalasia in which there are symptoms and manometric findings like achalasia but occurs due to any cause other than idiopathic degeneration of inhibitory neurons of the esophageal submucosal myenteric plexus. Esophageal manometry was performed for all cases to define LES pressure along with esophageal motility status. This was used to confirm our diagnosis. Achalasia was classified according to Chicago classification into Types I, II, and III<sup>[17]</sup>.

### ***Surgical procedure***

All surgeries were performed via the open or the laparoscopic approaches under general anesthesia. In both procedures, the abdominal esophagus was dissected freely from its diaphragmatic attachments, including the phrenicoesophageal membrane. Long myotomy was performed including 7 cm from the esophageal side and 3 cm from the gastric side. All muscle fibers were cut, till clear visualization of the mucosa and the nasogastric tube inside the lumen. After that, a Dor fundoplication was performed. After a good wash and hemostasis, drain insertion, the abdominal wound was closed.

Postoperative, all patients received the standard postoperative care, and oral fluid was allowed on the first postoperative day unless complications were encountered. Any complications like esophageal perforation, bleeding, or infection were noted and recorded.

### Follow-up

All cases were followed for at least 1 year after operation. Follow-up visits were scheduled at 1, 3, 6, 12, and 24 months after surgery.

During these visits, a clinical assessment of the cases was done. The same three scores applied preoperatively were repeated at follow-up. A postoperative Eckardt score greater than 3 was considered a treatment failure. Investigations like barium meal, upper endoscopy, and manometry will be ordered if the patient reports significant symptoms needing further assessment. The rate of reoperation was also assessed.

Primary outcomes included improvement of dysphagia measured by the EAT-10 assessment tool and the secondary outcomes included hospital stay, postoperative complications, improvement of other symptoms, GERD changes, and need for reoperation or balloon dilatation.

### Statistical analysis

The collected data was coded, processed and analyzed using the SPSS program (version 22) for Mac. The appropriate statistical tests were used when needed. The level of statistical significance will be considered at 5% (*P* value 0.05)

### RESULTS:

Table 1 shows that the mean age of the included cases was 43.48 years. Women were slightly predominant than men (54.7% vs. 45.3%, respectively). Their BMI ranged between 16.51 and 35.23 kg/m<sup>2</sup>. Smokers represented 13% of the study population. Regarding their physical status, most patients had class I (74.3%), followed by class II (24%), while the minority had class III (1.7%). The duration of manifestations ranged between one and ten years. The history of previous balloon dilatation was positive in 24.3% of cases. Regarding the applied scores and questionnaires, the total Eckardt score ranged between 2 and 12. Preoperative EAT-10 score had a mean value of 35.34 (30–40), while GERDHRQL questionnaire had a mean value of 1.21. Preoperative hemoglobin and albumin mean levels were 12.57 and 3.99 gm/dl, respectively. On barium examination, most cases had a straight esophagus (72.7%), while the remaining ratio had a sigmoid one. Regarding manometric findings, LES had a mean value of 46.72 mm Hg, while % LES relaxation was 63.39%. Abdominal and total LES had mean values of 2.81 and 3.91 cm, respectively.

Table 2 shows the duration of the surgical myotomy procedure ranged between 1.5 and 4 h (mean = 1.99). The mucosal injury occurred in 49 (13.5%) cases and all these cases were discovered intraoperatively, apart from 1 case who developed postoperative abdominal collection

and required reoperation (late mucosal perforation). Most myotomy procedures were performed via laparoscopy (66%), while the open approach was used in 28.2% of cases. The remaining cases (5.8%) showed failure of the laparoscopic approach which was mainly secondary to the occurrence of intraoperative mucosal injury. Esophageal muscle division was achieved by harmonic scalpel (56.9%), Kelly clamp (28.2%), or ligasure (14.9%).

Table 3 shows postoperative abdominal collection occurred in only one (0.3%) patient secondary to delayed mucosal perforation. That patient required reoperation and repair of the injury. The duration of the first oral fluid intake ranged between 1 and 8 days (mean = 1.73), while the hospitalization period ranged between 2 and 12 days (mean = 2.94). During the scheduled 2-year follow-up, recurrence was detected in 36 cases, with an incidence of 9.94%, 13 cases of them were presented with sigmoid-shaped esophagus. The median age of the patients at the time of reoperation for recurrence was 53 years. 46% of the patients were male. Recurrence rates were raised in elevated BMI patients. In patients who developed recurrence, 19 of them were managed by endoscopic balloon dilatation, while the remaining cases underwent redo-myotomy (Fig. 1).

Table 4 shows that the myotomy procedure was associated with a significant decline in Eckardt dysphagia score over the 2-year follow-up period (*P*<0.001). EAT-10 score expressed equivalent changes to the Eckardt dysphagia score, as it significantly declines over the 2-year follow-up period. Eckardt chest pain score showed a significant decline over the scheduled follow-up period (*P*<0.001). Eckardt regurgitation and weight loss scores showed similar changes after the same procedure. The total Eckardt score showed a significant decline after the procedure compared with the baseline value (*P*<0.001).

Table 5 shows that GERDHRQL increased significantly after the myotomy procedure, as it had increased follow-up values compared with the corresponding baseline ones.

**Table 1:** Baseline demographic and Preoperative clinical, laboratory, radiological, and manometric findings

Parameter	Data (n=362)
Age (years)	
Mean (SD)	43.48±10.88
Median (range)	45 (18–60)
Sex, n (%)	
Male	164 (45.3)
Female	198 (54.7)
BMI (kg/m <sup>2</sup> )	
Mean (SD)	23.91±3.58
Median (range)	23.46 (16.51–35.23)
Smoking, n (%)	47 (13)
ASA class, n (%)	

I	269 (74.3)
II	87 (24)
III	6 (1.7)
Disease duration (years)	
Mean (SD)	3.35±1.98
Median (range)	3 (1–10)
Previous balloon dilatation, <i>n</i> (%)	88 (24.3)
Eckardt dysphagia score	
Mean (SD)	2.64±0.48
Median (range)	3 (2–3)
Eckardt pain score	
Mean (SD)	1.46±1.15
Median (range)	1 (0–3)
Eckardt regurgitation score	
Mean (SD)	1.59±1.14
Median (range)	2 (0–3)
Eckardt weight loss score	
Mean (SD)	1.53±1.1
Median (range)	2 (0–3)
Eckardt total score	
Mean (SD)	7.23±1.93
Median (range)	7 (2–12)
EAT-10	
Mean (SD)	35.34±3.09
Median (range)	35 (30–40)
Reflux GERDHRQL score	
Mean (SD)	1.21±1.76
Median (range)	0 (0–6)
Hemoglobin (gm/dl)	
Mean (SD)	12.57±1.22
Median (range)	12.5 (10.3–15.1)
Albumin (gm/dl)	
Mean (SD)	3.99±0.15
Median (range)	4.0 (3.53–4.48)
Esophageal shape in barium, <i>n</i> (%)	
Straight	263 (72.7)
Sigmoid	99 (27.3)
LESP	
Mean (SD)	46.72±12.02
Median (range)	47.27 (11.11–83.71)
Abdominal LES length	
Mean (SD)	2.81±0.38
Median (range)	2.79 (1.44–3.79)
Total LES length	
Mean (SD)	3.91±0.49
Median (range)	3.93 (2.7–5.38)

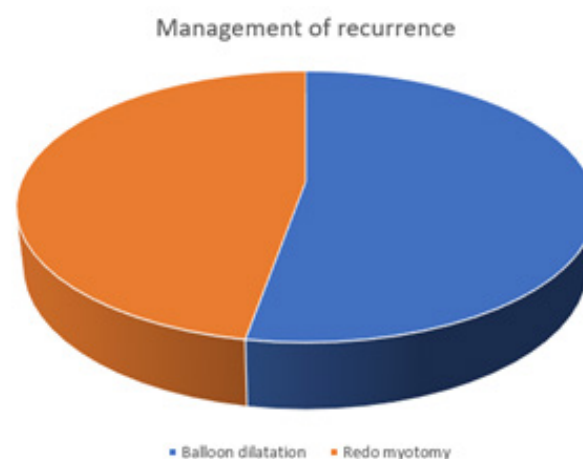
% LES relaxation	
Mean (SD)	63.39±13.86
Median (range)	63.07 (23.07–88.94)

**Table 2:** Intraoperative data

Parameter	Data ( <i>N</i> =362) [ <i>n</i> (%)]
Operative time (h)	
Mean (SD)	1.99±0.64
Median (range)	2 (1.5–4)
Mucosal injury	
	49 (13.5)
Approach	
Open	102 (28.2)
Laparoscopy	239 (66)
Failed laparoscopy (converted to open)	21 (5.8)
Dissection method	
Harmonic	206 (56.9)
Ligasure	54 (14.9)
Kelly clamp	102 (28.2)

**Table 3:** Postoperative complications, hospital stay, and oral intake

Parameter	Data ( <i>N</i> =362)
Abdominal collection, <i>n</i> (%)	1 (0.3)
Reoperation, <i>n</i> (%)	1 (0.3)
Hospital stay (day)	
Mean (SD)	2.94±2.32
Median (range)	2 (2–12)
First oral intake (day)	
Mean (SD)	1.73±1.87
Median (range)	1 (1–8)
Recurrence, <i>n</i> (%)	36 (9.94)

**Fig. 1:** Management of recurrence.

**Table 4:** Changes in EAT-10, Eckardt dysphagia, Eckardt chest pain, Eckardt regurgitation, Eckardt weight loss and Eckardt total scores and at follow-up.

Parameter	Baseline	1 month	6 months	12 months	48 months	P value
<b>Eckardt dysphagia</b>						
Mean (SD)	2.64±0.48	0.28±0.81	0.27±0.8	0.26±0.8	0.26±0.8	< 0.001
Median (range)	3 (2–3)	0 (0–3)	0 (0–3)	0 (0–3)	0 (0–3)	
		< 0.001	< 0.001	< 0.001	< 0.001	
<b>EAT-10</b>						
Mean (SD)	35.34±3.09	3.55±10.23	4.28±10.48	3.39±10.17	3.34±10.27	< 0.001
Median (range)	35 (30–40)	0 (0–38)	0 (0–39)	0 (0–38)	0 (0–39)	
		< 0.001	< 0.001	< 0.001	< 0.001	
<b>Eckardt chest pain</b>						
Mean (SD)	1.46±1.15	0.1±0.32	0.11±0.37	0.11±0.34	0.11±0.37	< 0.001
Median (range)	1 (0–3)	0 (0–2)	0 (0–2)	0 (0–2)	0 (0–2)	
		< 0.001	< 0.001	< 0.001	< 0.001	
<b>Eckardt regurgitation</b>						
Mean (SD)	1.59±1.14	0.09±0.33	0.1±0.35	0.1±0.36	0.1±0.36	< 0.001
Median (range)	2 (0–3)	0 (0–2)	0 (0–2)	0 (0–2)	0 (0–2)	
		< 0.001	< 0.001	< 0.001	< 0.001	
<b>Eckardt weight loss</b>						
Mean (SD)	1.53±1.1	0.02±0.15	0.03±0.16	0.04±0.19	0.03±0.17	< 0.001
Median (range)	2 (0–3)	0 (0–1)	0 (0–1)	0 (0–1)	0 (0–1)	
		< 0.001	< 0.001	< 0.001	< 0.001	
<b>Eckardt total</b>						
Mean (SD)	7.23±1.93	0.49±1.47	0.51±1.54	0.51±1.57	0.51±1.57	< 0.001
Median (range)	7 (2–12)	0 (0–6)	0 (0–7)	0 (0–7)	0 (0–7)	
		< 0.001	< 0.001	< 0.001	< 0.001	

**Table 5:** Changes in GERDHRQL

Parameter	Baseline	1 month	6 months	12 months	48 months	P value
<b>GERDHRQL</b>						
Mean (SD)	1.21±1.76	11.19±5.04	13.0±6.61	11.07±5.35	10.03±6.05	< 0.001
Median (range)	0 (0–6)	11 (0–20)	13 (0–25)	11 (0–20)	10 (0–20)	
		< 0.001	< 0.001	< 0.001	< 0.001	

## DISCUSSION

The absence of esophageal peristalsis and poor relaxations of the LES are the hallmarks of achalasia. In most cases, LES muscle fiber disruption with forceful endoscopic pneumatic dilations (PD) or surgical myotomy division can result in an effective and long-lasting palliation of the associated dysphagia symptoms, even though the pathogenesis of achalasia is still unknown and no conclusive therapy is available<sup>[18]</sup>. Since achalasia is relatively uncommon, most patients will receive care based on local knowledge and preferences.

PD has always been the primary line of treatment; surgery is only performed for patients who cannot get better with repeated dilations<sup>[19]</sup>.

The initial description of laparoscopic Heller myotomy (LHM) for achalasia was provided by Shimi *et al.*,<sup>[20]</sup>. A partial anterior fundoplication was added to LHM, which is now known as the laparoscopic Heller-Dor (LHD) procedure. With its significantly lower surgical morbidity, LHM has quickly emerged as the method of choice for the majority of gastroenterologists and surgeons treating primary achalasia. Since the early 1990s, it appears that LHM has entirely altered the treatment strategy for achalasia<sup>[21]</sup>.



The so-called peroral endoscopic myotomy, a novel endoscopic technique, has just been available and is becoming increasingly popular. It produces positive short- to mid-term outcomes and could displace LHM (as well as PD) as the initial treatment for achalasia<sup>[22]</sup>.

Therefore, the current study aimed to evaluate the postoperative outcomes after Heller cardiomyotomy and Dor fundoplication for patients diagnosed with achalasia. The current study included 362 patients (both prospective and retrospective) who underwent the Heller procedure in the Gastrointestinal Surgical Center for achalasia.

The current study found that the mean age of the included cases was 43.48 years. Women were slightly predominant than men (54.7% vs. 45.3%, respectively). Their BMI ranged between 16.51 and 35.23 kg/m<sup>2</sup>. Smokers represented 13% of the study population. Regarding their physical status, most patients had class I (74.3%), followed by class II (24%), while the minority had class III (1.7%). The current study found that the mean duration of manifestations was 3.35 years. History of previous balloon dilatation was positive in 24.3% of cases. Preoperative mean HB and albumin levels were (12.57 and 3.99 gm/dl, respectively). On barium examination, most cases had a straight esophagus (72.7%), while the remaining ratio had a sigmoid one. Regarding manometric findings, LES had a mean value of 46.72 mm Hg, while %LES relaxation was 63.39%. Abdominal and total LES had mean values of 2.81 and 3.91 cm, respectively.

In harmony with our results, Doubova *et al.*,<sup>[23]</sup> study cohort consisted of 29 men and 25 women, with a median age of 50.5. Preoperative manometry was available for 45 patients and the median average LES pressure was 58 mm Hg. The median integrated relaxation pressure was 54.9 mm Hg. Eight patients had previous interventions for achalasia: 5 patients had dilatation; 1 patient had botulinum toxin injection alone; 1 had botulinum toxin injection and dilatation; and 1 had a prior thoracic myotomy

Interestingly, the current study found that mean duration of the surgical myotomy procedure was (= 1.99). Mucosal injury occurred in 49 cases (13.5%) and all of these cases were discovered intraoperatively, apart from one case which developed postoperative abdominal collection and required reoperation (late mucosal perforation). Most myotomy procedures were performed via laparoscopy (66%), while the open approach was used in 28.2% of cases. The remaining cases (5.8%) showed failure of the laparoscopic approach which was mainly secondary to the occurrence of intraoperative mucosal injury. Esophageal muscle division was achieved by harmonic scalpel (56.9%), Kelly clamp (28.2%), or ligasure (14.9%).

Costantini *et al.*, however,<sup>[24]</sup> reported that all but eight patients (0.8%) had the surgical procedure finished laparoscopically; these patients' conversion to open surgery was caused by mucosal perforation in four cases, adhesions in two, an abdominal mass (an unexpected ectopic kidney) in one, and spleen damage (requiring splenectomy) in one. A single peri-operative death (0.1%) occurred in an elderly male patient with persistent coronary disease, parkinsonism, and a history of unsatisfactory endoscopic treatment.

The current study found that during the scheduled 2-year follow-up, recurrence was detected in 36 cases, with an incidence of 9.94%, denoting success rate exceeding 90%. Thirteen cases of them were presented with sigmoid-shaped esophagus. The median age of the patients at the time of reoperation for recurrence was 53 years. 46% of the patients were males. Recurrence rates were raised in elevated BMI patients. In patients who developed recurrence, 19 of them were managed by endoscopic balloon dilatation, while the remaining cases underwent redo-myotomy. In agreement, the 5-year follow-up study of the European trial found an 84% success rate for LHM<sup>[25]</sup> and in a previous study by Costantini *et al.*,<sup>[24]</sup> who reported good results in 85% of 71 patients who completed a minimum 6-year follow-up.

These earlier results are further supported by a research by Costantini *et al.*,<sup>[24]</sup> which found that the treatment was successful in almost 90% of 1,000 patients with a median follow-up of more than five years (62 months). According to a recent report by Krishnamoham *et al.*,<sup>[26]</sup> out of 500 patients in their series, almost half were contacted and 86% of cases had good dysphagia management at a median follow-up of 77 months.

Specifically, the current study found that regarding the applied scores and questionnaires, the total Eckardt score ranged between 2 and 12 (mean = 7.23). Preoperative EAT-10 score had a mean value of 35.34 (30–40), while GERDHRQL questionnaire had a mean value of 1.21 (range, 0–6). Then the myotomy procedure was associated with a significant decline in Eckardt dysphagia score over the 2-year follow-up period ( $P < 0.001$ ). Similarly, the EAT-10 score expressed equivalent changes like the Eckardt dysphagia score, as it significantly declines over the 2-year follow-up period. Also, Eckardt chest pain score showed a significant decline over the scheduled follow-up period ( $P < 0.001$ ). Eckardt regurgitation and weight loss scores showed similar changes after the same procedure. The total Eckardt score showed a significant decline after the procedure compared with the baseline value ( $P < 0.001$ ). On the other hand, GERDHRQL increased significantly after the myotomy procedure, as it had increased follow-up values compared with the corresponding baseline ones.

In agreement with current results, Asti *et al.*<sup>[27]</sup> found that the proportion of patients with Eckardt stage II–III decreased from 94.9% (n=112) at baseline to 13% (n=15) postoperatively ( $P<.001$ ). The mean preoperative and postoperative Eckardt score was  $6.9\pm 1.9$  and  $1.7\pm 1.2$ , respectively. The mean of differences of the Eckardt score between postoperative and preoperative values was statistically different from 0 ( $P<.001$ ). But, in disagreement with current results, Asti *et al.*<sup>[27]</sup> study confirms that the GERD-HRQL score significantly decreased after operation, indicating that the laparoscopic Heller-Dor operation relieved the outflow obstruction without inducing gastroesophageal reflux. That was in agreement with a meta-analysis of 7,855 patients showing that laparoscopic Heller myotomy combined with fundoplication does reduce the incidence of troublesome postoperative GERD to 8.8%<sup>[28]</sup>.

Additionally, in agreement with current results, in Doubova *et al.*<sup>[23]</sup> cohort study of patients, 2–3 years after LHMDor, an increase was seen in the GERD score, likely corresponding to a recurrence of symptoms; and 6–7 years postoperatively, the GERD score had returned to preoperative levels. That finding was similar to Bloomston *et al.*<sup>[29]</sup> who described an increase in GERD postoperatively but never observed a return to preoperative levels at 3 years of follow-up.

Among the strengths of the present study is a fairly good sample size, considering that achalasia is a rare disease; the multidimensional patient assessment including one structured clinical scoring system and one validated questionnaire, completed pre- and post-operatively in all patients to avoid the phenomenon of recall distortion.

Limitations of the present study are the lack of quality-of-life data measured in the early (3-6 months) postoperative period, the lack of sequential quality of life measurements over time.

## CONCLUSION

The Heller-Dor operation provides sustained symptom relief and a satisfactory quality of life two years after surgery.

## CONFLICT OF INTEREST

There are no conflicts of interest.

## REFERENCES

- Schlottmann F, Patti MG. Esophageal achalasia: current diagnosis and treatment. *Expert Rev Gastroenterol Hepatol* 2018; 12:711–721.
- Islam S. Achalasia. *Semin Pediatr Surg* 2017; 26:116–120.
- Wadhwa V, Thota PN, Parikh MP, *et al.* Changing Trends in Age, Gender, Racial Distribution and Inpatient Burden of Achalasia. *Gastroenterology Res* 2017; 10:70–77.
- Pressman A, Behar J. Etiology and Pathogenesis of Idiopathic Achalasia. *J Clin Gastroenterol* 2017; 51:195–202.
- Francis DL, Katzka DA. Achalasia: update on the disease and its treatment. *Gastroenterology* 2010; 139:369–374.
- Vaezi MF, Pandolfino JE, Yadlapati RH, *et al.* ACG Clinical Guidelines: Diagnosis and Management of Achalasia. *Am J Gastroenterol* 2020; 115:1393–1411.
- Khashab MA, Vela MF, Thosani N, *et al.* ASGE guideline on the management of achalasia. *Gastrointest Endosc* 2020; 91:213–227.
- Tuason J, Inoue H. Current status of achalasia management: a review on diagnosis and treatment. *J Gastroenterol* 2017; 52:401–406.
- Mari A, Abu Baker F, Pellicano R, *et al.* Diagnosis and Management of Achalasia: Updates of the Last Two Years. *J Clin Med* 2021; 10.
- Zaninotto G, Leusink A, Markar SR. Management of achalasia in 2019. *Curr Opin Gastroenterol* 2019; 35:356–362.
- Haisley KR, Preston JF, Dolan JP, *et al.* Twenty-year trends in the utilization of Heller myotomy for achalasia in the United States. *Am J Surg* 2017; 214:299–302.
- Rosemurgy AS, Morton CA, Rosas M, *et al.* A single institution's experience with more than 500 laparoscopic Heller myotomies for achalasia. *J Am Coll Surg* 2010; 210:637-645–645-637.
- Kummerow Broman K, Phillips SE, Faqih A, *et al.* Heller myotomy versus Heller myotomy with Dor fundoplication for achalasia: long-term symptomatic follow-up of a prospective randomized controlled trial. *Surg Endosc* 2018; 32:1668–1674.
- Eckardt VF, Stauf B, Bernhard G. Chest pain in achalasia: patient characteristics and clinical course. *Gastroenterology* 1999; 116:1300–1304.

15. Hansen T, Kjaersgaard A. Item analysis of the Eating Assessment Tool (EAT-10) by the Rasch model: a secondary analysis of cross-sectional survey data obtained among community-dwelling elders. *Health and Quality of Life Outcomes* 2020; 18:1–14.
16. Velanovich V. The development of the GERD-HRQL symptom severity instrument. *Diseases of the Esophagus* 2007; 20:130–134.
17. Kahrilas PJ, Bredenoord AJ, Fox M, *et al.* The Chicago Classification of esophageal motility disorders, v3.0. *Neurogastroenterol Motil* 2015; 27:160–174.
18. Capovilla G, Costantini A, Provenzano L, *et al.* Long-term Outcomes (5 Years or More) After Myotomy. *Foregut* 2022; 2:432–439.
19. Vespa E, Barchi A, Passaretti S, *et al.* Pneumatic dilation for achalasia in the ‘POEM era’: Still a valuable ally. *Digestive and Liver Disease* 2023.
20. Shimi S, Newman E, Hopwood D, *et al.* Semi-permeable microcapsules for cell culture: Ultra-structural characterization. *Journal of microencapsulation* 1991; 8:307–316.
21. Aoki T, Ozawa S, Hayashi K, *et al.* Laparoscopic Heller myotomy and Dor fundoplication following an unsuccessful peroral endoscopic myotomy. *Surg Case Rep* 2023; 9:106.
22. Zhang X, Modayil R, Stavropoulos SN. Peroral Endoscopic Myotomy (POEM) for Achalasia: Indications, Techniques, and Outcomes. *Gastrointest Pancreatico-Biliary Diseases: Adv Diagnos Therap Endosc* 2021:1–32.
23. Doubova M, Gowing S, Robaidi H, *et al.* Long-term symptom control after laparoscopic Heller myotomy and Dor fundoplication for achalasia. *Ann Thorac Surg* 2021; 111:1717–1723.
24. Costantini M, Salvador R, Capovilla G, *et al.* A thousand and one laparoscopic Heller myotomies for esophageal achalasia: a 25-year experience at a single tertiary center. *J Gastrointest Surg* 2019; 23:23–35.
25. Moonen A, Annese V, Belmans A, *et al.* Long-term results of the European achalasia trial: a multicentre randomised controlled trial comparing pneumatic dilation versus laparoscopic Heller myotomy. *Gut* 2016; 65:732–739.
26. Krishnamohan P, Allen MS, Shen KR, *et al.* Long-term outcome after laparoscopic myotomy for achalasia. *J thorac cardiovasc surg* 2014; 147:730–737.
27. Asti E, Sironi A, Lovece A, *et al.* Health-related quality of life after laparoscopic Heller myotomy and Dor fundoplication for achalasia. *Surgery* 2017; 161:977–983.
28. Campos GM, Vittinghoff E, Rabl C, *et al.* Endoscopic and surgical treatments for achalasia: a systematic review and meta-analysis. *Ann surg* 2009; 249:45–57.
29. Bloomston M, Durkin A, Boyce HW, *et al.* Early results of laparoscopic Heller myotomy do not necessarily predict long-term outcome. *Am j surg* 2004; 187:403–407.