

Endovascular management of central venous occlusion in the hemodialysis patients

Original Article

Abdelrahman S. A. Eldeib, Ehab M. Abdo and Sameh E. Elimam

Department of Vascular and Endovascular Surgery, Faculty of Medicine (Girls), Al-Azhar University, Cairo, Egypt.

ABSTRACT

Background: A Central vein occlusion is a frequent complication in end-stage renal disease patients undergoing regular hemodialysis (HD). Percutaneous transluminal angioplasty (PTA), with or without stenting, has become the primary treatment method for this condition.

Objective: To evaluate the effectiveness and safety of PTA, with or without stenting, in treating central venous occlusion in HD patients.

Patients and Methods: This prospective study included 30 end-stage renal disease patients on HD who exhibited symptoms of venous hypertension such as arm and facial edema, painful hand, color changes like cyanosis, ulceration, distended collateral veins on the chest wall, impaired flow during dialysis, or prolonged bleeding from the access puncture site postdialysis. Patients underwent duplex ultrasonography, venography, nerve conduction studies, and consultations with cardiology and nephrology before receiving PTA using balloons or venous stents.

Results: The key predictors of technical success for PTA, with or without stenting, included the type of AV access (brachiocephalic fistula + brachiobasilic fistula/AVBG), type of lesion (stenosis/occlusion), and the length of the affected segment (<5 cm). Postintervention, there were statistically significant improvements in pain, swelling, and dilated chest and neck veins. However, there was no significant improvement in ulceration, cyanosis, or impaired finger function. No statistically significant difference in patency rates between PTA with stenting (100%) and without stenting (76.5%).

Conclusion: PTA enhances primary patency for treating central vein stenosis or occlusion in HD patients, with no significant difference in patency rates between procedures with or without stenting.

Key Words: Central venous occlusion, end stage renal disease, hemodialysis, percutaneous transluminal angioplasty.

Received: 13 August 2024, **Accepted:** 4 September 2024, **Published:** 1 January 2025

Corresponding Author: Abdelrahman S. A. Eldeib, MSc, Department of Vascular and Endovascular Surgery, Faculty of Medicine, (Girls), Al-Azhar University, Cairo, Egypt. **Tel.:** +0109 783 8596, **E-mail:** abdelrahmansobhyali@gmail.com

ISSN: 1110-1121, January 2025, Vol. 44, No. 1: 272-278, © The Egyptian Journal of Surgery

INTRODUCTION

Central venous occlusion (CVO) is a significant complication in hemodialysis (HD) patients, primarily due to the long-term use of central venous catheters (CVCs). This condition can lead to substantial morbidity, including compromised vascular access, which is critical for the effective management of HD. The endovascular management of CVO has emerged as a crucial area of interest, offering minimally invasive alternatives to traditional surgical interventions^[1].

HD, a lifesaving treatment for patients with end-stage renal disease (ESRD), relies on efficient and reliable vascular access. The use of CVCs, while necessary, poses a risk for the development of venous stenosis, occlusions and venous hypertension due to repeated punctures, long-term catheter placement, and associated infections, which severely impacts the functionality of arteriovenous fistulae (AVFs), essential for effective HD. Studies have shown that up to 40% of HD patients may develop some

form of central venous stenosis or occlusion, which can significantly impact their treatment outcomes^[2].

The management of venous hypertension resulting from CVO has evolved with the advent of endovascular interventions, particularly percutaneous transluminal angioplasty (PTA) and stenting. PTA, with or without the addition of stents, has emerged as a promising technique to restore venous patency and alleviate the symptoms associated with venous hypertension in HD patients. These minimally invasive procedures offer several advantages, including shorter recovery times and the preservation of existing vascular access sites, which are pivotal for patients who rely on AVFs for dialysis^[3].

Despite the potential benefits of PTA and stenting, there remains a need for comprehensive evaluation to determine their effectiveness and safety in the treatment of CVO-induced venous hypertension in HD patients. Previous studies have shown variable outcomes in terms of procedural success and long-term patency rates,

necessitating further research to establish standardized treatment protocols and improve patient outcomes^[4].

The rationale of our study is to determine the effectiveness and safety of PTA, with or without stenting, in treating venous hypertension due to CVO in HD patients with functioning AVFs.

PATIENTS AND METHODS:

This prospective study was conducted at Dialysis Units, Al-Zahraa University Hospital between February 2023 and February 2024. This included 30 HD patients with ESRD, all exhibiting symptomatic venous hypertension. Symptoms such as arm and face edema, painful hand, cyanosis, ulceration, distended collateral veins, impaired dialysis flow, and prolonged postdialysis bleeding were prevalent.

Patients selected for PTA had to meet specific clinical and radiological criteria, confirmed through duplex ultrasonography (US) and computed tomography venography (CTV). Inclusion criteria included adult and elderly ESRD patients on regular HD complicated by central venous disease (CVD). Exclusion criteria ruled out patients on peritoneal dialysis, those with prior failed endovascular procedures for the same condition, lower limb AVFs, pediatric patients, congenital central vein anomalies, mediastinal syndrome, pregnancy, and contrast media allergies.

The study documentation included a thorough medical history and clinical examination, focusing on venous access history, chronic diseases, past surgeries, pain assessment, limb edema measurements, skin changes, and wrist and hand joint movements. Investigations encompassed laboratory tests, duplex US, venography, nerve conduction studies if needed, and consultations with cardiac and nephrology specialists.

Treatment involved percutaneous angioplasty using balloons or venous stents, performed under local anesthesia with sedation for severe pain. The procedure involved placing a vascular sheath under US guidance into the main draining vein of the fistula or via the venous side of the graft in the symptomatic arm. Balloon angioplasty was the first-line therapy, using adjacent normal-looking veins to accurately assess balloon size. Balloons were carefully inflated, taking patient pain complaints into account during dilatation. Stents were inserted in cases of refractory angioplasty with immediate flow-limiting elastic recoil, residual stenosis greater than 30%, persistent significant collaterals, or early recurrent symptomatic stenosis within 4 weeks after balloon angioplasty.

The postoperative evaluation included immediate assessment of symptom relief and follow-up visits at 1, 3, and 6 months to monitor shunt feasibility for

dialysis, duplex US to detect blood flow improvement and documentation of any complications. Each case was meticulously documented regarding anesthesia type, puncture site, procedure duration, and equipment used. Preprocedural medication included a loading dose of Clopidogrel, with Heparin administered intraprocedurally and Aspirin and Apixaban, prescribed postprocedurally to ensure proper anticoagulation.

Statistical analysis

The data collected were analyzed using the Statistical Package for Social Sciences (SPSS), version 26.0 (SPSS Inc., Chicago, Illinois, USA). Quantitative data were summarized as mean±standard deviation and ranges, while qualitative variables were reported as frequencies and percentages. For statistical analysis, we employed the independent-samples t-test to compare mean values between groups. The χ^2 test and Fisher's exact test were used to evaluate associations between categorical variables. Additionally, Kaplan–Meier survival analysis was utilized to assess time-to-event outcomes. We considered *P value* significant if less than 0.05.

RESULTS:

The study group consisted of 30 patients with a mean age of 52.53±6.60 years. The majority were male (83.3%), with the remaining 16.7% being female. Common comorbidities included hypertension (23.3%), diabetes mellitus (DM) (16.7%), a combination of hypertension and DM (40.0%), and heart diseases (20.0%). A significant portion of the patients (20.0%) were smokers (Table 1).

Patients had a mean duration of chronic renal failure of 9.62±7.17 years and a mean duration of fistula use of 3.63±2.74 months. All patients had upper extremity access sites, with a history of previous CVC insertion in subclavian veins (76.7%) or internal jugular veins (23.3%). The central veins affected included subclavian (63.3%) and innominate veins (36.7%), with the right upper extremity being more commonly affected (73.3%). The types of AV access were brachiocephalic fistula (BCF) (46.7%), brachio basilic fistula (BBF) (33.3%), and AVBG (Arteriovenous bridge graft) (20.0%). The lesions were categorized as stenosis (36.6%) or occlusion (63.4%), with the length of the affected segments ranging from 1 to 5 cm (Table 2).

All patients presented with swelling (100%), with other symptoms including pain (30%), dilated chest and neck veins (86.7%), cyanosis (20%), impaired finger function (6.7%), and ulcers (6.7%). Interventions included PTA with or without stenting. Postintervention, there was a significant improvement in total flow rates at 1 month (mean change of 1371.36±552.86 ml/min, $P<0.001$), 3 months (mean change of 1445.71±439.59 ml/min,

$P<0.001$), and 6 months (mean change of 1370.0 ± 581.19 ml/min, $P<0.001$) (Table 3).

At 1 month, 76.7% of patients showed improvement, which increased to 95.7% at 6 months. There were 23.3% primary failures at 1 month, and some patients required re-intervention with secondary stenting. One patient died during the 6-month follow-up period due to myocardial infarction (Table 4).

Technical success was achieved in 76.7% of cases. There was no significant relationship between technical success and general characteristics such as age, sex, and comorbidities. However, significant predictors for technical success included the type of AV access (BCF and BBF over AVBG, $P<0.001$), type of lesion (stenosis over occlusion, $P=0.046$), and length of the affected segment (<5 cm over >5 cm, $P=0.023$) (Table 5).

There was a significant reduction in pain ($P=0.022$), swelling ($P<0.001$), and dilated chest and neck veins ($P<0.001$) postintervention. Cyanosis and impaired finger function did not show statistically significant improvement (Table 6).

Morbidity included access site hematoma in 10% of patients and stent migration in 3.3%. Mortality was 3.3%, with one patient dying from myocardial infarction during the 6-month follow-up.

Kaplan–Meier survival analysis showed no significant difference in patency rates between PTA with stent (100% patency) and PTA without stent (76.5% patency), with a log-rank χ^2 value of 1.653 (df=1, $P=0.201$) (Fig. 1).

Table 1: Patient’s demographics

General characteristics	Study group (n=30) N (%)
Age (year) Mean±SD	52.53±6.60
Sex	
Male	25 (83.3)
Female	5 (16.7)
Comorbidities	
Hypertension	7 (23.3)
DM	5 (16.7)

Hypertension and DM	12 (40.0)
Heart diseases	6 (20.0)
Smoking	
Yes	6 (20.0)
No	24 (80.0)

Table 2: Clinical characteristics of the patients

Clinical characteristics	Study group (n=30) N (%)
Duration of chronic renal failure (year)	
Mean±SD	9.62±7.17
Range	1–24
Duration of fistula (month)	
Mean±SD	3.63±2.74
Range	1–12
Access site	
Upper extremity	30 (100)
History of previous CVC insertion	
Subclavian veins	23 (76.7)
Internal Jugular veins	7 (23.3)
Central veins affected	
Subclavian	19 (63.3)
Innominate	11 (36.7)
Side affected	
Right upper extremity	22 (73.3)
Left upper extremity	8 (26.7)
Type of AVaccess	
BCF	14 (46.7)
BBF	10 (33.3)
AVBG	6 (20)
Type of lesion	
Stenosis	11 (36.6)
Occlusion	19 (63.4)
Length of affected segment	
1–3 cm	8 (26.6)
3–5 cm	13 (43.4)
5 cm	9 (30.0)

Table 3: Distribution of the studied group regarding the flow rate (ml/min) pre and postintervention

	Total flow (ml/min)			Paired <i>t</i> test	<i>P</i> value
	Pre Mean±SD	Post Mean±SD	Relative change		
Patients improved at within 1 month (n=22)	593.18±134.63	1964.54±598.28	1371.36±552.86	11.63	<0.001*
Patients improved at 3 months (n=21)	601.90±131.43	2047.61±465.21	1445.71±439.59	15.07	<0.001*
Patients improved at 6 months (n=20)	586.0±138.95	1956.0±628.10	1370.0±581.19	10.54	<0.001*

Table 4: Follow-up of the studied group

Outcome	Follow-up		
	Within 1 month (N=30) n (%)	After 3 months (N=23) n (%)	After 6 months (N=23) n (%)
Improved patients	23 (76.7)	18 (78.3)	22 (95.7)
Primary failure	7 (23.3)	–	–
Re-intervention by		4 (17.3)	–
Secondary Stenting	–	4 (17.3)	–
Died patients	–	–	1 (4.3)

Table 5: Relation between technical success and clinical characteristics

Clinical characteristics	Technical success			Test value	P value
	Success (n=23)	Failed (n=7)			
Duration of chronic renal failure (year) [Mean±SD]	9.62±7.17	8.57±4.68	10.36±6.12	0.825	0.416
Duration of fistula (month) [Mean±SD]	3.63±2.74	3.41±2.01	3.75±2.61	0.366	0.717
History of previous CVC insertion, n (%)					
Subclavian veins (n=23)	18 (78.3)	5 (71.4)		0.019	0.892
Internal Jugular veins (n=7)	5 (21.7)	2 (28.6)			
Central veins affected, n (%)					
Subclavian (n=19)	15 (65.2)	4 (57.1)		0.036	0.952
Innominate (n=11)	8 (34.8)	3 (42.9)			
Side affected, n (%)					
Right upper extremity (n=22)	17 (73.9)	5 (71.4)		0.128	0.720
Left upper Left extremity (n=8)	6 (26.1)	2 (28.6)			
Type of AV access, n (%)					
BCF (n=14)	13 (56.5)	1 (14.3)		15.120	<0.001**
BBF (n=10)	9 (39.1)	1 (14.3)			
AVBG (n=6)	1 (4.3)	5 (71.4)			
Type of lesion, n (%)					
Stenosis(n=11)	11 (47.8)	0		4.427	0.046*
Occlusion (n=19)	13 (52.2)	7 (100.0)			
Length of affected segment, n (%)					
1–3 cm (n=8)	7 (30.4)	1 (14.3)		7.526	0.023*
3-5 cm (n=13)	12 (52.2)	1 (14.3)			
>5 cm (n=9)	4 (17.4)	5 (71.4)			

P value greater than 0.05 is insignificant.

*P value less than 0.05 is significant.

**P value less than 0.001 is highly significant.

Table 6: Comparison between symptoms at presentation and after intervention

Symptoms	At admission (n=30)		After intervention (n=30)		x ²	P value
	N (%)		Failed (n=7) N (%)	Success (n=23) N (%)		
Pain	9 (30.0)		2 (22.2)	7 (77.8)	5.226	0.022*
Swelling	30 (100.0)		7 (23.3)	23 (76.7)	16.824	<0.001**
Ulcer	2 (6.7)		1 (50.0)	1 (50.0)	0.000	1.000
Dilated chest and neck veins	26 (86.7)		7 (26.9)	19 (73.1)	10.886	<0.001**
Cyanosis	6 (20.0)		2 (33.3)	4 (66.7)	1.227	0.268
Impaired fingers' function	2 (6.7)		2 (100.0)	0 (0.0)	3.000	0.083

P value greater than 0.05 is insignificant.

*P value less than 0.05 is significant.

**P value less than 0.001 is highly significant.

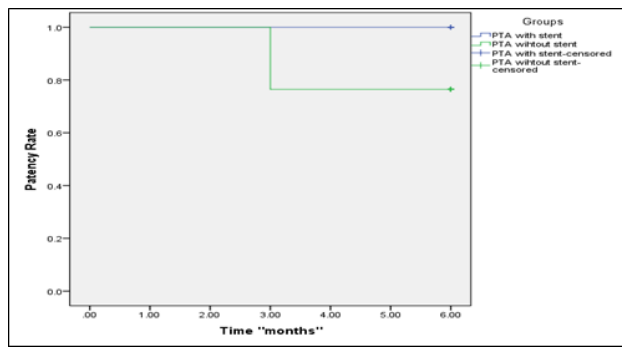


Fig. 1: Kaplan–Meier survival curves in percutaneous transluminal angioplasty with stent group and percutaneous transluminal angioplasty without stent.

Case (1): A 58-year-old male patient presented with significant edema in the left arm, forearm, and hand, indicative of a stenotic lesion in the left innominate vein. She underwent PTA, where the waisting of the balloon during inflation (black arrow) highlighted the stenotic area. Complete inflation of a 16x80mm venous balloon was achieved, improving blood flow post-PTA. Preoperative images showed severe edema in the arm and forearm, which significantly resolved 6 months post-PTA, markedly enhancing limb function and quality of life. Additionally, preoperative hand edema resolved within three months post-PTA, with visible superficial dorsal veins and normal skin corrugations, underscoring the effectiveness of PTA in alleviating symptoms of CVO (Figs. 2–4).

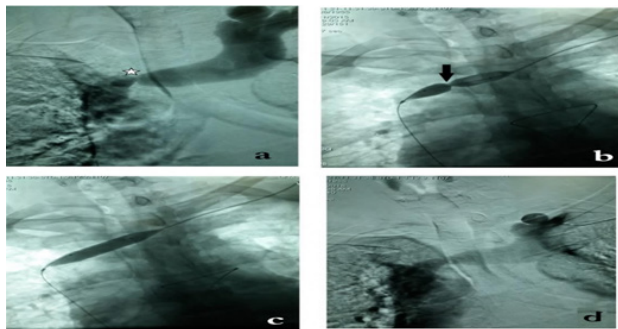


Fig. 2: A patient with a stenotic lesion in the left innominate vein (a) underwent percutaneous transluminal angioplasty. The waisting of the balloon during inflation is shown by the black arrow (b). Complete inflation of the 16x80mm venous balloon was achieved (c), resulting in improved blood flow post-Percutaneous transluminal angioplasty (d).

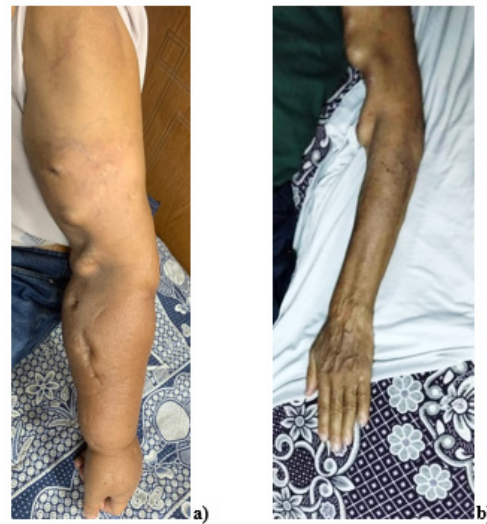

Fig. 3: Preoperative images show significant arm and forearm edema (a). 6 months post- Percutaneous transluminal angioplasty, the edema resolved substantially, improving limb function and quality of life (b).

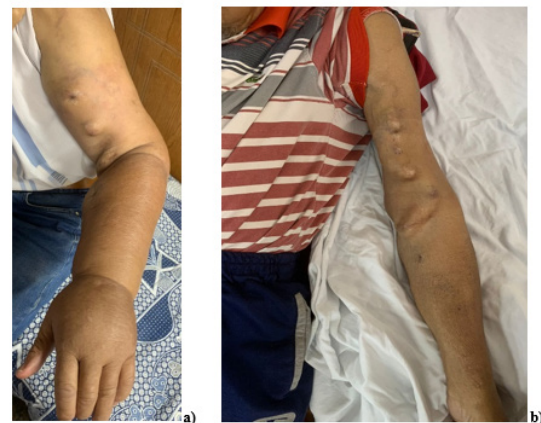

Fig. 4: Preoperative images show substantial hand edema (a). Three months post- percutaneous transluminal angioplasty, the edema resolved, with visible superficial dorsal veins and normal skin corrugations (b), demonstrating the effectiveness of percutaneous transluminal angioplasty in managing central venous occlusion symptoms.

DISCUSSION

Venous hypertension is a major issue for chronic HD patients, leading to debilitating upper extremity edema and compromised arteriovenous access function^[5]. This study aimed to evaluate the effectiveness and safety of PTA, with or without stenting, in treating venous hypertension caused by CVO in HD patients with functioning AVFs.

Our study included 30 HD patients, predominantly male (83.3%) with a mean age of 52.53±6.60 years. Common comorbidities included hypertension (23.3%) and DM (16.7%). In comparison, Mazhar *et al.*^[6] reported a similar demographic with 80% male patients and a mean age of 55 years. Mehrotra^[7] also found that younger patients (<50 years) had a higher success rate (82%) compared with older patients (>60 years) who had a success rate of 65%.

All patients presented with swelling (100%), pain (30%), and dilated chest and neck veins (86.7%). Postintervention, significant improvements in total flow rates were observed, with a technical success rate of 76.7%. Yildiz *et al.*^[8] reported that 100% of their patients had technical success and 97% had clinical success, with a dysfunction recurrence rate of 30.4%. Additionally, Salmela *et al.*^[9] found that early PTA had a technical success rate of 85% and a primary patency rate of 70% at 6 months, highlighting the effectiveness of early intervention.

At 1 month, 76.7% of our patients showed improvement, increasing to 95.7% at 6 months. Primary failure was observed in 23.3% of patients at 1 month, with some requiring re-intervention. One patient (3.3%) died during the 6-month follow-up due to myocardial infarction. Neuen *et al.*^[10] reported a primary patency rate of 65% at 6 months, decreasing to 40% at 12 months, while Boutrous *et al.*^[11] found a primary patency rate of 87% at 3 months, 67.4% at 6 months, and 51.7% at 12 months, underscoring the importance of ongoing follow-up.

We found no significant relationship between general characteristics (age, sex, comorbidities) and technical success. Significant predictors included the type of AV access (BCF and BBF over AVBG), type of lesion (stenosis over occlusion), and length of the affected segment (<5 cm over >5 cm). Aggarwal^[12] reported success rates of 95–100% for acute, nonocclusive thrombus, 50–80% for acute, occlusive thrombus, 70–90% for subacute, fibrinous occlusions, and 30–50% for chronic, fibrotic occlusions. Neuen *et al.*^[10] reported that newer fistulae (<6 months) and longer lesion lengths (>2 cm) were associated with lower primary patency rates of 55% and 45% at 6 and 12 months, respectively.

Postintervention, significant improvements were observed in symptoms such as pain, swelling, and dilated chest and neck veins. However, improvements in ulceration, cyanosis, and impaired finger function were not statistically significant. Horita^[13] reported a 75% improvement in pain and 85% reduction in swelling post-PTA. Stival and Montesi^[14] observed significant symptom relief in 80% of their patients, with improvements in chest pain (70%), shortness of breath (65%), and arm swelling (90%).

Complications included access site hematoma (10%), stent migration (3.3%), and one mortality (3.3%) due to myocardial infarction. Duerinckx *et al.*^[15] reported a complication rate of 15%, including vascular trauma (5%), infection (3%), and re-narrowing of the vein (7%). Yildiz *et al.*^[8] found a 10% complication rate, primarily due to access site hematoma (6%) and infection (4%).

There was no statistically significant difference in patency rates between PTA with and without stenting (100% vs. 76.5%, respectively). Saroukhani and Sedighi^[16] reported a primary patency rate of 85% at 3 months, which declined to 50% at 6 months. Boutrous *et al.*^[11] found a primary patency rate of 87% at 3 months, 67.4% at 6 months, and 51.7% at 12 months. Liao *et al.*^[17] reported that drug-coated balloons showed better long-term patency rates of 70% at 12 months compared with 45% for conventional angioplasty.

This study's strengths include its comparative clinical cross-sectional design, with no loss of patients, ensuring complete data integrity. Potential confounders were excluded before analysis. As the first study at Al-Azhar University Hospitals to assess PTA with or without stenting for venous hypertension in HD patients, it provided valuable insights. Consistent imaging procedures and uniform clinical assessments by the same team enhanced the study's reliability. Additionally, the inclusion of both rural and urban populations ensured a representative sample.

However, the study's limitations include being hospital-based with a relatively small sample size, which limits the generalizability of the findings. The absence of a multicentric approach increases the risk of publication bias. These factors underscore the need for larger, multicentric studies to validate and expand upon these findings.

CONCLUSION

Our study found that PTA enhances primary patency for central vein stenosis or occlusion in HD patients, with no significant difference in patency rates between PTA with and without stenting. PTA is effective, safe, and preferred over open surgery, despite the potential for restenosis and

re-intervention. Key factors for success include the type of AV access, lesion type, and segment length. We recommend endovascular intervention as the first-line treatment for these patients. Emphasis on training in PTA techniques.

CONFLICT OF INTEREST

There are no conflicts of interest.

REFERENCES

- Kelly YP, Kuperman GJ, Steele DJ, Mendu ML. Interoperability and patient electronic health record accessibility: opportunities to improve care delivery for dialysis patients. *Am J Kidney Dis* 2020; 76:427–430.
- Mollahosseini A, Abdelrasoul A, Shoker A. Challenges and advances in hemodialysis membranes. *Adv Membr Technol* 2020.
- Echefu G, Stowe I, Lukan A, Sharma G, Basu-Ray I, Guidry L, *et al*. Central vein stenosis in hemodialysis vascular access: clinical manifestations and contemporary management strategies. *Front Nephrol*. 2023; 3:1280666.
- Kitrou P, Katsanos K, Karnabatidis D. Management of central venous stenoses and occlusions. *Cardiovasc Intervent Radiol*. 2023; 46:1182–1191.
- Lok CE, Huber TS, Orchanian-Cheff A, Rajan DK. Arteriovenous access for hemodialysis: a review. *JAMA* 2024; 331:1307–1317.
- Mazhar A, Kay C, Altay F. Effect of age and sex on the outcome of percutaneous transluminal angioplasty in hemodialysis patients. *J Vasc Surg* 2017; 65:814–820.
- Mehrotra R. Factors affecting the success of percutaneous transluminal angioplasty of hemodialysis fistulas. *Ren Fail* 2017; 39:226–233.
- Yildiz I. The efficacy of percutaneous transluminal angioplasty for the endovascular management of arteriovenous fistula dysfunction: a retrospective analysis in patients with end-stage renal disease. *Int Angiol* 2020; 39:341–348.
- Salmela B, Hartman J, Peltonen S, Albäck A, Lassila R. Thrombophilia and arteriovenous fistula survival in ESRD. *Clin J Am Soc Nephrol* 2013; 8:962–968.
- Neuen BL, Gunnarsson R, Webster AC, Baer RA, Gollidge J, Mantha ML. Predictors of patency after balloon angioplasty in hemodialysis fistulas: a systematic review. *J Vasc Interv Radiol*. 2014; 25:917–924.
- Boutrous ML, Alvarez AC, Okoye OT, Laws JC, Jacobs DL, Smeds MR. Stent-graft length is associated with decreased patency in treatment of central venous stenosis in hemodialysis patients. *Ann Vasc Surg* 2019; 59:225–230.
- Aggarwal S. Percutaneous transluminal angioplasty in the management of central venous occlusion: a single-center experience. *J Vasc Interv Radiol* 2002; 13:1133–1138.
- Horita Y. Percutaneous transluminal angioplasty for central venous stenosis or occlusion in hemodialysis patients. *J Vasc Access* 2019; 20(1_suppl):87–92.
- Stival C, Montesi L. Percutaneous transluminal angioplasty for central venous occlusion. *J Vasc Surg Venous Lymphat Disord* 2019; 7:210–219.
- Duerinckx AJ, Tuytelaars J, Vanholder R. Complications of percutaneous transluminal angioplasty in the treatment of central venous occlusion in hemodialysis patients. *Acta Clin Belg* 2018; 73:177–184.
- Saroukhani A, Sedighi A. Efficacy of balloon angioplasty in patients with central venous stenosis or obstruction resulting from central vein catheter placement. *Adv Biomed Res* 2023; 12:223.
- Liao MT, Chen MK, Hsieh MY, Yeh NL, Chien KL. Drug-coated balloon versus conventional balloon angioplasty of hemodialysis arteriovenous fistula or graft: a systematic review and meta-analysis of randomized controlled trials. *PLoS ONE* 2020; 15:4.